

Renal Coccidiosis

Cause

Renal coccidiosis is caused by protozoal parasites that infect the kidneys and associated tissues. Most of the coccidia that infect the tissues in birds are *Eimeria* sp. As with most other parasitic infections, this infection is not synonymous with clinical or apparent disease. Asymptomatic infections are far more common than those that are severe and cause mortality.

Life Cycle

Typical *Eimeria*-type life cycles have an internal or endogenous phase of development within the host. A bird becomes a host when it feeds or drinks from a source that is contaminated with oocysts (cystic, infectious stage) that have become infectious following multiple fission of the sporont (zygote) to form four sporocysts, each containing two infective sporozoites.

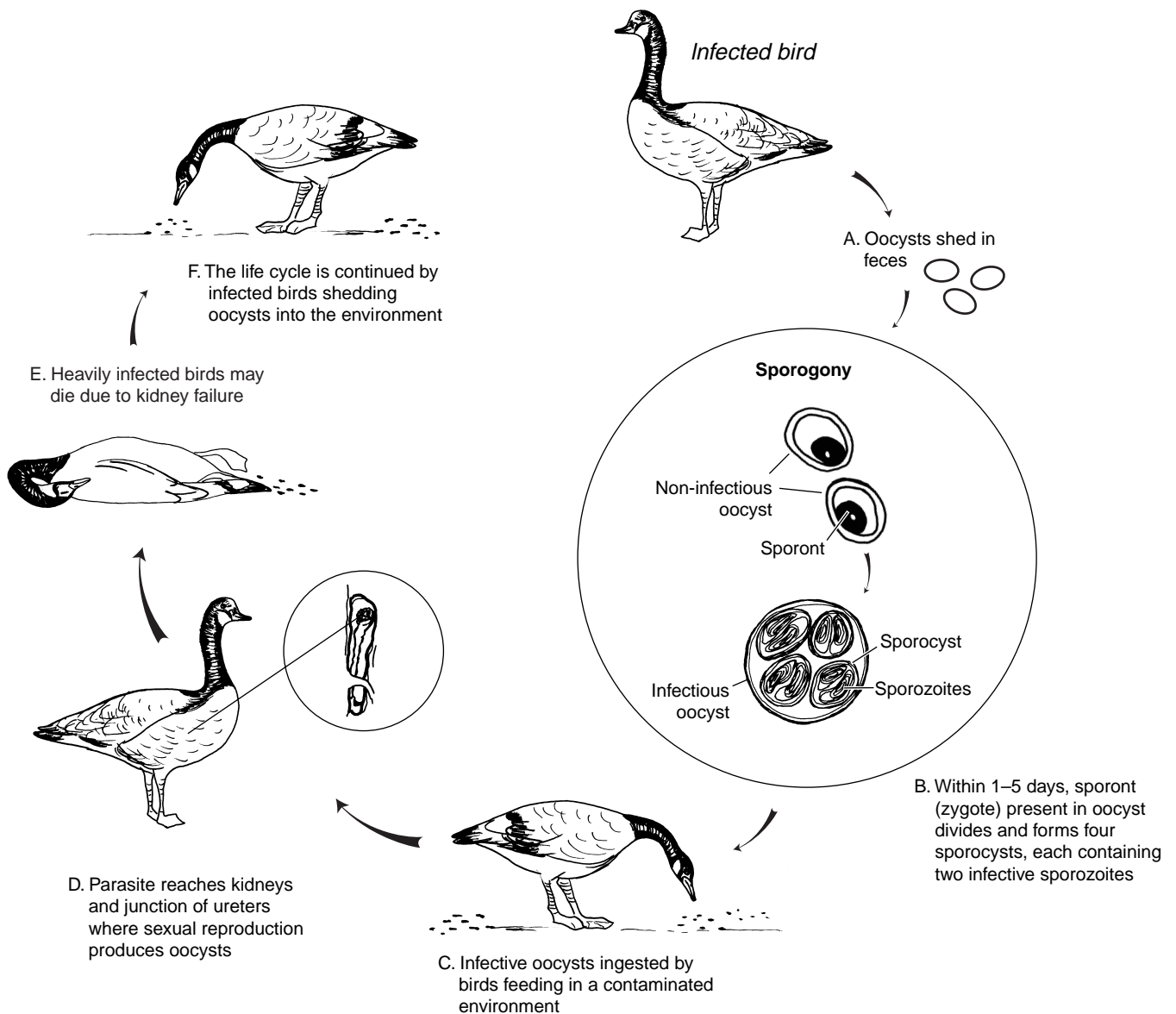


Figure 27.1 Life cycle of *Eimeria truncata*, which is one of the parasites that causes renal coccidiosis.

tious sporozoites (sporogony) within each oocyst. The infective sporozoites within the sporocysts of the oocysts invade the bird's intestinal lining, where they may undergo several developmental stages depending on the *Eimeria* species. *E. truncata*, the most well known of the renal coccidia, matures and reproduces only in the kidneys and in the cloaca near its junction with the ureter (Fig. 27.1). It is not known how the *E. truncata* sporozoites get from the intestine to the kidneys; the sporozoites probably undergo asexual reproduction or multiple fission before they reach the kidneys. The

sexual phase of the *E. truncata* life cycle, or gamogony, takes place in the kidneys, producing noninfectious oocysts which are voided with the host bird's feces into the environment. Sporulated oocysts are resistant to environmental extremes, and their sporozoites can remain infectious for months.

The life cycles of the coccidia that cause renal coccidiosis are similar to those that cause intestinal coccidiosis (see Chapter 26). However, less is known about the species of *Eimeria* that cause renal coccidiosis than about those that cause intestinal coccidiosis.











Types of birds		Species of coccidia
Waterfowl		
Ducks		<i>Eimeria boschadis</i> , <i>E. somatarie</i> , <i>E. sp.</i>
Geese		<i>E. truncata</i> , <i>E. sp.</i>
Swans		<i>E. christianseni</i>
Fish-eating birds		
Gulls		<i>E. wobeseri</i> , <i>E. goelandi</i> , <i>E. renicola</i>
Cormorants		<i>E. sp.</i>
Loons		<i>E. graviae</i>
Marine Birds		
Puffins		<i>E. fracterculae</i>
Shearwaters		<i>E. sp.</i> , unidentified coccidia
Land Birds		
Owls		Unidentified coccidia
Woodcock		Unidentified coccidia (in captive colony)

Figure 27.2 Reported occurrences of renal coccidia in wild birds.

Species Affected

Avian coccidiosis was first reported in France. Canadian investigators have reported that virtually all species of wild ducks they examined are susceptible to renal coccidiosis. Different species of renal coccidia are found in different species of birds (Fig. 27.2). Most reports of renal coccidiosis are of asymptomatic birds or birds that show minor physiological or pathological changes due to the parasite. Young birds and those that have been stressed by various conditions are most likely to have clinical cases of renal coccidiosis. Mortality has occurred in free-ranging wild geese, eider ducklings, and double-crested cormorants. Disease in domestic geese is usually acute, lasts only 2–3 days, and can kill large segments of the flock.

Distribution

Renal coccidiosis is found in birds worldwide.

Seasonality

Mortality from renal coccidiosis is most common during periods of the year when birds are densely aggregated on their breeding grounds or wintering areas.

Field Signs

There are no specific field signs that indicate that a bird is infected with renal coccidia. Young birds will often be emaciated and weak, but many other diseases cause similar clinical signs.

Gross Lesions

Infected birds may be emaciated and have a prominent keel. In severe infections, kidneys may become enlarged and pale, containing multiple spots or foci of infection that coalesce into a mottled pattern (Fig. 27.3). Cutting through these white foci may reveal material that has the consistency of chalk due to the build up of uric acid salts (Fig. 27.4).

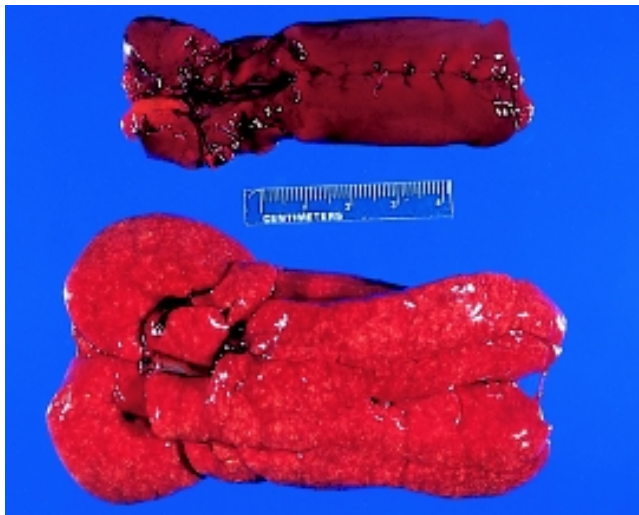


Photo by J. Christian Fransson

Figure 27.3 Kidneys from double-crested cormorants. Top: normal size and color. Bottom: enlarged kidneys with diffuse pale areas from a bird infected with renal coccidia.

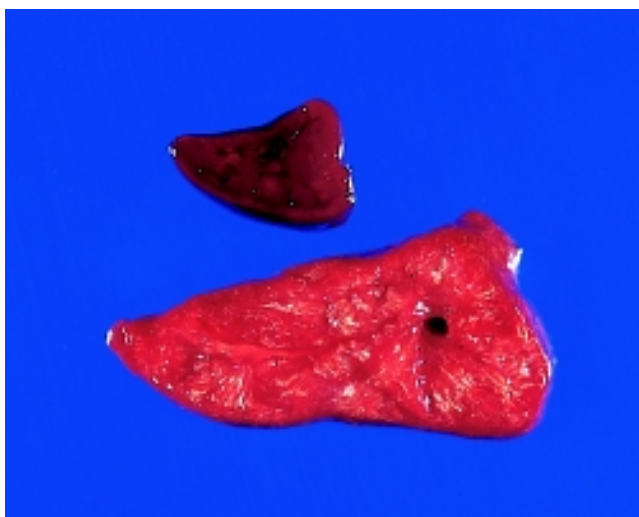


Photo by J. Christian Fransson

Figure 27.4 Cut surfaces from the same two kidneys as in Fig. 27.3. Bottom kidney shows chalky material from buildup of uric acid salts.

Diagnosis

Confirmation of renal coccidiosis requires microscopic examination of tissue by the trained staff of a diagnostic laboratory. Whole carcasses are generally needed to determine the cause of death unless kidney damage is so severe that it unquestionably would have caused death. When whole refrigerated carcasses cannot be provided for evaluation because of field circumstances, the kidneys should be removed, preserved in a 10:1 volume of 10 percent buffered neutral formalin and submitted for diagnosis (see Chapter 2).

Control

Control of renal coccidiosis in free-ranging birds is not feasible. Crowded conditions facilitate transmission of the parasite through fecal contamination of the environment. Prevention of degradation of habitat quantity and quality on breeding grounds and wintering areas is needed to minimize disease risks.

Human Health Considerations

There are no reports of human health concerns with this disease.

Rebecca A. Cole

Supplementary Reading

- Gajadhar, A.A., and Leighton, F.A., 1988, *Eimeria wobeseri* sp. n. and *Eimeria goelandi* sp. n. (Protozoa: Apicomplexa) in the kidneys of herring gulls (*Larus argentatus*): *Journal of Wildlife Diseases*, v. 24, p. 538–546.
- Oksanen, A., 1994, Mortality associated with renal coccidiosis in juvenile wild greylag geese (*Anser anser anser*): *Journal of Wildlife Disease*, v. 30, p. 554–556.
- Wobeser, G., and Stockdale, P.H.G., 1983, Coccidia of domestic and wild waterfowl (Anseriformes): *Canadian Journal of Zoology*, v. 61, p. 1–24.