

Chronic Thrombotic Obstruction of Major Pulmonary Arteries*

Report of a Case Successfully Treated by Thrombendarterectomy, and a Review of the Literature

LT. CMDR. VERNON N. HOUK, MC, USN, CHARLES A. HUFNAGEL, M.D.,
Bethesda, Maryland *Washington, D. C.*

CMDR. JAMES E. MCCLENATHAN, MC, USN and KENNETH M. MOSER, M.D.
Bethesda, Maryland *Washington, D. C.*

EXTENSIVE pulmonary thromboembolism is usually regarded as a sudden, dramatic event accompanied by acute symptoms and an appreciable immediate mortality. Less widely recognized is the type of pulmonary thromboembolic disease which is relatively silent and clinically evident in the form of pulmonary insufficiency and chronic cor pulmonale due to marked reduction in the pulmonary vascular bed area [7-5]. Recent improvements in surgical capabilities have made discovery of patients with "thrombotic cor pulmonale" of considerable importance since this form of cor pulmonale is now, at least, potentially curable.

Most of the literature dealing with surgical intervention in patients with extensive pulmonary embolism has dealt with the feasibility of immediate embolectomy in the face of acute, massive occlusion of the pulmonary artery or its major branches. In 1908 Trendelenberg [5] first attempted this then daring procedure on a patient who was at the point of death, unconscious and without pulse so that no anesthesia was required. Since this pioneer effort, there have been multiple reports of attempted emergency embolectomy, with several instances of success [6-14]. Recently, the use of emergency cardiopulmonary bypass has extended the serious limitations of time imposed by massive occlusion, thus enhancing the feasibility and success of surgical intervention [15].

The emphasis on detection and therapy of acute massive pulmonary vascular obstruction is understandable, since chronic obstruction of major pulmonary arteries is less dramatic, less frequently encountered and even less frequently diagnosed during life. Furthermore, despite a history of embolic episodes preceding the appearance of cor pulmonale, therapeutic enthusiasm has often been dampened by the assumption that the occlusive disease involves multiple small peripheral branches and, therefore, is not subject to correction, and the acknowledged increased risk of cardiac catheterization and angiographic study of patients with compromise of the pulmonary vascular bed. Nevertheless, extensive pulmonary thrombi constitute such a major threat to the patient in terms of both morbidity [16-19] and mortality that this potentially curable entity must be ruled out in patients who present with the suggestive signs and symptoms to be recounted here.

A search of the literature has revealed approximately 250 reported cases of chronic thromboembolic obstruction of the major pulmonary arteries. In only six of these was the diagnosis established before death [1,10,20,27], and in only three was direct surgical therapy attempted. In the first of these three, the patient underwent an exploratory operation in 1950, at which time the left pulmonary artery was found to be small with minimal pulsations [20]. No

* From the Departments of Medicine and Surgery, U.S. Naval Hospital, Bethesda, Maryland, and the Georgetown University Medical School, Washington, D.C. and The Pulmonary Section, Georgetown Clinical Research Institute, Aviation Medical Service, Federal Aviation Agency, Washington, D.C. The opinions expressed are those of the authors and do not necessarily reflect the opinions of the Navy Department. Manuscript received July 25, 1962.

attempt was made to relieve the obstruction. The second patient underwent an exploratory operation because of a lesion in the right lung, and a lower right lobectomy was carried out [10]. The pulmonary artery to that lobe was surrounded by dense inflammatory tissue and was filled with thrombi. Microscopic examination revealed a thickened vessel wall indicative of endarteritis. Subsequently this patient died, and autopsy revealed massive thromboembolic occlusion of the left main pulmonary artery and adherent emboli in the right main pulmonary artery. The third patient underwent thoracotomy because of a suspected aneurysm of the pulmonary artery. The occluded vessel and the entire lung were resected [21].

Thus, although embolectomy or endarterectomy in chronic obstruction of the major pulmonary arteries has been suggested [22], our review of the literature failed to disclose an instance in which this procedure was successfully carried out. This presentation is the description of a patient with this condition who was significantly improved by bilateral pulmonary embolectomy-endarterectomy.

CASE REPORT

A forty-one year old white man (K. E.) was first admitted to a hospital on July 19, 1961, because of increasing dyspnea of five days' duration.

History disclosed that the patient had been an extremely athletic and vigorous man. A routine electrocardiogram taken one year previously had been normal. Approximately six months prior to hospital admission, he had dislocated his left shoulder and had been placed in a shoulder spica for three weeks. Since that time, he had noted mild but definite dyspnea on moderate to severe exertion. On July 14, 1961, after a fairly rough and extended airplane trip, he became nauseated, weak and dyspneic. The next day he noted diarrhea and increasing dyspnea. His temperature was recorded at 100.4°F., and at rest, his pulse ranged from 104 to 120 beats per minute. The fever and diarrhea disappeared in three days, but increased dyspnea and tachycardia persisted. An electrocardiogram showed sinus tachycardia and T wave inversion in leads V₁ and V₂. Two days later (July 19), the electrocardiogram was unaltered, but a friction rub was heard over the precordium, and the patient was admitted to the hospital.

Physical examination on admission revealed normal temperature, blood pressure and pulse. The patient was moderately dyspneic at rest. There was no cyanosis or neck vein distention. The lungs were clear. The heart was not enlarged. There was a "to-and-fro" friction rub in the fourth intercostal

space at the left sternal border. A high-pitched, blowing systolic murmur was heard over the base of the heart that radiated toward the left shoulder and into the back. The second heart sound in the pulmonic area was greater than that in the aortic area and was widely split. A systolic gallop sound was present. The remainder of the examination revealed no abnormalities.

The electrocardiogram on the day of admission showed T wave inversion in leads II, aVF and V₄R through V₃. A chest roentgenogram suggested moderate enlargement of left pulmonary artery. The hemoglobin, hematocrit, white blood cell count, urinalysis and serum glutamic oxalacetic transaminase (SGOT) were within normal limits.

The initial clinical impression was that of a viral myocarditis. The patient was placed at bed rest and, because of the persistence of the pulmonic systolic murmur, the possibility of a pulmonary arteriovenous fistula was entertained. Arterial oxygen saturation determined with the patient at rest and breathing room air was reported to be 95 per cent. On July 21 the arm to lung circulation time was seven seconds and arm to tongue, twenty-seven seconds. Venous pressures were normal. On July 25 the patient complained of pain in the right groin, and by July 26 this had developed into clinical thrombophlebitis. He was given heparin on July 27 and 28. A single dose of 60 mg. warfarin sodium given on July 27 elevated his prothrombin time into the usual therapeutic range, and it was maintained in that range with warfarin sodium therapy. On August 3 while his prothrombin time was recorded at fifty-nine seconds (control thirteen seconds), he started to move about; he experienced new tenderness in the calf of the right leg and was again placed at bed rest. The following day he experienced pleuritic pain on the right side of the chest, and a friction rub was heard over that area. He remained at rest until August 27 when anticoagulant therapy was discontinued, and he was permitted to be ambulant again. During the course of this hospitalization serial electrocardiograms revealed inverted T waves in leads V₁ through V₃ until July 26. By August 21 the T waves were inverted only in leads V₄R and V₁.

The patient was transferred to the U. S. Naval Hospital, Bethesda, Maryland, for evaluation on September 15. On admission physical examination revealed a well developed, well nourished, muscular white man who was not dyspneic at rest. The vital signs were within normal limits. The neck veins were not distended at 30 degree elevation, and hepatogastric reflex was not elicited. The lungs were clear to palpation, percussion and auscultation. The heart was not clinically enlarged; normal sinus rhythm was present. The second heart sound was widely split on inspiration but closed normally with expiration. The pulmonary component of the second heart sound was accentuated. There was a grade 2 blowing holosystolic murmur which broached the second sound

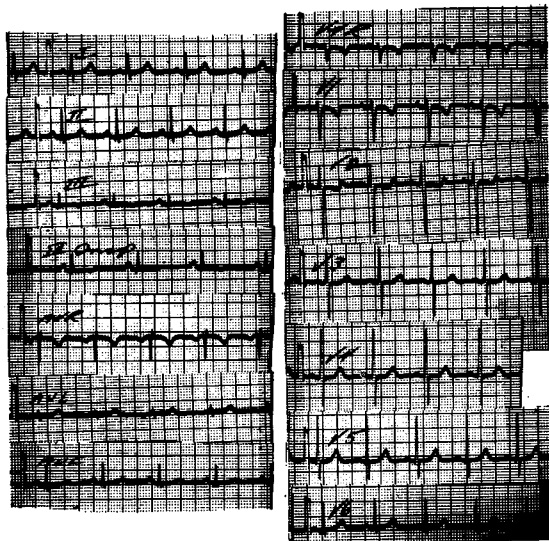


FIG. 1. Electrocardiogram obtained on September 15, 1961, showing nonspecific changes in the S-T segment and T wave.

and was heard best in the third intercostal space 3 cm. lateral to the left sternal border. This murmur increased markedly with inspiration and radiated toward the left shoulder; it was heard well in the neck, back and axilla on the left but was not heard to the right of the mediastinum. The liver was not palpably enlarged. There was no clubbing or cyanosis.

Laboratory data showed a hemoglobin of 12.2 gm. per cent, hematocrit of 38 per cent and a normal white blood cell count. The electrocardiogram (Fig. 1) showed nonspecific changes in the S-T segment and T wave.

A chest roentgenogram (Fig. 2A) showed relative avascularity of the upper left lung field. The heart was normal in configuration, but the pulmonary

TABLE I
VENTILATORY STUDIES BEFORE OPERATION

Study	Actual Values	Predicted Values	Per cent of Predicted Values
Tidal air volume (cc.)	1,634
Vital capacity (cc.)	4,576	3,946	116
Timed vital capacity (%)			
1 second	86	>85	...
2 seconds	92	>90	...
3 seconds	100	100	...
Maximum breathing capacity (L./min.)	164	116	141
Functional residual capacity (cc.)	2,885
Residual volume (cc.)	1,844
Total lung capacity (cc.)	6,420	5,818	110
Ratio of residual volume to total lung capacity (%)	29	<30	...
Per cent N ₂ after 7 minutes	2.6	<2.5	...

outflow tract and major branches of the pulmonary artery were prominent. There were pleural adhesions on the right with moderate elevation of the right hemidiaphragm.

Because the clinical data accumulated to this point suggested extensive pulmonary vascular occlusive disease, detailed evaluation of cardiopulmonary function was carried out. Ventilatory studies (Table I) disclosed no evidence of impairment; indeed, the maximum breathing capacity and vital capacity were well above the predicted normal values. Since these data did not suggest the presence of significant parenchymal involvement to explain the patient's dyspnea, arterial blood gas studies and cardiac catheterization were performed. The patient was studied at rest, during and after exercise, and during periods of breathing 32 and 100 per cent oxygen. The data (Table II) were of great interest. Pulmonary arterial hypertension (mean: 35 mm. Hg) was

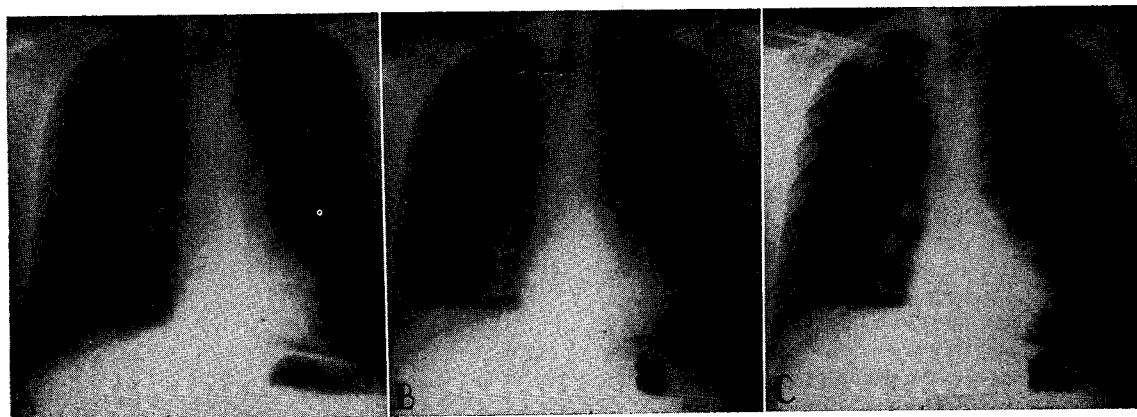


FIG. 2. A, Chest roentgenogram before operation (September 18, 1961) showing prominent pulmonary arterial shadows, avascularity of the upper lobe of the left lung and tenting of the right hemidiaphragm. B and C, chest roentgenograms after operation (January 9 and April 8, 1962) showing decrease in size of pulmonary arterial shadows.

present with the patient at rest; this was markedly accentuated during exercise, a peak level of 70 mm. Hg being reached in the tenth minute of exercise when the cardiac output was approximately two and a half times the resting value. The calculated pulmonary resistance remained essentially unchanged with exercise. Although there was hyperventilation at rest and during exercise (as indicated by the decreased carbon dioxide tension values), arterial desaturation was present at rest and worsened during exercise. The A-a oxygen tension gradient, which widened appreciably during exercise, reached a maximum value of 65 mm. Hg during the tenth minute of exercise.

Ten minutes after exercise, pulmonary arterial pressure declined, oxygen saturation improved and the A-a oxygen tension gradient narrowed. With the patient breathing 32 per cent oxygen, arterial oxygen saturation normalized, and pulmonary arterial pressure fell to the upper limits of normal. Normal arterial oxygen saturation was achieved with the inhalation of 100 per cent oxygen, and the mean pulmonary arterial pressure remained at the upper limits of normal. Cardiac catheterization disclosed no evidence of an intracardiac shunt.

The data suggested that the patient had primary vascular disease of the lung. Furthermore, it appeared that this vascular disease had resulted in a sufficient reduction in the pulmonary capillary bed area to produce a diffusion abnormality and pulmonary hypertension.

An end tidal-arterial carbon dioxide tension gradient, which was carried out while the patient was at rest (Table II), revealed that gradient to be 27 mm. Hg. This abnormally wide gradient indicated that a large area of the lungs was ventilated but not perfused.

A selective pulmonary cineangiogram was carried out next. This revealed a marked reduction in blood flow to the middle and lower lobes of the right lung and to the upper lobe of the left lung. The dye stream was interrupted abruptly in these regions, and there appeared to be a constant filling defect in the right pulmonary artery. (Fig. 3.) The study was interpreted as indicating obstruction of the middle and lower right and upper left lobar branches of the pulmonary artery.

It was considered that these data justified an attempt at surgical correction of the obstructive defects. Without correction, it was evident that the chronic increase in right ventricular work due to pulmonary hypertension would lead to the development of right ventricular hypertrophy and failure in subsequent years. Furthermore, the risk of extension of the existing embolic occlusion to the remaining lobar branches was thought to be considerable.

The patient was maintained on heparin therapy throughout hospitalization. On November 1 he underwent exploratory thoracotomy.

TABLE II*
BLOOD GAS AND CIRCULATORY DYNAMICS BEFORE OPERATION

Data	Minute	O ₂ % Van Slyke	PACO ₂ (mm. Hg)	PaO ₂ (mm. Hg)	A-a O ₂ (mm. Hg)	pCO ₂ (mm. Hg)	pH	V _E (cc./min.)	O ₂ Cons. (cc./min.)	Mean Pulmonary Artery Pressure (mm. Hg)	Cardiac Index (L./min./M ²)	Pulmonary Vascular Resistance (dynes/sec./cm ⁻⁵)
Resting.....	...	90	107	61	46	36	7.42	4,640	213.4	35	2.92	525
During exercise†.....	1	38
	3	89	112	58	54	32	7.39	50
	7	55
	10	86	119	54	65	31	7.37	36,806	1,656	60	7.42	500
After exercise.....	10	91	112	64	48	32	7.40	50
During inhalation of 32% oxygen.....	1	40
	3	35
	8	94	187	73	...	36	7.40	4,820	240.4	30	2.54	395
	10	7.40	20
During inhalation of 100% oxygen.....	10	98	...	102	...	38	7.40	20

Note: The end tidal-arterial carbon dioxide tension difference at rest was 27 mm. Hg.
 * In this and following tables O₂ % Van Slyke = per cent oxygen saturation by Van Slyke technic, PAO₂ = partial pressure of oxygen in alveolus, PaO₂ = partial pressure of oxygen in arterial blood, A-a O₂ = alveolar-arterial oxygen tension difference, pCO₂ = partial pressure of carbon dioxide in arterial blood, V_E = minute ventilation, O₂ Cons. = oxygen uptake.
 † The patient was exercised at the work level of 50 watts, the level established by patient tolerance to exercise the previous day.

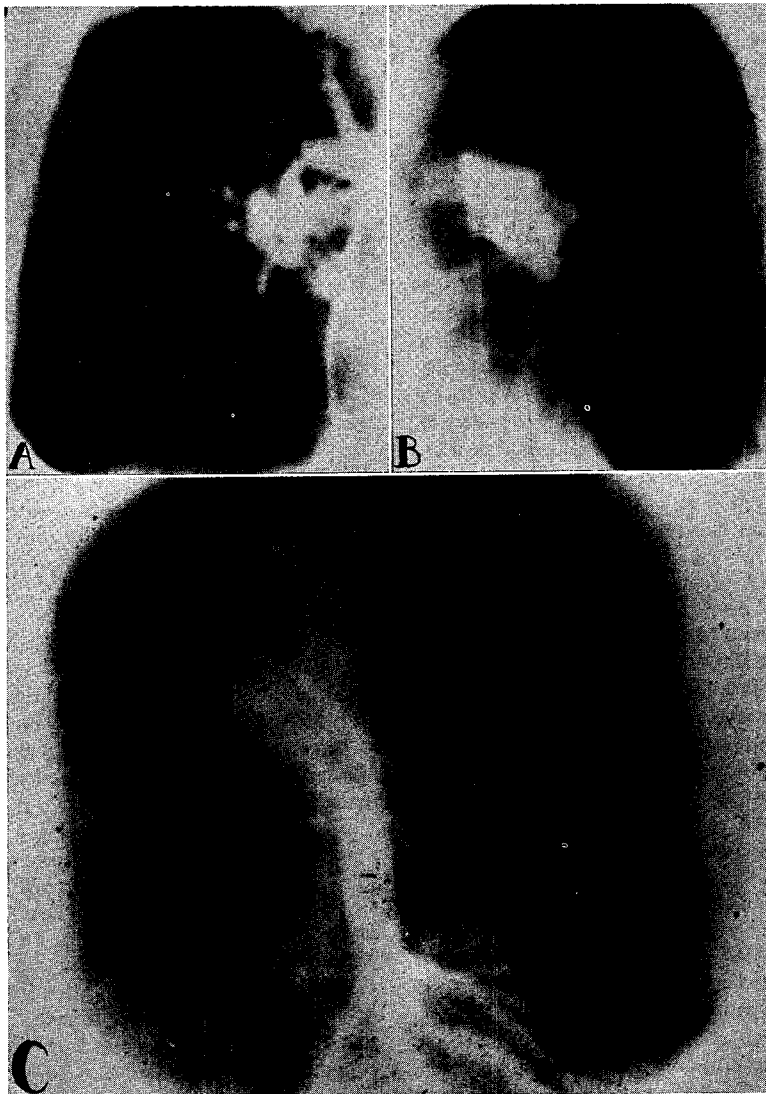


FIG. 3. Cineangiogram frames. A, poor filling of middle and lower lobes of right lung. B, poor filling of upper lobe of left lung in posteroanterior projection. C, oblique projection.

Surgical exploration was planned with cardiopulmonary bypass standby. It was believed from available evidence that, since the major portion of the right pulmonary flow was already obstructed, the patient might tolerate complete occlusion of the right main pulmonary artery, permitting open thromboendarterectomy without bypass. If relief of the right pulmonary artery obstruction were achieved, the left pulmonary artery then could be occluded, and repair of obstructions to the left upper lobar branch accomplished. Cardiopulmonary bypass could have been instituted promptly with a minimum of risk and manipulation.

A bilateral anterior thoracotomy was performed in

the right fourth and left third interspaces with sternal transection. Excellent surgical exposure of the lungs and pulmonary arteries was afforded by this approach. Vascular fibrous pleural symphysis was present over the entire middle and lower lobes of the right lung and over the apical posterior segment of the left lung. The areas of involvement were further evident by difficulty in maintaining a clean plane when dissecting the adventitia of the large apical posterior pulmonary artery branch on the left and upper and middle lobe branches on the right. Palpation disclosed marked fibrous thickening in these vessels and strongly suggested complete occlusion.

The main pulmonary artery measured 3.5 to 4 cm.

in diameter and was tense. No palpable disease was noted therein.

Complete occlusion of the right pulmonary artery produced a palpable increase in pulmonary artery pressure on the left and a bigeminal cardiac rhythm which continued throughout the twenty-five minute period necessary to complete the endarterectomy. Careful dissection within the right pulmonary artery freed an adherent, organized thrombus which had its origin in the most distal portion of the right pulmonary artery and extended into one of the upper, the middle and the lower lobe branches. The specimen (Fig. 4) measured 5 cm. in length. The staghorn appearance was as expected from the cineangiograms. Occlusion of the left pulmonary artery was then easily tolerated, and fifteen minutes were required to dissect free a complete occlusion of the first branch (apical posterior) of the pulmonary artery to the upper lobe of the left lung. Since the patient was being maintained on heparin therapy, meticulous surgical hemostasis was necessary. At the completion of the surgical procedure, a tracheostomy was performed to improve tracheobronchial cleansing and assist respiration if such proved necessary.

Heparin anticoagulation, prophylactic penicillin and streptomycin, and digitalis therapy were continued after the operation. Convalescence was smooth with minimal drainage from the chest; the tubes were removed on the fourth day after operation.

Clinical improvement was noted by the patient in the early period after operation and was confirmed by various physiologic measurements.

Despite the restrictive ventilatory effects of surgery and mild associated alveolar hypoventilation twenty-four hours after the surgical procedure, the end-alveolar arterial blood carbon dioxide tension gradient was recorded as 15 mm. Hg—a significant reduction from the value of 27 mm. Hg before the operation.

In mid December (six weeks after the operation), arterial blood gas studies and ventilatory studies were

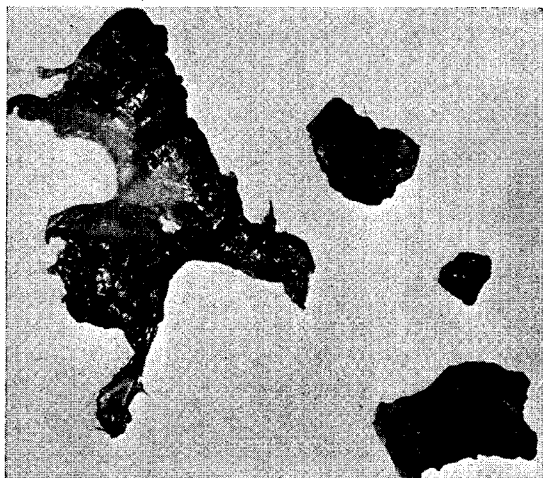

FIG. 4. Thrombotic cast of distal right pulmonary artery and branches plus fragments of this thrombus and that from upper lobe branch of left pulmonary artery.

obtained. (Tables III and IV.) At that time the end tidal-arterial blood carbon dioxide gradient was 12 mm. Hg. There was still a moderate restrictive ventilatory defect present; this was due no doubt to the effects of the bilateral thoracotomy. Chest roentgenograms during this admission (Fig. 2B) showed marked reduction in the size of the pulmonary artery shadows.

The patient was readmitted six months after surgery for restudy. Cardiac catheterization was attempted. However, no suitable vein could be found in the upper extremities for introduction of the catheter. It was not considered justified to catheterize the right side of the heart via the inferior vena cava since it was thought that this vessel had been involved at the time of the original thrombophlebitis. Although it was disappointing not to have hemodynamic data, the repeated blood gas studies (Table V) indicated that the patient's alveolar gas exchange had returned to

TABLE III*
BLOOD GAS STUDIES SIX WEEKS AFTER OPERATION

Data	Minute	O ₂ % Van Slyke	PAO ₂ (mm. Hg)	PaO ₂ (mm. Hg)	A-a (mm. Hg)	pCO ₂ (mm. Hg)	pH
At rest	95	107	75	32	38	7.40
During exercise	5	93	103	69	34	41	7.38
	10	94	105	73	32	39	7.37
After exercise	10	96	115	82	33	31	7.40
During inhalation of 32% oxygen	10	101	199	113	...	29	7.44

NOTE: End tidal-arterial carbon dioxide tension difference at rest was 12 mm. Hg. Exercise level same as in Table II.

TABLE IV
VENTILATORY STUDIES

Study	Actual Values	Predicted Values	Per cent of Predicted Values
<i>Postoperative*</i>			
Tidal air volume (cc.)	1,094
Vital capacity (cc.)	3,073	3,946	78
Timed vital capacity (%)			
1 second	86	>85	...
2 seconds	96	>90	...
3 seconds	100	100	...
Maximum breathing capacity (L./min.)	90	116	78
Functional residual capacity (cc.)	2,919
Residual volume (cc.)	873
Total lung capacity (cc.)	4,847	5,818	83
Ratio of residual volume to total lung capacity (%)	18	<30	...
Per cent N ₂ after 7 minutes	3.2	<2.5	...
<i>Convalescent†</i>			
Tidal air volume (cc.)	1,620
Vital capacity (cc.)	4,320	3,927	110
Timed vital capacity (%)			
1 second	88	>85	...
2 seconds	100	>90	...
3 seconds
Maximum breathing capacity (L./min.)	141	114	121
Functional residual capacity (cc.)	2,910
Residual volume (cc.)	1,635
Total lung capacity (cc.)	6,056	5,806	105
Ratio of residual volume to total lung capacity (%)	27	<30	...
Per cent N ₂ after 7 minutes	2.4	<2.5	...

* December 13, 1961, six weeks after operation.
† May 9, 1962, six months after operation.

normal. Ventilatory studies (Table iv) yielded normal results, and the chest roentgenogram (Fig. 2C) was unchanged from that obtained in mid December. The end tidal-alveolar arterial blood carbon dioxide tension gradient was 7 mm. Hg. The patient has progressively improved following surgery. At present, he is fully active and does not experience

dyspnea. The pulmonary component to the second heart sound is no longer accentuated, the pulmonary systolic murmur is absent, and the splitting of the second heart sound is normal. His exercise tolerance is similar to that which he enjoyed two years previously.

COMMENTS

In the past, extensive thrombotic occlusion of the pulmonary arterial system attracted interest primarily as an unusual postmortem finding in patients who succumbed to chronic cor pulmonale. However, with the advent of surgical technics which have made pulmonary embolectomy and endarterectomy feasible, "thrombotic" cor pulmonale must now be added to the important list of potentially curable forms of heart disease. Indeed, it is now possible to diagnose chronic massive thrombosis of the pulmonary arteries prior to the development of clinically detectable heart disease. Diagnostic and surgical advances thus have imposed upon the physician a demand for increased alertness and accuracy in the detection of pulmonary embolic obstruction—a demand which must be met if "therapeutic availability" is to be translated into "therapeutic application." Identification of patients with this disorder requires familiarity with those situations in which it is most likely to occur, the clinical features associated with it and the laboratory studies which can be called upon to confirm the diagnosis.

Incidence. It is almost axiomatic that heightened interest in a given disease leads to an increased incidence of discovery. Therefore, current opinions regarding the rarity of extensive pulmonary thromboembolism may well be revised in the future, and available estimates of its incidence should be viewed in this light. Ring

TABLE V*
BLOOD GAS STUDIES SIX MONTHS AFTER OPERATION

Data	Minute	O ₂ % Van Slyke	PAO ₂ (mm. Hg)	PaO ₂ (mm. Hg)	A-a (mm. Hg)	pCO ₂ (mm. Hg)	pH
At rest	...	97	104	99	5	39	7.42
During exercise	5	95	108	89	19	36	7.44
	10	95	108	88	20	36	7.44
After exercise	10	98	105	100	5	38	7.43
During inhalation of 32% oxygen	10	100	181	40	7.40

NOTE: End tidal-arterial carbon dioxide tension difference at rest was 7 mm. Hg. Exercise level same as in Table II.

and Bakke [23] found twenty-one cases of massive pulmonary arterial occlusion in 11,511 autopsies carried out between 1935 and 1954, an incidence of 0.18 per cent. Billings [24], in an extensive review, reported an incidence in various autopsy series ranging from 0.2 to 0.7 per cent.

Such reports indicate that major thrombotic occlusion of the pulmonary vascular bed occurs with sufficient frequency to merit consideration in any patient with apparent "primary pulmonary hypertension." It has been demonstrated that thromboembolism constitutes the most frequent cause of pulmonary vascular obstruction [25] and that primary disease of the pulmonary vessels is rare [10]. Indeed, there is a growing body of evidence which suggests that a significant percentage of patients with "primary pulmonary hypertension" actually represent instances in which prior widespread pulmonary embolism and thrombosis has partially resolved, leaving in its wake histologic evidence suggesting primary vascular disease [10,26].

Although pulmonary embolic disease as a "pure" cause of cor pulmonale—as in the case reported herein—appears rather uncommon [2], thromboembolism as a major *contributory* cause to cor pulmonale in subjects with pre-existing cardiac or pulmonary disease is undoubtedly more frequent than is currently suspected. Pulmonary embolism is most common beyond the third decade [26], when latent and overt cardiopulmonary disease is also more frequent. The higher incidence of pulmonary embolism and infarction in patients with known cardiopulmonary disease is widely appreciated. Therefore, it is cogent to suggest that pulmonary vascular occlusion be considered in patients with antecedent cardiopulmonary disease who appear to be abruptly "deteriorating." If vascular occlusion of major branches is detected, such "deterioration" may prove to be surgically reversible.

Etiologic Substrates. In discussing the various conditions associated with major pulmonary arterial occlusion, one must touch upon the controversy as to whether the thrombi developed *in situ* as a primary thrombotic process, arose exclusively in the periphery and reached the lung as emboli or represent embolism with subsequent thrombotic extension. The problem is a knotty one not subject to definitive answer in many instances even after microscopic study.

Available evidence appears to indicate that primary *in situ* thrombosis does occur under special circumstances in which the pulmonary artery or its branches are the site of, or involved in, an inflammatory process. Instances believed to represent primary thrombosis have been reported in association with pulmonary artery aneurysms and syphilitic arteritis [27-29] and acute arteritis secondary to inflammatory disease of the surrounding lung [10,28,30]. In some reports, primary thrombosis has occurred under circumstances suggesting a generalized tendency towards thrombosis [7], whereas in other cases the etiology remained obscure even at autopsy. An apparent association between direct trauma to the chest and the subsequent discovery of pulmonary arterial thrombosis has been noted in young persons who were otherwise healthy [31-33]. Trauma has also been cited as a cause of phlebitis with subsequent embolization [34].

Of special interest is the occurrence of pulmonary thrombosis in patients with chronic pulmonary disease and congenital heart diseases with left to right shunt. Chronic pulmonary disease probably promotes thrombosis by the following three mechanisms: (1) destruction of pulmonary parenchyma and vascular bed with the production of pulmonary hypertension and, ultimately, pulmonary arterial atherosclerosis [27]; (2) production of obliterative arteritis; and (3) development of polycythemia [23]. Since certain forms of congenital heart disease share several of these same factors, the frequency of pulmonary thrombosis in such patients is not unexpected [27,28]. The incidence of extensive thrombotic obstruction has been particularly notable in patients with interatrial septal defects and large left to right shunts [31,35,36].

Even though primary thrombosis of the pulmonary artery does occur in the specialized circumstances mentioned, most investigators agree that chronic massive occlusion is usually embolic in origin. In many instances—as in the case reported herein—the history and the presence of a known embolic source appear to document this sequence. Silent or overt peripheral venous thrombosis, often in association with right ventricular failure, may well be the single most common source for massive embolization [1,27]. However, extensive occlusion also has been noted in association with mural thrombosis following myocardial infarction [37], and a significant number of reported cases have occurred in patients with mitral stenosis.

Mitral stenosis was present in six of twenty-three cases in one series [7] and in nineteen of eighty-eight cases in another [30]. More recently, the percentage of patients with mitral stenosis in whom extensive thrombotic occlusion develops appears to be on the decline [10,22].

The available data, therefore, indicate that cor pulmonale due to thrombotic occlusion of major pulmonary arteries is most frequent in those situations in which the diagnosis is easily obscured by the presence of known cardiac or pulmonary disease. The symptoms of occlusion often have been dismissed as compatible with "deterioration" of function due to the coexisting disorder. It is likely that attention to unexplained "deterioration," especially in the form of cor pulmonale, may lead to discovery of additional cases amenable to surgical correction.

Symptoms. Chronic pulmonary thromboembolism has been described in patients ranging in age from fifteen months to eighty-nine years. However, the disorder is most common in patients beyond the age of forty in whom the incidence of all forms of thromboembolism is highest. As mentioned previously, antecedent cardiac or pulmonary disease is commonly present. There is no sex difference.

Dyspnea is by far the most commonly reported complaint [1,10,20,23,30,38,39]. This dyspnea is frequently out of proportion to that expected on the basis of collateral evidence of cardiopulmonary disease. This disparity between "dyspnea expected" and "dyspnea observed" is an important diagnostic clue in patients with massive thrombosis. The dyspnea is also rather characteristic in its lack of response to treatment. Indeed, unremitting progression despite vigorous therapy is often noted.

Hemoptysis and pleuritic chest pain have been frequently noted by previous investigators. Carroll [20] reported such a history in four of five cases and Ball et al. [7] in fourteen of twenty-three cases. Both of these symptoms often have been attributed to recurrent pneumonitis associated with underlying pulmonary disease during life and recognized as manifestations of embolism only retrospectively. These symptoms of repeated pulmonary infarction in patients with massive occlusive thrombi probably reflect periodic release of clot fragments of the primary thrombus to more distal pulmonary arterial branches [17]. Recurrent episodes of fever and cough, usually attributed to "pneumonitis," may provide an important historic clue,

especially if associated with dyspnea, hemoptysis and/or chest pain.

Severe substernal and epigastric pain also have been described in a number of patients. The mechanism of the former is poorly understood and has been attributed by some to a vagal reflex [38], by others to a decreased coronary flow caused by right ventricular dilatation and increased coronary venous pressure [39], and by still others to dilatation of the pulmonary artery with compression of the right coronary artery at its origin. Epigastric pain most commonly has been associated with hepatic congestion after the development of right ventricular failure, but has been encountered in some patients well in advance of this event.

Worthy of special mention are the symptoms suggestive of central nervous system disease which have been noted in a number of patients with extensive pulmonary thrombotic occlusion. Syncopal attacks, often recurrent [1,10,22], blurred vision [39] and varying degrees of mental confusion [1,10,22,30,40,41] have all been described with some frequency. These symptoms may have multiple etiologies including marked venous hypertension with cerebral edema, severe reduction in cardiac output with cerebral ischemia, "reflexes" initiated by embolism *per se* and, rarely, terminal carbon dioxide intoxication [40,41]. Recurrent paralysis of the left laryngeal nerve due to pressure from a distended left pulmonary artery has also been reported [10].

Although the symptoms of extensive pulmonary thrombosis are numerous, it is important to emphasize that they can easily be attributed to the underlying cardiac or pulmonary disease *per se*. It is essential to recognize that the symptoms of massive occlusion are more frequently insidious than dramatic. If sudden, dramatic onset or progression of symptoms is required before the diagnosis is entertained, many cases will be overlooked [42].

Physical Signs. Like the historic features, the physical signs encountered in chronic massive occlusion are far from uniform. They are determined by the location, extent and duration of the thrombotic process, as well as by the presence of other cardiopulmonary disease.

In the absence of primary lung disease, physical examination in such patients may be surprisingly unrewarding despite a history of severe dyspnea. Clubbing of the digits and cyanosis are usually absent, although peripheral

cyanosis may be present if the cardiac output is severely reduced. The chest may expand well and may be normal to percussion and auscultation, as in the patient described herein.

Cardiac examination, however, is often more revealing. A variety of murmurs has been described whose unusual transmission and timing may suggest an extracardiac origin [20,22]. Most commonly noted has been a high-pitched systolic murmur in the pulmonic region [38,43], although occasionally a systolic murmur at the apex has been reported. Diastolic, "to-and-fro" and continuous murmurs have also been described [22,43]. It is probable that these murmurs arise from the turbulence created in a large vessel by flow past a partial obstruction. We have seen three patients with high-pitched systolic murmurs in the pulmonic area which appeared to extend through the second sound (an observation confirmed in one case by phonocardiography) and which became louder with inspiration. One patient was the subject of this report. The two other patients had evidence suggesting pulmonary embolism involving the upper lobe of the left lung. Such a murmur, therefore, may have diagnostic value. In reviewing the reported series, it appears that the discovery of a systolic murmur with some atypical features—in the absence of primary cardiac disease—should suggest the possibility of pulmonary vascular occlusive disease. However, the absence of murmurs does not exclude the diagnosis [7,43].

The presence of an accentuated pulmonic component of the second sound is the usual finding in patients with extensive embolic obstruction. However, it has been stated that a normal pulmonary component may occur in such patients and, when it does, suggests obstruction of the pulmonary artery near the pulmonary valve rather than in more distal portions of the vascular tree [7].

As full-blown cor pulmonale appears, of course, the characteristic physical findings associated with right ventricular failure—hepatomegaly, ascites and peripheral edema—make their appearance.

Evidence of recent or remote peripheral venous disease is the exception rather than the rule in such patients. This indicates that either the original venous embolic source was not in the extremities or that the embolic source has resolved before the patient's problem reached clinical detection. The frequency of mural

thrombi in the right side of the heart as an embolic foci in patients with emphysema and cor pulmonale has recently been emphasized by Baum and Fisher [42].

Laboratory Studies. The *white blood cell count* and *hematocrit* are usually within normal limits [2]. *Polycythemia* is not encountered with massive pulmonary artery occlusion *per se* but when present is a consequence of associated cardiopulmonary disease.

The *chest roentgenogram* so often reveals no abnormalities that this does not exclude the diagnosis [25,43,44]. Marked enlargement of the pulmonary arterial shadows, particularly unilateral enlargement, is suggestive. Zones of radiolucency in the lung fields associated with zones of increased vascularity elsewhere (as in our patient) may provide a clue. Evidence of old pleural disease and/or fibrotic linear parenchymal residuals compatible with prior infarction may be helpful. Of special value may be the fluoroscopic observation of absent or diminished hilar pulsations in a patient with a prominent pulmonary conus or other evidence of right ventricular overload.

The *electrocardiogram* is of little differential value. With long-standing cor pulmonale, the electrocardiogram shows the changes expected, indicating right ventricular dilatation and hypertrophy. Often, as in our patient, the electrocardiogram is normal because the process has not been of sufficient duration to have induced significant alteration in the right ventricle or atrium.

Since the routine studies, as described, rarely provide a definitive answer, cardiac catheterization, pulmonary angiography and detailed measurements of the arterial blood gases are usually necessary to confirm the diagnosis. Although the first two procedures are not without risk in patients with pulmonary vascular compromise, one must have definitive data if a decision regarding a procedure such as pulmonary endarterectomy/embolectomy is required. However, before proceeding to catheterization and angiography, arterial blood gas studies may be used to provide supportive evidence for the diagnosis of extensive embolic occlusion.

Perhaps the simplest screening test is the measurement of the end tidal-arterial carbon dioxide gradient [45,46]. This test is based on the concept that embolic occlusion produces a zone of ventilation without perfusion. Therefore,

the end tidal ("mean alveolar") carbon dioxide tension falls below the directly measured arterial carbon dioxide tension by an amount proportional to the area blockaded. Although the development of infarction, the presence of associated pulmonary disease and other factors [45,47] limit the utility of this procedure, it would seem to have its greatest value in the patients under discussion herein—those with massive embolic occlusion. The end tidal-arterial carbon dioxide gradient in the case reported herein was definitely abnormal and diagnostically helpful. This patient's gradient of 27 mm. Hg before operation was well above the value of 17.2 mm. Hg observed in the most severely emphysematous patient (residual volume/total lung capacity = 67 per cent) yet studied in our laboratory [50].

Measurement of lung volumes is of value only in excluding the presence of associated obstructive or restrictive ventilatory defects. Demonstration of normal lung volumes is helpful in ruling out other disorders which may produce dyspnea.

Measurement of the *arterial blood gases* at rest, during exercise and during the breathing of oxygen-rich mixtures is of greater value than lung volume determinations. The physiologic abnormalities induced by extensive pulmonary embolization have been reviewed in detail by Parker and Smith [26] and by Nelson and Smith [49]. These investigators have pointed out that the pulmonary vascular reserve is so vast that occlusion of 60 to 70 per cent of the vascular bed is required before pulmonary hypertension appears with the subject at rest. However, study of arterial blood gases, particularly during exercise, may reveal occlusions of lesser degree. Arterial blood gas values with the patient at rest are usually within normal limits, although the carbon dioxide pressure may be slightly reduced due to alveolar hyperventilation. During exercise, however, the increase in pulmonary blood flow may be associated with a widening of the alveoloarterial oxygen tension gradient characteristic of a diffusion insufficiency. This widening of the oxygen tension gradient reflects critical reduction of the alveolocapillary area available for gaseous exchange [2,48]. The high diffusibility of carbon dioxide and the characteristics of the carbon dioxide dissociation curve prevent the appearance of significant elevation in arterial carbon dioxide tension under these circumstances. In truly massive occlusion, an abnormal A-a oxygen gradient

may be present at rest with normal pulmonary blood flow, and this gradient widens further with exercise. Inhalation of oxygen-rich mixtures serves to differentiate shunt from diffusion insufficiency, since normal oxygen saturation is achieved in diffusion defects but not when a significant shunt is present. The type of diffusion abnormality encountered in extensive embolic occlusion is similar to that seen following pneumonectomy, i.e., it is due to a critical loss of available diffusing surface rather than a thickened alveolocapillary membrane.

Right heart catheterization is a valuable procedure in establishing the diagnosis of embolic occlusion. The presence of congenital cardiac defects which might be associated with pulmonary vascular obliteration can be excluded. In the absence of such defects, the characteristic abnormalities of "primary pulmonary hypertension" are discovered. Assuming that the pulmonary artery and "wedge" can be entered, catheterization with the subject at rest will disclose a normal wedge pressure but mild to moderate pulmonary hypertension which is sharply accentuated during exercise. In patients with less extensive occlusion, exercise during catheterization becomes critical since normal pulmonary arterial pressures may be present at rest. With exercise, however, progressive elevation in pulmonary arterial pressure will be noted as the pulmonary bed becomes a "fixed resistance" system in which increased flow is attained only with an increase in pressure. The level of flow at which hypertension appears is a function of the degree of vascular depletion although associated hypoxemia may increase the degree of pulmonary hypertension [51-53].

Unfortunately, all the studies mentioned thus far may not yield a diagnosis. In those instances in which congenital cardiac disease or significant lung disease exists, the data obtained may be compatible with these disorders and the possible contribution of embolic occlusion uncertain. Furthermore, occlusion of a major pulmonary arterial branch—even total unilateral occlusion—may be difficult to detect by cardiac catheterization and arterial blood studies if the unobstructed lung is normal. Finally, even though the diagnosis is strongly suggested by prior studies, localization of the occlusion(s) is vital in determining the feasibility and technic of surgical attack. Such localization is possible only by angiocardiology. In carrying out this procedure, the preferred method is selective

cineangiography which permits detailed observation of a specific vascular bed area using small amounts of contrast medium. Large injections of contrast medium should be avoided in the interests of safety. Repeated small injections via a catheter in the pulmonary artery or, if this is not possible, in the right atrium or ventricle, provide data which should be definitive in patients with occlusion of major pulmonary arterial branches.

Operative Approach. Certain features of the operative approach in patients with massive occlusion are worthy of mention. Although unilateral occlusion may be employed successfully, as in the case reported herein, cardiopulmonary bypass has certain advantages: further overload of the right ventricle during occlusion is avoided; the pulmonary vascular tree can be examined in detail; and the surgical procedure itself can be accomplished in more leisurely fashion. The disadvantages of bypass (e.g., bleeding tendency after operation, necessity for multiple cannulations) must be balanced against these advantages.

Inspection—and even palpation—of the major pulmonary arterial branches is not always reliable in confirming the presence of a thrombus, particularly when soft thrombus or a thrombus which partially occludes a vessel is being dealt with. Thus, with angiographic evidence of occlusion, arteriotomy should not be abandoned when palpation of the involved vessels fails to disclose a firm intravascular mass.

In patients severely disabled by their disease, in whom surgery has not been feasible in the past, the suggestion of Cooley and Beall [15] that bypass be instituted using a portable apparatus and peripheral vessels seems worthy of mention. This procedure might also be used in patients who would be benefited by the procedure but might otherwise be unable to withstand the operation.

The need for anticoagulant therapy with heparin before and after surgery should be stressed also. In patients suspected of this disorder, heparin therapy should be utilized to forestall further thrombotic or embolic disease during the diagnostic period. Preservation of vascular patency after surgery is obviously critical, and heparin therapy is strongly advised, especially if endarterectomy is required. Now that high potency, low toxicity fibrinolytic agents are available, it is possible that these agents may be used in an effort to restore

vascular patency in those patients in whom the diagnosis is made promptly. They are also worthy of trial when operative facilities for definitive surgery are not available and when evidence of rethrombosis appears in the period after operation.

CONCLUSIONS

Our discussion has indicated that the path leading to the diagnosis of treatable forms of massive pulmonary embolic occlusion is a difficult one to follow. Obviously, the diagnosis is much more easily made in the patient without coexisting pulmonary or cardiac disease. Yet, despite the diagnostic difficulties involved, the possibility of embolic occlusion should not be abandoned in the face of other cardiopulmonary disorders, for its incidence is greatest in such patients. Discovery of extensive occlusion may transform an apparent "end-stage" patient into a treatable one. Even the demonstration that multiple small peripheral emboli exist is not without benefit; for, even though surgery is not feasible in such patients, such data may lead to re-evaluation of the need for anticoagulant therapy in patients with chronic cardiopulmonary disease.

It seems likely that heightened awareness of the possibility of remediable massive occlusion, plus the increasing availability of sophisticated diagnostic and surgical technics, will lead to the report of many similar cases in which this disorder is treated successfully in the future.

SUMMARY

A case is reported of chronic massive thromboembolic occlusion of major pulmonary arterial branches successfully treated with embolectomy and endarterectomy. The historic features, physical signs and pathophysiologic alterations which form the basis for the diagnosis of this disorder are reviewed.

REFERENCES

1. BALL, K. P., GOODWIN, J. K. and HARRISON, C. V. Massive thrombotic occlusion of large pulmonary arteries. *Circulation*, 14: 766, 1956.
2. HARVEY, R. M. and FERRER, M. I. A clinical consideration of cor pulmonale. *Circulation*, 21: 236, 1960.
3. PETCH, C. P. Cor pulmonale from recurrent pulmonary emboli. *Lancet*, 1: 345, 1951.
4. HARRIS, P. and HEATH, D. *The Human Pulmonary Circulation*, p. 318. Baltimore, 1962. Williams & Wilkins Co.
5. TRENDELENBERG, F. Ueber die Operative Behand-

- lung der Embolie der Lungenarterie. *Arch. klin. Chir.*, 86: 686, 1908.
6. COOLEY, D. A., BEALL, A. C. and ALEXANDER, J. K. Acute massive pulmonary embolism. *J. A. M. A.*, 177: 283, 1961.
 7. WIEBERDINK, J. Trendelenberg's operation for pulmonary embolism—modified technique. *J. Internat. Coll. Surgeons*, 34: 380, 1960.
 8. GAHAGAN, T. The Trendelenberg operation: pulmonary artery embolectomy. *Henry Ford Hosp. M. Bull.*, 8: 455, 1960.
 9. STEENBERG, R. W., WARREN, R., WILSON, R. E. and RUDOLF, L. E. A new look at pulmonary embolectomy. *Surg. Gynec. & Obst.*, 107: 214, 1958.
 10. ALLISON, P. R., DUNNILL, M. S. and MARSHALL, R. Pulmonary embolism. *Thorax*, 15: 273, 1960.
 11. HAMPSON, J., MILNE, A. C. and SMALL, W. P. The surgical treatment of pulmonary embolism. *Lancet*, 2: 402, 1961.
 12. FANCILLION, J., MARION, P., TARTULIER, M. and RANTENBERG, J. Emboli pulmonaire. Coeur pulmonaire aigu a forme progressive. Embolectomie guerison. *Lyon chir.*, 51: 304, 1956.
 13. LERICHE, R. Rapports: coeur pulmonaire aigu, arteriotomie pulmonaire gauche. Embolectomie retrograde partielle guerison. *Mem. Acad. chir.*, 79: 239, 1953.
 14. VANDECASTEELE, J., LINQUEITE, M. and DESRUELLES, J. Embolies pulmonaires recidivantes. Embolectomie pulmonaire et ligature de la veine cave inferieure dans le meme temps operatoire. *Arch. mal. coeur*, 84: 872, 1955.
 15. COOLEY, D. A. and BEALL, A. C. Surgical treatment of acute massive pulmonary embolism using temporary cardiopulmonary bypass. *Dis. Chest*, 41: 102, 1962.
 16. Case Records of Massachusetts General Hospital. *New England J. Med.*, 256: 850, 1957.
 17. *Ibid.*, 260: 874, 1959.
 18. *Ibid.*, 262: 140, 1960.
 19. OWEN, W. R., THOMAS, W. A., CASTLEMAN, B. and BLAND, E. F. Unrecognized emboli with subsequent cor pulmonale. *New England J. Med.*, 249: 919, 1953.
 20. CARROLL, D. Chronic obstruction of major pulmonary arteries. *Am. J. Med.*, 9: 175, 1950.
 21. BOUCHER, H., PROTOR, M. and BERTEIN, J. Aneurysme de la branche droite de l'artere pulmonaire par embol latent post phlebitique. *J. franc. méd. et chir. thorac.*, 5: 421, 1951.
 22. HOLLISTER, L. F. and CULL, V. L. The syndrome of chronic thrombosis of the major pulmonary arteries. *Am. J. Med.*, 21: 312, 1956.
 23. RING, A. and BAKKE, J. R. Chronic massive pulmonary artery thromboses. *Ann. Int. Med.*, 43: 781, 1955.
 24. BILLINGS, F. T. Primary thrombosis of pulmonary artery. *Pennsylvania M. J.*, 25: 152, 1921.
 25. HAMELIN, J. and EYLER, W. R. Pulmonary artery thrombosis: roentgen manifestations. *Radiology*, 56: 689, 1951.
 26. PARKER, B. M. and SMITH, J. F. Pulmonary embolism and infarction. *Am. J. Med.*, 24: 402, 1958.
 27. BRYSON, W. J. Propagating pulmonary artery thrombosis (a specific syndrome). *Dis. Chest*, 15: 336, 1949.
 28. BRENNER, O. Pathology of vessels of the pulmonary circulation. *Arch. Int. Med.*, 56: 1189, 1935.
 29. IRVIN, G. E. Contribution to the pathogenesis of chronic cor pulmonale; report of a case with multiple aneurysms, intravascular bands and old massive thrombus of the pulmonary artery. *Am. Heart J.*, 37: 1147, 1949.
 30. SAVACOLL, J. W. and CHARR, R. Thrombosis of pulmonary artery. *Am. Rev. Tuberc.*, 44: 42, 1941.
 31. DIAMOND, E. G. and JONES, T. R. Pulmonary artery thrombosis simulating pulmonic valve stenosis with patent foramen ovale. *Am. Heart J.*, 47: 105, 1954.
 32. BRIGGS, G. C., CARLSON, H. A. and HOUSEWORTH, J. H. Superior vena cava obstruction with complete obstruction of the right main pulmonary artery. *Am. Heart J.*, 48: 288, 1954.
 33. HARVEY, E. B. and HOGG, P. Thrombosis of the pulmonary artery in children, report of a case with review of the literature. *Am. J. Dis. Child.*, 71: 67, 1946.
 34. PITTS, H. H. and SPARKS, F. P. Unusual cardiac death due to trauma. *Bull. Vancouver M. A.*, 19: 345, 1943.
 35. CANADA, W. J., GOODALE, F. and CURRENS, J. H. Defect of interatrial septum with thrombosis of pulmonary, report of 3 cases. *New England J. Med.*, 248: 309, 1953.
 36. Case Records of Massachusetts General Hospital. *New England J. Med.*, 246: 419, 1952.
 37. CONKLIN, F. L. and LITWIN, L. E. Pulmonary artery thrombosis, a case report. *J. Michigan M. Soc.*, 51: 488, 1952.
 38. MIDDLETON, W. S. Abdominal pain in pulmonary thrombosis. *Ann. Int. Med.*, 18: 345, 1943.
 39. OSLER, W. Notes on hemorrhagic infarction. *Tr. A. Am. Physicians*, 2: 113, 1887.
 40. SIEKER, H. O. and HICKMAN, J. B. Carbon dioxide intoxication: the clinical syndrome, its etiology and management with particular reference to the use of mechanical respirators. *Medicine*, 35: 389, 1956.
 41. O'REILLY, R. J. The clinical recognition of carbon dioxide intoxication. *Dis. Chest*, 37: 185, 1960.
 42. BAUM, G. L. and FISHER, F. D. Relationship of fatal pulmonary insufficiency with cor pulmonale, right sided mural thrombi and pulmonary emboli: a preliminary report. *Am. J. M. Sc.*, 240: 605, 1960.
 43. KEATING, D. R., BURKEY, J. N., HELLERSTEIN, H. K. and FEIL, H. Chronic massive thrombosis of pulmonary arteries: a report of 7 cases with clinical and necropsy studies. *Am. J. Roentgenol.*, 69: 208, 1953.
 44. KJELLBERG, S. R. and OLSSEN, S. E. Roentgenological studies of experimental pulmonary embolism without complicating infarction in the dog. *Acta radiol.*, 33: 507, 1950.
 45. ROBIN, E. D., JULIAN, D. G., TRAVIS, D. M. and CRUMP, C. H. A physiologic approach to the diagnosis of acute pulmonary embolism. *New England J. Med.*, 260: 586, 1959.
 46. SEVERINGHAUS, J. W., STUFFEL, M. A. and BRADLEY, A. F. Alveolar dead space and arterial to end-tidal carbon dioxide differences during hypothermia in dog and man. *J. Appl. Physiol.*, 10: 349, 1957.

282 Chronic Thrombotic Obstruction of Pulmonary Arteries—*Houk et al.*

47. HARRISON, W. and LIEBOW, A. A. Gas exchange in lung deprived of pulmonary arterial supply. *Yale J. Biol. & Med.*, 22: 251, 1960.
48. HOUK, V. N. and MOSER, K. M. Unpublished data.
49. NELSON, J. R. and SMITH, J. R. The pathologic physiology of pulmonary embolism. A physiologic discussion of the vascular reactions following pulmonary arterial obstruction by emboli of various sizes. *Am. Heart J.*, 58: 916, 1959.
50. ROSSIER, P. H., BUHLMANN, A. A. and WIESINGER, K. *Respiration*. Edited and translated by Luchsinger, P. C. and Moser, K. M. St. Louis, Mo., 1960: C. V. Mosby Co.
51. DOYL, J. T., WILSON, J. S. and WARREN, J. V. The pulmonary vascular response to short term hypoxia in human subjects. *Circulation*, 5: 263, 1952.
52. DUKE, H. N. Observation on effects of hypoxia on pulmonary vascular bed. *J. Physiol.*, 135: 45, 1957.
53. RIVERA-ESTRADA, C., SALTZMAN, P. W., SINGER, D. and KATZ, L. N. Action of hypoxia on pulmonary vasculature. *Circulation*, 6: 10, 1958.