

## Mortality in Laysan Ducks (*Anas laysanensis*) by Emaciation Complicated by *Echinuria uncinata* on Laysan Island, Hawaii, 1993

Thierry M. Work,<sup>1,3</sup> Carol U. Meteyer,<sup>2</sup> and Rebecca A. Cole<sup>2</sup> <sup>1</sup>National Wildlife Health Center, Honolulu Field Station, PO Box 50167, Honolulu, Hawaii 96850, USA; <sup>2</sup>National Wildlife Health Center, 6006 Schroeder Road, Madison, Wisconsin 53711, USA; <sup>3</sup>Corresponding author (email: thierry\_work@usgs.gov)

**ABSTRACT:** In November 1993, unusual mortality occurred among endangered Laysan ducks on Laysan Island, one of the remote refugia of the Northwestern Hawaiian Islands National Wildlife Refuge (USA). Ten live ducks were emaciated, and blood samples documented anemia, heterophilia, and eosinophilia. Pathology in 13 duck carcasses revealed emaciation, marked thickening of the proventricular wall, abundant mucus, and nodules in the gastrointestinal tract. Histology revealed granulomata associated with nematodes in the proventriculus, small intestines, and body walls of nine of 10 ducks examined on histology. We suspect that low rainfall and low food abundance that year contributed to enhanced pathogenicity of parasite infection, either through increased exposure or decreased host resistance. Because the Laysan duck is found only on Laysan island and is critically endangered, translocation of this species to other islands is being considered. Given that we have not seen pathology associated with *Echinuria* spp. in native waterfowl on other Hawaiian Islands and given the parasite's potential to cause significant lesions in Laysan ducks, it will be important to prevent the translocation of *Echinuria* spp.

**Key words:** *Echinuria uncinata*, hematology, Laysan duck, pathology.

Laysan (25°46'N, 171°44'W) is a 370-ha island located about 1,300 km northwest of Honolulu, Hawaii (USA), in the Northwestern Hawaiian Islands National Wildlife Refuge. Laysan contains a large, shallow (<10 m), saline (10–15% salt) lake, making it unique among the northwestern Hawaiian Islands (Ely and Clapp, 1973). Laysan is accessible only by boat and is inhabited by a small number ( $n=4-6$ ) of field biologists who monitor wildlife.

Laysan harbors several endemic birds, including the Laysan duck (*Anas laysanensis*) that exists only on that island. The Laysan duck is a small, endangered, non-migratory waterfowl that nests in vegetation surrounding the lake, eats brine flies

on the lakeshore, and depends on freshwater seeps near the lake for water. Peak populations do not exceed 400–500 birds (Moulton and Weller, 1984).

Past mortalities of Laysan ducks have been attributed to collision-induced trauma with seabirds or starvation (Moulton and Weller, 1984); nothing is known about infectious disease in this bird. In 1993, biologists reported unusually high mortality of Laysan ducks. This paper describes clinical and pathology findings from this mortality event.

Between 23 October and 4 November 1993, carcasses were collected and frozen by biologists. From 11–13 November, one of us (TMW) did a field investigation to collect fresh carcasses, conduct necropsies, and examine live animals. Ten live ducks were captured at night around the edge of the lake with hand nets. Ducks were weighed in mesh bags with a spring scale and examined for clinical abnormalities. A blood sample (3 ml) was taken from the brachial vein with a 3 ml syringe and 0.8×25-mm needle. Five hundred microliters of blood were dispensed in ethylenediaminetetraacetic acid (Microtainer, Beckton Dickinson and Co., Franklin Lakes, New Jersey, USA). Blood was analyzed for hematocrit, estimated total solids, total white cell count with an eosinophil unopette (Unopette 5077, Beckton Dickinson), and differentials (Work, 1996).

On Laysan, 10 carcasses were weighed with a spring scale and systematically examined externally and internally. Three additional frozen carcasses were sent to the National Wildlife Health Center (NWHC; Madison, Wisconsin, USA) for similar examination. For 10 ducks, tissues (brain, kidney, lung, liver, spleen, esopha-

gus, proventriculus, intestines, pancreas, and gonad) were fixed in 10% neutral buffered formalin, embedded in paraffin, sectioned at 5  $\mu\text{m}$ , stained with hematoxylin and eosin, and examined microscopically. Acid-fast stains were used to detect *Mycobacterium* sp.

For the three ducks submitted to NWHC, the entire gastrointestinal tract was examined for protozoan and metazoan parasites. Nematodes were removed primarily from the lesions and lumen of the proventriculus, preserved in 70% ethanol, and identified to species (Cram, 1927; Anderson et al., 1975). Swabs from intestines of two duck carcasses necropsied at NWHC were cultured on blood agar plate, and bacteria were identified with the use of API systems (bioMerieux, St. Louis, Missouri, USA). Portions of intestines from two ducks necropsied at NWHC were assayed for viruses in cell culture (Senne, 1979) and in embryonated hens' eggs (Docherty and Slota, 1977).

Live ducks appeared weak with atrophied pectoral musculature and dull feather coats. Mean ( $\pm$ SD) weight (g); hematocrit (%); estimated total solids (g/dl); and lymphocyte, heterophil, eosinophil, monocyte, basophil, and total white cell counts ( $/\mu\text{l}$ ) were 406 (66), 35 (5), 4.8 (1.3), 2,076 (1,610), 2,795 (562), 1,659 (1,333), 7 (21), 27 (52), and 6,563 (2,370), respectively. No parasites were seen in the blood.

All dead ducks were adults (eight males, five females) in poor body condition with marked atrophy of breast muscles and lack of coelomic and cardiac fat. Mean weight ( $\pm$ SD) of males and females was 244 (29) and 232 (21) g, respectively. Seven ducks had one to 10 variably sized (0.5–1 cm) firm nodules with a caseous core on the serosa and walls of the proventriculus, small and large intestines, or body wall. Five ducks also had marked thickening of the wall of the proventriculus with partial occlusion of the lumen.

On microscopy, inflammatory lesions associated with *Echinuria uncinata* were seen in nine of 10 ducks. The normal ar-

chitecture of the proventriculus was disrupted. Instead of the normal flask shape of the submucosal glands, many proventricular glands were open, were flattened, and lacked distinct boundaries to adjacent glands. The superficial mucosal glands were covered with a thick layer of mucoid material with papillary proliferation of the mucosa and multifocal ulceration. Nematodes, some of which contained embryonated eggs, were seen within the lumina of submucosal proventricular glands, lamina propria, smooth muscle wall, and occasional granulomata (Fig. 1). Granulocytic inflammation surrounded nematodes within the muscle wall, and foci of subacute inflammation with giant cells were present in the mucosa. Nodules in intestines, proventriculus, and body wall consisted of a core of necrotic debris and inflammatory cells accompanied by clumps of bacteria that were negative for mycobacteria with acid-fast stain and occasional nematodes. These were lined by fibroblasts and smooth muscle. A moderate multifocal lymphocytic inflammation was present in the lamina propria. Other infrequently encountered lesions included mild parabronchial lymphoid infiltrates and mild interstitial lymphoid infiltrates in the kidneys (one bird each). No other metazoans were seen.

Nematodes were identified as *E. uncinata* (Cram, 1927). Voucher specimens were deposited at the National Parasite Collection (Beltsville, Maryland; accession number 16985). Numbers of worms recovered from three proventriculi ranged from 50 to 294 per bird; no protozoa or other metazoans were seen. No viruses were isolated from intestine, but mixed aerobic bacteria, including *E. coli*, were cultured.

Cause of death in this mortality was emaciation complicated by infection with *E. uncinata*. That ducks were emaciated was evident by the low body weight of carcasses. Moulton and Weller (1984) observed that weights of Laysan ducks decrease from March to August. We did our

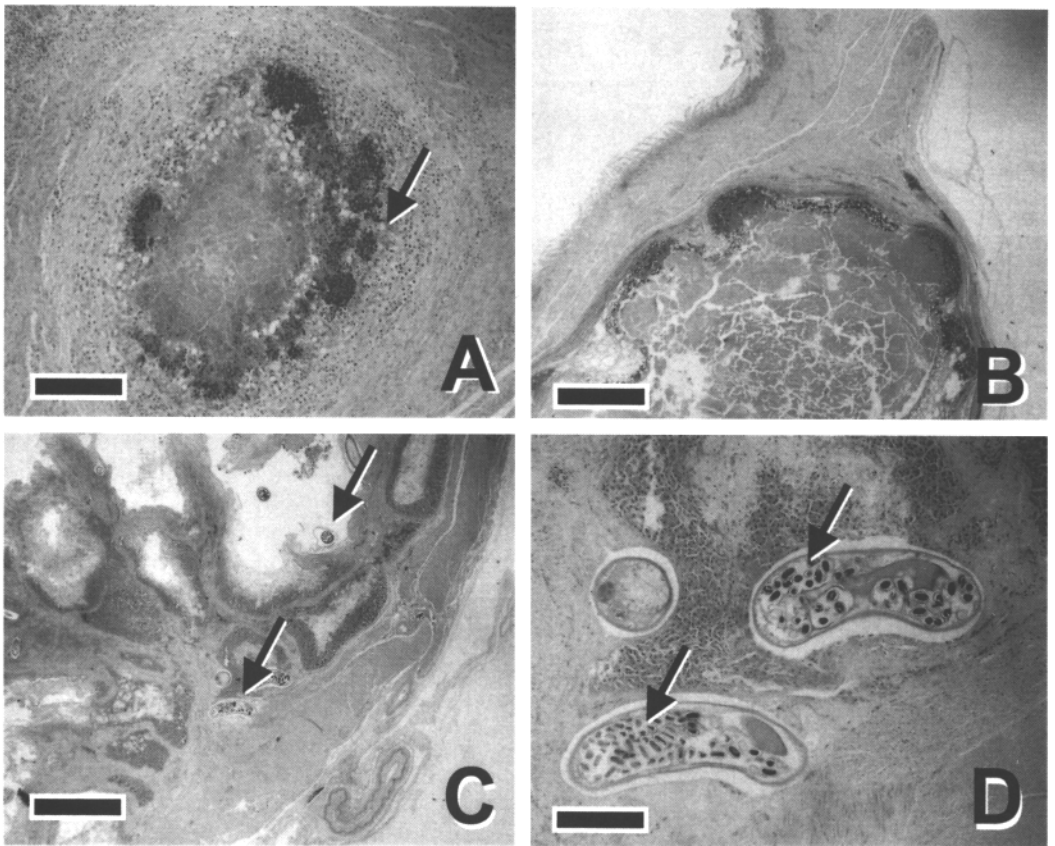


FIGURE 1. A. Early granuloma in small intestines of Laysan duck infected with *Echinuria uncinata*. Note the core of necrotic debris and bacteria and infiltrates of granulocytes (arrow). Bar = 100  $\mu\text{m}$ . B. Larger granulomas, small intestines (mucosal surface on upper left). Bar = 500  $\mu\text{m}$ . C. Proventriculus. Note dilation and disruption of proventricular glands and presence of nematodes (arrows). Bar = 500  $\mu\text{m}$ . D. Close-up of nematodes. Note embryonated eggs (arrow). Bar = 100  $\mu\text{m}$ .

investigations in November; however, the weights of dead ducks in this study (215–263 g) were much lower than those reported by Moulton and Weller (1984) in August (402–456 g). Live birds also appeared emaciated, and compared to mallards (Fairbrother and O'Loughlin, 1990), a species of duck closely related to the Laysan duck (Lack, 1970; Weller, 1980), hematology revealed anemia, heterophilia, and eosinophilia. In the absence of any primary hematologic pathology, the anemia would be compatible with the poor body condition observed in most live ducks. Heterophilia is a sign of stress in birds (Gross and Siegel, 1983), and eosinophilia is often a manifestation of parasite infections (Campbell, 1994).

Infection with *E. uncinata* was evident by presence of gastrointestinal pathology associated with nematodes in 90% of carcasses where tissues were examined by microscopy. Gross pathology of *E. uncinata* in Laysan ducks was similar to that described by others (Gibson and Barnes, 1957; Cornwell, 1963); however, in addition to nodules in the proventriculus, Laysan ducks had granulomata in multiple sites, such as intestines and body wall. In many cases, not all granulomata had worms (Cornwell, 1963; Austin and Welch, 1972; Ould and Welch, 1980). Buxton et al. (1952) described an acute form of echinuriasis, in which numerous worms were found in proventricular nodules, and a chronic form, in which proventricular

nodules had few worms and were filled with caseous material. Lack of acid-fast staining in bacteria associated with nodules did not implicate tuberculosis as the cause of lesions. We suspect bacteria opportunistically colonized nodules originally colonized by nematodes.

Given the inflammatory lesions associated with nematodes in Laysan ducks and the absence of other metazoans, we suspect *E. uncinata* played a role in this mortality. However, our data are too incomplete to sort out whether emaciation preceded parasites or vice versa. Parasites as a cause of morbidity and mortality have been documented in other wildlife (Gulland, 1992; Murray et al., 1997). However, these authors have incorporated observations of animals over time and from case control prospective studies involving treatment of animals with antihelminthics. The ecosystem on Laysan appears to be able to support about 400–500 birds (Moulton and Weller, 1984), although obtaining accurate counts can be difficult (Marshall, 1992). Survivorship is high once ducks reach adulthood, and limiting factors for the population are thought to include space, availability of freshwater, and food. The role *E. uncinata* plays in modulating the Laysan duck population and the extent of infection on the population merits further study.

Infections with *Echinuria* spp. can cause significant disease, particularly in birds experiencing crowding stress (Ould and Welch, 1980) or during drought, when birds are concentrated around freshwater sources, presumably enhancing chances of exposure and infection (Cornwell, 1963). Prior to the Laysan duck die-off, biologists noted that rains that replenished freshwater seeps had been very low in the past months, that the lake level and brine fly populations were lower than normal, and that ducks had been congregating on the few remaining seeps. Freshwater appears to be an important limiting factor for Laysan ducks (Moulton and Weller, 1984). We suspect that the combination of stress, low

water, and low food abundance coupled with crowding around limited water seeps could have either made the animals physiologically more susceptible to disease or allowed high numbers of worms to accumulate in ducks.

Water fleas (*Daphnia* and *Cyclops* spp., Order Cladocera) are the zooplankton that serve as intermediate hosts for *Echinuria* spp. (Austin and Welch, 1972). Only two species of invertebrates are documented in the lake on Laysan Island, including a brine fly (*Neoscatella sexnotata*) and a brine shrimp (*Artemia* sp.) (Butler and Usinger, 1963). Nothing is known of the invertebrate fauna of freshwater seeps on Laysan. The Laysan duck feeds extensively on the fly (Moulton and Weller, 1984) and probably the shrimp although seeds and insect larvae also comprise an important part of their diet (Reynolds, 2002). The role of invertebrates in the transmission of *E. uncinata* to Laysan ducks deserves further investigation.

Translocation of ducks to other islands is proposed as part of the recovery efforts for this species. Lesions associated with *E. uncinata* have not been documented in previous surveys of parasites in native Hawaiian birds (van Riper and van Riper, 1984; Work, unpubl.). Given *E. uncinata*'s potential to cause significant lesions, it would be wise to ensure that translocation of ducks does not include translocation of parasites to new areas. Carbon tetrachloride (Stoican, 1972), phenothiazines (Muhlhausler, 1970), piperazine (Cornwell, 1963), and ivermectin (Kock et al., 1987) have been used to treat waterfowl for *Echinuria* spp. with variable success and should be considered as potential treatment options for ducks slated for translocation.

The authors thank biologists R. Duncan and D. Docherty on Laysan for assistance in the field with bacteriology and virology, respectively. We are grateful to C. Fran-son, L. Sileo, C. Brand, S. Wright, and anonymous reviewers who provided constructive comments.

## LITERATURE CITED

- ANDERSON, R. C., A. G. CHABAUD, AND S. WILLMOTT. 1975. Commonwealth Institute of Helminthology keys to the nematode parasites of vertebrates, Vol. 3. Commonwealth Institute of Helminthology, St. Albans, UK, 58 pp.
- AUSTIN, F. G., AND H. E. WELCH. 1972. The occurrence, life cycle, and pathogenicity of *Echinuria uncinata* (Rudolphi, 1819) Soloviev, 1912 (Spirurida, Nematoda) in waterfowl at Delta, Manitoba. *Canadian Journal of Zoology* 50: 385–393.
- BUTLER, G. D., JR., AND R. L. USINGER. 1963. Insects and other invertebrates from Laysan Island. *Atoll Research Bulletin* 98: 1–30.
- BUXTON, J. C., C. M. FORD, AND I. B. MUNRO. 1952. Infestation of domestic ducks with *Acuaria (Echinuria) uncinata*. *The Veterinary Record* 64: 5–6.
- CAMPBELL, T. 1994. Hematology. In *Avian medicine: Principles and application*, B. W. Ritchie, G. J. Harrison and L. R. Harrison (eds.). Wingers, Lake Worth, Florida, pp. 176–198.
- CRAM, E. 1927. Bird parasites of the nematode suborders Strongylata, Ascaridata and Spirurata. Smithsonian Institution, U.S. National Museum, Washington, D.C., 462 pp.
- CORNWELL, G. 1963. Observations on waterfowl mortality in southern Manitoba caused by *Echinuria uncinata* (Nematoda, Acuariidae). *Canadian Journal of Zoology* 41: 699–703.
- DOCHERTY, D. E., AND P. G. SLOTA. 1977. Use of muscovy duck embryo fibroblasts for the isolation of viruses from wild birds. *Journal of Tissue Culture Methods* 11: 165–170.
- ELY, C. A., AND R. B. CLAPP. 1973. The natural history of Laysan Island, northwestern Hawaiian Islands. *Atoll Research Bulletin* 171: 1–361.
- FAIRBROTHER, A., AND D. O'LOUGHLIN. 1990. Differential white blood cell values of the mallard (*Anas platyrhynchos*) across differential age and reproductive states. *Journal of Wildlife Diseases* 26: 78–82.
- GIBSON, E. A., AND E. G. BARNES. 1957. *Acuaria uncinata* infestation in domestic geese and ducks. *The Veterinary Record* 69: 754–756.
- GROSS, W. B., AND H. S. SIEGEL. 1983. Evaluation of heterophil/lymphocyte ratio as a measure of stress in chickens. *Avian Diseases* 27: 972–979.
- GULLAND, F. M. D. 1992. The role of nematode parasites in Soay sheep (*Ovis aries* L.) mortality during a population crash. *Parasitology* 105: 483–503.
- KOCK, R. A., G. M. HENDERSON, E. C. APPLEBY, C. M. HAWKEY, AND R. N. CINDERREY. 1987. Acuariais in water fowl at Whipsnade Zoo. *Verhandlungsbericht des 29 Internationalen Symposiums uber die Ekkrankungen der Zootiere*, May 20–24, Cardiff, UK, pp. 65–73.
- LACK, D. 1970. The endemic ducks of remote islands. *Wildfowl* 21: 5–10.
- MARSHALL, A. P. 1992. Censusing Laysan ducks *Anas laysanensis*: A lesson in the pitfalls of estimating threatened species populations. *Bird Conservation International* 2: 239–251.
- MOULTON, D. W., AND M. W. WELLER. 1984. Biology and conservation of the Laysan duck (*Anas laysanensis*). *The Condor* 86: 105–117.
- MUHLHAUSLER, P. 1970. A simple method of demonstration of *Echinuria* larvae in *Daphnia*, and attempted prophylaxis of experimental Echinuriasis with phenothiazine feed supplementation. *Deutsches Tierärztliche Wochenschrift* 77: 577–600.
- MURRAY, D. L., J. R. CARY, AND L. B. KEITH. 1997. Interactive effects of sublethal nematodes and nutritional status on snowshoe hare vulnerability to predation. *Journal of Animal Ecology* 66: 250–264.
- OULD, P., AND H. E. WELCH. 1980. The effect of stress on the parasitism of mallard ducklings by *Echinuria uncinata* (Nematoda: Spirurida). *Canadian Journal of Zoology* 58: 228–234.
- REYNOLDS, M. M. 2002. The foraging ecology, habitat use, and population dynamics of the Laysan teal (*Anas laysanensis*). PhD Dissertation, Virginia Polytechnic Institute and State University, Blacksburg, Virginia, 189 pp.
- SENNE, D. A. 1979. Virus propagation in embryonated eggs. In *A laboratory manual for the isolation and identification of avian pathogens*, 3rd Edition, H. G. Purchase, L. H. Arp, C. H. Dommert and J. E. Pearson (eds.). American Association of Avian Pathologists, Kennett Square, Pennsylvania, pp. 176–181.
- STOICAN, E. 1972. O enzootie de echinurioză la ratele domestice. *Revista de Zootehnie si Medicina Veterinară* 6: 95–98.
- VAN RIPER, S. G., AND C. VAN RIPER III. 1984. A summary of known parasites and diseases recorded from the avifauna of the Hawaiian Islands. In *Hawaii's terrestrial ecosystems: Preservation and management*, C. P. Stone and J. M. Scott (eds.). Cooperative National Park Resources Studies Unit, Honolulu, Hawaii, pp. 298–371.
- WELLER, M. W. 1980. The island waterfowl. Iowa State University Press, Ames, Iowa, 121 pp.
- WORK, T. M. 1996. Weights, hematology, and serum chemistry of seven species of free-ranging tropical pelagic seabirds. *Journal of Wildlife Diseases* 32: 643–657.

Received for publication 5 February 2003.