

OREGON PUBLIC HEALTH DIVISION • DEPARTMENT OF HUMAN SERVICES

**TAPEWORMS: A COMMUNICABLE CAUSE OF SEIZURES**

In 2004, a 4-year-old Hispanic boy from Washington County presented to the emergency department with a first-onset seizure. A CT scan showed cystic structures in his brain parenchyma. Some months later, a 3-year-old Hispanic boy presented to a separate hospital with seizures and similar cystic findings in the brain. Neurocysticercosis (NCC), a parasitic disease of the central nervous system caused by the larval form of the pork tapeworm *Taenia solium*, was implicated in both cases. NCC is responsible for up to 30% of seizures in endemic countries, but these children had not traveled outside of the U.S. Both cases were reported to local health departments, and the ensuing public health investigation linked the two families. It is likely that these two children acquired NCC in Oregon, and the father of one child was found to harbor a tapeworm. Tapeworm infections are easily treated, and these NCC cases could have been prevented.

**A LITTLE BACKGROUND**

Worldwide, more than 50 million people are infected with *T. solium*.<sup>1</sup> People get cysticercosis by ingesting *T. solium* eggs from the feces of a human tapeworm carrier. These eggs develop into larvae within the small intestine, and then disseminate and form encapsulated cysts in the soft tissues of the body. Neurocysticercosis occurs when the larvae encyst within the central nervous system.<sup>2</sup> Although rare, hydrocephalus and death occur when developing larval cysts obstruct the flow of cerebral spinal fluid.

**NEUROCYSTICERCOSIS HERE?**

Within certain populations in the U.S., the prevalence of cysticercosis rivals that of endemic countries.<sup>3</sup> Here in Oregon, a study limited to hospital discharge diagnoses found 43 cases of NCC in 5 years.<sup>4</sup> The

estimated mean annual incidence for NCC of 3.1/100,000 among Oregon Hispanics is higher than rates previously reported in Los Angeles (1.6/100,000) and in Mexico (0.8/100,000).<sup>5,6</sup> The clinical and public health implications are significant. Approximately 10% of emergency department visits for seizures in Los Angeles are from NCC.<sup>7</sup> In Houston, 2% of all outpatient neurology appointments result from NCC.<sup>8</sup>

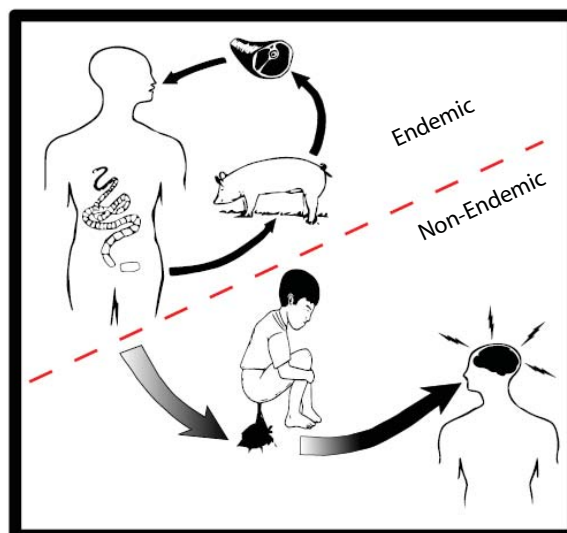
With a rapidly growing Hispanic population, an increasing number of Oregonians are at risk for NCC. Hispanics make up 11% of all Oregonians, and half were born in Latin America where *T. solium* is endemic.<sup>9</sup> While most NCC cases seen here likely occur in already-infected immigrants who enter the U.S., domestic transmission does occur.<sup>10</sup> As the two childhood cases presented above show, NCC prevention is not just a job for endemic countries. Identifying and treating source tapeworm carriers in Oregon may prevent NCC cases.

**IT'S NOT THE PORK**

There is a common misconception that you get NCC from eating

undercooked pork. In fact, while involved in the overall lifecycle of the parasite, pigs aren't necessary for the transmission of cysticercosis (Figure 1). This was clearly illustrated when an orthodox Jewish community in New York was struck by a cluster of NCC cases. These cases were eventually tied to live-in housekeepers from Central America who likely brought their tapeworms with them from their home countries.<sup>11</sup>

The adult tapeworm lives comfortably inside a human intestine for years to decades, happily shedding up to 200,000 eggs per day. These eggs are excreted in the stool and are highly infectious. When the eggs are consumed by either pigs or humans, they develop into larvae within the small intestine. The larvae, in turn, invade the intestinal wall, get carried via the bloodstream throughout the body, embed themselves in the soft tissue and encapsulate within a protective cyst. This is cysticercosis. If the cyst is in a pig, however, and someone goes on to eat it in an undercooked porkchop, the larva will come out of its cyst and complete the cycle by growing into an adult tape-



**Figure 1**  
**People, pork, pigs and poo**

People get tapeworms in endemic areas by eating undercooked pork. They shed tapeworm eggs in their feces. Neurocysticercosis occurs when someone accidentally eats those eggs. (Yuck!) This usually happens in endemic areas, but also occurs when people infected with tapeworms move to a non-endemic area such as Oregon.



If you need this material in an alternate format, call us at 971-673-1111.

IF YOU WOULD PREFER to have your CD Summary delivered by e-mail, zap your request to [cd.summary@state.or.us](mailto:cd.summary@state.or.us). Please include your full name and mailing address (not just your e-mail address), so that we can effectively purge you from our print mailing list, thus saving trees, taxpayer dollars, postal worker injuries, etc.

worm. Harboring an adult tapeworm is known as taeniasis. To summarize: if you eat an egg, you get a cyst; if you eat a cyst, you get a worm.

#### DIAGNOSIS AND TREATMENT

Larval cysts that form in muscles rarely cause symptoms. However, up to 70% of patients in whom larvae invade the CNS will develop seizures. Seizures typically occur with the death of a cyst, from the ensuing brain inflammation and calcification. Anti-parasitic treatment is therefore tricky, as killing the cysts in the brain can precipitate seizures. Treatment may require steroids, surgery or long-term antiepileptics, so expert consultation is advised. Other symptoms of NCC include chronic headaches, memory loss and focal neurological deficits. The cysts can also cause encephalitis or affect any part of the eye. Diagnosis is usually made by CT or MRI imaging showing the characteristic cysts.

Tapeworms cause relatively few symptoms and often go undetected. Our ability to screen for carriers has been limited by the insensitivity of light microscopy for the detection of eggs in stool. The federal Centers for Disease Control\* (CDC) has developed a serologic test — the enzyme-linked immunoelectrotransfer blot ("EITB") — which has high sensitivity and specificity for circulating antibodies to adult tapeworms.<sup>12</sup> It may be useful in the investigation of contacts. An ELISA test for tapeworm antigens in stool is also available for

confirmation. In addition, the oral anti-parasitic drug praziquantel is very effective against tapeworms. However, screening for co-existing NCC is indicated before treatment because praziquantel also kills *T. solium* larvae — which can precipitate seizures, as tapeworm carriers are at high risk for co-existing NCC from auto-inoculation. Niclosamide is an oral anti-parasitic that is a safe alternative, because it is not systemically absorbed; it is, however, available only from a few compounding pharmacies.

#### WHERE DO WE GO FROM HERE?

Although reportable in Oregon since 2002, few data are available on cysticercosis and taeniasis. Surveillance has been limited by a lack of investigative guidelines and probably by underreporting. Recognizing the growing population at risk in Oregon, our Emerging Infections Program is starting a two-year enhanced surveillance project, to get a more accurate picture of the disease burden and to develop guidelines for public health intervention. Included in these activities is screening household contacts of NCC cases to evaluate CDC's new serologic test for tapeworm carriers.

We ask that you report suspected and confirmed cases of both taeniasis and cysticercosis so that we can identify and treat tapeworm carriers, thereby preventing additional cases of NCC.

To report cases, call your local public health department.

#### REFERENCES

1. CDC. Recommendations of the International Task Force for Disease Eradication. *MMWR* 1993;42(RR-16):1–38.
2. Garcia HH, Del Brutto OH. Neurocysticercosis: updated concepts about an old disease. *Lancet Neurol* 2005;4:653–61.
3. Larralde C, Padilla A, Hernandez M, et al. Seroepidemiology of cysticercosis in Mexico. *Salud Publica Mex* 1992;34:197–210.
4. Townes JM, Hoffmann CJ, Kohn MA. Neurocysticercosis in Oregon, 1995–2000. *Emerg Infect Dis* 2004;10:508–10.
5. Sorvillo FJ, Waterman SH, Richards FO, Schantz PM. Cysticercosis surveillance: locally acquired and travel-related infections and detection of intestinal tapeworm carriers in Los Angeles County. *Am J Trop Med Hyg* 1992;47:365–71.
6. Roman G, Sotela J, Del Brutto O, et al. A proposal to declare neurocysticercosis an international reportable disease. *Bull WHO* 2000;78:399–406.
7. Ong S, Talan DA, Moran GJ, et al. Neurocysticercosis in radiographically imaged seizure patients in U.S. emergency departments. *Emerg Infect Dis* 2002;8:608–13.
8. de la Garza Y, Graviss EA, Daver NG, et al. Epidemiology of neurocysticercosis in Houston, Texas. *Am J Trop Med Hyg* 2005;73:766–70.
9. American Community Survey. US Census Bureau, 2005.
10. DeGiorgio CM, Sorvillo F, Escueta SP. Neurocysticercosis in the United States: review of an important emerging infection. *Neurology* 2005;64:1486.
11. Schantz PM, Moore AC, Munoz JL, et al. Neurocysticercosis in an Orthodox Jewish community in New York City. *N Engl J Med* 1992;327:692–5.
12. Levine MZ, Lewis MM, Rodriguez S, et al. Development of an enzyme-linked immunoelectrotransfer blot (EITB) assay using two baculovirus expressed recombinant antigens for diagnosis of *Taenia solium* taeniasis. *J Parasitol* 2007;93:409–17.