

Retroperitoneoscopic-guided radiofrequency ablation of renal tumors

Stephen E. Pautler, MD, Christian P. Pavlovich, MD, Igor Mikityansky, Darrel E. Drachenberg, MD, Peter L. Choyke, MD, W. Marston Linehan, MD, Bradford J. Wood, MD, McClellan M. Walther, MD

Urologic Oncology Branch, National Cancer Institute and the Diagnostic Radiology Department, Warren G. Magnuson Clinical Center, National Institutes of Health, Bethesda, Maryland

PAUTLER SE, PAVLOVICH CP, MIKITYANSKY I, DRACHENBERG DE, CHOYKE PL, LINEHAN M, WOOD J, WALTHER MM. Retroperitoneoscopic-guided radiofrequency ablation of renal tumors. *The Canadian Journal of Urology*. 2001;8(4):0000-0000.

Objective: Minimally invasive approaches to the management of renal tumors are being studied intensively in urology. Herein, we describe the use of multiple organ-sparing techniques for the management of tumors in a patient with von Hippel Lindau disease (VHL).

Materials and Methods: A 42 year-old woman with VHL underwent a right partial adrenalectomy and a left renal radiofrequency ablation (RFA) of two renal tumors.

Results: A 2.2 cm solitary right adrenal pheochromocytoma was resected using a transperitoneal approach. A retroperitoneal approach to the left kidney

was performed and RFA of the two renal tumors completed using sonographic guidance. On the 5-month follow-up CT scan, there was no evidence of residual adrenal tumors and both renal lesions lacked contrast enhancement. No complications occurred during the post-operative recovery.

Conclusions: Multiple organ-ablative laparoscopic procedures may be performed in a single sitting. Laparoscopic partial adrenalectomy is an effective technique in patients with bilateral tumors or a familial syndrome predisposing to multiple adrenal tumors. Further study of renal RFA is required to assess the long-term durability of the procedure.

Key Words: kidney neoplasms, laparoscopy, surgical procedures, minimally-invasive, radiofrequency ablation

Introduction

Patients with von Hippel Lindau (VHL) disease are predisposed to the development of multifocal, bilateral renal cell carcinoma and pheochromocytoma, along with a variety of other tumors. Due to the

potential of multiple renal and adrenal surgeries during a patient's lifetime, a minimally-invasive option for tumor eradication is desired. Adrenal-sparing laparoscopic surgery is an attractive option in patients with familial forms of pheochromocytoma.¹ For renal tumors, an alternative therapy under development is radiofrequency ablation (RFA). Laparoscopic-guided RFA to facilitate partial nephrectomy has been reported.² Herein, we describe multiple retroperitoneoscopic-guided RFA treatments in one kidney employed as the sole treatment modality.

Accepted for publication July 2001

Address correspondence to Dr. McClellan Walther, Urologic Oncology Branch, National Cancer Institute, NIH, Bldg 10, Rm 2B-43, 10 Center Drive, Bethesda, Maryland 20892, USA
Tel: (301) 402-2251 Fax: (301) 402-0922

Case Report

An asymptomatic 42 year-old woman with VHL (germ-line mutation g>a, nt 713 of the VHL exon III) was evaluated. An open transperitoneal right radical nephrectomy was performed seven years previously for multifocal clear cell renal cancer. On screening evaluation, blood pressure was normal and serum and urine catecholamines were mildly elevated. Contrast-

enhanced abdominal CT demonstrated a 2.2 cm right adrenal tumor and multiple enhancing renal tumors (Figures 1 and 2).

After pharmacologic blockade of the pheochromocytoma using metyrasine and phenoxybenzamine, the patient underwent right transperitoneal laparoscopic partial adrenalectomy in the right flank position.¹ A solitary adrenal tumor was identified by laparoscopic ultrasound (LUS) using a

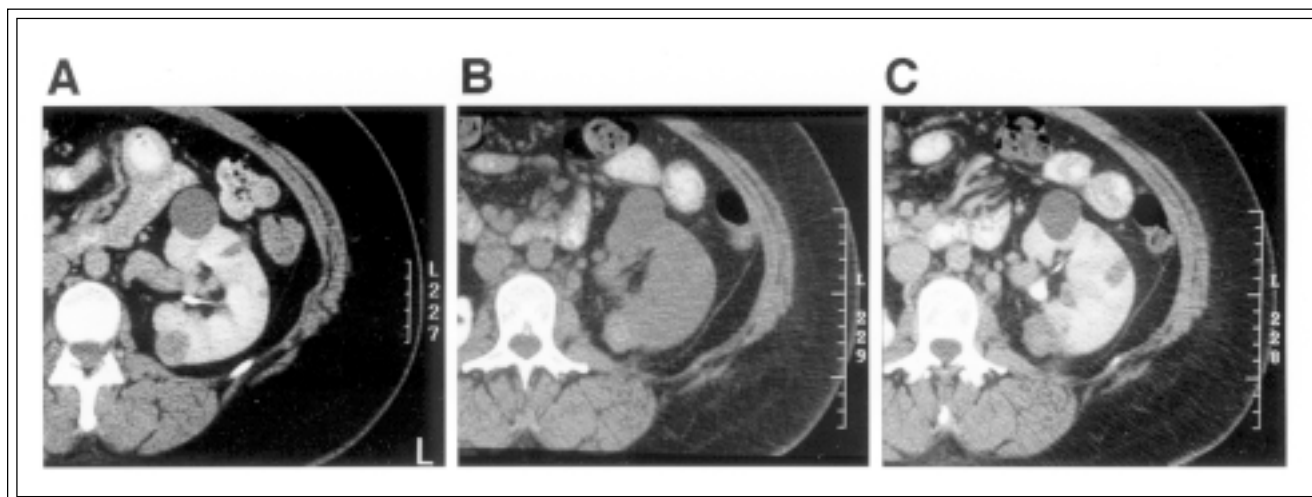


Figure 1. Posterior tumor. Panel A: Contrast CT prior to RFA demonstrated a solid tumor (2.7cm by 2.4 cm) with contrast enhancement of Δ HU+27. The solid nature of the tumor was confirmed by intra-operative ultrasound. The other lesions visible were cysts. Panel B: Two-month post-treatment non-contrast CT. A hyperdense treatment area (66 HU), presumably from tumor necrosis and hemorrhage is observed. Panel C: Contrast CT. The tumor was smaller (2.5 cm by 1.9 cm) and demonstrated no enhancement compared with the non-contrast image (66 HU \pm 65 HU; Δ HU-1).

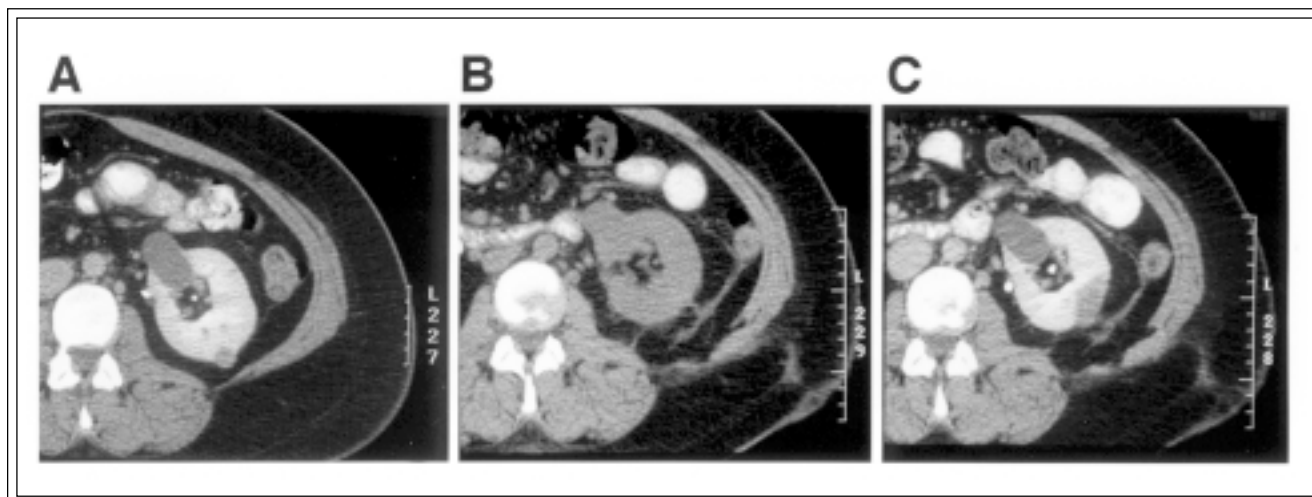


Figure 2. Renal tumor. Panel A: Contrast CT prior to RFA treatment revealed an enhancing solid renal tumor (Δ HU+27). Panel B: On follow-up non-contrast CT, the treated lesion appeared hyperdense. Panel C: After contrast administration, the treatment zone no longer enhanced (Δ HU+2) and measured 3.3 cm x 1.7 cm. The size of the treatment zone suggests that some collateral damage to adjacent renal parenchyma occurred during the RFA treatment.

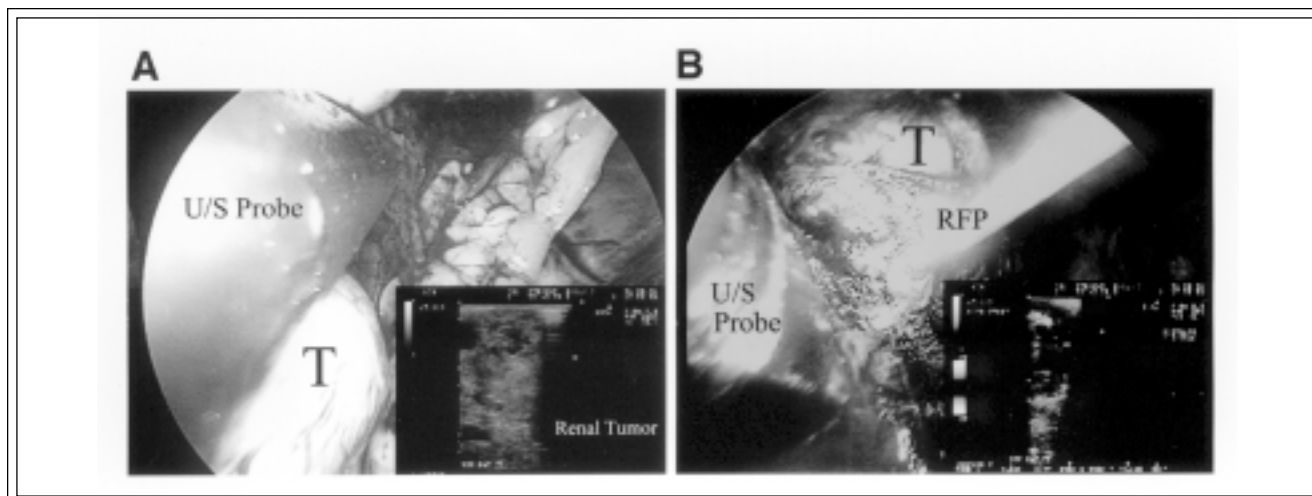


Figure 3. An intraoperative photograph of the partly exophytic tumor imaged with laparoscopic ultrasound (Panel A) and the radiofrequency probe within the tumor and concomitant laparoscopic ultrasound monitoring of the treatment (Panel B). U/S: ultrasound, T: tumor, RFP: radiofrequency probe

7.5 MHz linear transducer with a directable head (Aloka SSD-1700 system, Wallingford, CT). The patient was then repositioned to expose the left flank and retroperitoneoscopic access to the left kidney was obtained using two 12 mm and one 5 mm port. LUS was performed and identified two solid renal tumors (2.7 cm x 2.4 cm and 1.3 cm x 1.1 cm) and several renal cysts. A 17-gauge coaxial Radionics Cool-tip™ probe (Radionics Corp., Burlington, MA) was introduced using visual and LUS guidance (Figure 3). Two 12-minute heating cycles were completed for each of the two tumors. The patient's post-operative course was uneventful and 2-month follow-up demonstrated loss of CT contrast enhancement of both renal lesions (Δ HU -1 and Δ HU +2 respectively) (Figures 1 and 2). At 2 months the RFA treatment zones measured 2.5 cm x 1.9 cm and 3.3 cm x 1.7 cm, respectively. With further follow-up of 5 months, both lesions continued to get smaller (2.1 cm x 1.9 cm and 2.7 cm x 1.6 cm, respectively) and lacked enhancement (Δ HU +4 and Δ HU +8 respectively). Pathologic review of the adrenal tumor was consistent with pheochromocytoma. No adrenal tumor was noted on follow-up imaging or catecholamine studies.

Discussion

The use of minimally-invasive approaches for the management of renal and adrenal tumors is expanding. For patients with hereditary forms of renal and adrenal tumors, organ-sparing approaches are attractive to preserve function and avoid the

morbidity of repeated open surgery, dialysis, or adrenal replacement therapy. Judicious abdominal CT imaging allows the urologist to identify lesions and plan management strategies. Our current management strategy of renal tumors in VHL includes RFA for renal tumors less than 3 cm that demonstrate growth. For tumors larger than 3 cm, partial nephrectomy remains the gold standard.³ Adrenal pheochromocytomas are followed until function is demonstrated or significant tumor growth is observed before organ-sparing surgery is performed. Although this patient met the inclusion criteria for a phase II trial of percutaneous RFA being done at the NCI, this would have required two separate procedures. To minimize patient morbidity, a combined procedure was performed.

During RFA, accurate probe placement is critical to create an adequate ablation zone. With percutaneous RFA, computed tomographic or sonographic guidance facilitates probe placement. During laparoscopic RFA, correct placement was confirmed with LUS, which is more technically challenging. Alternatively, during renal cryoablation, a discrete iceball with a hyperechoic rim is created allowing monitoring of the freezing process and treatment zone. Unfortunately, RFA does not produce tissue effects that can be monitored sonographically to adequately assess the treatment zone.^{4,5} Therefore, ablations were performed according to needle placement, energy delivery, and probe thermometry. Although the optimum technique for monitoring the ablation process remains to be determined, tissue

thermometry or impedance monitoring may prove to be the best real-time techniques.^{6,7}

Short-term follow-up suggests that the lack of contrast enhancement correlates with tumor destruction, as has been demonstrated with RFA of liver tumors.⁸ The hyperdense nature of the ablated lesions on post-treatment non-contrast CT imaging suggests tumor necrosis and hemorrhage are present. Longer follow-up is needed to follow the natural history of renal tumors treated by RFA to ensure complete destruction. We have not subjected patients undergoing RFA to pretreatment renal biopsy because the pathology of the renal tumors is predictable based on the VHL mutation status.⁹ Further, follow-up biopsies have not been employed due to potential morbidity and sampling error. Rather, CT scans have been our follow-up modality of choice to preserve the minimally-invasive benefits of this procedure.

Laparoscopic partial adrenalectomy appears to be an effective organ-sparing treatment strategy.¹ Multiple studies addressing the use of RFA in hepatic tumors have been published^{8,10,11} but clinical experience in the kidney is limited.¹²⁻¹⁴ At this time, renal RFA must be considered experimental and further study of RFA is mandatory before broad application of this technology is recommended. However, RFA in the kidney may be safely performed using laparoscopic guidance in selected cases. Long-term follow-up is required to determine the cancer-control outcomes of this technique. □

8. Goldberg SN, Gazelle GS, Compton CC, et al. Treatment of intrahepatic malignancy with radiofrequency ablation. *Cancer* 2000;88:2452-2463.
9. Poston CD, Jaffe GS, Lubensky IA, et al. Characterization of the renal pathology of a familial form of renal cell carcinoma associated with von Hippel-Lindau disease: clinical and molecular genetic implications. *J Urol* 1995;153:22-26.
10. Curley SA, Izzo F, Ellis LM, et al. Radiofrequency ablation of hepatocellular cancer in 110 patients with cirrhosis. *Ann Surg* 2000;232:381-391.
11. de Baere T, Elias D, Dromain C, et al. Radiofrequency ablation in 100 hepatic metastases with a mean follow-up of more than 1 year. *AJR* 2000;175:1619-1625.
12. Zlotta AR, Wildschutz T, Raviv G, et al. Radiofrequency interstitial tumor ablation (RITA) is a possible new modality for treatment of renal cancer: ex vivo and in vivo experience. *J Endourol* 1997;11: 51-258.
13. Walther MM, Shawker TH, Libutti SK, et al. A phase 2 study of radio frequency interstitial tissue ablation of localized renal tumors. *J Urol* 2000;163:1424-1427.
14. Gervais DA, McGovern FJ, Wood BJ, et al. Radio-frequency ablation of renal cell carcinoma: Early clinical experience. *Radiology* 2000;217:665-672.

References

1. Walther MM, Herring J, Choyke PL, et al. Laparoscopic partial adrenalectomy in patients with hereditary forms of pheochromocytoma. *J Urol* 2000;164:14-17.
2. Corwin TS, Cadeddu JA. Radio frequency coagulation to facilitate laparoscopic partial nephrectomy. *J Urol* 2001;165:175-176.
3. Herring JC, Enquist EG, Chernoff A, et al. Parenchymal sparing surgery in patients with hereditary renal cell carcinoma: 10-year experience. *J Urol* 2001;165:777-781.
4. Cha CH, Lee FT, Gurney JM, et al. CT versus sonography for monitoring radiofrequency ablation in a porcine liver. *AJR* 2000;175:705-711.
5. Crowley JD, Shelton J, Iverson AJ, et al. Laparoscopic and computed tomography-guided percutaneous radiofrequency ablation of renal tissue: Acute and chronic effects in an animal model. *Urology* 2001;57:976-980.
6. Goldberg SN, Gazelle GS, Dawson SL, et al. Tissue ablation with radiofrequency: Effect of probe size, gauge, duration and temperature on lesion volume. *Acad Radiol* 1995;2:399-404.
7. Goldberg SN, Gazelle GS, Halpern EF, et al. Radiofrequency tissue ablation: Importance of local temperature along the electrode tip exposure in determining lesion shape and size. *Acad Radiol* 1996;3:212-218.