

413

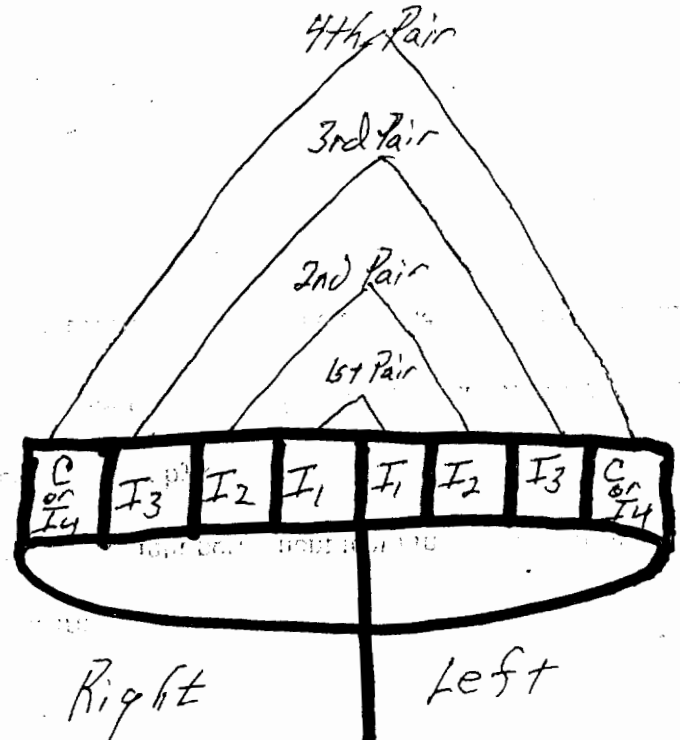
RECEIVED  
FSIS DOCKET ROOM  
Clinton J. Hilt, DVM  
P.O. Box 38 04 MAR -8 PM 3:22  
Dutton, MT 59433  
(406) 799-1130 mobile  
(406) 463-2426 office

February 21, 2004

FSIS Docket  
Docket #03-0251F  
Room 102, Cotton Annex  
300 12<sup>th</sup> and C Street, SW  
Washington, DC 20250-3700

To Whom It May Concern:

Cattle have a total of eight permanent teeth in the front of the lower jaw. These are preceded by eight deciduous (baby or temporary) teeth. According to Sisson and Grossmen's Anatomy of Domestic Animals Fifth Edition, a standard veterinary medical anatomy text, the deciduous and permanent teeth are numbered and identified from the middle of the jaw to left and middle of jaw to the right. Hence, there are two sets of four teeth. The teeth are identified as Incisor 1 (I1), Incisor 2 (I2), Incisor 3 (I3), and Canine ( C or I4). The fourth tooth is developmentally a canine tooth, but has been described and classified as an incisor.



The eruption time of these permanent teeth are stated as:

I1: 1 ½ to 2 years

I2: 2 to 2 ½ years

I3: 3 years

Canine (I4): 3 ½ to 4 years

Obviously there is variation in time when these teeth erupt. Today I examined the dentition on 14 commercial Angus heifers with known ages of 21 ½ to 23 ½ months. The findings follow:

5 heifers	8 deciduous incisors
1 heifer	8 deciduous incisors, roots only
5 heifers	Both I1 fully developed permanent incisors. Balance deciduous incisors.
2 heifers	Left permanent I1 fully developed. No right I1. Balance deciduous incisors.
1 heifer	2 permanent I1 fully developed. Balance deciduous incisor roots.

In Bovine Medicine and Surgery, an article entitled "Eruption of Teeth" by L. Mac Cropsey states, "There is a general agreement among experienced veterinarians that the age at which teeth erupt in cattle varies widely." He also states when bilateral teeth do not erupt or develop synchronously, the assessment of age is based on the one that is less developed. For example, with a pair of incisors, if the left I2 is erupted but not the right I2, the age is based on the right I2.

FSIS Notice 5-04 Section IV.D. states that FSIS recognizes that the permanent incisors of cattle erupt from 24-30 months of age. This is not correct according to Sisson & Grossman. Rather, the age is 18-48 months. Section IV.D also states age is based when at least one of the second set of permanent incisors has erupted and is the most developed of the pair. This is also

incorrect according to L. Mac Cropsey. The assessment of age is based on the bilateral tooth that is less developed.

The attachment to FSIS 5-04 incorrectly refers to I2, the second set of incisors, as the third and fourth incisors (see notation or attachment). As you can see the written description and the attachment depiction are not anatomically correct.

L. Mac Cropsey described maximum development at 29 ½ months as the second pair of permanent incisors being fully developed and gingiva (gum) at the base of third deciduous incisors is receding from the gum line. This is essentially what the attachment states as the erupting third permanent (incorrectly depicting I2) incisor top of the tooth, not above gum line. However, this is not what is depicted. Cropsey's would more accurately age thirty month old cattle.

These discrepancies cause me to doubt the amount of research and proofreading the USDA completed for this notice. At the end of L. Mac Cropsey's article, he states, "Without knowing the animal's history, it is generally unwise to predict an exact age on the basis of dental eruption and development."

During the BSE incident, the USDA stated numerous times that their actions were based on science, but does the "Two Teeth Rule" have scientific basis? According to the quoted texts, this rule does not appear to be based upon veterinary medical information. In my opinion, this interim guidance is advance aging and devaluing young cattle by the misinformation presented in FSIS Notice 5-04.

Sincerely,



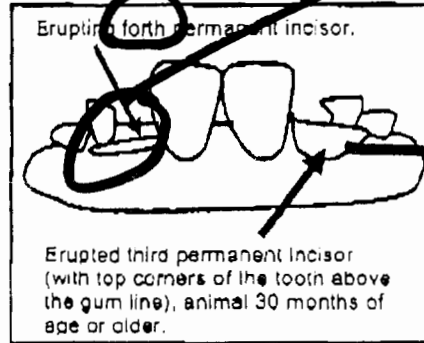
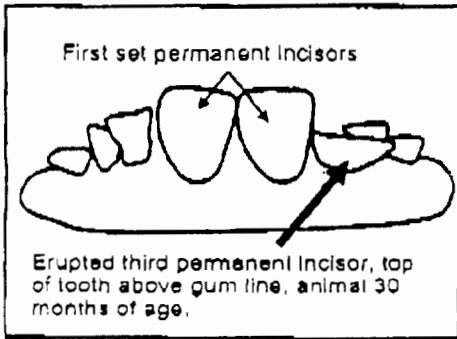
Clinton J. Hilf, DVM

*sp. dentition*

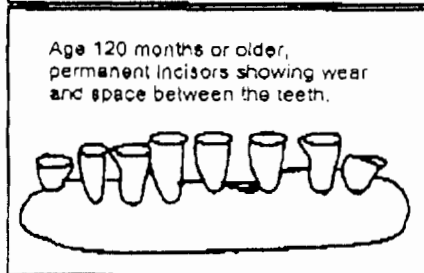
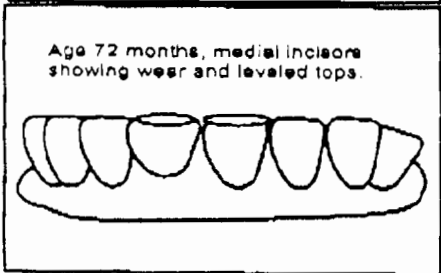
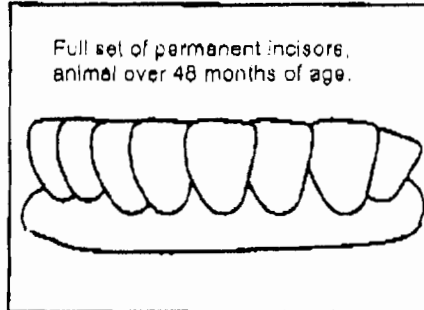
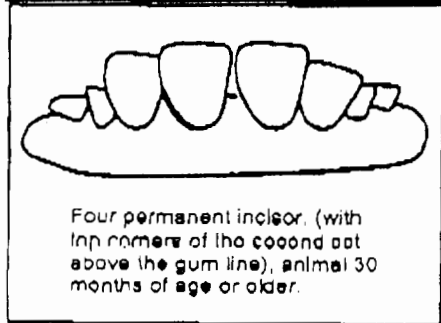
*57. fourth*

The dentition depicted below represents animals 30 months of age or older.

*This is I<sub>2</sub>  
not ~~I<sub>3</sub>~~ fourth*



*This is I<sub>2</sub>  
not third*

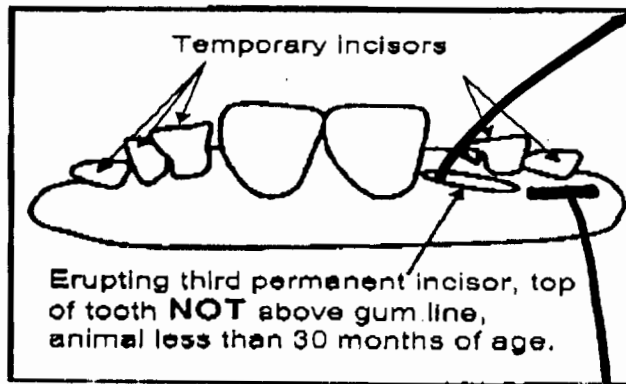


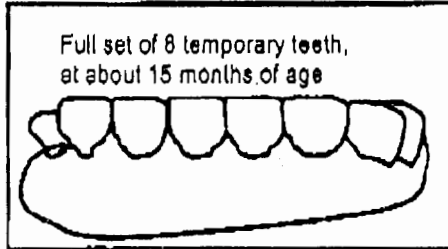
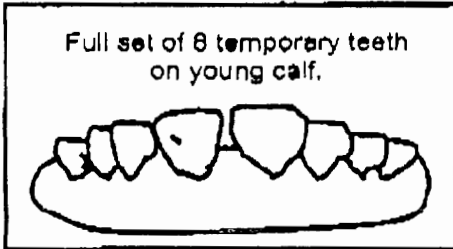


*sp. dentition*

FSIS NOTICE

Attachment

The dentition depicted below represents animals less than 30 months of age.



*This is the second permanent incisor (I2)*

*The third permanent incisor (I3) would be here. Described by L. Mac Cross, as before I3 erupts as being ~30 months. The USDA is 1 Incisor off. It should be called: 4 teeth rule not 2 teeth.*