



NOAA TECHNICAL MEMORANDUM NMFS-SEFSC-537

**Report on Marine Mammal Unusual Mortality Event UMESE0501Sp:
Multispecies Mass Stranding of Pilot Whales (*Globicephala macrorhynchus*),
Minke Whale (*Balaenoptera acutorostrata*), and Dwarf Sperm Whales
(*Kogia sima*) in North Carolina on 15-16 January 2005**

**Aleta A. Hohn
David S. Rotstein
Craig A. Harms
Brandon L. Southall**



March 2006

U. S. Department of Commerce
National Oceanic and Atmospheric Administration
National Marine Fisheries Service
Southeast Fisheries Science Center

This page left blank intentionally



NOAA TECHNICAL MEMORANDUM NMFS-SEFSC-537

Report on Marine Mammal Unusual Mortality Event UMESE0501Sp:
Multispecies Mass Stranding of Pilot Whales (*Globicephala macrorhynchus*),
Minke Whale (*Balaenoptera acutorostrata*), and Dwarf Sperm Whales
(*Kogia sima*) in North Carolina on 15-16 January 2005

Aleta A. Hohn, PhD¹
David S. Rotstein, DVM, MPVM, Dipl. ACVP²
Craig A. Harms, DVM, PhD, Dipl. ACZM³
Brandon L. Southall, PhD⁴

¹NOAA, National Marine Fisheries Service, Southeast Fisheries Science Center, NOAA Beaufort Laboratory, 101 Pivers Island Rd, Beaufort, NC 28516

²NOAA Center for Marine Animal Health, Department of Pathobiology, College of Veterinary Medicine, University of Tennessee, 2407 River Drive, Room A201, Knoxville, TN 37996

³North Carolina State University, College of Veterinary Medicine, Department of Clinical Sciences, Center for Marine Sciences and Technology, 303 College Circle, Morehead City, NC 28557

⁴Director, NOAA Ocean Acoustics Program, National Marine Fisheries Service, Office of Science and Technology, 1315 East West Hwy, SSMC III #12539, Silver Spring, MD 20910

U. S. DEPARTMENT OF COMMERCE
Carlos M. Gutierrez, Secretary
NATIONAL OCEANIC AND ATMOSPHERIC ADMINISTRATION
Conrad C. Lautenbacher, Jr., Administrator
NATIONAL MARINE FISHERIES SERVICE
William T. Hogarth, Assistant Administrator for Fisheries

March 2006

Technical Memoranda are used for documentation and timely communication of preliminary results, interim reports, or special-purpose information.

NOTICE

The National Marine Fisheries Service (NMFS) does not approve, recommend or endorse any proprietary product or material mentioned in this publication. No reference shall be made to NMFS, or to this publication furnished by NMFS, in any advertising or sales promotion which would indicate or imply that NMFS approves, recommends or endorses any proprietary product or proprietary material herein or which has as its purpose any intent to cause directly or indirectly the advertised product to be used or purchased because of NMFS publication.

Correct citation of this report is:

Hohn, A.A., D.S. Rotstein, C.A. Harms, and B.L. Southall. 2006. Report on marine mammal unusual mortality event UMESE0501Sp: Multispecies mass stranding of pilot whales (*Globicephala macrorhynchus*), minke whale (*Balaenoptera acutorostrata*), and dwarf sperm whales (*Kogia sima*) in North Carolina on 15-16 January 2005. NOAA Technical Memorandum NMFS-SEFSC-537, 222 p.

Copies of this report can be obtained from:

http://www.sefsc.noaa.gov/PDFdocs/Report_on_UMESE0501Sp.pdf

Report on Marine Mammal Unusual Mortality Event UMESE0501Sp:

Multispecies Mass Stranding of Pilot Whales (*Globicephala macrorhynchus*), Minke Whale (*Balaenoptera acutorostrata*), and Dwarf Sperm Whales (*Kogia sima*) in North Carolina on 15-16 January 2005

Executive Summary

On 15-16 January 2005, three offshore species of cetaceans (33 short-finned pilot whales, *Globicephala macrorhynchus*, one minke whale, *Balaenoptera acutorostrata*, and two dwarf sperm whales, *Kogia sima*) stranded alive on the beaches of North Carolina. The pilot whales stranded near Oregon Inlet, the minke whale in northern North Carolina, and the dwarf sperm whales near Cape Hatteras. Live strandings of three species in one weekend was unique in North Carolina and qualified as an Unusual Mortality Event.

Gross necropsies were conducted on 16-17 January 2005 on 27 pilot whales, two dwarf sperm whales, and the minke whale. Samples were collected for clinical pathology, parasitology, gross pathology, histopathology, microbiology and serology. There was variation in the number of animals sampled for each collection type, however, due to carcasses washing off the beach or degradation in carcass condition during the course of the response. Comprehensive histologic examination was conducted on 16 pilot whales, both dwarf sperm whales, and the minke whale. Limited organ or only head tissue suites were obtained from nine pilot whales. Histologic examination of tissues began in February 2005 and concluded in December 2005 when final sampling was concluded.

Neither the pilot whales nor dwarf sperm whales were emaciated although none had recently ingested prey in their stomachs. The minke whale was emaciated; it was likely a dependent calf that became separated from the female. Most serum biochemistry abnormalities appear to have resulted from the stranding and indicated deteriorating condition from being on land for an extended period. Three pilot whales had clinical evidence of pre-existing systemic inflammation, which was supported by histopathologic findings.

Although gross and histologic lesions involving all organ systems were noted, consistent lesions were not observed across species. Verminous pterygoid sinusitis and healed fishery interactions were seen in pilot whales but neither of these changes were causes of debilitation or death. In three pilot whales and one dwarf sperm whale there was evidence of clinically significant disease in post-cranial tissues which led to chronic debilitation. Cardiovascular disease was present in one pilot whale and one dwarf sperm whale; musculoskeletal disease and intra-abdominal granulomas were present in two pilot whales. These lesions were possible, but not definitive, causal factors in the stranding. Remaining lesions were incidental or post-stranding. The minke whale and three of five tested pilot whales had positive morbillivirus titers ($\geq 1:8$ with one at $>1:256$), but there was no histologic evidence of active viral infection. Parasites (nematodes, cestodes, and trematodes) were collected from 26 pilot whales and two dwarf sperm whales. Sites of collection included stomach, nasal/pterygoid, peribullar sinuses, blubber, and abdominal cavity. Parasite species, locations and loads were within normal limits for free-ranging cetaceans and were not considered causative for the stranding event. Gas emboli lesions which were considered consistent with or diagnostic of sonar-associated strandings of beaked whales or small cetaceans were not found in the whales stranded as part of UMESE0501Sp.

Twenty-five heads were examined with nine specific anatomic locations of interest: extramandibular fat, intramandibular fat, auditory meatus, peribullar acoustic fat, peribullar soft tissue, peribullar sinus, pterygoid sinus, melon, and brain. The common finding in all examined heads was verminous pterygoid sinusitis. Intramandibular adipose tissue reddening, typically adjacent to the vascular plexus, was observed in some individuals and could represent localized hemorrhage resulting from vascular rete rupture, hypostatic congestion, or erythrocyte rupture during the freeze/thaw cycle. One cetacean had peracute to acute subdural hemorrhage that likely occurred from thrashing on the beach post-stranding, although its occurrence prior to stranding cannot be excluded.

Information provided to NMFS by the U.S. Navy indicated routine tactical mid-frequency sonar operations from individual surface vessels over relatively short durations and small spatial scales within the area and time period investigated. No marine mammals were detected by marine mammal observers on operational vessels; standard operating procedure for surface naval vessels operating mid-frequency sonar is the use of trained visual lookouts using high-powered binoculars. Sound propagation modeling using information provided to NMFS indicated that acoustic conditions in the vicinity likely depended heavily on position of the receivers (*e.g.*, range, bearing, depth) relative to that of the sources. Absent explicit information on the location of animals meant that it was not possible to estimate received acoustic exposures from active sonar transmissions.

Nonetheless, the event was associated in time and space with naval activity using mid-frequency active sonar. It also had a number of features in common (*e.g.*, the “atypical” distribution of strandings involving multiple offshore species, all stranding alive, and without evidence of common infectious or other disease process) with other sonar-related cetacean mass stranding events. Given that this event was the only stranding of offshore species to occur within a 2-3 day period in the region on record (*i.e.*, a very rare event), and given the occurrence of the event simultaneously in time and space with a naval exercise using active sonar, the association between the naval sonar activity and the location and timing of the event could be a causal rather than a coincidental relationship. However, evidence supporting a definitive association is lacking, and, in particular, there are differences in operational/environmental characteristics between this event and previous events where sonar has apparently played a role in marine mammal strandings. This does not preclude behavioral avoidance of noise exposure.

No harmful algal blooms were present along the Atlantic coast south of the Chesapeake Bay during the months prior to the event. Environmental conditions, including strong winds, changes in upwelling- to downwelling-favorable conditions, and gently sloping bathymetry, were consistent with conditions which have been correlated with other mass strandings.

In summary, we did not find commonality in gross and histologic lesions that would indicate a single cause for this stranding event. Three pilot whales and one dwarf sperm whale had debilitating conditions identified that could have contributed to stranding, one pilot whale had a debilitating condition (subdural hemorrhage) that could have been present prior to or resulting from stranding. While the pilot and dwarf sperm whale strandings may have had a common cause, the minke whale stranding was probably just coincidental. On the basis of examination of physical evidence in the affected whales, however, we cannot definitively conclude that there was or was not a causal link between anthropogenic sonar activity or environmental conditions (or a combination of these factors) and the strandings. Overall, the cause of UMESE0501Sp in North Carolina is not and likely will not be definitively known.

Table of Contents

Introduction	1
A. Background on Strandings in North Carolina and the Species Affected	1
B. Determination of 15-16 Jan 05 Strandings as an Unusual Mortality Event	7
C. Chronology of UMESE0501Sp	9
Epidemiology	15
A. Numerical and Spatial Overview of UMESE0501Sp	15
B. Data and Sample Collection	16
C. Environmental Conditions	19
D. Summary of Known Active Mid-Frequency Sonar Transmissions	25
Biomedical Findings	33
A. Clinical Signs	33
B. Clinical Pathology	34
C. Gross Pathology	40
1. Gross Findings: General	40
2. Gross Findings: Post-Cranial	44
3. Gross Findings: Cranial	45
D. Histopathology	48
1. Histologic Findings: General	48
2. Histologic Findings: Post-Cranial	49
3. Histologic Findings: Cranial	53
E. Summary of Gross and Histologic Findings	55
F. Microbiology	57
G. Serology	58
H. Parasitology	59
I. Toxicology	60
J. CT Scans of Heads	60
Comparison of Biomedical Findings	60
A. Individual and Multiple Strandings of <i>Globicephala</i>, <i>Kogia</i>, and <i>B. acutorostrata</i> ...	60
1. Published Reports	60
2. Individual and Mass Strandings: Unpublished Reports	62
3. Comparison of UMESE0501Sp to Published and Unpublished Cases	64
B. Strandings Associated with Use of Military Sonar	66
Differential Diagnoses and Final Diagnoses	68
A. Differential and Final Diagnoses from Clinical and Pathological Results	68
B. Conclusions Regarding Active Military Sonar Transmissions	69
C. Overall Diagnosis	70
Further Tests and Investigations Planned	71
Impact on Affected Populations	72
Recommendations for the Future	74
Acknowledgments	74
Literature Cited	76
Appendices	83

This page left blank intentionally

Introduction

A. Background on Strandings in North Carolina and the Species Affected

NOAA's National Marine Fisheries Service (NMFS) established a stranding response program in North Carolina following the 1987-88 mortality event of bottlenose dolphins along the Atlantic coast. Continuous, consistent, intensive stranding response along most of North Carolina's coast began in 1997 with beach surveys, further development of a volunteer network, and cooperation from the National Park Service (NPS), U.S. Coast Guard, University of North Carolina at Wilmington, Duke University, Virginia Aquarium, and others. The NOAA Lab in Beaufort, NC, has maintained a database of North Carolina stranding events since 1992. Stranding events reported prior to 1997 are deemed reliable although not necessarily complete. From 1997 to the present, it is likely that most stranded marine mammals are reported and that many of those are investigated. Necropsies are conducted or, when the carcass condition is poor, samples are collected when possible.

Since 1992, 31 species of cetaceans are known to have stranded along the coasts of North Carolina. The strandings that occurred on 15-16 Jan 2005 comprised three species that had previously stranded in North Carolina, short-finned pilot whales (*Globicephala macrorhynchus*), dwarf sperm whales (*Kogia sima*), and minke whales (*Balaenoptera acutorostrata*). There are two species in the Genus *Globicephala* and two species in the Genus *Kogia*; both species in each genus strand in North Carolina (Table 1). Short-finned pilot whales strand more frequently than long-finned pilot whales (*G. melas*); pygmy sperm whales (*K. breviceps*) strand more frequently than dwarf sperm whales.

Pilot Whales

Pilot whales have been sighted relatively frequently during surveys off the coasts of North Carolina and the mid-Atlantic. Within the U.S. Atlantic Exclusive Economic Zone (EEZ) along the mid-Atlantic coast, most sightings have occurred primarily within the Gulf Stream (Waring *et al.* 2002, Garrison *et al.* 2003) and along or just offshore of the shelf break (Hamazaki 2002, Mullin and Fulling 2003). For ten sightings of pilot whales during the summer of 1998 (Mullin and Fulling 2003), average water depth was 1,527 m (range 251-4,280 m) and average water temperature was 28.6 °C (range 23.2-31.6 °C). The average group size for nine groups was 16.6 (CV=0.19) (Mullin and Fulling 2003), ranging from 4-30 whales (K. Mullin, SEFSC, unpub data). During winter surveys, there were six sightings of pilot whales with an average group size of 6.83 (CV=23.1). Although long-finned pilot whales are more common in colder waters while short-finned pilot whales are more common in warmer waters, it is difficult to differentiate the species from sightings. Most sightings are identified as *Globicephala* sp. It has been suggested that the primary range of overlap of the species is from North Carolina to New Jersey (Waring *et al.* 2002). Estimates of abundance are available in NMFS stock assessment reports (SAR) [<http://www.nefsc.noaa.gov/psb/assesspdfs.htm>]. The most recently published estimate of abundance for *Globicephala* sp. is 14,524 (CV=0.30) from surveys conducted during the summer of 1998 from the Gulf of St. Lawrence to Florida (Waring *et al.* 2002). More recent surveys covering the same range were conducted during the summer of 2004 by the NMFS Southeast Fisheries Science Center (SEFSC) and Northeast Fisheries Science Center (NEFSC).

Table 1. Strandings of pilot whales (*Globicephala* sp.), pygmy and dwarf sperm whales (*Kogia* sp.), and minke whales (*Balaenoptera acutorostrata*) in North Carolina from 1992-2005.

Month	<i>Globicephala</i>			<i>Kogia</i>			<i>B. acutorostrata</i>
	<i>macrorhynchus</i>	<i>melas</i>	sp.	<i>breviceps</i>	<i>sima</i>	sp.	
1	33	0	0	3	4	0	1
2	6	1	0	2	3	1	1
3	4	2	0	5	1	0	1
4	2	1	2	9	3	0	2
5	2	4	2	4	2	1	1
6	2	1	0	5	2	0	0
7	1	0	0	4	1	0	0
8	0	0	0	3	0	0	0
9	1	1	0	3	1	0	0
10	2	0	0	1	1	0	0
11	0	1	0	4	5	0	1
12	0	0	0	1	1	0	0
Total	53	11	4	44	24	2	7

The new estimate of abundance is 31,139 (CV=0.27) (SEFSC and NEFSC unpub data). The higher abundance estimate is due to better coverage of pilot-whale habitat and better weather conditions during the survey (L. Garrison, SEFSC, pers. comm). The reviewed estimate will be included in the 2006 SAR (in review). The estimate is provisional pending that review.

Known human-caused sources of mortality for pilot whales include interactions with the pelagic longline fishery, mid-Atlantic coastal gillnets, mid-Atlantic bottom trawl fishery, and North Atlantic bottom and mid-water trawl fisheries, with the highest level of mortality from the pelagic longline fishery (Waring *et al.* 2002). The most recently published estimates of mean total annual mortality of pilot whales in all fishing gear from 1996-2000 was 199 (CV=0.43) (Waring *et al.* 2002). Observed takes in that fishery were primarily from South Carolina to Cape Cod (Garrison 2003). According to Waring *et al.* (2002) and Garrison (2003), bycatch from January-March (the time frame of the mass stranding) was concentrated on the continental shelf northeast of Cape Hatteras, consistent with sighting patterns. Estimated mortality and serious injury from longlines declined from 109 during 2000 to 21 during 2003 (Garrison 2003, Garrison and Richards 2004). As with the estimates of abundance, more recent estimates of mortality are under review. Mean annual mortality from 2000-2004 has been estimated as 115 whales (CV=0.23) from all commercial fisheries (NEFSC and SEFSC unpub data). The updated estimate will be included in the 2006 SAR (in review). The estimate given here is provisional pending that review.

From January 1992 through December 2005, 68 pilot whales were reported on North Carolina beaches: 53 short-finned, 11 long-finned, and four of unknown species (Table 1). They were primarily distributed north of Cape Hatteras (Fig. 1). Of the 53 confirmed short-finned pilot whales, 33 were part of the mass stranding in January 2005. Of the remaining 20, the median strandings annually was two (mean=1.4, range=0-8). Only in 1994 and 2005 did more than two short-finned pilot whales strand in a year (Fig. 2). From 1992-2005, there have been four mass strandings (≥ 2 animals) of short-finned pilot whales (Table 2). In October 1973, there was a mass stranding of 28 short-finned pilot whales at Cape Lookout, NC (records in Smithsonian

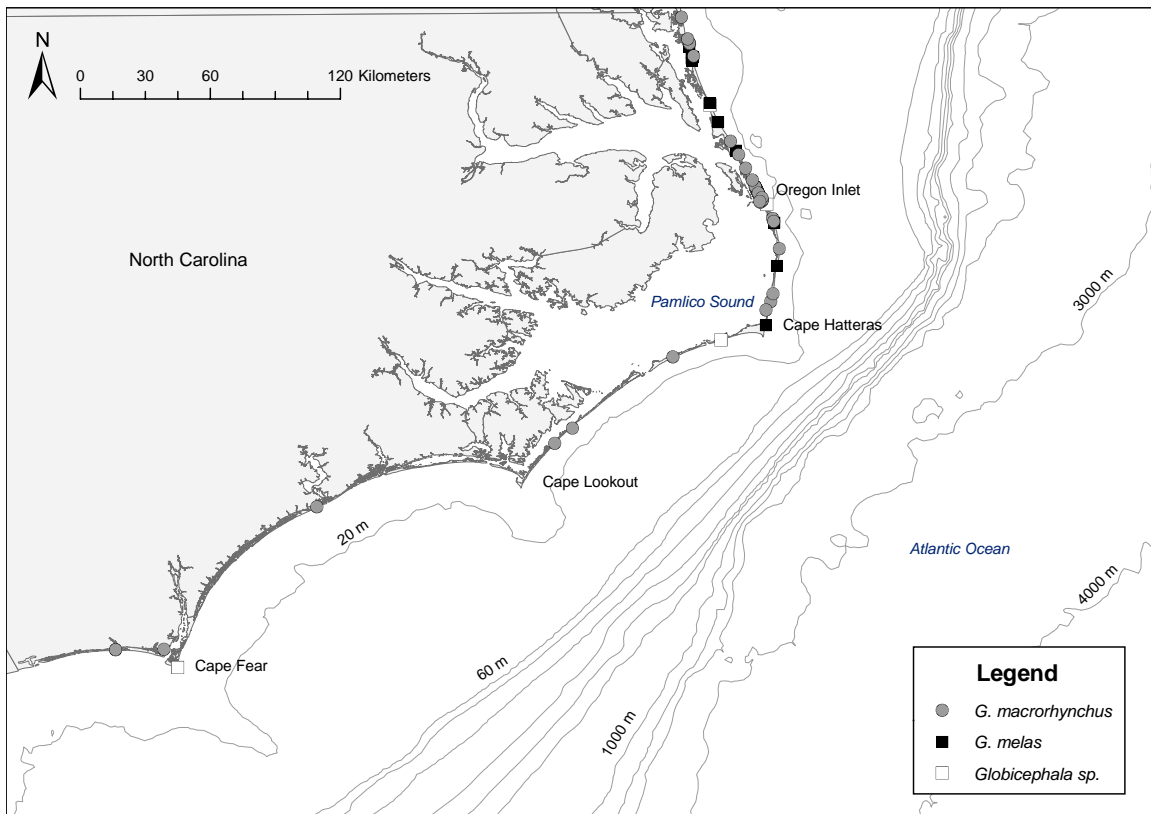


Figure 1. Distribution of pilot whale strandings along the coast of North Carolina, 1992-2005, with bathymetry isobaths. The strandings on 15-16 Jan 2005 are included and are north of Oregon Inlet.

Cetacean Distributional Database). Since then, the only mass stranding of more than three animals occurred in January 2005. Following that stranding through December 2005, four additional short-finned pilot whales and two pilot whales of unconfirmed species stranded. Even excluding the January 2005 mass stranding, there has been a seasonal component to the strandings, with 10 of the 22 strandings occurring in February and March (Fig. 3) consistent with the highest levels of take in the pelagic long-line fishery off of North Carolina. The past five years of stranding records along the Atlantic coast, including Nova Scotia, are included in the SAR (Waring *et al.* 2002). Pilot whales strand much more frequently from Massachusetts north and in Florida than along beaches in between.

Friedlander *et al.* (2005) reviewed records from 86 mass strandings of short-finned pilot whales from 1887-2005 along the Atlantic and Gulf of Mexico coasts. Mass strandings along the Atlantic coast (n=45) occurred most frequently between central and northeastern Florida and from January-March, with a mean group size of 16.5, a mode of two animals, and a range of 2-140. Fifteen mass strandings were north of Florida; ten of those were in North Carolina. Five of the 15 included more than ten animals and four of those were in North Carolina.

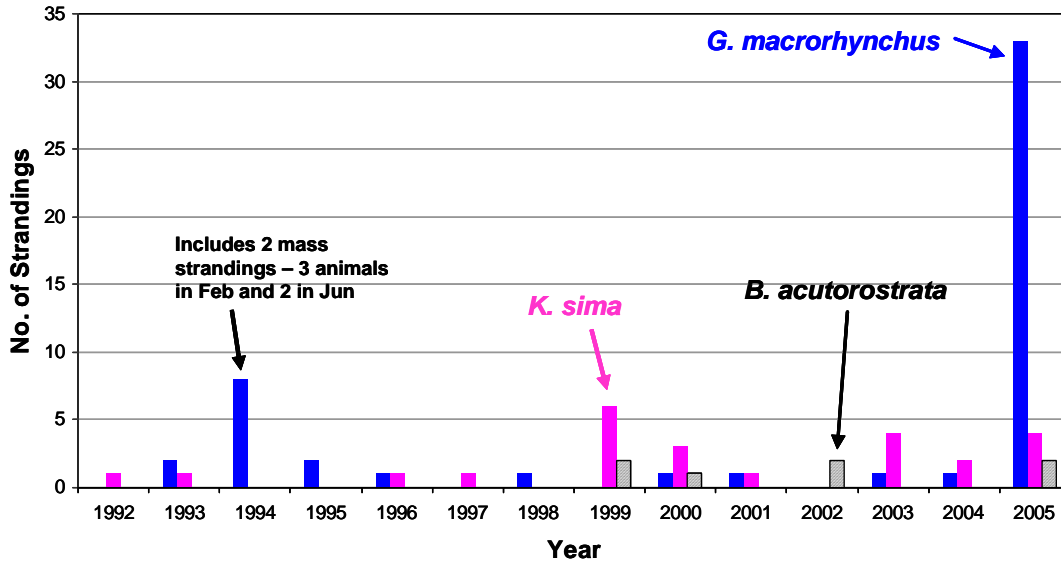


Figure 2. Total annual strandings of short-finned pilot whales (*G. macrorhynchus*) (blue bars), dwarf sperm whales (*K. sima*) (pink bars) and minke whales (*B. acutorostrata*) (black diagonal bars) in North Carolina from 1992-2005. Stranding events reported prior to 1997 are deemed reliable although not as complete as those after 1997.

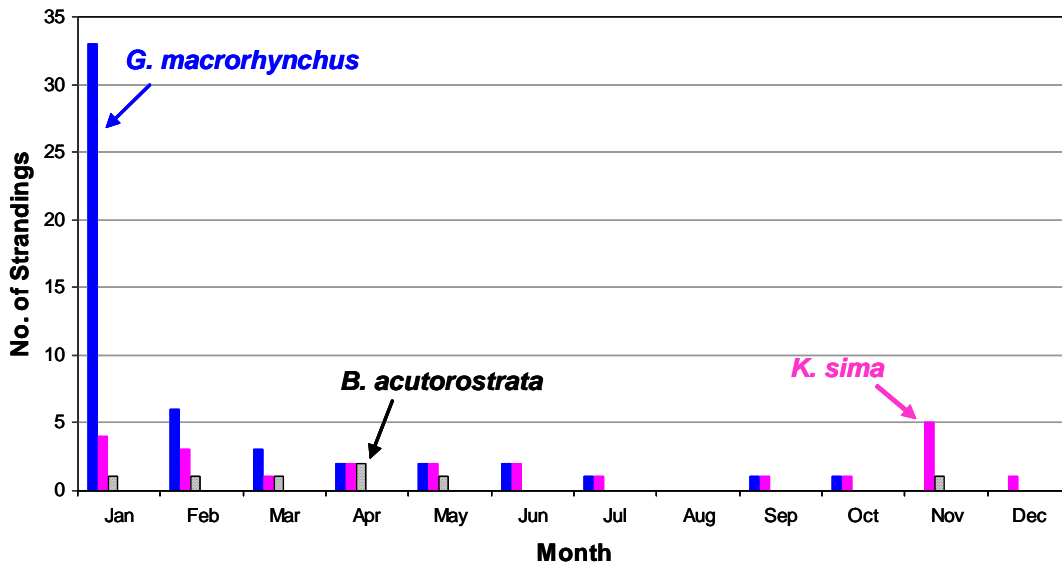


Figure 3. Total monthly strandings of short-finned pilot whales (*G. macrorhynchus*) (blue bars), dwarf sperm whales (*K. sima*) (pink bars) and minke whales (*B. acutorostrata*) (black diagonal bars) in North Carolina from 1992-2005.

Table 2. Known mass strandings (≥ 2 animals) of pilot whales and dwarf sperm whales in North Carolina from 1992-2005. All were short-finned pilot whales; no long-finned pilot whales mass stranded in NC during those dates. A small dwarf sperm whale calf was found dead on North Core Banks on 19 Jan 2005 in Condition Code 3. Abrasions suggested it stranded alive; size suggested it was a dependent calf. Location and Condition suggested that it was the calf of the lactating female that stranded on 16 Jan 2005.

Date	No.	Status when Found	Location	Age classes	Sex
Pilot Whales					
26-Feb-94	3	All fresh dead	Corolla	Adult, subadult?	2 F, 1 M
01-Jun-94	2	1 fresh dead, 1 alive	Holden Beach	Adult	2 M
24-Mar-95	2	Both alive	Manteo / Kill Devil Hills	Adult	1 M, 1 F
15-Jan-05	33	18 alive, 15 dead	South Nags Head	All	21 F, 6 M, 6 not examined
Dwarf Sperm Whales					
29-Nov-99	2	Alive	Hatteras	Adult and calf	2 F
23-Nov-03	2	Alive	Southern Shores	Adult and calf	2 F
16-Jan-05	2	1 alive, 1 fresh dead	Buxton	Adult	1 lactating F, 1 M
(19-Jan-05)	(1)	(dead)	(South Core Banks)	(Calf)	(1 calf)

Dwarf Sperm Whales

Dwarf sperm whales are a pelagic species distributed widely in temperate and tropical waters (Waring *et al.* 2003). They are similar in appearance to pygmy sperm whales; the two species are difficult to differentiate during surveys (Mullin and Fulling 2003). As a result, sightings in the western North Atlantic are generally classified as *Kogia* sp. During summer surveys in the western North Atlantic, *Kogia* sp. were sighted in water depths of 766-4,079 m (mean=2,586 m, n=9 sightings) and water temperatures of 26.9-30.9° C (mean=29.6° C, n=9) (Mullin and Fulling 2003). Average group size was 1.9 (CV=0.16) (Mullin and Fulling 2003) with a range of 1-3 (Mullin, NMFS SEFSC, pers. comm.). A rehabilitated radio-tracked pygmy sperm whale released on the continental shelf off of Florida headed directly toward the shelf break then traveled along or just offshore of the shelf break along the eastern edge of the Gulf Stream during five days of tracking (Scott *et al.* 2001). Abundance of *Kogia* sp. in the western North Atlantic has been estimated at 695 (CV=0.49) (Waring *et al.* 2003). These results are from summer surveys; seasonal shifts in distribution are unknown. The same surveys conducted by the Southeast and Northeast Fisheries Science Centers during the summer of 2004 that resulted in a more recent estimate of abundance for pilot whales also provided data that resulted in a more recent estimate for *Kogia* sp. of 395 (CV=0.41) (SEFSC and NEFSC unpub data). The updated estimate will be included in the 2006 SAR (in review). The estimate given here is provisional pending that review. There are no known significant sources of human-caused mortality; there were no known takes in commercial fisheries from 1996-2000 (Waring *et al.* 2003).

The stranding network in North Carolina reported 70 stranded *Kogia* from January 1992 through December 2005 (Table 1), primarily north of Cape Lookout (Fig. 4). It is the third most commonly stranded genus (after *Tursiops* and *Phocoena*) in North Carolina despite the low estimate of abundance. Dwarf sperm whales were reported 24 times, ranking it as the 8th most abundant of 31 stranded species of cetacean in North Carolina, although in ninth (of 13) years there was none or only one stranding (Fig. 2). Four stranded during 2005, including two, and

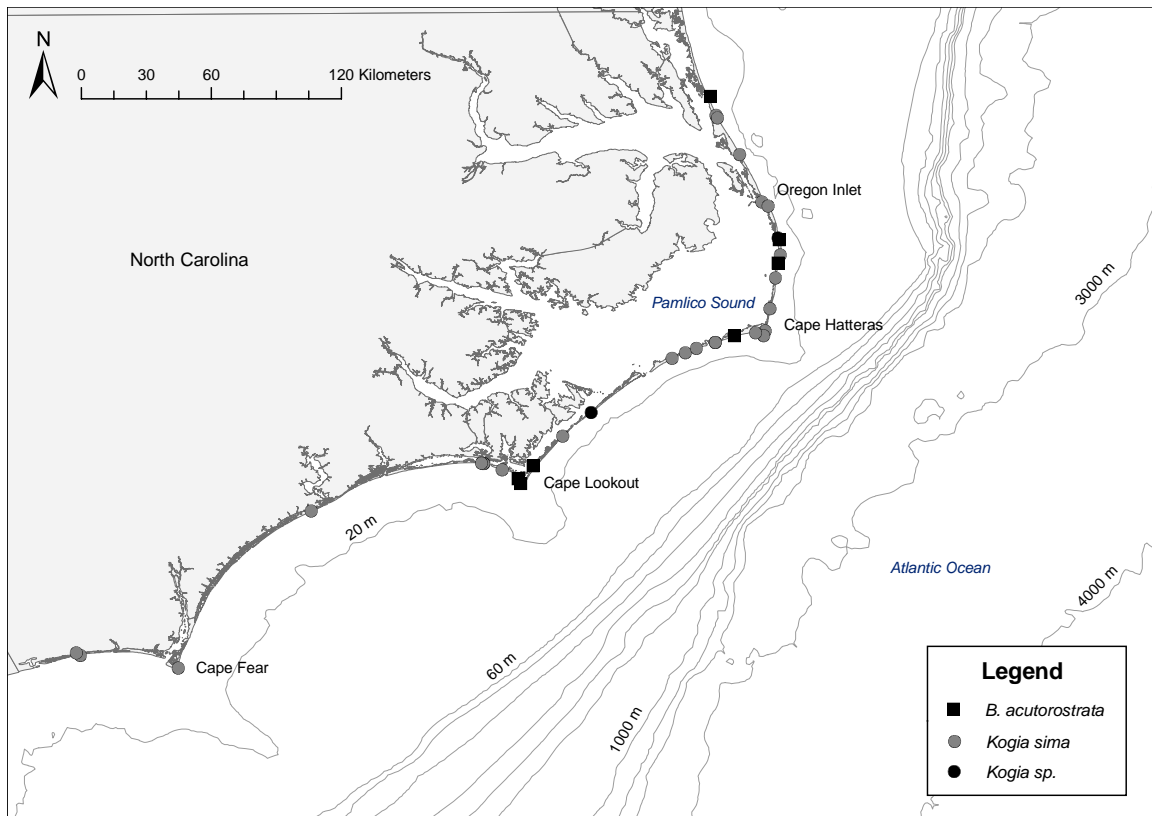


Figure 4. Distribution of dwarf sperm whale (*K. sima*), unidentified *Kogia* sp., and minke whale (*B. acutorostrata*) strandings along the coast of North Carolina, 1992-2005. The 15-16 Jan 2005 strandings are included (the northernmost minke whale and the dwarf sperm whales at Cape Hatteras and north of Cape Lookout).

possibly three (see description in the Epidemiology section), on 16 Jan 2005. Strandings occurred during most months but with fewer in summer (Fig. 3). Mass strandings (≥ 2 animals) have occurred three times since 1992, including the January 2005 strandings (Table 2). The past five years of stranding along the Atlantic coast are included in the SAR (Waring *et al.* 2003). Thirty-five dwarf sperm whales were reported stranded along the Atlantic coast from North Carolina through Florida from 1999-2003, with strandings much more common in North Carolina ($n=17$) and Florida ($n=11$) than South Carolina ($n=4$) or Georgia ($n=3$) (NOAA National Marine Mammal Health and Stranding Response Database; to be included in the 2006 SAR pending review).

Minke Whales

Minke whales are widely distributed in the world's oceans. In the Atlantic, several stocks are recognized; western North Atlantic minke whales are part of the Canadian East Coast stock (Waring *et al.* 2003). Sightings during surveys in the western North Atlantic have primarily been off New England and Canada rather than the mid-Atlantic (Hamazaki 2002, Waring *et al.* 2003). The southernmost sighting in recent surveys by the National Marine Fisheries Service was of one whale offshore of the mouth of the Chesapeake Bay (north of North Carolina) at a depth of 3,475 m (Mullin and Fulling 2003). These sightings occurred during summer surveys. It is possible that the winter distribution is in the West Indies and south and east of Bermuda

(Mitchell 1991, Waring *et al.* 2003). Abundance of the Canadian East Coast stock of minke whales has been estimated as 2,998 (CV=0.19) (Waring *et al.* 2003). This remains the most recent estimate of abundance. Known sources of human-caused mortality include commercial fishing pots and gillnets, as well as ship strikes (Waring *et al.* 2003). According to Waring *et al.* (2003), from 1997 to 2001, the average annual human-caused mortality was 3.6 minke whales per year in the U.S. More current estimates of mortality are not available.

Stranded minke whales were reported in North Carolina five times from 1992 to 2005 (Table 1), all from 1999-2002 (Fig. 2). Two were found in 2005, the animal from the UME and a second animal in March. All of the whales stranded at or north of Cape Lookout (Fig. 4). Strandings have occurred in January (n=1, total length of 284 cm), February (n=1 at 475 cm), March (n=1 at 293 cm), April (n=2 at 303 cm and 321 cm), May (n=1 at 456 cm), and November (n=1 at 359 cm) (Fig. 3), suggesting the possibility that minke whales may be offshore of North Carolina during migration. Length at birth is 240-280 cm (Sergeant 1963); births occur from November through February but are primarily in December and January (Evans and Stirling 2001). Five of the eight strandings had body lengths of 359 cm or less, suggesting that they were young of the year. Four likely stranded within weeks or months of birth. The smallest was the animal that stranded in January 2005.

B. Determination of 15-16 Jan 05 Strandings as an Unusual Mortality Event

The Working Group on Marine Mammal Unusual Mortality Events has developed a set of criteria to be utilized in determining an Unusual Mortality Event (UME) (<http://www.nmfs.noaa.gov/pr/health/mmume/criteria.htm>). As noted on the website, a single criterion or combination of criteria may indicate the occurrence of an Unusual Mortality Event (UME). The criteria are:

1. A marked increase in the magnitude of strandings when compared with prior records.
2. Animals are stranding at a time of the year when strandings are unusual.
3. An increase in strandings is occurring in a very localized area (possibly suggesting a localized problem), is occurring throughout the geographical range of the species/population, or spreads geographically with time.
4. The species, age, or sex composition of the stranded animals is different than that of animals that normally strand in the area at that time of the year.
5. Stranded animals exhibit similar or unusual pathologic findings or the general physical condition (*e.g.*, blubber thickness) of stranded animals is different from what is normally seen.
6. Mortality is accompanied by behavior patterns observed among living individuals in the wild that are unusual, such as occurrence in habitats normally avoided or abnormal patterns of swimming and diving.
7. Critically endangered species are stranding.

On 15-16 Jan 2005, three offshore species of cetaceans (33 pilot whales, one minke whale, and two dwarf sperm whales) stranded alive on the beaches of North Carolina. Although the focus of the response was the pilot whales, mass strandings of pilot whales do occur periodically along the east coast, albeit more frequently in Massachusetts and Florida than North Carolina (McFee 1990, Friedlander *et al.* 2005, NOAA National Marine Mammal Health and Stranding Response

Table 3. Strandings of alive or freshly dead multiple offshore species of cetaceans within a short time period along North Carolina beaches from 1992 through 2005 has been rare and comprised only two species. Three species stranded alive or were found fresh dead within a 7-day period only twice, with the strandings occurring within a 4- or 5-day time frame. Bottlenose dolphins have been excluded because morphotype (*i.e.*, coastal or offshore) has only recently been recorded in the database.

Date	Species Stranded	Number of Animals
Strandings of two species within a 3 day period		
6, 8 Feb 1992	Fin whale and Atlantic spotted dolphin	2
6, 7 Jun 1993	Pygmy sperm whale and <i>Mesoplodon</i> sp.	2
11, 13 Feb 1994	Striped dolphin and Risso's dolphin	2
16 Feb 1995	Common dolphin and Risso's dolphin	2
29, 31 May 1996	Cuvier's and True's beaked whales	2
12, 14 Feb 2001	Humpback whale and short-finned pilot whale	2
2, 4 Apr 2002	Pantropical spotted dolphin and Pygmy sperm whale (2)	3
27, 28 Jan 2003	Pygmy sperm whale and clymene dolphin	2
28, 30 Jan 2004	Dense beaked whale and sperm whale	2
25 Apr 2004	Dwarf sperm whale and Atlantic white-sided dolphin	2
Strandings of three species within a 7-day period		
2, 6, 7 Jun 1993	Pygmy and dwarf sperm whales, <i>Mesoplodon</i> sp.	3
16, 19 Feb 1995	Common dolphin, striped dolphin, Risso's dolphin	3

Database). In itself, a mass stranding of pilot whales is not an unusual mortality event. In addition, the timing of strandings for the three species was not unusual; strandings of each species in North Carolina tends to be during the winter.

Why was this event an UME? In North Carolina, 2,038 cetacean strandings were reported from 1992-2005, a mean of 145.6 cetaceans per year. Only ten times has there been more than two pelagic species stranding alive or freshly dead within a 2-day period (Table 3). There are no reports of three pelagic species stranding within a 2-3 day period. Three offshore species have stranded previously within 4-6 days, once in 1993 and once in 1995 (Table 3).

Using North Carolina data from 1992 through 2004 (*i.e.*, excluding the January 2005 event), we calculated the probability of a live-stranding, under normal circumstances, for each species in the event by dividing the number of stranding events by the number of days these events could have occurred (13 years = 4,745 24-hour periods). During this time, there were six live-stranding events for *G. macrorhynchus*, of which one was a multi-animal stranding. Therefore the probability of a pilot whale stranding any given day is 1.26×10^{-3} . *K. sima* had eight live-stranding events and two were multi-animal, giving a stranding probability of 1.68×10^{-3} . Likewise the probability for *B. acutorostrata* was calculated as 2.11×10^{-4} from one stranding event (no multi-animal).

The prior probabilities describe only a few of the many species we encounter and consider only live-strandings, which are already a small proportion of all strandings. While these probabilities seem quite small, we are highly likely to continue having live-strandings. The probability of going an entire year without a *K. sima* stranding is $(1 - 1.68 \times 10^{-3})^{365} = 0.54$. When we consider only the three species in the January 2005 event, the probability of no live-stranding events drops

to 0.32, *i.e.*, there is a 68% chance that we will have a live-stranding event that includes one of these three species discussed in a given year.

Nonetheless, considering the probabilities of daily stranding and assuming the independence of live-strandings among the three species involved in the January 2005 event, the probability of all three species live-stranding under normal circumstances is the product of their individual live-stranding probabilities, the probabilities of multi-animal live-stranding events for *K. sima* (0.25) and *G. macrorhynchus* (0.17), and the probability of a single animal stranding for *B. acutorostrata* (1.00) $[(1.26 \times 10^{-3})(0.17)(1.68 \times 10^{-3})(0.25)(2.11 \times 10^{-4})(1.00) = 1.87 \times 10^{-11}]$ or about a 2 in 100 billion chance.

The event of 15-16 Jan 2005 met the UME criteria of an increase in strandings occurring in a very localized area (possibly suggesting a localized problem) (criterion #3), the species composition was different than that of animals normally stranding in the area because three species stranded in less than 48 hours (criterion #4), and the stranded animals of disparate species were alive (criterion #5). The event was deemed to be an UME by the Working Group on Marine Mammal Unusual Mortality Events in August 2005.

Five other UMEs have occurred on the U.S. east coast from 2003-2005 that included North Carolina or species involved in the North Carolina January 2005 multi-species UME: (1) harbor seals and minke whales in Maine in 2003-2004, (2) small cetaceans in Virginia in 2004, (3) offshore species of small cetaceans from North Carolina through Georgia in 2004, (4) harbor porpoise in North Carolina in 2005, and (5) large whales in the northeast U.S. in 2005. In the first UME, there were 19 minke whale mortalities from May through November 2003 and all occurred during a biotoxin event. None of the mortalities was directly attributed to the event; two died due to entanglement (one was euthanized due to severe entanglement) while for the others cause of death was not determined (data from NMFS Northeast Regional Office). During the second UME, one minke whale stranded, in May. No pilot whales or dwarf sperm whales were involved. Cause of the UME and cause of death of the minke whale remain unknown (data from NMFS Northeast Regional Office). In the third UME, one short-finned pilot whale and one dwarf sperm whale were included in the event. Investigation of the UME is in progress. Only harbor porpoise comprised the harbor porpoise (4th) UME in North Carolina in 2005. Cause of the event is unknown. The fifth UME encompassed 10 stranded and floating minke whales from July through October 2005 during another harmful algal bloom (*Alexandrium* spp) (Anderson *et al.* 2005, Doucette *et al.* 2006). Actual cause of death for nine of the whales has not been determined directly; the 10th was an entanglement (data from NMFS Northeast Regional Office). Investigation of these UMEs and their causes is on-going.

In the NOAA National Marine Mammal Health and Stranding Response Database, the Unusual Mortality Event that occurred in North Carolina on 15-16 Jan 2005 is labeled UMESE0501Sp, as a multispecies (Sp) UME that was the first in 2005 (0501) in the southeast (SE) United States. We shall refer to this event by that label throughout the remainder of this report.

C. Chronology of UMESE0501Sp

The first report of the mass stranding on 15 Jan 2005 was made by a National Park Service (NPS) Ranger who was walking the beach in southern Nags Head early that Saturday morning.

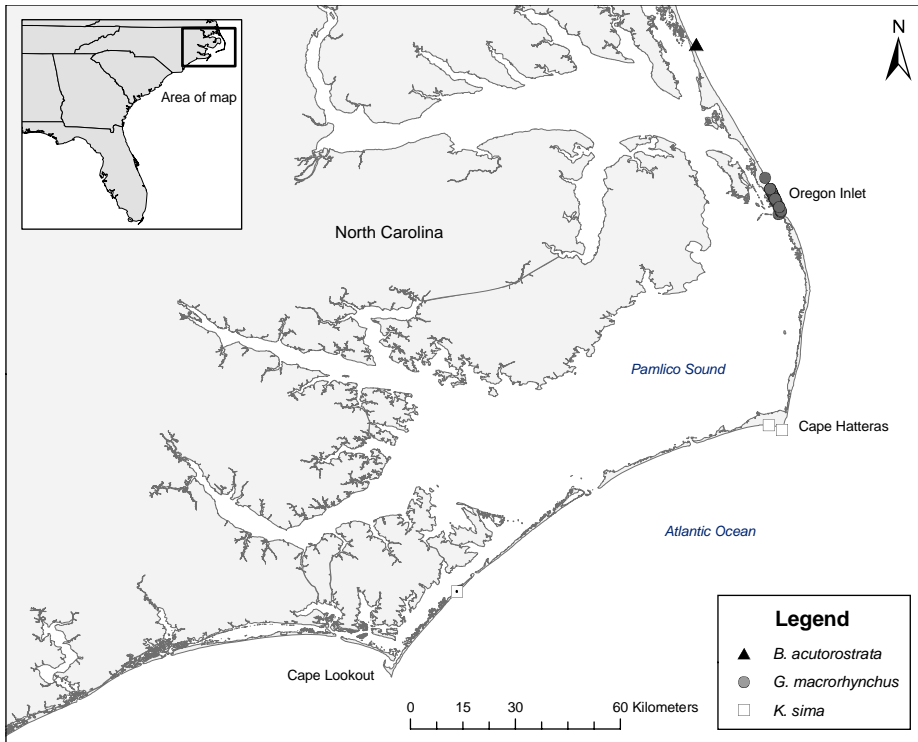


Figure 5. Distribution of stranded short-finned pilot whales (*G. macrorhynchus*), dwarf sperm whales (*K. sima*) and minke whale (*B. acutorostrata*) in North Carolina during UMESE0501Sp. Included is the calf dwarf sperm whale that stranded on 19 Jan 2005 (southernmost stranding, with a dot in the square).

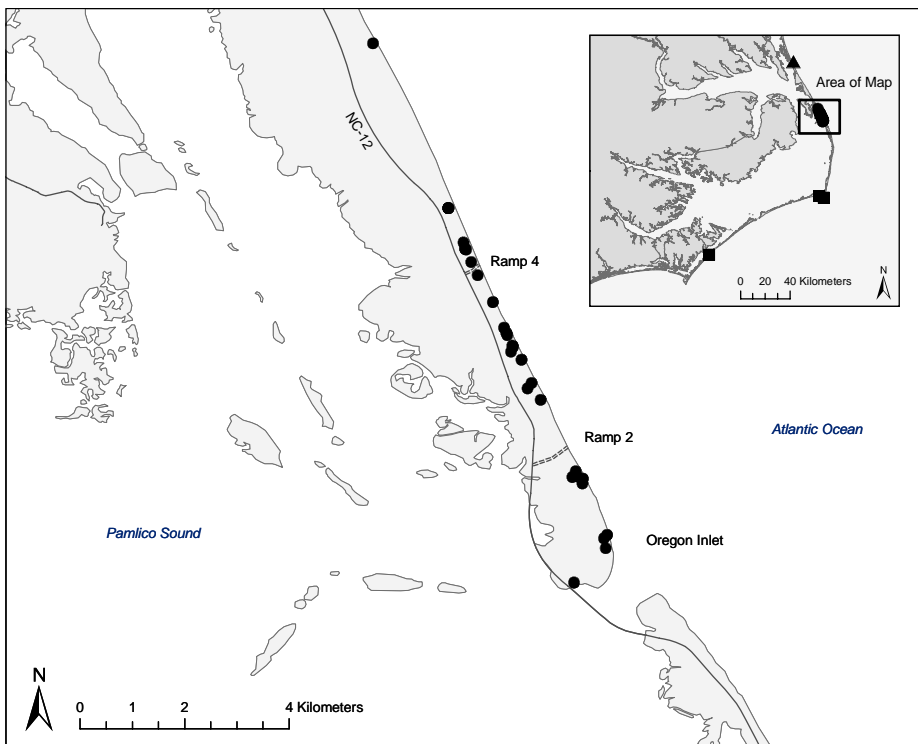


Figure 6. Distribution of the mass-stranded short-finned pilot whales found on 15 Jan 2005. The insert shows the area included in the larger map as well as the stranding locations of the minke whale (triangle) and dwarf sperm whales (squares).

He called the NOAA stranding response contact on the Outer Banks, Karen Sayles, who called Aleta Hohn in Beaufort. The latter call was received at approximately 0750 hrs EST. At that time the NPS Ranger thought the animals were pilot whales but it was yet to be confirmed. He counted 15 animals dead and another 18 animals alive in the surf (Fig. 5). Soon after, Karen confirmed that they were pilot whales. In immediate discussion with the SEFSC, Blair Mase, Southeast Regional Stranding Coordinator, was designated as offsite coordinator and Aleta Hohn as onsite coordinator.

At 0810 hrs EST, Gretchen Lovewell, coordinator for marine mammal stranding response at NOAA's Beaufort laboratory, received a page about a live whale on the beach in northern North Carolina (Fig. 5). With that call, we were concerned that there might be pilot whales from Oregon Inlet north almost to Virginia, a distance of about 48 km from the pilot whales to the minke whale. The Virginia Aquarium's (VAQS) stranding team was contacted with the request to respond to the stranding and they subsequently identified it as a live minke whale.

As with other mass strandings, the response required a large number people and resources. A phone tree was established to mobilize beach responders and a NPS heavy equipment operator. Phone calls were made to individuals from a number of institutions from North Carolina to Maryland. Many individuals were able to assist (Appendix I) and a core team traveled to Nags Head on Saturday. NOAA vehicles were filled with supplies for necropsy of 33 whales (the maximum number counted) and by 1130 hrs EST all NOAA vehicles had left for Nags Head, a 4-hr drive. Other responders, some closer and some further from the stranding, had also mobilized, bringing gear and supplies. To determine the spatial extent of the stranding, aerial surveys were conducted by the U.S. Coast Guard and NPS and the beaches south of Oregon Inlet were checked by Pea Island Wildlife Refuge staff. The southernmost animal was just inside Oregon Inlet; the northernmost was south of Nags Head, 10.3 km north of the southernmost animal (Fig. 6).

First responders on the beach had to cease work because the high tide (at 1149 hrs EST) and narrow beaches restricted access to the whales. The first team on-site able to evaluate the condition of the pilot whales was from VAQS, led by Denise Boyd; they arrived about 1200 hrs EST. Another team from VAQS, led by Wendy Walton, LVT, euthanized the minke whale in Corolla, left the carcass on the beach, and drove directly to Nags Head, arriving at approximately 1230 hrs EST. Upon return to the beach after high tide, they found 31 animals, seven of which were alive. All live animals were located south of Ramp 4 (Fig. 6). The animals' condition, high surf, gusting winds, narrow beaches and an incoming tide posed serious risks to responders allowing for no immediate relocation or release option for the whales. Throughout the afternoon and early evening, each live whale encountered was euthanized (Table 4). For carcasses north of Ramp 2, numbers were put on the carcasses for identification; blood, vitreous fluid and notes were taken. Animals south of Ramp 2 were not tagged initially. Later in the afternoon, each carcass was tagged with rototags or Tyvek tags and cable ties by staff and students from Duke University. Responders left the beach shortly after dark.

An all-hands debriefing was held on Saturday night to evaluate the situation and develop the protocol for response on Sunday and Monday. We reviewed what had been learned and done during that day, including how many animals had been counted and marked, how the numbers on carcasses corresponded to the rototags, how many animal had been euthanized, how many blood



Fig. 7. Pilot whales stranded on a narrow strip of beach between Nags Head and Oregon Inlet on 16 Jan 2005. Photo was taken during an incoming tide. The whales washed out before they could be moved to a wider beach above the high tide line. Photo by the Cetacean and Sea Turtle Team, NMFS SEFSC at NOAA Beaufort Lab.

samples had been collected, the spatial distribution of carcasses, and special circumstances such as narrow beaches that would not only be unsuitable for working up carcasses but also would be impassable at high tide (Fig. 7). It was decided that the field number for each carcass would be the rototag (RT) number. Priorities and protocols for sampling were established, including histology, virology, genetics, bacteriology, toxicology and life history. In planning for necropsies, we established 10 teams of 4-5 people with each team led by a person with considerable marine mammal necropsy experience (Appendix I). The goal was to collect as extensively as possible from each carcass and for each team to work up three carcasses on Sunday in order to collect samples before carcasses degraded. The on-site coordinator was designated to be mobile, rotating among teams to ensure each had sufficient necropsy supplies and peanut butter sandwiches, and to provide a warm vehicle in the event of overexposure of individuals to the cold and wind (see environmental conditions below). Datasheet packets were compiled and handed out to team leaders.

On Sunday, 16 Jan 2005, teams set out to the beach at first light. Each team was provided with supplies and vehicles were coordinated to transport teams to carcasses. Adverse conditions (drizzle, wind chill, gusting winds) hindered progress. In addition, it soon became apparent that more carcasses than anticipated needed to be moved because they were on beaches where the high tides would render the beaches unworkable and, in many cases, wash out the carcasses. The NPS provided a front-end loader to relocate carcasses to wider beaches with adequate beach above high tide (Fig. 8) and some carcasses were moved. Nonetheless, during the afternoon on Sunday, four carcasses did wash out before they could be relocated. Additional overflights by

Table 4. Condition and time of each whale when first examined. For whales euthanized, method and dose is given. In many cases, the team focused on searching for live whales and did not note the time when dead whales were found. The first notes were recorded on 15 Jan 2005 for the pilot whales (RT) and minke whale (CTH001) and 16 Jan 2005 for the dwarf sperm whales (KMS). Times are EST (local time). n/r = not recorded

Field ID	Condition when First Evaluated	Time of First Notes	Euthanasia Method and Dose
RT12	Alive	n/r	diazepam 20 mg IM, sodium pentobarbital 23,400 mg & phenytoin 300 mg intrahepatic
RT13	Alive	16:20	meperidine 100 mg IM, sodium pentobarbital 19,500 mg & phenytoin 2,500 mg intracardiac
RT19	Alive	n/r	xylazine 6,000 mg & acepromazine 100 mg IM only
RT20	Dead	n/r	
RT21	Alive	15:46	
RT22	Dead	n/r	
RT24	Firm rigor	13:32	
RT47	No rigor	12:40	
RT48	Alive	n/r	sodium pentobarbital 46,800 mg & phenytoin 6,000 mg
RT49	Jaw in rigor, still warm	13:05	
RT50	Rigor just setting in	12:56	
RT54	Dead	n/r	
RT57	Dead	n/r	
RT59	Dead	n/r	
RT63	Alive	n/r	xylazine 1000 mg & acepromazine 100 mg IM, sodium pentobarbital 46,800 mg & phenytoin 6,000 mg
RT66	Alive	n/r	sodium pentobarbital 46,800 mg & phenytoin 6,000 mg
RT67	Dead	n/r	
RT68	Firm rigor	13:26	
RT69	Dead	n/r	
RT71	Dead	16:31	
RT72	Alive	15:37	
RT74	Alive	n/r	xylazine 6,000 mg & acepromazine 100 mg IM only
RT89	Dead	n/r	
RT100	Dead	13:46	
RT101	Dead	13:54	
RT102	Dead	13:59	
RT103	Dead	14:11	
RT104	Dead	14:14	
RT105	Dead	14:17	
RT106	Dead	14:31	
RT107	Dead	14:37	
CTH001	Alive	~09:30	20 mg diazepam IM, sodium pentobarbital 70,200 mg & phenytoin 9,000 mg intrahepatic
KMS379	Alive	10:00	
KMS380	Alive	10:00	

the U.S. Coast Guard and the NPS both north and south of Nags Head and Oregon Inlet confirmed that the strandings remained contained within the initial range. On Sunday, 14 carcasses received thorough necropsies, with an impressive array of samples and data collected under the circumstances. Carcasses were buried by NPS after necropsies were completed (Fig. 8). Blood samples collected on Saturday were taken to Sentara Laboratory in Norfolk, VA.



Fig. 8. Whales and stranding response team aligned near Ramp 2 on Monday, 17 Jan 2005, for the final necropsies; remaining carcasses were towed to this site. Vehicles were arranged to serve as wind blocks. After necropsy, carcasses were buried. Photos by the Cetacean and Sea Turtle Team, NMFS SEFSC at NOAA Beaufort Lab.

Teams broke at dusk to wash equipment and reconvene to debrief. On Sunday evening, another all-hands meeting was held to review the day and plan for necropsies on Monday. There were some changes in personnel as a number of individuals had to leave and others arrived to assist on Monday.

Also on Sunday, at 0800 hrs EST, we received a page about two additional live whales on the beach just north of Cape Hatteras. At 0915 hrs EST, Karen Sayles and Matt Kelcourse, DVM and a stranding network volunteer, called to say that these were dwarf sperm whales and that both died shortly before they arrived on site. Both animals were necropsied immediately. In addition, on Sunday a second team from VAQS went to Corolla, NC, to transport the minke whale to Virginia Beach for necropsy.

On Monday, 17 Jan 2005, the adverse weather conditions continued. The GPS location of the remaining 14 pilot whale carcasses was recorded then the carcasses were moved by NPS front-end loader to a high beach at Ramp 2 (Fig. 8). Consolidating the carcasses was a more efficient way to use staff, eliminated the possibility of carcasses washing out, and allowed us to use the vehicles as wind blocks. All of these carcasses were now more than 24 hours post-mortem and many were thought to no longer be in adequate condition for extensive histopathological analysis. On degrading carcasses, sampling was curtailed to gross examinations, limited histology, genetics and life history. Thus, the necropsies were completed faster than anticipated, with the last necropsy ending in mid-afternoon. The NPS buried the carcasses. Responders began to depart in mid-afternoon. Whale heads remaining on site were moved to the NPS maintenance yard and ear bones (tympanic bullae) were removed from two. The final crew left at dusk after cleaning gear at the NPS maintenance yard. Also on Monday, the minke whale was necropsied at the VAQS stranding center.

Epidemiology

A. Numerical and Spatial Overview of UMESE0501Sp

UMESE0501Sp comprised 33 pilot whales, one minke whale, and two dwarf sperm whales. One of the dwarf sperm whales was lactating. Three days later, on 19 Jan 2005, a 197 cm dwarf sperm whale calf was found by NPS personnel on a barrier island (South Core Banks) 48 km (straight line distance) southwest of the beached lactating female (Fig. 5). Given that the female was lactating and the calf was very young, as well as the low stranding rate of dwarf sperm whales in North Carolina, we speculate that these two animals were a cow/calf pair. Future genetic analysis may change that interpretation but the calf will be included in the description here. Few biological samples and no histopathology samples were collected from the calf because its condition (late Code 3) was too degraded when found.

The 36 whales that stranded on 15-16 Jan 2006 were distributed from northern North Carolina to Cape Hatteras, NC, (Table 5, Fig. 5) as follows:

- approximately 111 km straight line distance following the coast from the minke whale to the dwarf sperm whales;
- 43 km from the minke whale to the mid-point of the pilot whale strandings;

- 10.3 km from the northernmost pilot whale in south of Nags Head to the southernmost pilot whale at Oregon Inlet;
- 67 km from the midpoint of the pilot whales to the dwarf sperm whales; and
- 1.3 km between the two dwarf sperm whales.

In addition, as noted above, the dwarf sperm whale calf reported on 19 Jan 2005 was 48 km southwest of the lactating female.

Using length and reproductive data to assign age classes (Table 6), the UMESE0501SP strandings included all age classes, from calf to adult (Table 7). Growth curves are not available for short-finned pilot whales from the western North Atlantic or for dwarf sperm whales so predicted lengths-at-age do not exist. An approximation of the relative age classes of the pilot whales can be estimated from data, including fetal length, available from short-finned pilot whales that have stranded along the Atlantic coast and Florida Keys (NOAA National Marine Mammal Health and Stranding Response Database and Smithsonian Cetacean Distributional Database). Length at birth for western North Atlantic pilot whales appears to be approximately 155 cm (AAH approximation) so the smallest pilot whales were young calves and one (156 cm) was nearly newborn.

Of the 31 pilot whales identified with an RT number, 16 were mature females; six of those were pregnant with fetuses ranging from 54-120 cm in length with one fetus length not recorded (Table 6). Lactation was not recorded for any of the females; we cannot determine from the field notes whether females were checked for lactation and they were not lactating so nothing was recorded or if most females were not checked for lactation. Examination of mammary glands was noted in only three specimens: one was not lactating and the two others exhibited a green exudate not described as milk. We do not know how many females were lactating. Of the six male pilot whales, only one was an adult. As noted earlier, the dwarf sperm whales stranding on 16 Jan 2005 were adults, and the female was lactating, while the one found on 19 Jan 2005 was a calf. The minke was likely within weeks or months of birth and, thus, still a dependent calf.

B. Data and Sample Collection

Thirty-one of the 33 pilot whales initially reported as stranded were individually identified (Table 5); the other two presumably washed out during the high tide that forced responders off the beach at mid-day on 15 Jan 2005. Of the 31 identified pilot whales, two washed out before any samples or data were collected and two washed out after only blood and ocular fluid were collected. For the remaining 27 carcasses, despite the cold, blustery weather on 16-17 Jan 2005, a large amount of data and samples were collected (Appendix II, III). Data sheets on Level A, human interaction, morphometrics, sample checklist for histology, sample checklist for analysis other than histology, and necropsy notes were completed to the extent possible. Sample collection was variable among animals, from extensive on 16 Jan, when many of the carcasses were only about 24 hours post-mortem, to minimal on 17 Jan when all of the remaining carcasses were more than 24 hours post-mortem. The dwarf sperm whales were necropsied within hours of death; the samples from those animals were the least degraded. The minke whale was necropsied two days post-mortem. For all of the species, analyses completed included clinical pathology, histopathology, microbiology, serology, parasitology, and genetics (Appendix IV, V).

Table 5. Each whale involved in UMESE0501Sp that received a Field ID number also received a NC stranding catalog number. Associated data were collected when possible. For carcasses moved before a GPS latitude and longitude were taken, the latitude and longitude are approximate (noted with *). Strand dates are all 2005. Carcasses that washed out were not examined (n/e) and not necropsied (n/a) (RT89 and 100 washed out before any data or samples were collected, RT21 and 101 washed out after blood and ocular fluid was collected). Lesions potentially contributed to cause of the stranding for some animals; ** indicates cases with partial samples. For RT63 and 74, so few samples were collected that it could not be determined (CBD) whether lesions contributed to the stranding. RT numbers are pilot whales, CTH is the minke whale, and KMS numbers are the dwarf sperm whales. The dwarf sperm whale calf (CALO0504) was reported on 19 Jan 05.

Field ID	NC Catalog Numer	Sex	Length (cm)	Fishery Interaction	Latitude	Longitude	Strand Date	Necropsy Date	Lesions Contribute to / Cause Stranding or Post-Stranding
RT12	NC05-006	Female	210	No	35.83 *	-75.56	15-Jan-05	16-Jan-05	N
RT13	NC05-007	Female	297	No	35.78	-75.54	15-Jan-05	17-Jan-05	N
RT19	NC05-008	Female	358	Healed	35.79	-75.54	15-Jan-05	17-Jan-05	N
RT20	NC05-009	Male	251	Healed	35.82	-75.55	15-Jan-05	17-Jan-05	N**
RT21	NC05-043	n/e	n/e	n/e	35.87 *	-75.55	15-Jan-05	n/a	n/e
RT22	NC05-010	Female	359.5	Healed	35.82	-75.55	15-Jan-05	17-Jan-05	N**
RT24	NC05-011	Female	330	Healed	35.78	-75.53	15-Jan-05	15-Jan-05	Y**
RT47	NC05-012	Male	177	Healed	35.83 *	-75.56	15-Jan-05	16-Jan-05	N
RT48	NC05-013	Female	352	No	35.83	-75.56	15-Jan-05	16-Jan-05	N
RT49	NC05-014	Female	375	No	35.83	-75.56	15-Jan-05	16-Jan-05	N
RT50	NC05-015	Female	380	No	35.83	-75.56	15-Jan-05	16-Jan-05	Y
RT54	NC05-016	Female	275	No	35.82 *	-75.55	15-Jan-05	16-Jan-05	N
RT57	NC05-017	Male	506	Healed	35.82	-75.55	15-Jan-05	17-Jan-05	N**
RT59	NC05-018	Female	383	No	35.83	-75.56	15-Jan-05	16-Jan-05	Y
RT63	NC05-019	Female	359	No	35.80	-75.54	15-Jan-05	17-Jan-05	CBD**
RT66	NC05-020	Female	350	No	35.81	-75.54	15-Jan-05	17-Jan-05	N
RT67	NC05-021	Female	212	No	35.79	-75.54	15-Jan-05	17-Jan-05	N**
RT68	NC05-022	Female	334	No	35.81 *	-75.55	15-Jan-05	16-Jan-05	N
RT69	NC05-023	Male	330	Healed	35.81	-75.55	15-Jan-05	17-Jan-05	N**
RT71	NC05-024	Male	156	No	35.78	-75.53	15-Jan-05	17-Jan-05	N**
RT72	NC05-025	Male	269	No	35.82	-75.55	15-Jan-05	17-Jan-05	N**
RT74	NC05-026	Female	349	No	35.82	-75.55	15-Jan-05	17-Jan-05	CBD**
RT89	NC05-044	n/e	n/e	n/e	35.81 *	-75.55	15-Jan-05	n/a	n/e
RT100	NC05-045	n/e	n/e	n/e	35.78 *	-75.53	15-Jan-05	n/a	n/e
RT101	NC05-046	n/e	n/e	n/e	35.79	-75.54	15-Jan-05	n/a	n/e
RT102	NC05-027	Female	387	No	35.79	-75.54	15-Jan-05	17-Jan-05	N**
RT103	NC05-028	Female	349	No	35.82 *	-75.55	15-Jan-05	16-Jan-05	Y
RT104	NC05-029	Female	267	No	35.84	-75.56	15-Jan-05	16-Jan-05	N
RT105	NC05-030	Female	375	Healed	35.84	-75.56	15-Jan-05	16-Jan-05	Y
RT106	NC05-031	Female	364	No	35.84	-75.56	15-Jan-05	16-Jan-05	N
RT107	NC05-032	Female	357	Healed	35.84	-75.56	15-Jan-05	16-Jan-05	N
CTH001	NC05-035	Male	284	No	36.21	-75.75	15-Jan-05	17-Jan-05	Y
KMS379	NC05-033	Male	242	No	35.22	-75.53	16-Jan-05	16-Jan-05	Y
KMS380	NC05-034	Female	240	No	35.23	-75.56	16-Jan-05	16-Jan-05	N
CALO0504	NC05-038	Female	197	No	34.81	-76.36	19-Jan-05	20-Jan-05	n/e

Table 6. Maturation and reproductive condition of the whales involved in UMESE0501Sp. Determination of maturation for females was by presence of corpora on the ovaries or, if the ovaries were not examined, on pregnancy. For males, maturation was assumed from testis size. All known sexually mature animals are listed as Adult age class. For animals not sexually mature or when gonads were not examined and pregnancy was unknown, age class was estimated from length. n/e = not examined. n/r = not recorded.

Field ID	Sex	Length (cm)	Mat-ure	Age Class	Estimated Age Class	Preg-nant	Fetal Length (cm)	Lacta-ting	Corpora Present	Corpus Luteum Present
RT12	Female	210			Calf	No		n/r	n/e	
RT67	Female	212	N		Calf	No		n/r	N	
RT104	Female	267	N		Juvenile	No		n/r	N	
RT54	Female	275	N		Juvenile	No		N	N	
RT13	Female	297	N		Subadult	No		n/r	N	
RT24	Female	330	Y	Adult		Yes	54	n/r	Y	Y
RT68	Female	334	Y	Adult		No		n/r	Y	
RT103	Female	349	Y	Adult		No		n/r	Y	
RT74	Female	349	Y	Adult		No		n/r	Y	
RT66	Female	350	Y	Adult		Yes	105	n/r	Y	Y
RT48	Female	352	Y	Adult		Yes	120	n/r	Y	Y
RT107	Female	357	Y	Adult		No		N	Y	
RT19	Female	358	Y	Adult		No		Y	Y	
RT63	Female	359	Y	Adult		No		N	Y	
RT22	Female	359			Adult	No		n/r	n/e	
RT106	Female	364	Y	Adult		Yes	112	n/r	n/e	Y
RT105	Female	375	Y	Adult		No		n/r	Y	
RT49	Female	375	Y	Adult		Yes	115	N	Y	Y
RT50	Female	380	Y	Adult		Yes	n/r	N	Y	Y
RT59	Female	383	Y	Adult		No		N	Y	
RT102	Female	387			Adult	No		n/r	n/e	
RT71	Male	156			Calf	--		--	--	
RT47	Male	177			Calf	--		--	--	
RT20	Male	251			Juvenile	--		--	--	
RT72	Male	269			Juvenile	--		--	--	
RT69	Male	330			Juvenile	--		--	--	
RT57	Male	506		Adult		--		--	--	
RT100	CBD	n/e			n/e	n/e		n/e	n/e	
RT101	CBD	n/e			n/e	n/e		n/e	n/e	
RT21	CBD	n/e			n/e	n/e		n/e	n/e	
RT89	CBD	n/e			n/e	n/e		n/e	n/e	
CTH001	Male	284	N		Calf	--		--	n/e	
KMS380	Female	240	Y	Adult		No		Y	Y	
KMS379	Male	242	Y	Adult		--		--	--	
CALO 0504	Female	197	N		Calf	No		n/e	n/e	

Stomachs from 26 pilot whales and both of the adult dwarf sperm whales were collected intact, frozen, thawed, and then examined at the NOAA lab in Beaufort. Contents were collected from another. The minke whale stomach was collected and examined during the necropsy at VAQS. Only two sets of ears were collected from the pilot whales in the field (on 17 Jan 2005). By the time of collection, the carcasses were Condition Code 3. The remainder of the pilot whale heads were frozen at various times post mortem: four after one day, 11 after two days, and 12 after five days. The dwarf sperm whale and minke whale heads were frozen following necropsy. CT (computerized tomography) scans were conducted on two pilot whales and the two adult dwarf sperm whales at NCSU (Appendix IV). All had been frozen.

Table 7. Suggested age-class distribution of whales included in UMESE0501Sp. The dwarf sperm whale calf stranded on 19 Jan 2005.

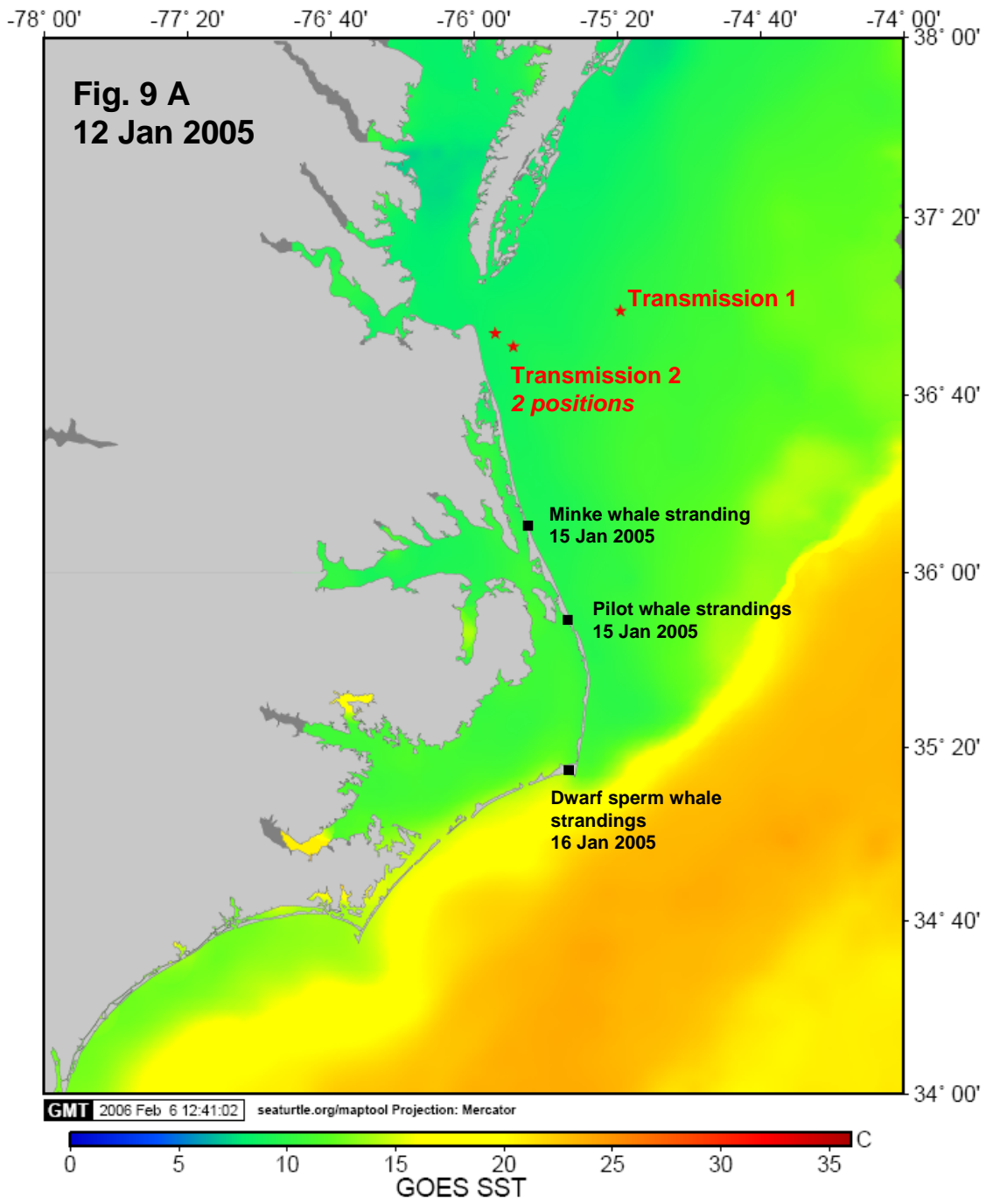
Species	Age class	Female	Male	Unknown
Pilot whales	Calf	2	2	
	Juvenile	2		
	Sub-adult	1	3	
	Adult	16	1	
	Unknown			6
Minke whale	Calf		1	
Dwarf sperm whales	Calf	1		
	Adult	1	1	

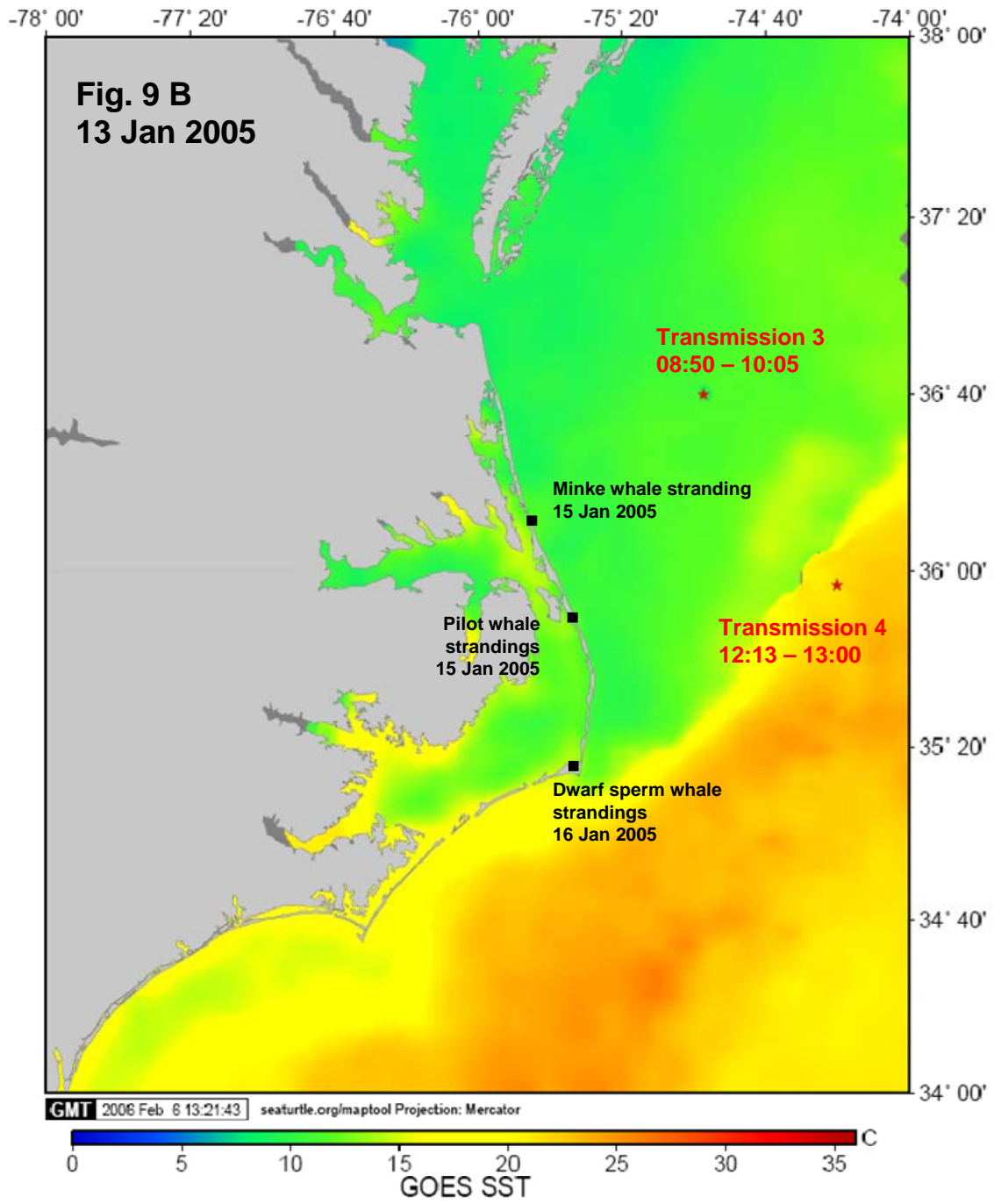
C. Environmental Conditions

The oceanography of shelf waters near Cape Hatteras is complex and has been well studied (see, for example, Flagg *et al.* 2002, Pietrafesa *et al.* 1994). Typically during winter in the nearshore and shelf waters from Cape Hatteras to northern North Carolina, the area encompassing the strandings on 15-16 Jan 2005, there is a strong thermal gradient caused by the proximity of the Gulf Stream front to cooler shelf waters originating from northern coastal water masses (*e.g.*, Fig. 9). Warm-water eddies are common and bring warm Gulf Stream water towards shore. Otherwise, continental shelf waters are generally isothermal due to strong wind mixing and convective mixing due to surface cooling (Pietrafesa *et al.* 1985, Churchill and Cornillon 1991). Frequent shifts in wind direction result in frequent nearshore wind-forced changes in upwelling-favorable (northward winds) and downwelling-favorable (southward winds) conditions (Pietrafesa *et al.* 1985, Lentz *et al.* 1999, Rennie *et al.* 1999). The continental shelf from Cape Hatteras to the Chesapeake Bay is closer to shore off Cape Hatteras than any other location along the U.S. Atlantic coast north of southern Florida. The shelf slopes gently to the break (Fig. 10).

The pilot whales were first seen on the beach at approximately sunrise (0713 hrs EST), two hours after low tide (Table 8). At the time, 15 whales were up on the beach suggesting that they came ashore several hours earlier when the tide was high or nearly high. The remaining whales may have stranded simultaneously or later, as the tide was waning. The previous high tide occurred at 2329 hrs EST on 14 Jan. Mean tidal range at Oregon Inlet is 2.0 ft (61 cm), mean tide level is 1.1 ft (33.5 cm) and the spring tide range is 2.4 ft (73.2 cm). On 14 Jan the tide height at high tide was 2.0 ft (61 cm).

Environmental conditions the week of the strandings (9-17 Jan 2005) were variable (Table 9), with the most notable atmospheric changes in wind direction and speed (Fig. 11). There was an abrupt shift in wind direction from northeasterly to southerly from 11 Jan to 12 Jan 2005. During the two days prior to the pilot whale stranding, winds were from the south and relatively light, on average, with moderate gusts. On 14-15 Jan 2005, winds shifted back to ENE and NNE and increased in average and gust speeds. The prevailing winds remained high and from the north and east or north and west throughout the time frame of the strandings. These changes in wind direction and speed would have caused a change from downwelling-favorable (southward) to upwelling-favorable (northward) and back to downwelling-favorable conditions within those





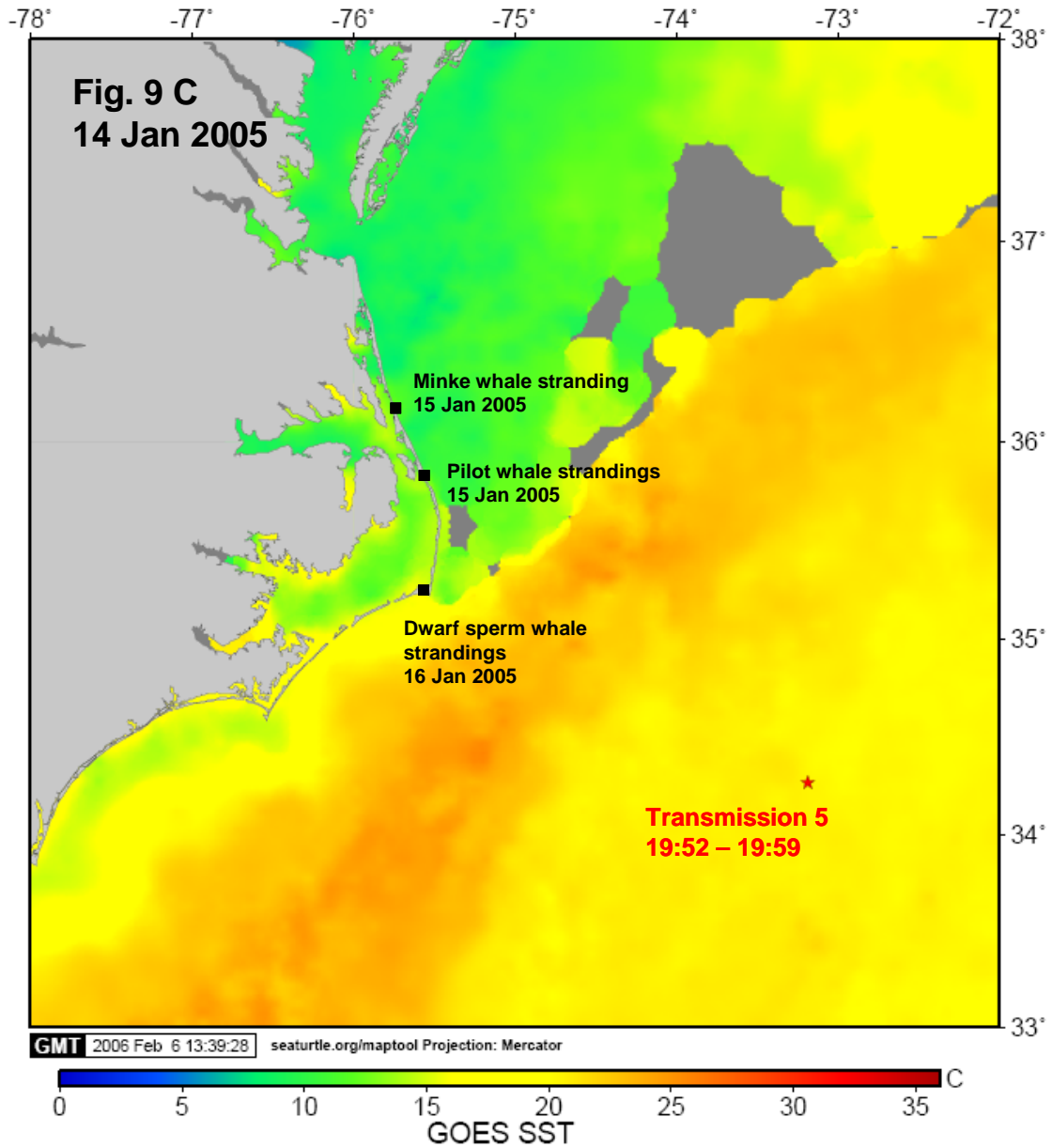


Fig. 9. Location of the U.S. Navy vessels (stars) during sonar operations in the days preceding the strandings and the location of strandings on 15-16 Jan 2005 (squares). Sea surface temperatures (SST) were from the dates of the transmission. The Gulf Stream is represented by the warm (red) water mass. Gray areas over the ocean represent cloud cover, preventing remote sensing of SST. Times are eastern standard time (EST) (local) time. (A) 12 Jan 2006, (B) 13 Jan 2006, and (C) 14 Jan 2006. Duration of transmissions at each site is given as the time each day the transmission pulses occurred. On 12 Jan, the duration of transmissions was not reported to NMFS.

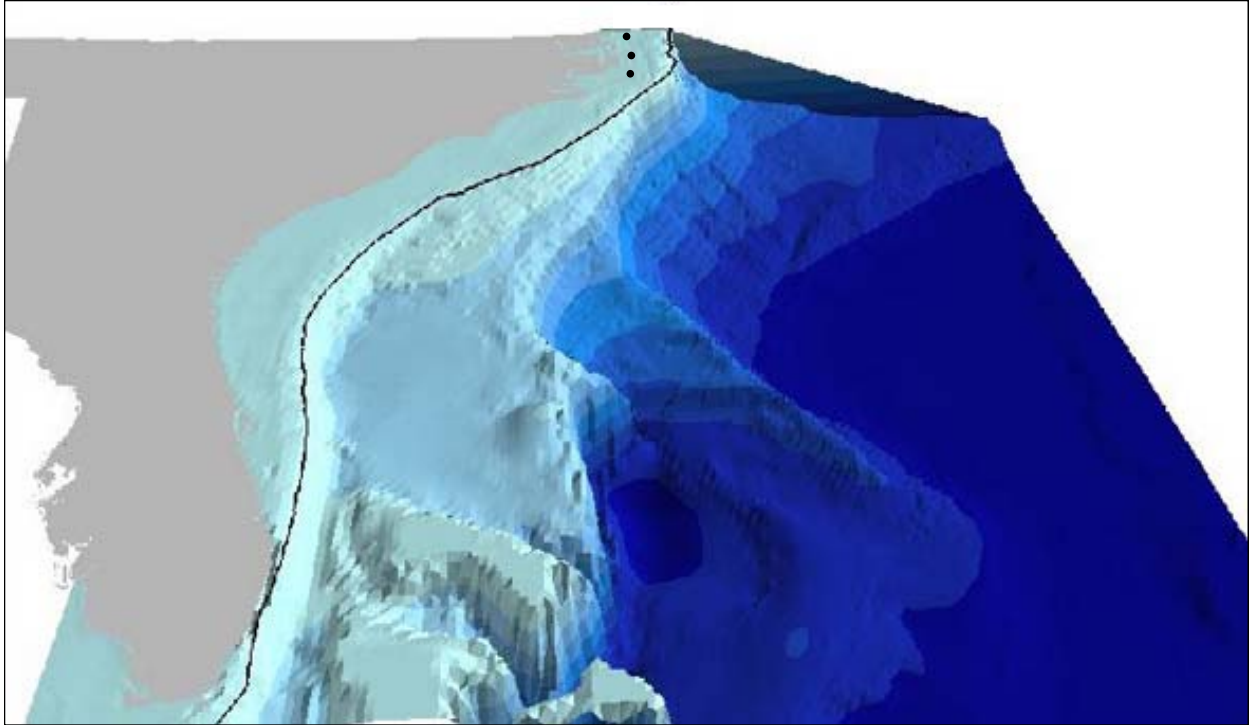


Fig. 10. Representation of ocean topography off the southeast portion of the United States. The location of the UMESE0501Sp strandings are marked by black circles (northernmost – minke whale, middle – pilot whales, southernmost – dwarf sperm whales at Cape Hatteras). Image by Phil Weinbach, courtesy of the NOAA Ocean Explorer program (<http://oceanexplorer.noaa.gov/explorations/03bump/logs/aug12/media/multibeam.htm>).

five days would have caused a change from downwelling-favorable (southward) to upwelling-favorable (northward) and back to downwelling-favorable conditions within those five days. Mass strandings of short-finned pilot whales and other species on the east coast of Florida occurred within a week of a change in wind direction (Walker *et al.* 2005). That change was always from upwelling favorable to downwelling favorable conditions (Walker *et al.* 2005). They also found that this shift occurred primarily 3-4 days prior to the mass strandings. They suggested that cetaceans tracking frontal convergences, such as might occur with offshore species (Björge 2001), become confused when that front disappears, contributing to the stranding. A mass stranding of long-finned pilot whales occurred on the mainland-facing side of Sable Island, Canada, on 23 Dec 1976 (Geraci and St. Aubin 1977). The tide was near peak high tide. They note that “weather conditions for the week were not unseasonable”; historic average wind direction during December on Sable Island is westerly (www.wunderground.com). On 17 and 21 Dec, the wind changed to southerly (“between W and SE”). Given that the beach on which the whales stranded faces approximately NNW, the average wind direction (west) would have produced downwelling-favorable conditions. Thus, the southerly wind would have created upwelling-favorable conditions twice, at six and three days, before the stranding. The change in conditions for 15 Jan 2005 mass stranding of pilot whales in North Carolina are consistent with the Walker *et al.* (2005) results except that the shift occurred within a day of UMESE0501Sp, a time frame seen in only one of 15 events reported by Walker *et al.* (2005). Nonetheless, there is no history of mass strandings of any magnitude despite a long time series of data and frequent changes in upwelling conditions in that area.

Table 8. Tide times and heights at Oregon Inlet the week before and weekend during UMESE0501Sp. The pilot whales and minke whale were found on the morning of 15 Jan 2005; the dwarf sperm whales were found on the morning of 16 Jan 2005. Mean tidal range is 2.0 ft, spring range is 2.4 ft, and the mean tide level is 1.1 ft. Heights are referenced to Mean Lower Low Water (MLLW).

Jan	Day	Time	Height (ft)		Time	Height (ft)		Time	Height (ft)	Time	Height (ft)
9	Sun	06:28 am	2.6	H	01:21 pm	-0.1	L	06:53 pm	1.6	H	--
10	Mon	12:45 am	-0.1	L	07:21 am	2.6	H	02:15 pm	-0.1	L	07:47 pm 1.8 H
11	Tue	01:45 am	-0.1	L	08:11 am	2.6	H	03:06 pm	-0.1	L	08:42 pm 1.8 H
12	Wed	02:44 am	-0.1	L	09:00 am	2.6	H	03:55 pm	-0.1	L	09:37 pm 1.8 H
13	Thu	03:45 am	-0.1	L	09:50 am	2.4	H	04:42 pm	-0.1	L	10:32 pm 2.0 H
14	Fri	04:47 am	0.0	L	10:40 am	2.0	H	05:28 pm	-0.1	L	11:29 pm 2.0 H
15	Sat	05:50 am	0.0	L	11:33 am	1.8	H	06:16 pm	-0.1	L	--
16	Sun	12:27 am	2.0	H	06:54 am	0.0	L	12:31 pm	1.6	H	07:05 pm 0.0 L
17	Mon	01:27 am	2.0	H	07:57 am	0.1	L	01:38 pm	1.4	H	07:57 pm 0.0 L

Walker *et al.* (2005) also found that the Florida mass strandings occurred significantly more often on beaches with a gentle slope and sudden drop in depth close to shore. Brabyn and McLean (1992) found that 100 mass strandings (defined as >4 whales) of 11 species on mainland New Zealand occurred primarily in four locations with similar coastal configurations. As with the Walker *et al.* (2005) findings, the New Zealand strandings were associated with gently sloping beaches and deep water nearshore. They were also associated with some form of protrusion from the coastline, such as a peninsula or spit or harbor entrance. Brabyn and McLean (1992) reviewed the literature with regard to characteristics of stranding sites for mass strandings around the world and found that many occurred in areas with spits or peninsulas or in shallow bays. In the New Zealand mass strandings, they also found that the most frequent stranding beaches were less indented (*i.e.*, shallow bays) while there were no significant effects due to water depth or sediment type. There was a tendency for strandings to occur where surface currents move toward the beach. They conclude that coastal morphology is an important factor in cetacean mass strandings, albeit only a partial explanation for the proximate causes of the stranding. With regard to UMESE0501Sp, the pilot whales stranded where the shelf is still relatively narrow, the beach is gently sloping, an inlet was present so there was a protuberance, and there was no deep embayment. Similar characteristics apply to the location, very close to Cape Hatteras, where the dwarf sperm whales stranded.

McFee (1990) reviewed factors that might have contributed to 87 mass strandings of long-finned pilot whales on Cape Cod, Massachusetts, from 1620 to 1990. Similar to the New Zealand stranding pattern, the majority of strandings occurred in specific sites. In Cape Cod, the two sites have been Wellfleet and Eastham. For strandings for which weather conditions were considered (n=8), the events were associated with greater than average tides and strong winds but from different directions during different events. The stranding sites around Cape Cod had extensive mud flats and gently sloping, sandy beaches. The bathymetry of Wellfleet Harbor is complex and includes abrupt changes in water depth in some areas. Still, McFee (1990) was unable to find commonality to explain the mass strandings with the data available at that time. Evans *et al.* (2005) found a correlation between single and mass strandings in southeastern Australia and an 11-13 yr periodicity in westerly and southerly winds associated with nutrient-rich water being driven closer to shore.

Table 9. Weather conditions the week before and weekend of UMESE0501Sp. The pilot whales and minke whale were found on the morning of 15 Jan 2005, the dwarf sperm whales were on the morning of 16 Jan. 2005.

Date		Temperature (°F)			Visibility (mi)			Wind Speed (mph)			Wind	Precip.	Events
Day	Jan	high	avg	low	high	avg	low	high	avg	gust	Direction	(inches)	
Sun	9	53	48	42	10	10	5	17	16	24	NNE	0	
Mon	10	60	50	41	10	7	0	10	2	-	W	0	Fog
Tue	11	55	52	48	10	8	5	16	6	18	ENE	0	
Wed	12	68	60	53	10	5	1	16	2	21	S	0	
Thu	13	71	66	60	10	7	2	18	9	23	S	0	Rain
Fri	14	68	56	44	10	7	1	32	13	44	ENE	0.69	Rain
Sat	15	48	47	46	10	10	10	25	22	33	NNE	0	
Sun	16	51	48	44	10	8	4	24	22	36	N	0.03	Rain
Mon	17	42	36	30	10	10	10	17	13	26	NNW	0	Rain

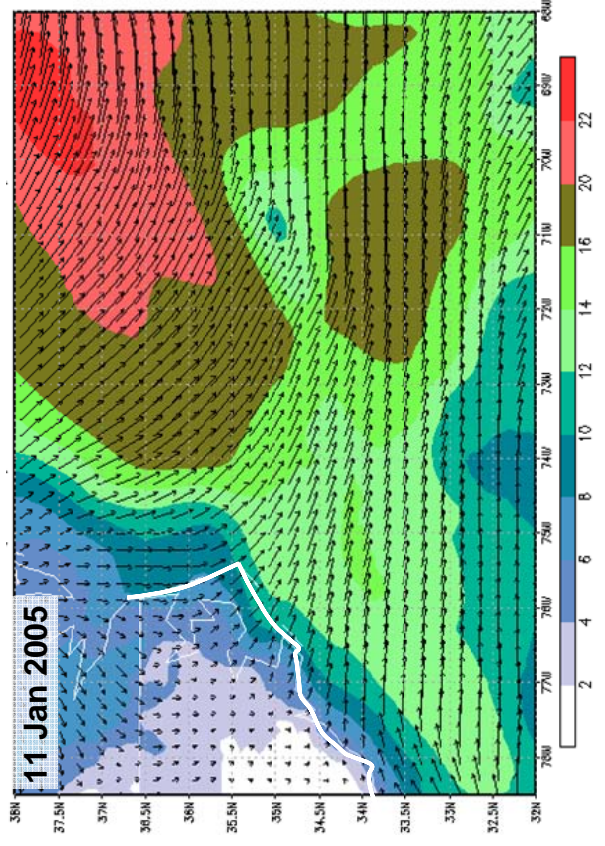
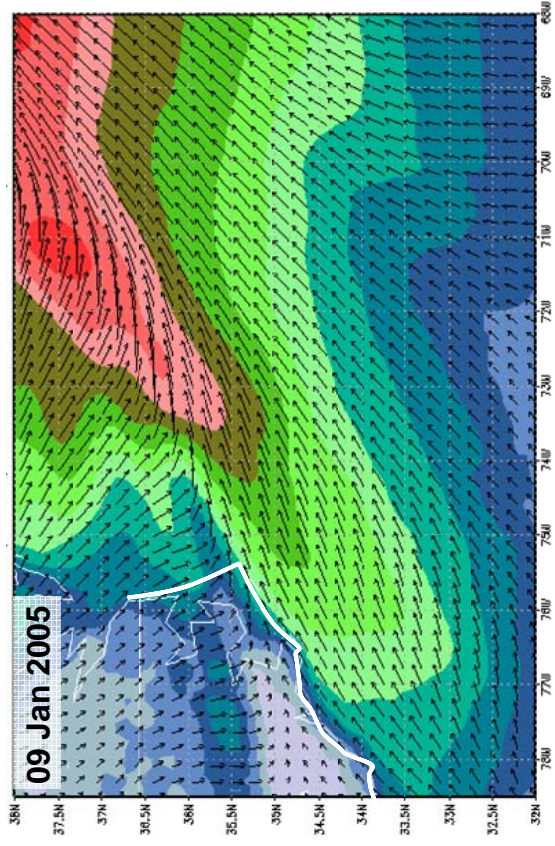
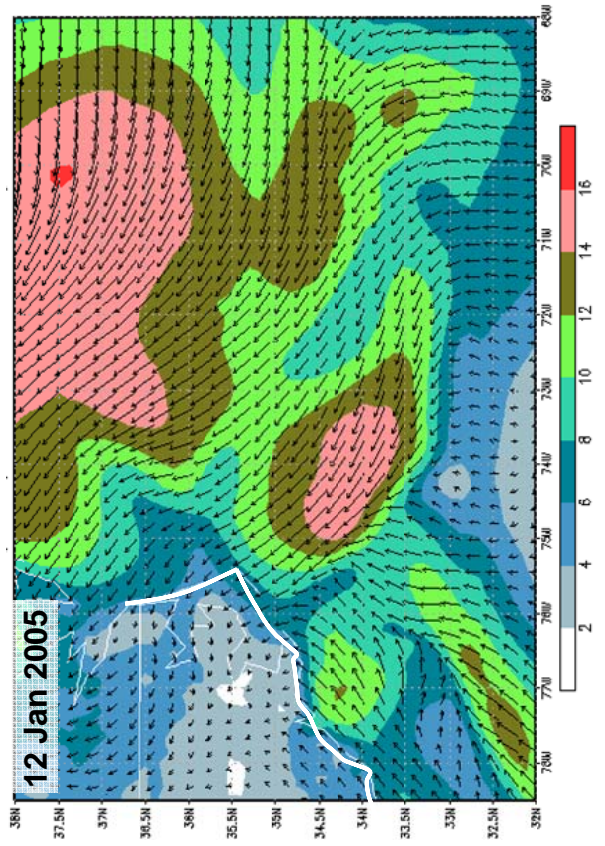
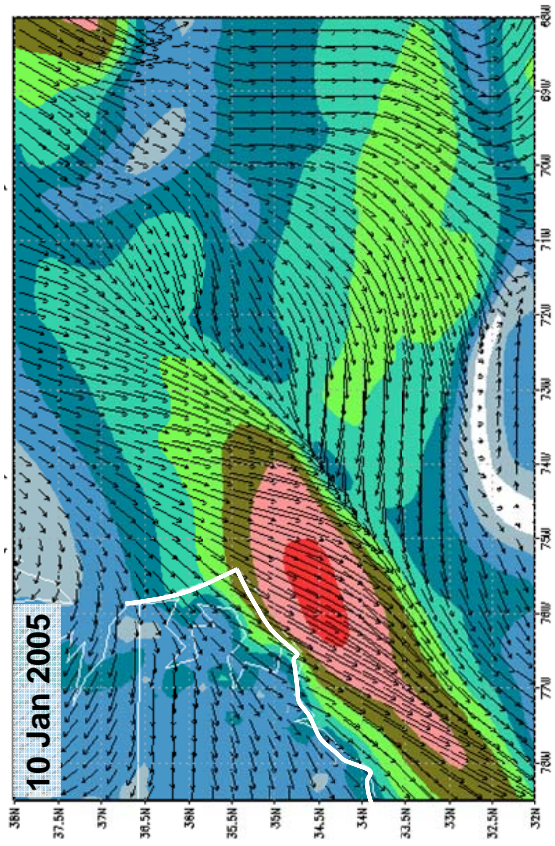
Oregon Inlet, where the pilot whales stranded on 15 Jan 2005, is not far from where the Gulf Stream typically moves away from the coast of North Carolina (Fig. 9). Because they are associated with the Gulf Stream off North Carolina and warm-water eddies are common, a possible explanation for the stranding is that they came close to shore in an eddie. However, no warm-water eddies were visible nearshore between Cape Hatteras and Oregon Inlet from AVHRR sea-surface temperature images the week of UMESE0501Sp (Fig. 9). Dwarf sperm whales are also associated with warm water. Warm water from the Gulf Stream abutted the coast between Cape Hatteras and Cape Lookout in the days prior to the stranding; all of the *Kogia* stranded within this area (Fig. 9).

There were no harmful algal blooms reported along the mid-Atlantic coast south of the Chesapeake Bay during the winter of 2004-2005 (P. Tester, pers. comm.). The only biotoxin-producing species that occurs in this region is *Karenia breve*, the Florida red-tide dinoflagellate. *K. breve* is transported up the Atlantic coast via the Gulf Stream from the Florida coast but is rare north of Cape Hatteras (Tester and Steidinger 1997). There also were no blooms detected along the Atlantic coast of Florida from late December 2004 through January 2005 and only low levels of bloom activity were observed north of the Florida Keys and along the central Gulf coast of Florida (http://coastwatch.noaa.gov/hab/bulletins_ns.htm and W. Litaker, pers. comm.).

D. Summary of Known Active Mid-Frequency Sonar Transmissions in the Vicinity of Oregon Inlet, 12-17 January 2005

As standard procedure following a marine mammal mass stranding, NMFS sought information on, among many things, the presence of high-intensity acoustic sources in reasonable temporal and spatial proximity to the strandings. The occurrence of detonations associated with harbor blasting or other coastal development, military live fire exercises, and active sonar transmissions was investigated as follows.

Information was requested regarding operations ("official" training activities as well as "other" use) involving high-power sources from 12-17 Jan 2005, a period from three days prior to the first stranding on 15 Jan 2005 through the duration of the response on 17 Jan 2005. We estimated the possible transit speed of the species in question (based on evidence from several cetacean species indicating sustained swimming speeds on the order of 1.8-3.1 m/s (Costa and



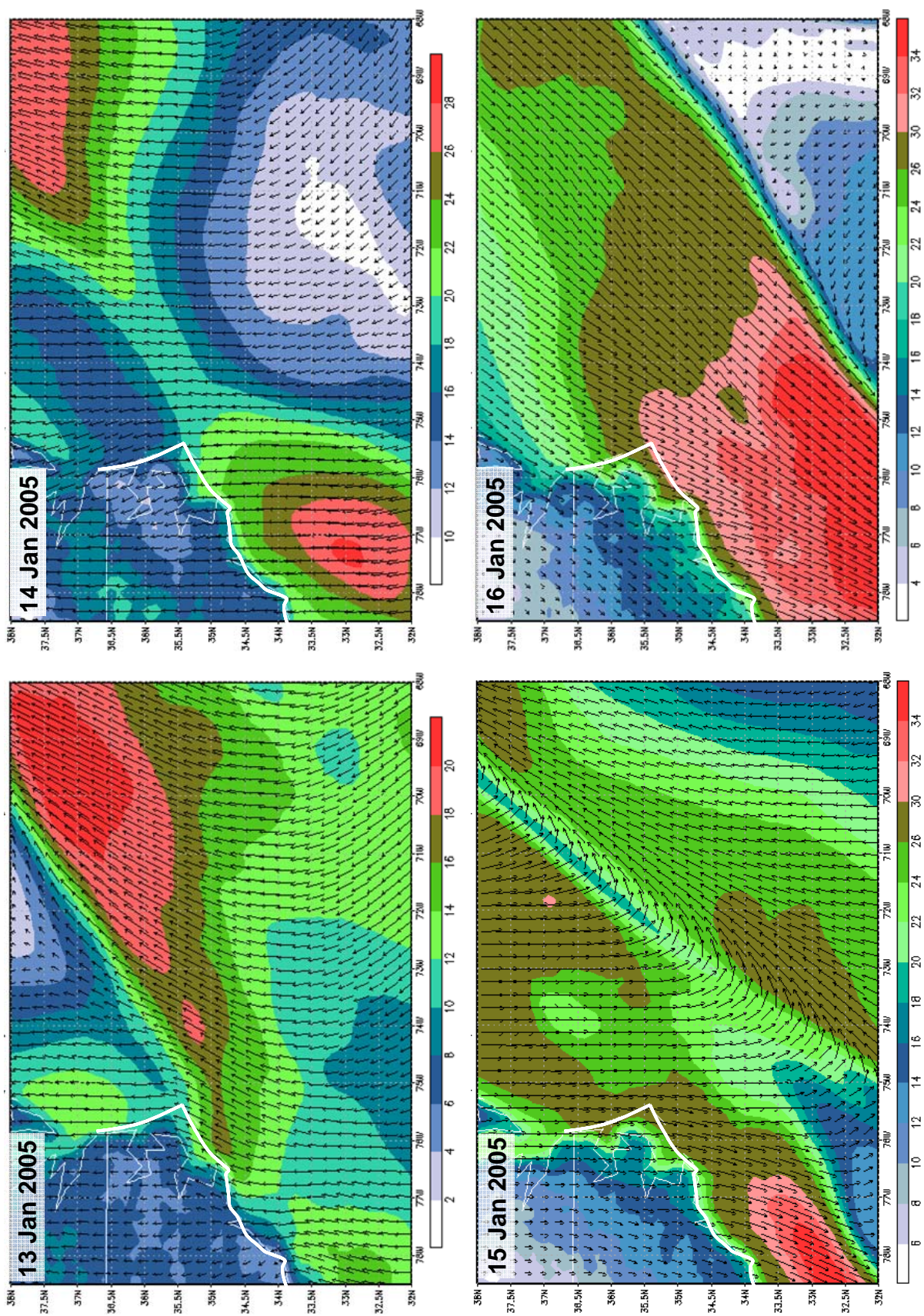


Fig. 11. Wind speed and direction from 9-16 Jan 2005, the week during which UMASE0501SP occurred. The white line approximates the North Carolina coast. Note that the scales are not identical among plots. Wind data are from NOAA's National Weather Service (NWS) NCDC NOMADS site (see Rutledge *et al.* 2006) and plots were made by NWS Research Scientific Services Division, Eastern Regional Headquarters.

Williams 2000)) to be up to ~90-100 km/day. For the above time period, this calculation results in a ~350-400 km radius area to evaluate for the presence of powerful acoustic sources (375 km (200 nautical miles) was the actual radius over which information was requested). The 375 km radius was centered on Oregon Inlet where the vast majority of animals stranded. This radius was used to restrict the investigation to a biologically reasonable spatial scale, but it is acknowledged to be a somewhat conservative (wide) range.

According to information received by NMFS from the U. S. Army Corps of Engineers and the U.S. Navy, there were no known detonations associated with coastal development, harbor or channel deepening, or live fire training in the area of consideration from 12-17 Jan 2005. However, routine tactical mid-frequency sonar operations from individual U.S. Navy surface vessels were reported to have occurred over relatively short durations and small spatial scales within the area and time period investigated (Fig. 9). Information provided to NMFS by the U.S. Navy (Fleet Forces Command) indicated the following: (1) No active military sonar occurred within 93 km (50 nm) of Oregon Inlet on 15-16 Jan 2005 or 4 days prior; (2) Routine unit level training occurred between 93 and 185 km (50-100 nm) from Oregon Inlet, along the Virginia and North Carolina coasts (detailed information about timing and duration of active sonar transmissions was provided and is given briefly below); and (3) Between 13-15 Jan 2005 the Kearsarge Expeditionary Strike Group (ESG) conducted a training exercise more than 445 km (240 nm) south of Oregon Inlet, with the closest point of ESG active sonar transmissions being 650 km (351 nm). Regarding known sonar transmissions (12-14 Jan 2005), individual surface vessels did deploy tactical mid-frequency active sonar (presumed to be nominal SQS-53C U. S. Navy systems) on a limited basis in the area of consideration. A single surface ship employed active sonar for some duration (exact value not reported to NMFS; transmissions reported to have ceased at 1800 hrs EST) on 12 Jan 2005 in very shallow water (< 20 m depth) to the north-northwest of Oregon Inlet at a range of 120-150 km (55-81 nm) (Fig. 9a). A second surface vessel transmitted mid-frequency sonar for 27 minutes on 12 Jan 2005 at a range of 161 km (87 nm). On 13 Jan 2005, the following active sonar transmissions occurred on or near the shelf break to the east and northeast of Oregon Inlet (Fig. 9b): (1) a single surface vessel transmitted active sonar during two brief intervals (1 and 35 min.) at a range of 100-109 km (54-59 nm) and (2) an additional vessel transmitted active sonar for 35 min. at a range of 161 km (87 nm). Active mid-frequency sonar was also transmitted by a single surface vessel for 7 minutes on 14 Jan 2005 at a range of 172 km (93 nm) to the south-southeast of Oregon Inlet (Fig. 9c). There were no active transmissions on 15-16 Jan 2005 in the area considered. It is important to note that the reported transmissions of individual surface vessels during the 12-14 Jan 2005 timeframe were all in the context of routine unit level training, equipment testing, and calibration. There were no reported anti-submarine warfare exercises over long durations of time or involving multiple vessels simultaneously active. These mid-frequency, tactical sonar activities are not atypical for the geographical area, which falls within the U.S. Navy Virginia Capes (VACAPES) operational area, nor are they atypical for the time of year.

Information provided to NMFS by the U. S. Navy indicates that all of the above transmissions were conducted in accordance with standard protective measures (*e.g.*, the use of lookouts trained in marine mammal recognition, stand-off ranges, and source level reduction if mammals are sighted). They further reported that no marine mammals were detected by those vessels reporting sonar use during the above periods and locations.

We conducted sound propagation modeling (using the Bellhop Gaussian beam/finite element ray-tracing model available at: www.hlsresearch.com/oalib) for each of the source locations presuming nominal source characteristics of the tactical, mid-frequency active sonar system SQS-53C. A custom acoustic propagation visualization program was used to visualize estimated sound fields surrounding active sources. This modeling procedure has certain limitations in estimating the actual acoustic fields produced by sonar transmissions on 12-14 Jan 2005. For instance, empirical *in situ* measurements of sound velocity profiles for the dates in question are not available; nominal monthly sound velocity profiles for explicit locations were used (from the Generalized Digital Environmental Model (GDEM), available at: <https://128.160.23.42/gdemv/gdemv.html>). Deviations in sound propagation conditions (*e.g.*, related to changing wind conditions on 14-15 Jan 2005) could have resulted in significantly different sound fields than those estimated. Additionally, the propagation visualization program used does not account for the known directionality of tactical sonar systems. Despite these limitations, the sound propagation analysis provides some useful information regarding approximate exposure conditions and, perhaps more importantly, the high degree of likely variability based on the location of active sonar transmissions.

Sound fields were modeled for three transmission positions: transmission #2 on 12 Jan 2005 (Fig. 12); transmission # 3 on 13 Jan 2005 (Fig. 13); and transmission #5 on 14 Jan 2005 (Fig. 14). In each figure a plan view of the estimated received levels surrounding the source at its estimated depth (3m) are shown. Additionally, two radials for each transmission location were selected and sound fields over a variety of depths and ranges depicted. The discontinuities in the received levels in range and depth in Figs. 12 and 13 are associated with the numerical approximations used by the propagation model which become particularly apparent in very shallow water environments; actual underwater sound fields show smoother transitions in received levels. As evident in Figs. 12-14, the estimated sound fields from identical transmissions in these three positions are highly variable in several regards. This is likely due to great differences in water depth and bathymetric features between the transmission sites as well as the presence of the Gulf Stream and the resulting strong lateral variations in water temperature at certain locations. These features result, particularly in shallower transmission locations, in sound fields that are significantly more complicated than would be expected in laterally homogeneous environments. An important observation from Fig. 14 (B and C) is the presence of a nominal surface duct (evidenced by the relatively high received level versus range near the surface) at the location of the 14 Jan 2005 active sonar transmission. Based on the monthly sound velocity profiles available in the GDEM database, surface thermal mixing is estimated to occur over the upper 50m or so of the water column, favoring relatively efficient propagation of sounds produced in this depth band. The active sonar transmissions of 14 Jan 2005 were produced from a surface vessel and thus within this zone, but the extent to which surface ducting conditions existed or approximated those predicted by the nominal sound velocity profiles are unknown (due to the absence of *in situ* measurements).

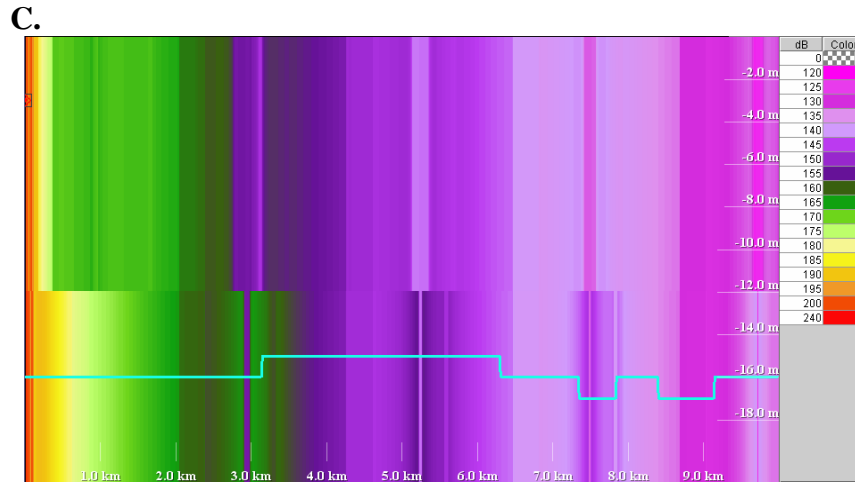
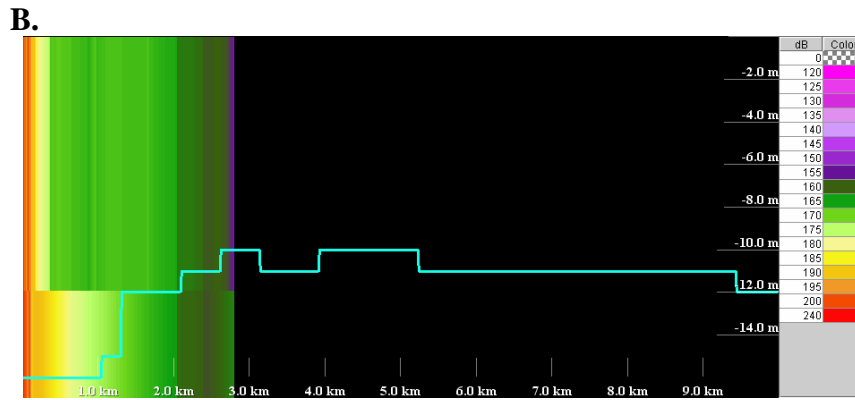
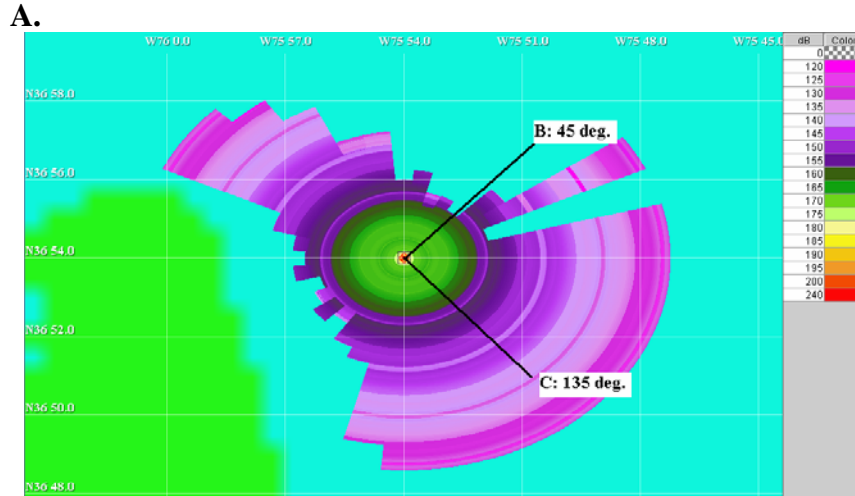


Figure 12. Modeled sound fields for a hypothetical (omni-directional) tactical mid-frequency sonar located at the position of transmission 2. Shaded colors indicate estimated received levels at various ranges. The light-blue lines with a stair-step appearance represent an approximation to the bathymetry. A plan view of the modeled sound field at the approximate depth of the sonar source (3m) is shown in A. Side views showing estimated received sound conditions over various depths and ranges for two bearings from the sound source are shown in B (45°) and C (145°).

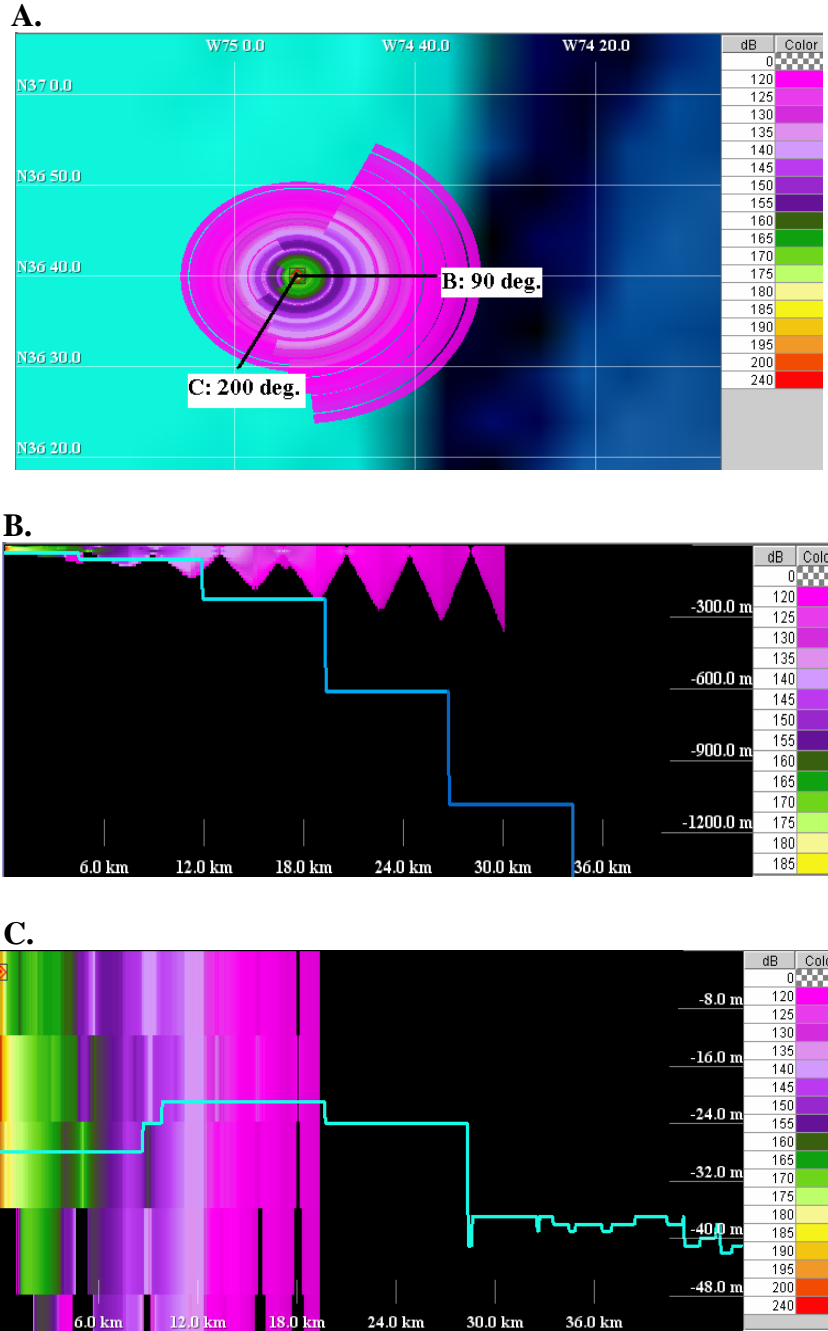


Figure 13. Modeled sound fields for a hypothetical (omni-directional) tactical mid-frequency sonar located at the position of transmission 3. A plan view of the modeled sound field at the approximate depth of the sonar source (3m) is shown in A. Side views showing estimated received sound conditions over various depths and ranges for two bearings from the sound source are shown in B (90°) and C (200°). Note the differences in depth and range scale from Fig. 12.


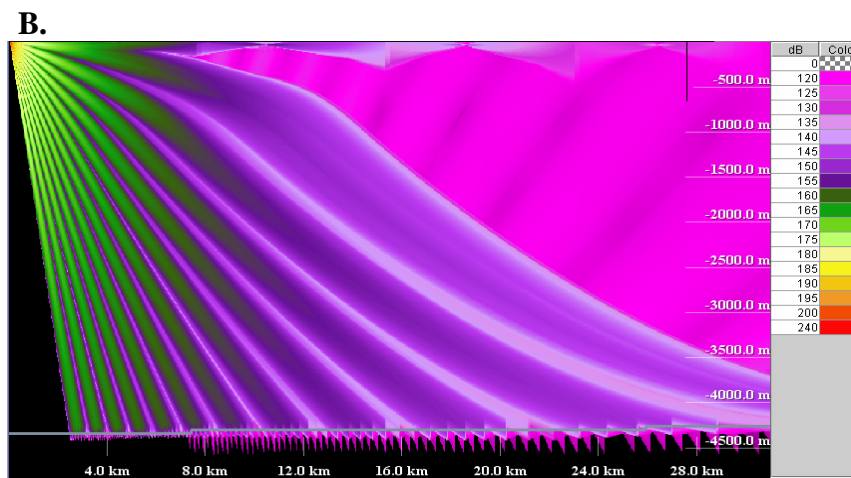
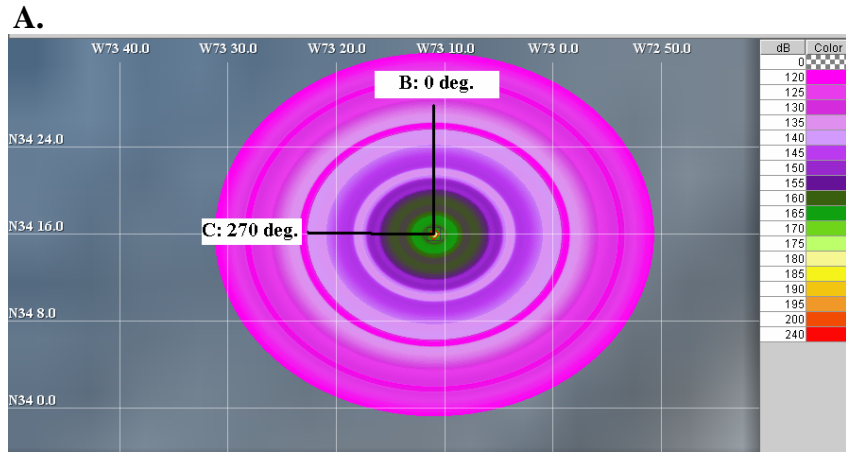


Figure 14. Modeled sound fields for a hypothetical (omni-directional) tactical mid-frequency sonar located at the position of transmission 5. Shaded colors indicate estimated received levels at various ranges. A plan view of the modeled sound field at the approximate depth of the sonar source (3m) is shown in A. Side views showing received sound conditions for two bearings from the sound source are shown in B (0°) and C (270°). Note the differences in depth and range scale from Fig. 13.

While the sound propagation modeling does provide some useful information in approximating the acoustic environment, particularly the high degree of spatial variability, the greatest limitation in terms of estimating received sound conditions for marine mammals is a lack of data on their position during transmissions. Absent explicit information on the location of animals in the vicinity of sound sources, it is not possible to estimate with any degree of confidence the received acoustic exposures by the animals from active sonar transmissions, regardless of the precision of sound propagation modeling.

Biomedical Findings

Most samples were distributed for analysis after field response had ended and the samples had been sorted and verified (Appendix IV). Due to remoteness of stranding site and difficult conditions, blood was spun and whole blood was analyzed for Complete Blood Counts (CBC) on 16 Jan 2005 at approximately 2100 hrs EST, more than 24 hr post-mortem. The laboratory, Sentara Labs, has been analyzing blood for the VAQS stranding program and providing consistent results (W. Walton, pers comm). WBC counts were checked manually. Serum and ocular fluid samples were frozen and analyzed after results from histopathology could be used to determine the most appropriate clinical and serological tests to run on the limited samples. Results from the various analyses were received at various times throughout 2005 (Appendix V). Methodology and results are discussed below.

A. Clinical Signs

As noted above, 15 dead and 18 live pilot whales were reported shortly after sunrise on the morning of 15 Jan 2005. Based on their position on the beach, the whales were estimated to have stranded while the tide was still relatively high, either late on 14 Jan 2005 or in the early morning hours of 15 Jan 2005. By the time stranding teams started to evaluate the whales, nine were found alive, 23 were dead, and two had presumably washed out. State of rigor was recorded for four of the dead animals: two were in firm rigor throughout the body, one was not in rigor, and one was still warm with the jaw in rigor. Clinical signs for the nine live animals included two noted as initially alive but which died prior to any clinical data being recorded, two that were moribund (nonresponsive, slow respirations, minimal corneal reflex, blowhole not closing well), and five that were responsive, although two of these had high respiratory rates (>6/min) and one had peeling skin on the dorsum.

Gravitational effects on a marine mammal on land cause severe progressive compromise of respiratory and circulatory systems, and catecholamines released due to stress of being on land cause further insult to the cardiovascular system. By the time personnel had arrived to evaluate the condition of the whales, the whales had been on the beach for an estimated 7-10 hrs. By the time personnel had arrived in any numbers by mid-afternoon, some the whales had been on the beach for 24 hr or more. At least 23 whales had died and the nine living animals were compromised, including two that died shortly thereafter. The length of time on the beach made long-term survival doubtful even for the few responsive animals remaining. As noted by Bossart *et al.* (1991), these circumstances “raise questions regarding the humanity of returning recently mass-stranded cetaceans to the sea.” In addition, high surf, strong currents and cold water made the option of immediate return to water too hazardous to personnel. The high onshore winds

would have required moving whales well offshore to prevent rapid restranding; boats were not readily available for this task, nor were water conditions safe for the personnel. Extensive areas of the stranding beach could only be accessed by vehicles at low tide, and heavy equipment for transport was initially not readily available even when the beach was accessible. There were no adequate holding facilities in northeast North Carolina or within a reasonable drive that could house a pilot whale even for short-term rehabilitation. For these reasons, the remaining seven living pilot whales were humanely euthanized (Table 4). Euthanasia methods and drug doses varied by response team, drug availability and by condition of the animal (Greer *et al.* 2001; doses in Table 4). Two moribund animals received euthanasia solution (sodium pentobarbital plus phenytoin sodium) directly without premedication (one intracardiac, one intrahepatic). One received diazepam intramuscularly as premedication followed by euthanasia solution (intrahepatic). One received a combination of xylazine and acepromazine intramuscularly followed by euthanasia solution (intracardiac). One received meperidine intramuscularly followed by euthanasia solution (intracardiac). Two received xylazine and acepromazine intramuscularly only, which sufficed to effect euthanasia without pentobarbital/phenytoin solution.

The minke whale was reported alive at 0810 hrs EST on the morning of 15 Jan 2005 and the stranding team arrived on site mid-morning. The whale was assessed as extremely emaciated and probably a dependent calf. Respirations were 4-6/min, and the whale was exhibiting fluke movements and muscle tremors. For reasons outlined above for the pilot whales, with the additional factor that as a dependent calf it would not survive if returned to the ocean, euthanasia was performed. Diazepam was administered intramuscularly, which reduced fluke movements and tremors, followed by euthanasia solution (intrahepatic).

The dwarf sperm whales were initially reported alive on the morning of 16 Jan 2005 just as multiple necropsies were about to commence on the pilot whales. One response team was promptly dispatched to investigate. By the time the team arrived on site, the whales had died. Both whales had signs of having stranded alive (abrasions on leading edges of flukes and flippers, bruised ventrum). One (KMS380, female) had one eye missing already and the other eye damaged by scavenging gulls.

All animals that received pentobarbital/phenytoin euthanasia solution (Table 4) were buried deep (approximately 2.4 m) in the sand above high tide line (pilot whales) or in a landfill (minke whale) after necropsy, to preclude secondary toxicity to scavengers.

B. Clinical Pathology

(CBC, serum biochemistry, ocular fluid biochemistry, and urinalysis)

Methods

Blood was collected from 16 pilot whales and the minke whale on 15 Jan 2005 once sample collection materials and sufficient personnel arrived on site. Three of these 16 pilot whales and the minke whale were alive when initially encountered and were sampled ante-mortem (one pilot whale) or immediately post-mortem (two pilot whales and the minke whale), the rest were already dead so time post-mortem is unknown. Ante-mortem blood collection was from a fluke vessel and post-mortem blood collection was by cardiac puncture. Blood was stored and

transported cool. Clot tubes were centrifuged about 9 pm that evening, and serum was separated and frozen (initially -20 °C, then -80 °C). Although large volumes of blood were collected in each case, the volume of serum harvested after centrifugation was small (possibly due to dehydration, collection from areas of the heart where cells had settled, or lack of clot retraction). With the limited serum available, priorities for further testing were determined after the preliminary histopathology results were available. The limited samples precluded full chemistry panels in many cases because some serum was required for serology as well. Ocular fluid (mostly vitreous humor, but also some aqueous humor) was collected post-mortem from 17 pilot whales. Serum and ocular fluids were stored frozen, initially at -20 °C and then at -80 °C, prior to analysis.

Complete blood counts were performed on three pilot whales (RT13, 21, and 48) and the minke whale (all of which were alive when initially encountered) by Sentara Laboratory Services, Norfolk, VA, the day after blood collection. Full serum biochemistry panels were performed on the three pilot whale samples for which there was sufficient volume (RT49, 59, and 105) by the New York State Animal Health Diagnostic Laboratory at the College of Veterinary Medicine, Cornell University (the laboratory used routinely in NMFS cetacean health assessment studies on the east coast of the U.S.). For 10 serum samples that had insufficient volume for full biochemistry panels and serology, or had sufficient extra volume after allocation to those priorities, a more limited biochemistry panel was performed with the Abaxis VetScan using the Comprehensive Diagnostic Profile rotor (requires only 0.2 ml) at NCSU CMAST (CAH). Ocular fluid biochemistry panels were performed on 16 samples by Cornell, and on 10 samples by the NCSU College of Veterinary Medicine, Veterinary Teaching Hospital, Clinical Pathology Laboratory, for a total of 17 samples (one performed only at NCSU, seven only at Cornell, and nine at both laboratories). VetScan analysis was attempted with the ocular fluid samples, but viscosity was too low for proper rotor loading, resulting in multiple failed readings.

There were only three serum samples for which both the VetScan and the Cornell laboratory could be compared. Analytes which differed to a clinically significant extent for those three samples were albumin (VetScan 1.0 – 1.4 g/dl lower than Cornell), creatinine (VetScan 0.2 – 0.9 mg/dl higher than Cornell), and globulin (VetScan 1.3 – 2.1 g/dl higher than Cornell, largely because this is calculated as total protein – albumin = globulin).

Urine was collected post-mortem from 10 pilot whales – two by urinary catheter, one by cystocentesis during necropsy, and for seven the collection method was not recorded (but most likely cystocentesis). Urine specific gravity was determined by refractometry, and dip stick analysis was performed; urine sediment was not examined.

All clinical pathology results are listed by individual whale in the appendices (serum biochemistry in Appendix VI, ocular fluid biochemistry in Appendix VII, and urinalysis in Appendix VIII). Because CBCs were performed on only 3 pilot whales and the minke whale, individual whale results are in Table 10. Summaries are available for the other results (serum biochemistry in Table 11, ocular fluid biochemistry in Table 12, and urinalyses in Table 13). For interpretation of serum and ocular fluid biochemistry, the values from the method producing the most results are used preferentially (VetScan for serum, Cornell for ocular fluids), then one of

Table 10. Results from complete blood counts for the tested pilot whales (RT) and minke whale (CTH001) from UMESE0501Sp. Blood was analyzed more than 24 hr post-mortem. P = present.

Field ID	White blood cell x 10 ³ /μl	Red blood cell x 10 ⁶ /μl	Hemoglobin (Hgb) g/dl	Hematocrit (HCT) %	Mean cell volume (MCV) fl	Mean corpuscular Hgb (MCH) pg	MCH concentration g/dl	Red cell distribution width (RDW)	Platelets x 10 ³ /μl	Segmented neutrophils %	Lymphocytes %	Monocytes %	Eosinophils %	Atypical lymphocytes (ATYP) %	Absolute neutrophils x 10 ³ /μl	Absolute lymphocytes x 10 ³ /μl	Absolute monocytes x 10 ³ /μl	Absolute eosinophils x 10 ³ /μl	Absolute basophils x 10 ³ /μl	Absolute reactive lymphocytes x10 ³ /μl	Polychrom	Howell-Jolly body	
RT13	<0.4	4.58	19.2	56.2	123	42	34	16.5	56													1+	P
RT21	1.1	5.04	19.9	57.3	114	40	35	15.4	118	37	50	2	9	2	407	550	22	99	0	22			P
RT48	<0.4	5.69		75.3	132	46	35	16.6	19														P
CTH001	0.5	5.32	20.9	62.8	118	39	33	17.5	122														P

the other sources for any additional available results (Cornell for serum, NCSU for ocular fluids). Serum biochemistry reference ranges for wild healthy short-finned pilot whales are lacking. Therefore, in Table 11 we list values from captive short-finned pilot whales and wild bottlenose dolphins for general comparison, while acknowledging the problems of making cross-species and captive vs. wild comparisons in clinical pathology values. Abbreviations of hematological and biochemical parameters used below are cross-referenced with the full names and abbreviations in the corresponding tables and appendices.

Results

Complete blood counts (Table 10):

Complete blood counts from blood collected from live whales (RT13) or immediately following euthanasia (pilot whales RT21 and 48 and the minke whale) indicate hemoconcentration (elevated hematocrit, red blood cell count, and hemoglobin; reasonably normal red cell indices [MCV, MCH, MCHC]) for all four animals, probably secondary to dehydration. Howell-Jolly bodies were observed in all four animals, which have previously been reported in belugas, orcas and pilot whales (Walsh *et al.* 1991, Bossart *et al.* 2001) with significance uncertain. The white blood cell counts were profoundly low (<0.4, <0.4, 0.5 and 1.1 x 10³/μl) and differential counts were precluded on all but one pilot whale. There was no evidence of overwhelming infection and no left shift in the one animal for which a differential count was possible. White counts may have been artifactually low due to delay between blood collection and CBC analysis, although it was only a 24-hr delay and environmental temperatures were cool during the time prior to putting the blood samples in transport coolers. Or, considering the length of time the animals had been stranded prior to blood collection, white blood cells may have become marginalized in the vascular system in response to inflammatory mediators upregulated following tissue damage or onset of sepsis (Tizard 1996).

Table 11. Summary of serum chemistries of stranded pilot whales from UMESE0501Sp and reference ranges for short-finned pilot whales and bottlenose dolphins. Most reference ranges are from Bossart *et al.* (2001). The reference ranges for pilot whales are based on multiple samples from two captive animals. For bottlenose dolphin it is based on single samples from 36 wild dolphins, except for CK which is based on multiple samples from 38 captive dolphins. Reference ranges for A/G ratio, the alternate iron range, and TIBC and % iron saturation from Medway and Geraci (1986); the sample size was unspecified.

Analyte	Pilot Whales from UME			Reference Ranges	
	n	Median	Range	Pilot Whale	Bottlenose Dolphin
Total Protein (g/dl)	9	7.35	4.3 – 9.9	5.3 – 6.0	6.4 – 8.8
Albumin (g/dl)	9	2.5	1.2 – 3.1	2.9 – 3.3	2.9 – 3.7
Globulin (g/dl)	9	4.8	3.1 – 6.8	2.2 – 3.0	3.1 – 5.5
Albumin/globulin (A/G) ratio	3	0.96	0.9 – 1.03	1-2	2-3
Sodium (mmol/L)	10	161	100 – 170	153 - 154	151 – 158
Potassium (mmol/L)	10	6.5	4.2 – 12.8		3.2 – 4.4
Chloride (mmol/L)	3	109	97 - 123		108 – 118
Bicarbonate HCO ₃ (mmol/L)	3	15	6-18		
Anion Gap [= (Na + K) – (Cl + HCO ₃)]	3	41	29 - 67		
Calcium (mg/dl)	9	8.9	7.8 – 11.2		8.2 – 9.4
Phosphorus (mg/dl)	10	5.75	3.1 – 18.2	4.3 – 4.8	3.2 – 7.2
Magnesium (mg/dl)	3	3.2	2.4 – 3.7		
Glucose (mg/dl)	10	132	101 - 185	98 – 106	62 – 139
Blood urea nitrogen (BUN) (mg/dl)	10	40	35 – 53	46 – 55	45 – 72
Creatinine (Cr) (mg/dl)	10	1.6	1.0 – 3.0	2.0 – 2.4	1.0 – 2.1
Alkaline phosphatase (ALP) (U/L)	10	86.5	17 – 343	143 – 243	51 – 610
Alanine aminotransferase (ALT) (U/L)	10	18	7 – 126	26 – 69	9 – 33
Aspartate aminotransferase (AST) (U/L)	3	322	320 - 1345	170 – 317	133 – 318
Creatine kinase (CK) (U/L)	3	1078	430 – 2559	55 – 80	100 – 250
Gamma glutamyltransferase (GGT) (U/L)	3	21	16 – 42	39 – 41	17 – 31
Lactate dehydrogenase (LDH) (U/L)	3	1827	1817 – 1863	425 - 505	350 – 500
Total bilirubin (mg/dl)	3	0.3	0.2 – 0.5	0.1	0.1 – 0.4
Direct bilirubin (mg/dl)	3	0	0 – 0.1		
Indirect bilirubin (mg/dl)	3	0.4	0.3 – 0.4		
Triglyceride (mg/dl)	3	126	52 – 174		
Iron (µg/dl)	3	230	171 – 543	108 – 179 or 113 - 343	74 – 176 or 148 – 287
Total iron binding capacity (TIBC) (µg/dl)	3	230	196 – 543	385 – 585	380 – 591
Percent iron binding saturation (%Sat)	3	100	87 - 100	27 - 81	32 – 57

Serum biochemistry (Table 11, Appendix VI):

Due to post-mortem collection, field sample handling, and time between collection and serum separation, the serum for all animals was hemolyzed to some degree. Hemolysis in bottlenose dolphin blood causes artifactual changes in some analytes including increases in serum iron, LDH, potassium, uric acid, ALT, calcium, total protein, albumin, and globulin, and decreases in

creatinine, total bilirubin, and GGT (Morgan *et al.* 1999). Elevated potassium, LDH, ALT, total protein, globulin, serum iron, and possibly changes in other analytes measured from some pilot whales are thus considered at least partly artifactual due to post-mortem hemolysis and/or sample handling. Blood from animals that were still alive when first encountered had less hemolysis and lower potassium than blood from animals that were dead when first encountered (sample size insufficient for statistical testing), but all samples had some degree of hemolysis. However, metabolic acidosis and rhabdomyolysis associated with stranding could have contributed to the hyperkalemia and hyperphosphatemia (Bossart *et al.* 2001).

Dehydration is suggested variously by hypernatremia and elevated total protein, hematocrit, RBC and hemoglobin. Though the sample size for pilot whales with measured chloride, bicarbonate, and anion gap is small, the high anion gap and low bicarbonate in these animals is consistent with metabolic acidosis (which could result from increased lactate associated with struggling on the beach, although lactate was not measured due to sample volume constraints).

The three pilot whales with the highest globulin values also had intra-abdominal abscesses (RT103 and 105 with abscesses 32 cm diameter and 5 cm diameter, respectively) or membranous glomerulopathy suggestive of immune complex deposition (RT59), making the elevated globulin values consistent with other pathology findings indicating an inflammatory response. Values from the Cornell laboratory available for RT59 and 105 were also mildly elevated compared with values reported for captive pilot whales (Bossart *et al.* 2001).

Moderately elevated glucose values are consistent with a stress response. Mildly decreased BUN, despite possible dehydration, suggests a lack of recent feeding which is consistent with the results of the stomach content analysis. Elevated AST, LDH and CK are most consistent with muscle damage associated with stranding. The animal with the highest ALT, AST, LDH and total bilirubin also had moderate focal periportal hepatitis and periportal fibrosis, indicating that antemortem liver damage may have contributed to these abnormalities.

The serum chemistries for the minke whale (Appendix VI) were within ranges reported for harpooned minke whales (Tryland & Brun 2001), except for a low phosphorus. Hemoconcentration noted above for the minke whale based on CBC results was supported by sodium and total protein being near the high end of the ranges reported. Despite this, BUN was at the low end of the range reported, consistent with its emaciated condition.

Ocular fluid biochemistry (Table 12, Appendix VII):

Ocular fluid has the potential to avoid some pitfalls of post-mortem serum samples due to its protected location away from lysing red blood cells. Forensic interpretation of marine mammal ocular fluid biochemistry is still in its infancy (but see recent paper on manatee vitreous fluid biochemistry by Varela & Bossart 2005). Results are presented here to be complete, but are not interpreted relative to the condition of the stranded animals. Ocular fluid and serum values for electrolytes (Na, K, Cl, bicarbonate, Ca) and BUN were in rough agreement, and for these analytes ocular fluid may provide useful inferences regarding serum values when serum is not available, or be supportive of serum values in cases where hemolysis and other post-mortem changes may cloud interpretation. Ocular fluid creatinine was lower than, but correlated well with, serum creatinine. Proteins (including enzymes) were not consistent between serum and

Table 12. Summary of ocular fluid chemistries of stranded pilot whales from UMESE0501Sp. Samples were collected post-mortem. There are no reference ranges for ocular fluid chemistries of cetaceans. For manatee vitreous humor chemistries, see Varela and Bossart (2005). Abbreviations are as for serum chemistries.

Analyte	n	Median	Range
Total Protein (g/dl)	17	0.9	0.3 – 6.6
Sodium (mmol/L)	17	159	130 - 195
Potassium (mmol/L)	17	9.5	6.4 – 26.1
Chloride (mmol/L)	17	126	101 – 174
Bicarbonate HCO ₃ (mmol/L)	17	20	13 – 34
Anion Gap	17	21	17 – 34
Osmolality (mOsm)	11	335.4	321.7 – 375.2
Calcium (mg/dl)	17	8.3	6.0 – 11.9
Phosphorus (mg/dl)	17	2.2	0.9 – 10.0
Magnesium (mg/dl)	17	2.7	1.9 – 12.5
Glucose (mg/dl)	17	58	21 – 88
Blood urea nitrogen (mg/dl)	17	44	36 – 68
Creatinine (mg/dl)	17	0.8	0.1 – 1.1
Alkaline phosphatase (U/L)	17	3	1 – 44
Aspartate aminotransferase (U/L)	17	261	38 – 957
Creatine kinase (U/L)	17	2769	31 – 17710
Lactate dehydrogenase (U/L)	16	594	36 – 4115
Sorbitol Dehydrogenase (U/L)	16	14	2 - 1389

ocular fluid, and, unlike in manatees (Varela & Bossart 2005), total protein was considerably lower in ocular fluid. One ocular fluid sample contained a higher total protein, and several values intermediate between other serum and ocular fluid samples, indicating there may have been blood contamination of this sample

Urinalysis (Table 13, Appendix VIII):

The significance of protein and blood as detected by urine dip stick are difficult to interpret in samples collected post-mortem due to bladder and urethral mucosal sloughing and leakage. However, of the four pilot whales registering 3+ urine protein, two had histologic evidence of glomerular disease and another had the highest serum and ocular creatinine values of those tested. The fourth had no serum biochemistry or histopathology samples. The pilot whale with the most severe renal pathology (RT59, moderate multifocal membranous glomerulopathy with Bowman’s capsule thickening and multifocal tubulonephrosis) had 3+ proteinuria, urine specific gravity approaching isosthenuria (1.015) despite conditions promoting dehydration, and mildly elevated serum creatinine. One pilot whale’s urinary bladder was grossly leathery and atonic with an odiferous, intraluminal blood clot. The urine was abnormal resulting in uninterpretable results, including refractometry where the entire field turned white (markedly elevated specific gravity) and dip stick patches for protein, blood and urobilinogen that instantly turned colors not on the color charts. The alkaline urine (pH 8.5) confirmed the likelihood of cystitis (urine pH of cetaceans should be acidic (Bossart *et al.* 2001)), but kidney histopathology had no significant findings and the bladder tissue collected in formalin was not recovered from the tissue jar (or not identified as such because of its abnormal texture).

Table 13. Summary of urinalyses from stranded pilot whales from UMESE0501Sp.

Analyte	n	Median	Range
pH	10	6	5.0 – 8.5
Specific gravity	9	1.023	1.015 – 1.039
Bilirubin	10	all negative	
Blood	10	5 negative, 2 trace, three 3+	
Glucose	10	all negative	
Ketones	10	8 negative, 1 trace, 1 small	
Protein	9	1 negative, 1 trace, one 2+, four 3+	
Urobilinogen	9	all 0.2 mg/dl	

Summary of clinical pathology results

Post-mortem changes make full interpretation of clinical pathology results challenging. Still, some conclusions may be drawn. Most serum biochemistry abnormalities observed are expected in beached live cetaceans due to physiological deterioration from being on land for an extended time (dehydration, electrolyte imbalances, and muscle and organ degeneration). Some abnormalities, however, may indicate a more chronic condition. At least three pilot whales had evidence of systemic inflammation supported by histopathology findings, one pilot whale had evidence suggestive of liver impairment, also reinforced by histopathology, and several had serum biochemical changes indicating lack of recent feeding. In addition, urinalyses confirmed or reinforced gross, histologic or serum biochemistry findings of functional urinary tract pathology that would have existed prior to stranding in four of 10 pilot whales from which urine was collected.

C. Gross Pathology

1. Gross Findings: General

Necropsies were performed on 27 pilot whales and both dwarf sperm whales at the stranding site (field necropsy) while the minke whale was moved from the stranding site and necropsied at VAQS. Post-cranial tissues were collected on 16-17 Jan 2005. Extensive tissue suites, including major organs (heart, lung, liver, kidney, spleen, brain) and additional organs, were collected from 16 pilot whales, two dwarf sperm whales, and the minke whale calf (Appendix II, III). Due to more degraded carcasses or carcasses that washed out, partial tissue suites (solely head tissues or select organs) were collected from nine pilot whales (Appendix II, III). Virtually no histologic samples were collected from two pilot whales (RT57 and RT63). All tissues sampled for histopathology were collected in 10% neutral buffered formalin on site, transported via a commercial packaging service to the University of Tennessee for accessioning, transferred to cassettes, processed with established protocols, sectioned at 5 to 7 microns and stained with hematoxylin and eosin. Additional stains (“special stains” and immunohistochemistry) were utilized on an “as needed” basis, such as to aid in more precise identification of deposits, to indicate presence of substances such as fat, or to screen for infectious agents such as bacteria or fungi. Special stains and immunohistochemistry were conducted at additional histopathology laboratories. Individual case reports are given in Appendix IX.

In general, the pilot whales and dwarf sperm whales were in good body condition, not thin or emaciated. Stomachs or stomach contents were collected from 27 pilot whales and both dwarf sperm whales. No fresh prey or fleshy remains were found in any stomachs. Most (16 of the 27) pilot whale stomachs were empty. Jordán Sardi *et al.* (2005) reported on the durable prey remains found in the pilot whale stomachs: otoliths from one species of fish were found in stomachs from four pilot whales, mostly in small numbers, and squid beaks were found in stomachs from 10 whales. Squid beaks in the stomachs were from ten identified species, and some unidentified species. Number of individual prey ranged from 1-23 (Jordán Sardi *et al.* 2005). Fish otoliths and squid beaks were also found in stomachs from both dwarf sperm whales (63 prey remains in one animal and 111 in the other). All species found in the dwarf sperm whale stomachs were also found in the pilot whale stomachs. Predominant prey species, including both fish and squid, are widely distributed and known to inhabit deep water (Jordán Sardi *et al.* 2005). In contrast to the toothed whales, the minke whale calf was emaciated and the stomach was empty.

Gross lesions were observed in all animals involving all body systems (Appendix X). Variations between prosecution teams in descriptions and lesion identification did occur. However, in an effort to standardize these findings, gross diagnoses were provided by the pathologist on record (DSR) based upon the descriptions provided in the gross necropsy forms. It is important to stress that gross diagnoses are often provisional and may be confirmed or refuted by histologic evaluation. Frequently, histologic lesions of variable severity may be observed in the absence of gross lesions. In addition, a “lesion” or grossly observed deviation from a typical or expected appearance could be artifactual, have little clinical significance (incidental lesion), or have resulted in physical or physiological impairment (significant lesion). Significant changes are those that may have contributed to decreased function, morbidity, or mortality. Lesions may range from peracute (hours) to chronic (greater than 14 days).

In addition to variation in description of lesions, there were differences in recording methods. That is, in some cases, abbreviations such as n/e (not examined), NVL (no visible lesions) or NSF (no significant findings) were utilized for system evaluation. In other cases, no entry was placed on the necropsy form. No entry could mean that the system was not examined or that it was examined but findings, or lack thereof, were not recorded. For this reason, the abbreviation n/r, not recorded, has been adopted for the purpose of this report. The result of variation in systems examined or findings recorded is variation in the number of animals examined for each system.

The number of animals examined both with gross and histologic examinations, and raw number, type, and percentage of lesions is indicated in Table 14. The range of examined animals for each organ system was 11 (endocrine) to 28 (respiratory system and sinuses) with an average of 18 ± 4 animals examined per system. While the number of animals (denominators) varies, the overall trend for observation of changes in order of system with largest number of affected animals was: respiratory system and sinuses (27/28, 96.4%), nervous system (15/17, 88.2%), digestive system (14/20, 70%), integumentary system (13/19, 68.4%), reproductive system (9/22, 40.9%), hemolymphoreticular system (6/17, 35.3%), hepatobiliary system (4/18, 22.2%), body as a whole/body cavities (3/14, 21.4%), musculoskeletal system (2/15, 13.3%), urinary system (2/16, 12.5%), endocrine system (1/11, 9.1%), and cardiovascular system (2/16, 7.4%).

Table 14. Gross and histologic findings from pilot whales and dwarf sperm whales that stranded during UMESE0501Sp by system affected. The variation in numbers examined reflect either data that were not recorded or tissues that were not collected. In addition, the number of lesions may be greater than the number of animals examined as individual animals may have had more than one lesion in a given body system.

System and Tissue	Gross			Histology		
	Number Examined	Lesions	Percentage Affected	Number Examined	Lesions	Percentage Affected
Cardiovascular System	16	2	12.5	20	7	35.0
Serous atrophy of fat		2*	12.5		--	--
Fibrosis & ventricular dilation		1	6.3		--	--
Cardiomyocyte necrosis		--	--		1	5.0
Atrial fibrosis		--	--		1	5.0
Ventricular fibrosis		--	--		2	10.0
Epicarditis		--	--		1	5.0
Aortitis		--	--		1	5.0
Cardiomyocyte disarray		--	--		1	5.0
Respiratory System & Sinuses	28	27	96.4	22	19	86.4
Pulmonary congestion and edema		12	42.9		--	--
Pulmonary granulomas & verminous pneumonia hematoma		4	14.3		--	--
Pterygoid sinus hematoma		22	78.6		--	--
Pulmonary edema and/or congestion		--	--		5	22.7
Verminous pneumonia		--	--		3	13.6
Pulmonary hemorrhage		--	--		3	13.6
Tracheitis/Bronchitis		--	--		3	13.6
Fibrosis		--	--		2	9.1
Lipid pneumonia		--	--		1	4.5
Nervous System	17	15	88.2	26	12	46.2
Congestion		13	76.5		--	--
Subdural hemorrhage		3	17.6		--	--
Encephalitis		--	--		4	15.4
Subdural hemorrhage		--	--		1	3.8
Hypoxic change		--	--		5	19.2
Perivascular edema		--	--		2	7.7
Hemato / Lymphoreticular System	17	6	35.3	22	16	72.7
Congestion and edema		5	29.4		--	--
Small lymphoid organs		1	5.9		--	--
Pseudolymphomatous hyperplasia		--	--		1	4.5
Edema		--	--		4	18.2
Lymphoid hyperplasia/draining lymph node		--	--		4	18.2
Granulomatous lymphadenitis		--	--		4	18.2
Lymphoid depletion		--	--		1	4.5
Congestion		--	--		1	4.5
Anthracosis		--	--		1	4.5
Digestive System	20	14	70.0	19	11	57.9
Verminous esophagitis/gastritis/enteritis		13	65.0		--	--
Perigastric (mesenteric abscess)		1	5.0		--	--
Verminous gastritis/enteritis		--	--		4	21.1
Gastritis/Enteritis		--	--		3	15.8
Gastric ulcer		--	--		1	5.3
Stomatitis/glossitis		--	--		4	21.1

Table 14, continued	Gross			Histology		
	Number Examined	Lesions	Percentage Affected	Number Examined	Lesions	Percentage Affected
Musculoskeletal System	15	2	13.3	19	4	21.1
Occipital condyle necrosis & atlanto-occipital spondylosis		1	6.7	--	--	--
Acute mandibular fracture		1	6.7	--	--	--
Occipital condylar osteonecrosis		--	--	1	1	5.3
Contraction band formation		--	--	1	1	5.3
Interstitial myositis		--	--	1	1	5.3
Mineralization		--	--	1	1	5.3
Endocrine System	11	1	9.1	19	1	5.3
Adrenocortical hemorrhage/congestion		1	9.1	--	--	--
Thyroid follicular cysts		--	--	1	1	5.3
Pituitary gland fibrosis		--	--	1	1	5.3
Urinary System	16	2	12.5	14	9	64.3
Pericystic abscess		2	12.5	--	--	--
Interstitial nephritis		--	--	2	2	14.3
Membranous glomerulopathy		--	--	2	2	14.3
Tubuloproteinosis		--	--	1	1	7.1
Intraluminal mineral		--	--	2	2	14.3
Cystitis		--	--	2	2	14.3
Congestion		--	--	1	1	7.1
Renal infarct		--	--	1	1	7.1
Reproductive System	22	9	40.9	20	9	45.0
Pregnancy		3	13.6	--	--	--
Periuterine <i>Monorygma</i>		6	27.3	--	--	--
Endometritis		--	--	4	4	20.0
Cystic endometrial hyperplasia		--	--	1	1	5.0
Mucometra		--	--	1	1	5.0
Adenomyosis		--	--	1	1	5.0
Balanitis		--	--	1	1	5.0
Testicular involution		--	--	2	2	10.0
Hepatobiliary System	18	4	22.2	21	10	47.6
Congestion		2	11.1	--	--	--
Granulomatous hepatitis		2	11.1	--	--	--
Congestion, acute		--	--	4	4	19.0
Granulomatous hepatitis		--	--	1	1	4.8
Chronic passive congestion		--	--	2	2	9.5
Periportal fibrosis		--	--	1	1	4.8
Early telangiectasia		--	--	1	1	4.8
Biliary hyperplasia		--	--	3	3	14.3
Body as a Whole, Body Cavity	14	3	21.4	22	3	13.6
Intra-abdominal granulomas		3	21.4	--	--	--
Granulomatous peritonitis		--	--	3	3	13.6
Integumentary System	19	13	68.4	20	4	20.0
Healed Fishery Interaction		7	36.8	--	--	--
Verminous panniculitis		3	15.8	--	--	--
Rake marks		1	5.3	--	--	--
Ventral bruising		1	5.3	--	--	--
Focal ulcer		1	5.3	--	--	--
Peri-melon fat necrosis		1	5.3	--	--	--
Mammary gland fibrosis and mastitis		--	--	2	2	10
Fibrosis		--	--	1	1	5
Perimelon fat necrosis		--	--	1	1	5

*Pilot whale RT59 had cardiac fibrosis and serous atrophy of fat.

2. Gross Findings: Post-Cranial

Respiratory System. Findings in the pterygoid sinuses are discussed in section 3. Gross Findings: Cranial. Lungs were examined in 22 cetaceans. Pulmonary congestion and edema (13/22, 59%) were common findings. Other respiratory lesions include mild granulomatous and verminous pneumonia (18%, 4/22), and focal fibrosis (4%, 1/22). The terms verminous and metazoan are utilized as blanket terms for infestation by nematodes, trematodes, or cestodes in various cavities or organs.

Nervous System. Findings in the brain are discussed in section 3. Gross Findings: Cranial. One pilot whale, RT24, however, is briefly mentioned here as having extensive subdural hemorrhage.

Reproductive System. Six females were pregnant with fetuses ranging in standard length from 54-120 cm (Table 6). Fetuses were frozen and examination is pending. All pregnant females had corpora lutea and seven non-pregnant females had corpora albicantia on their ovaries (Table 6). Four females for which both ovaries were examined had no corpora. Periuterine cestodes (Etiology: *Monorygma* sp.) were observed in three females in the suspensory mesentery.

Digestive System. Metazoans were observed in the digestive tract of 65% (13/20) of cetaceans including both dwarf sperm whales. Sites included esophagus, stomach, and intestine. Presence within the esophagus likely represents either a primary site of infestation or post-mortem migration of parasites either as an active or inactive process from the stomach. One pilot whale, RT 105, had a 5 x 5 x 5 cm perigastric abscess in the mesentery.

Integumentary System. There were healed line marks around the mandible, which is evidence of prior fishery interaction, in 37% (7/19) of the pilot whales. Scar sites were not areas of active infection or inflammation and are considered incidental to the stranding, but provide important historical information as to life history and human interactions. Verminous panniculitis (blubber layer) with cestodes as the offending metazoan was observed in three pilot whales. Individual pilot whales had focal ulceration, rake marks, and peri-melon fat necrosis (presumptive). Peri-melon fat necrosis will be described in the following section. Ventral bruising (lividity) was observed in one dwarf sperm whale and was considered a result of contact with the substrate.

Hepatobiliary System. Congestion of the liver, which is characterized by exudation of blood on cut surface, was observed in one pilot whale (RT 59) and one dwarf sperm whale (KMS 379). This can be a peri-mortem occurrence or an indication of ongoing vascular compromise (chronic passive congestion) such as in cardiac disease. The pilot whale, RT59, with hepatic congestion had gross evidence of fibrosis and ventricular dilation (see Gross Findings: Post-Cranial, Cardiovascular System). Granulomas were observed in the liver of two pilot whales (RT22 and RT102) and did not involve a large portion of the liver.

Hematolymphoreticular System. Over one-third of examined animals (6/17) had lymph node changes. Congestion and edema of lymph nodes was observed in five pilot whales. Grossly, these lymph nodes exhibited mild enlargement and on cut surface exuded blood or wet, clear, and glistening fluid (edema). The minke whale had small lymph nodes, suggestive of inactivity.

Body Cavities. Within the abdominal cavity of three pilot whales (RT22, RT103, RT105) (21%, 3/14), there were variably-sized, firm nodules (granulomas). In one pilot whale, RT103, a 31 x 32 x 32 cm granuloma was associated with the kidney. Abdominal granulomas were of clinical significance in RT103, but were considered incidental in RT22 and RT105.

Musculoskeletal System. One pilot whale, RT50, had changes focused upon the occipital joint. There was a fibrous and boney adhesion between the occipital joint and cervical vertebrae one (C1). Additionally, the right occipital condyle was enlarged and had regions of boney loss and discoloration (osteonecrosis). One pilot whale, RT63, had an acute mandibular fracture with associated hemorrhage.

Urinary System. Excluding the previously mentioned pilot whale (RT103) with an adhered granuloma to the kidney, two pilot whales (RT57, RT107) had chronic-active pericystic abscesses which were suspected sites of parasitism and host reaction.

Cardiovascular System. Serous atrophy of cardiac fat, which is characterized by a wet, clear to light yellow cardiac fat in response to decreased nutritional stores and mobilization of body lipid stores was observed in one pilot whale (RT59) and the minke whale calf (CTH001). In addition, the affected pilot whale, RT59, had evidence of multifocal fibrosis and ventricular wall thinning and loss of normal turgor (*e.g.*, “flabby” heart).

Endocrine System. One pilot whale had bilateral congestion of the adrenal glands at the interface of the cortex and medulla.

Summary of Gross Findings: Post-Cranial

Overall, consistent lesions were not observed across the three species save for lack of gastric contents. The minke whale calf was emaciated with marked serous atrophy of fat indicating mobilization of body nutritional stores (*e.g.* fat and muscle). Healed cutaneous lesions as a result of fishery interactions were observed in many of the pilot whales, but were not causes of debilitation or death. Three pilot whales did have lesions that could be associated with debilitation including: (1) multiple, large granulomas within the abdominal cavity, (2) cardiac fibrosis and ventricular attenuation with hepatic chronic passive congestion, and (3) occipital condylar osteonecrosis and fibrosis at the atlanto-occipital joint. One pilot whale had extensive subdural hemorrhage which likely occurred on the beach from thrashing. Similarly, acute mandibular fracture in one pilot whale likely occurred on the beach. Other observed lesions were incidental including the abdominal granulomas, pulmonary granulomas, and hepatic granulomas. Assessment of pregnancy provided an indication of this group’s reproductive status.

3. Gross Findings: Cranial

Examination of 25 heads was completed, including 23 pilot whales and two dwarf sperm whales, during three examination sessions (Jan 2005 (n = 8), February 2005 (n = 9 including CT scanning (n = 4), and November 2005 (n = 8)). Heads had been frozen and were thawed for examination. Examination protocols did vary and there were cases where information was not recorded on findings. Again, this does not indicate an absence of investigation, but an absence

of recorded information. In some cases, tissues were not collected. Specific sites examined included extramandibular fat, intramandibular fat, auditory meatus, peribullar acoustic fat, peribullar soft tissue, peribullar sinus, pterygoid sinus, melon, and brain. In general, there was evidence of freeze/thaw artifact such as ice crystal formation, reddening of tissue associated with erythrocyte rupture and pigment release (hemoglobin imbition), and autolysis in the examined heads. Results of head dissections for individual whales are in Appendix XI and summarized in Table 15.

Extramandibular Fat. Gross lesions were not observed (n=9).

Intramandibular Fat. Of 16 examined whales, 69% (11/16) had evidence of congestion (n=1), focal or patchy hemorrhage (n=9) either unilaterally (n=5) or bilaterally (n=3), and focal reddening (n=1). Side distribution was not indicated in one pilot whale with presumptive hemorrhage. The term presumptive is utilized because of the discoloration of the adipose that was not definitively hemorrhagic. Hemorrhage was observed predominantly near the vascular rete. One pilot whale with focal hemorrhage had diffuse discoloration of the intramandibular fat. Both dwarf sperm whales had hemorrhage in the intramandibular fat. White, 1 mm constellatory foci were observed on the surface and within the intramandibular fat of one pilot whale, which were consistent with foci of post-mortem fat autolysis (saponification).

Auditory Meatus. Perimeatal fluid (transudate), petechiae (tiny red foci), and perimeatal congestion were observed in 3/12 (25%) pilot whales.

Peribullar Acoustic Fat. No visible gross lesions were reported.

Peribullar Soft Tissue. Unilateral congestion was observed in one dwarf sperm whale. Unilateral (n=2) and bilateral (n=1) superficial focal hemorrhage was observed in three pilot whales. This region was subjacent to a portion of the otic bone with a rounded protruberance (focal compression and vascular rupture).

Peribullar Sinus. Metazoans were observed in the peribullar sinus of 66% (6/9) pilot whales. The distribution was unilateral in four of the six pilot whales. A small clot was observed in one pilot whale, fluid without associated parasites in a pilot whale, and hemorrhage in the right peribullar sinus in a dwarf sperm whale.

Brain. Congestion of superficial vessels of the brain and meninges was a common finding (88%, 13/17) and typically was observed on the ventral surface of the brain (hypostatic congestion). Subdural hemorrhage (12%, 2/17) was observed in two animals ranging from extensive and patchy (RT24) to mild and focal (RT104). In two pilot whales, there were rare or few gas bubbles within superficial vessels. These bubbles were located near the site of vessel detachment when heads were separated from bodies.

Pterygoid Sinus. Please note that the number of animals described with pterygoid sinus lesions is greater than the number of examined heads indicated above because the two animals without full head necropsies were excluded from the head total. Verminous pterygoid sinusitis (22/27, 81%) was a common finding. Trematodes and nematodes were observed in densities that ranged from few to numerous. There were nine cases of verminous sinusitis; lifting of the mucosal

Table 15. Gross and histologic results of acoustic tissues and brain from pilot whales and dwarf sperm whales that stranded during UMSE0501Sp by system affected. The variation in numbers examined reflect either data that were not recorded or tissues that were not collected. The number of animals with pterygoid sinuses examined is lower here than in Table 14 because only cases with a detailed head examination were included here.

System and Tissue	Gross			Histology		
	Number Examined	Lesions	Percentage Affected	Number Examined	Lesions	Percentage Affected
Auditory Meatus	12	3	25.0	4	0	0.0
Perimetal reddening, petechiae, and		2	16.7		--	--
Perimeatal transudate		1	8.3		--	--
Peribullar Acoustic Fat	10	0	0.0	4	0	0.0
Peribullar Soft Tissue	7	4	57.1	5	2	40.0
Hemorrhage (focal & superficial)		3	42.9		--	--
Congestion		1	14.3		--	--
Peribullitis		--	--		1	20.0
Superficial & focal hemorrhage		--	--		1	20.0
Peribullar Sinus	11	9	81.8	3	1	33.3
Metazoans		6	54.5		--	--
Hemorrhage/post-mortem clot formation		2	18.2		--	--
Fluid accumulation		1	9.1		--	--
Post-mortem clot formation		--	--		1	33.3
Pterygoid Sinus	22	20	90.9	8	8	100.0
Verminous sinusitis w/ or w/out						
hematoma formation		16	72.7		--	--
Fluid		1	4.5		--	--
Hematoma/Hemorrhage		3	13.6		--	--
Verminous sinusitis/sinusitis		--	--		6	75.0
Congestion/hemorrhage		--	--		2	25.0
Melon	6	1	16.7	2	1	50.0
Perimelon fat necrosis		1	16.7		1	50.0
Brain	17	15	88.2	26	12	46.2
Congestion		13	76.5		--	--
Subdural hemorrhage		3	17.6		--	--
Encephalitis		--	--		4	15.4
Subdural hemorrhage		--	--		1	3.8
Hypoxic change		--	--		5	19.2
Perivascular edema		--	--		2	7.7
Extramandibular Fat	9	0	0.0	8	1	12.5
Perivascular hemorrhage & edema, mild		--	--		1	12.5
Intramandibular Fat	16	12	75.0	8	4	50.0
Hemorrhage, congestion		11	68.75		--	--
Miliary saponification (post-mortem)		1	6.25		--	--
Perivascular hemorrhage and edema		--	--		4	50

lining by blood clots (hematomas) was observed in association with the metazoan infestation in the sinuses. Rarely, there was mucosal hyperplasia, an indication of chronic mucosal epithelial reaction to parasites (1/27, 3.7%). In addition, pterygoid sinus fluid was observed in two animals in association with parasitic infestation. Fluid analysis (cytology) was not done due to the likelihood of poor yield associated with freezing (cell rupture) and autolysis. Speciation is discussed in the section H. In regards to the pilot whales, verminous sinusitis was a consistent finding in a majority of pilot whales (94%, 17/18). When indicated, bilateral infestation

predominated (82%, 14/17). Associated changes included hematomas and hemorrhage (n=5) and hyperplasia (n=2). Hemorrhage and hematoma formation was observed only in both dwarf sperm whales and one pilot whale without associated parasites.

Melon. In one pilot whale, there were two regions in the peri-melon soft tissue that were thickened, semi-translucent and well-demarcated.

Summary of Findings: Cranial

Twenty-five heads were examined with nine specific anatomic locations of interest: extramandibular fat, intramandibular fat, auditory meatus, peribullar acoustic fat, peribullar soft tissue, peribullar sinus, pterygoid sinus, melon, and brain. Parasitism was a common finding in pilot whales most frequently involving the pterygoid sinus, with lesser peribullar sinus involvement. Reaction to parasites, including hematoma formation and mucosal hyperplasia, was observed though not in all animals. Congestion was observed in the brain in nearly all of the cetaceans and likely represents hypostatic congestion, which is pooling of blood post-mortem. Few gas bubbles were observed in superficial vessels near the point where the vessel had been cut during the disarticulation process. Given the presence of these bubbles near the cut edge, time heads were left on beach, and freeze-thaw artifacts, this is considered to be the result of either iatrogenic introduction of air or the result of post-mortem bacterial gas production. Focal hemorrhage in the peribullar soft tissue is likely the result of localized pressure upon vascular structures in the soft tissue subjacent to a protruding portion of the otic bone which may be compressing and rupturing small vessels in an animal that is no longer underwater. Finally, hemorrhage was observed in the intramandibular fat. This typically was near the vascular rete. Erythrocytic extravasation from the vascular rete, either antemortem or post-mortem, may have occurred. In the case of post-mortem leakage, the term hemorrhage, an active event, would not apply; this would then be a form of hypostatic congestion or the result of erythrocyte breakdown and release of pigment (hemoglobin imbibition). Antemortem versus post-mortem extravasation could not be determined grossly.

D. Histopathology

1. Histologic Findings: General

Formalin-fixed tissue samples were processed with routine protocols, sectioned at 5 to 7 microns and stained with hematoxylin and eosin. Special stains, *e.g.*, those utilized to highlight bacteria, basement membranes, fungi, and fat, were utilized as needed. Similarly, immunohistochemical stains to identify specific cell types were employed on an as-needed basis to better classify observed changes. Since necropsies were conducted on the beach during windy conditions, mineral particulates did enter tissues and for that reason some were unable to be trimmed. This resulted in differences in the number of examined organs. Slides were examined by a board-certified pathologist (DSR). Two reviews and one consultation with a total of five pathologists were also conducted. Consultation was targeted, involving specific cases rather than all cases.

2. Histologic Findings: Post-Cranial

Table 14 indicates the number of animals examined, number of animals with lesions, types of lesions, and percentage affected for each body system and Appendix XII lists specific findings for each animal examined. Corresponding values for gross findings are also listed as a raw comparison of observational correlation grossly and histologically. Individual necropsy reports are provided in Appendix IX. Specific histologic findings for post-cranial systems were found in 25 pilot whales, 2 dwarf sperm whales, and one minke whale calf. Histologic samples were not available for two pilot whales, RT63 and RT74; and nine animals had only head tissues (brain, pterygoid sinus, acoustic fat, mandibular fat), and/or gastric samples, lymph nodes, or reproductive organs. As with gross findings, the number of animals with tissues for each organ system varied, ranging from 14-26 with an average of 20 ± 3 animals examined. While the number of animals (denominators) varies, the overall trend for observation of changes is: respiratory system and sinuses (19/22, 86.4%), hematolymphoreticular system (18/22, 81.8%), urinary system (9/14, 64.3%), digestive system (11/19, 57.9%), hepatobiliary system (10/21, 47.6%), nervous system (12/26, 46.2%), reproductive system (9/20, 45.0%), cardiovascular system (7/20, 35.0%), musculoskeletal system (4/19, 21.1%), integumentary system (4/20, 20.0%), body as a whole/body cavities (3/22, 13.6%), and endocrine system (1/19, 5.3%).

Respiratory System. Non-specific mild to moderate inflammation of trachea (tracheitis), bronchi (bronchi), bronchioles (bronchiolitis), interstitium (interstitial pneumonia), and alveoli (alveolitis) was observed in 27% of pilot whales. One dwarf sperm whale had subpleural lipid pneumonia which may be either exogenous or endogenous in causation. Lipid emanates from type II pneumocytes in response to localized tissue damage. A cause for the inflammation and lipid pneumonia was not observed. In two pilot whales, there was a verminous pneumonia eliciting an intense local reaction. Pulmonary congestion, edema, and hemorrhage were observed in 22.7% of pilot whales and dwarf sperm whales with pulmonary hemorrhage evident in both dwarf sperm whales and one pilot whale. Pulmonary edema and congestion are characterized by flooding of alveoli by lightly staining proteinaceous fluid and congestion by expanded vessels filled with erythrocytes. In the dwarf sperm whale, in addition to pulmonary congestion and hemorrhage, there was interstitial fibrosis.

Nervous System. See section 3. Histologic Findings: Cranial.

Reproductive System. Mild to moderate endometritis characterized by infiltration of the endometrium by lymphocytes and plasma cells was observed in four pilot whales. None of these females were pregnant. In the female dwarf sperm whale, there was cystic endometrial hyperplasia, mucometra (mucoproteinaceous fluid within the lumen), and presence of glands within the myometrium (adenomyosis). Two males had no evident sperm production (seasonal involution), and one of these males (RT47), had inflammation of the penis (balanitis); *Brucella* sp. was not cultured from preputial swabs of this animal.

Digestive System. Non-specific mild to moderate stomatitis and/or gastritis was observed in eight pilot whales and one dwarf sperm whale. Verminous gastritis in three pilot whales and intraluminal cestodes in one dwarf sperm whale was observed. One pilot whale had a gastric ulcer without associated bacteria, fungus, protozoa, or parasites.

Integumentary System. Fibrosis within the dermis was observed in two pilot whales, and, while the source of sampling was not indicating, could have been associated with the grossly observed fishery interaction or some other penetrating injury. There was mastitis in two pilot whales. Finally, one pilot whale with grossly observed changes in the peri-melon fat had evidence of collagen necrosis without associated inflammation.

Hepatobiliary System. Congestion of the liver was observed in four pilot whales and one dwarf sperm whale. In the dwarf sperm whale KMS379 and pilot whale RT59, there was associated deposition of hemosiderin either within Kupffer cells lining the sinusoids or in hepatocytes as well as hepatocellular atrophy (dwarf sperm whale) and fibrosis of central veins (pilot whale). In a pregnant female pilot whale, there was dilation of sinusoids suggestive of early telangiectasia. Pilot whale RT22 had granulomas within the liver with associated spaces that were either empty or contained a granular eosinophilic substance. The initiating cause of granuloma formation was not identified. Biliary hyperplasia (n=2) and periportal hepatitis (n=3) were observed in pilot whales. There was focal inflammation of a central vein (phlebitis) of unknown etiology.

Hematolymphoreticular System. Granulomas were present within the lymph nodes of three pilot whales and occupied less than 15% of the parenchyma. An etiologic agent was not evident. Depletion of lymphocytes was observed in two pilot whales and depletion of thymic lymphocytes was observed in the minke whale calf. Black granular pigment was observed in macrophages within the lymph node of one pilot whale and was most consistent with anthropogenic substances (carbon pigment). There was congestion and edema observed in the lymph nodes of three pilot whales and one dwarf sperm whale. In the dwarf sperm whale, intrahistiocytic hemosiderin was observed. Mild to moderate lymphoid hyperplasia characterized by either increased production of plasma cells and/or lymphocytes was observed in two pilot whales and one dwarf sperm whale. In one of the pilot whales, RT104, the pre-scapular lymph node exhibited an aberrant hyperplastic response (pseudolymphomatous hyperplasia). Immunohistochemical stains for B and T lymphocytes indicating increased T lymphocytes, but an overall retention of lymph node architecture. In the minke whale calf, lymphocyte populations were depleted in the thymus.

Body Cavities. Within the abdominal cavity of three pilot whales (RT22, RT103, RT105) (21%, 3/14), there were variably-sized, firm nodules (granulomas). In one pilot whale, a renal-associated granuloma infiltrated the capsule and superficial renal cortex. An etiologic agent was not evident and special stains for infectious agents such as bacteria, fungus, and mycobacteria were negative.

Musculoskeletal System. Interstitial myositis, mineralization of myofibers, and formation of contraction bands were observed in three pilot whales. Contraction bands result from hypercontracted myofibers. One pilot whale had fibrosis and inflammation associated with the occipital condyle. In addition, there was necrosis of bone of the right occipital condyle.

Urinary System. Glomerular and interstitial changes were observed in three pilot whales (RT13, RT59, RT103). Interstitial nephritis was observed in two pilot whales (RT13, RT103) including the pilot whale with abdominal granulomas. Pilot whale RT59 had changes to glomeruli including thickening of basement membranes. Protein was present within tubules of one dwarf sperm whale (KMS379); in addition, Bowman's capsule was thickened in most glomeruli. One

pilot whale and one dwarf sperm whale had mineral within tubules (RT50, KMS380). Finally one pilot whale (RT68) had evidence of prior infarction characterized by loss of tubules, fibrosis, and lymphoplasmacytic inflammation. Two pilot whales (RT 49, RT66) had inflammation of the urinary bladder (cystitis).

Cardiovascular System. Fibrosis of varying severity was observed in the atrium (n=1) (RT49) and ventricles (n=2) (RT59, RT68) of three pilot whales. Atrial fibrosis and ventricular fibrosis were mild in RT49 and RT68, respectively, and multifocal and moderate in RT59. Mild perivascular infiltrates of lymphocytes and plasma cells was observed around vessels of aortic collagen fibers in pilot whale RT103 and there was localized, mild epicardial inflammation in RT50. Acute coagulative necrosis of cardiomyocytes was observed in RT12. Finally, cardiomyocyte disarray and wavy fiber formation was observed in a dwarf sperm whale KMS379.

Endocrine System. In one pilot whale, RT59, follicular cysts were present within the thyroid gland, and there was fibrosis and mineralization of the pituitary gland.

Cetaceans with Significant Histologic Findings

Three pilot whales (RT50, RT59, RT103) and one dwarf sperm whale (KMS379) had lesions in one or several organ systems that contributed to chronic debilitation and possibly death. One pilot whale, RT24, to be described in the section Histologic Findings: Cranial, had acute changes that were responsible for its demise. This section details important histologic findings and their relationship from different organ systems in the aforementioned pilot whales and dwarf sperm whales. A general summary of post-cranial histologic findings follows this section.

Significant chronic cardiovascular disease was observed in two cetaceans, pilot whale RT59 and dwarf sperm whale KMS379. Specifically, in RT59, there was loss of cardiac muscle with replacement by fibrous connective tissue and mineralization of necrotic fibers. Chronic cardiac disease can lead to affects in other organs as a resulted of hypertension or decreased perfusion including hepatic chronic passive congestion and glomerulopathy, and pulmonary congestion, hemorrhage, and interstitial fibrosis. Hepatic and glomerular changes were observed in both KMS379 and RT59; additionally, pulmonary changes were observed in KMS379. Occasional muscle fibers were “wavy”, that is thinned or attenuated and undulating. A specific cause for these cardiac changes was not identified, and lesions likely represent an end-stage process. That is, the inciting cause such as infectious agent is no longer present, or is a cause, such as nutritional or toxic, that would not be detectable by histologic examination. It is likely that this is an older female based upon the presence of age-related changes, including follicular cysts within the thyroid gland, pituitary gland fibrosis, and excessive “wear and tear” pigments within neurons of the spinal cord. There was minimal and focal inflammation in the spinal cord nerve root in this cetacean, but this was not a widespread change and not a contributing cause to cardiac disease. Prior viral infection would be a consideration. Similar to RT59, KMS379 had evidence of cardiac muscle changes, chronic passive congestion of the liver and lung, hemosiderosis, and membranous changes in renal glomeruli. Occasional cardiac muscle fibers were arranged irregularly (myofiber disarray) and other fibers were thinned. These lesions are most consistent with “*Kogia* cardiomyopathy”, a condition most often reported in pygmy sperm whales (*K. breviceps*) (Bossart 1985). The cause of this condition is not known.

Pilot whales RT50 and RT103 had lesions in the vertebral column and abdominal cavity, respectively, that likely contributed to overall health status, but were unlikely direct causes of death. Both animals were in good body condition. There was marked spondylosis of the occipital condyle and first cervical vertebral body in RT50. This degenerative lesion may have affected movement and feeding and could result in discomfort. Vertebral column spondylosis has been previously described in pilot whales (Cowan 1966; Sweeny *et al.* 2005). Degeneration of white matter tracts of the spinal cord was not observed, so motor and sensory deficits are less likely. In addition, there was necrosis of the bone of the right occipital condyle. At the time of this report, larger sections of bone are in the process of examination to determine if the necrosis is associated with an infectious organism or neoplasm. Abdominal granulomas either associated with the mesentery, uterus, or urinary bladder were observed in several animals, but were small and not likely clinically significant aside from RT103. These granulomas ranged from chronic-active to chronic and senescent. That is, in some cases, there were lymphocytes and plasma cells present which are hallmarks of chronic inflammation as well as fibrosis, while in other cases, granulomas were composed primarily of mature fibrous tissue and cellular debris indicating the primary inflammatory response was no longer present. The granulomas in RT103 were associated with the kidney and did extend into the capsule. There was associated nephritis. It is this active inflammation that may have had some negative impact upon this cetacean. Clinical pathology results also are suggestive of effect. Special stains (gram, Giemsa, Fite's Acid Fast, and GMS) for infectious agents such as bacteria, fungi, and protozoa were negative in kidney sections. The granuloma was culture positive for *Aeromonas hydrophila/caviae* (see section F. Microbiology).

Summary of Histologic Findings: Post-Cranial

Summary of raw findings have been presented in the previous section and indicate a variety of lesions in all organ systems. The majority of lesions are incidental, that is, unlikely to result in debilitation or death of an animal. Other lesions may have occurred near the time of death with associated decreased cardiovascular function. Finally, in four animals, there is evidence of clinically significant disease which led to chronic debilitation. Cardiovascular disease was present in two of these cetaceans, a pilot whale and dwarf sperm whale; musculoskeletal disease and intra-abdominal granulomas were present in the other two pilot whales. In one cetacean, acute hemorrhage in the brain was observed. This case will be described and discussed further in the section 3. Histological Findings: Cranial.

Changes that likely occurred near the time of death include pulmonary congestion and edema, hypoxic change in the white matter of the nervous system (myelin sheath swelling), lymph node edema, perivascular edema in the brain, and hepatic congestion. These represent a response to decreased cardiovascular flow, electrolyte imbalances, and hypoxia.

Incidental lesions were numerous and include verminous gastritis, pneumonia, sinusitis, granulomatous hepatitis, periportal hepatitis, mastitis, endometritis, etc. In one pregnant female, congestion of the liver led to dilation of sinusoids suggestive of (early) telangiectasia. This process may represent telangiectasia of pregnancy, which has not been reported in cetaceans previously.

3. Histologic Findings: Cranial

Tissues examined correspond to samples collected during gross head necropsies; animals that did not have a complete work-up were excluded. Specific sites examined included extramandibular fat, intramandibular fat, auditory meatus, peribullar acoustic fat, peribullar soft tissue, peribullar sinus (exudate for histopath, if present), pterygoid sinus, melon, and brain. Results of head dissections are listed in Appendix XI. Extensive head dissections were conducted at two time points, the first in February at the time of CT scanning and the second in November. Examined tissues exhibited varying degrees of autolysis and freeze-thaw artifact, including rupture of red blood cells, post-mortem fat saponification, and bacterial overgrowth.

Extramandibular Fat. In one pilot whale, there was mild perivascular hemorrhage and edema.

Intramandibular Fat. Perivascular hemorrhage was observed in 50% (4/8) pilot whales. There was autolysis of fat observed in one pilot whale.

Auditory Meatus. Samples from three pilot whales were examined with no significant histologic findings.

Peribullar Acoustic Fat. Samples from four pilot whales were examined with no significant histologic findings.

Peribullar Soft Tissue. In one pilot whale, RT50, there was a lymphoplasmacytic infiltrate (peribullitis). In another, RT106, there was superficial focal hemorrhage corresponding to a similar gross finding.

Peribullar Sinus. A post-mortem clot was present, which was also observed grossly in a pilot whale.

Pterygoid Sinus. Inflammation of the pterygoid sinus was observed in six pilot whales (RT47, RT50, RT59, RT68, RT103, RT106); in four of these pilot whales (RT50, RT59, RT68, and RT106) metazoans were present. Vascular retia were dilated in one pilot whale (RT71) and there was vascular congestion and hemorrhage in one dwarf sperm whale (KMS379).

Melon. Corresponding to grossly observed regions of peri-melon adipose thickening and semi-translucency of the soft tissue, there was collagen necrosis (RT103). Vascular thrombi were not observed.

Brain. The most striking lesion was peracute to acute subdural hemorrhage with associated neuropil spongiosis and hypoxic change in pilot whale RT24, which likely led to this animal's demise. Swelling of myelin sheaths was observed in five pilot whales (19.2%) (RT13, RT22, RT24, RT47, RT68). Perivascular edema was observed in one pilot whale (RT67). In three pilot whales (RT47, RT72, RT103), there was mild, non-suppurative encephalitis and in one pilot whale (RT59), ganglioneuritis, which was characterized by cuffing of vessels by small to occasionally moderate numbers of lymphocytes and plasma cells. A cause of encephalitis and ganglioneuritis was not determined. None of the cetaceans with encephalitis had elevated morbillivirus titers; one of the serologically positive pilot whales, RT21, did not have available

tissues. In fact, RT59, the pilot whale with ganglioneuritis, had titers less than 1:4 for canine distemper virus, dolphin morbillivirus, porpoise morbillivirus, and phocine distemper virus. Immunohistochemistry for herpesvirus, a virus that can cause ganglioneuritis, and morbillivirus was not conducted. The pilot whale with the highest morbillivirus titers (Dolphin Morbillivirus >1:256; Porpoise Morbillivirus 1:128) did not have evident encephalitis.

Summary of Findings: Cranial

Twenty-five heads were examined with nine specific anatomic locations of interest: extramandibular fat, intramandibular fat, auditory meatus, peribullar acoustic fat, peribullar soft tissue, peribullar sinus, pterygoid sinus, melon, and brain. Consistent lesions were limited to pterygoid sinusitis, which was a result of metazoan infestation. Small hemorrhages were relegated to regions around highly dense areas of vessels in the rete suggesting a source of limited diathesis. Other lesions such as peribullitis are likely a response to parasites in the peribullar sinus, though, none were observed grossly in that specific case. Encephalitis was very mild and non-specific and likely reflect exposure to an infectious agent such as a virus or bacteria (*Brucella* sp., specifically). The encephalitis was unlikely to have resulted in neurologic deficits. Hypoxic change was evident in the white matter reflecting a peri-mortem change associated with decreased oxygenation of sensitive nervous tissue structures in stranded animals with poor vascular supply. Subdural hemorrhage was observed in one pilot whale. The lesion consisted of large numbers of extravasated erythrocytes, serum, and fibrin. Fibroblasts and macrophages were not observed and in addition, erythrocytes were intact suggesting at least by human forensics, that the hemorrhage was less than 24hr old (Leetsma, 1997). Thus, this was a peracute to acute occurrence with associated damage to the brain.

The exact cause of the subdural hemorrhage is not known, but traumatic rupture is considered likely as a result of vascular shearing. Other possible etiologies include coagulative disorders, or spontaneous hemorrhage. There was no evidence of vasculitis or fibrinoid necrosis of vessels. Unfortunately, sections from other organs were not available to determine if this was a systemic process. This seems less likely given the lack of such findings on gross necropsy.

Trauma is a fairly loose term to describe injuries that may have been direct (calvarium fracture, concussive force) or those that may be secondary to blasts, sonic booms, etc. Skull fractures were not described in the gross report, and thus, this is an unlikely cause of the hemorrhage. Concussive force (contrecoup) could occur if the animal was struggling on the beach. Hemorrhage within the neuropil of the brain was not observed.

Special Investigations: Consultations, Reviews, and Special Stains

Sampling from pilot whale head tissues was completed in December 2005. Three reviews were conducted on 24 May 2005, 5 Dec 2005, and 16-17 Dec 2005 involving two full reviews (24 May 2005, 16-17 Dec 2005) and one consultation with select cases (5 Dec 2005). Reviews involved five veterinary pathologists from the United States (G. Bossart and D. Miller), Canada (S. Raverty), UK (P. Jepson), and Canary Islands (A. Fernandez). Select cases included pilot whale with subdural hemorrhage, two dwarf sperm whales, six cetaceans that had clear structures within lymph nodes (n=6) and liver (n=2) with two pilot whales having changes observed in both organs. Differentials included either normal nodal lipid, abnormal lipid (e.g., emboli), or gas

emboli. Special stains including those for fat (Oil Red O) and immunohistochemical stains for endothelium (Factor VIII) were applied with no apparent positive staining or in a few cases, eosinophilic granularity of clear spaces similar to that observed in the perinodal adipose. No hemorrhages were observed. Osmium, another fat stain which, along with Oil Red O, was utilized by Fernandez *et al.* (2005), was not employed because following the peer review of slides the consensus was that lipid emboli were not present. Consensus opinion was that these structures were normal adipocytes within the lymph node and that the absence of hemorrhage and lack of parenchymal encroachment by these structures was *not* consistent with either lipid or gas emboli formation. Therefore, these cases were *not* consistent with the widely disseminated micro-hemorrhages and systemic gas and fat emboli (*i.e.*, lesions similar to decompression sickness) described by Fernandez *et al.* (2005) in beaked whales that stranded in association with mid-frequency active sonar exposure.

In one pilot whale, there were clear structures in the liver adjacent to granulomas. These structures did not stain with Oil Red O or Factor VIII and likely represent gas-filled structures. The formation is likely associated with the granulomas representing regions of parenchymal loss and formation of gas by bacteria either from the granuloma or ascending from the gastrointestinal tract. Similarly, one dwarf sperm whale had clear vacuoles within the mesenteric lymph node that were also associated with granulomas. This cetacean also had eosinophilic enteritis. The findings in the lymph node are similar to pigs with pneumatosis intestinalis where gas from the digestive tract enters the portal circulation. While distention of the digestive tract was not reported in this dwarf sperm whale, eosinophilic enteritis was present which may be an indicator of conditions that could predispose to decreased enteric function and gas production or changes in microflora such that gas-producing bacteria ascended the portal tract.

Alternatively, changes in the mesenteric lymph node could result from migration of parasites. One pregnant pilot whale had distended sinusoids with occasional lifting of the endothelial lining. This change likely represents the process of telangiectasia, which is a pooling of blood. This has been observed in women during pregnancy, and may be of similar causation in this female. The endothelium of these distended sinusoids stained positive with Factor VIII, but was negative for collagen (VVG) and fibrin (PTAH), an acute phase protein released during the inflammatory process or bleeding. Pulmonary hemorrhage was observed in the lungs of the two dwarf sperm whales. Given the presence of cardiac disease in one, this may be an associated change and in the other, it may be a perimortem change reflecting trauma or markedly increased respiratory effort. Oil Red O stained sections of the lung were negative for the presence of lipid.

E. Summary of Gross and Histologic Findings

Gross and histologic evaluation of the pilot whales, dwarf sperm whales, and minke whale calf did not indicate a common link along the animals. The pilot and dwarf sperm whales were in good body condition; the minke whale was emaciated. There was no evidence of infection leading to systemic disease and death of these animals; any inflammatory disease observed was relegated to individual whales and not a communicable disease. Endoparasitism was a common finding in the pilot whales, and is a common finding in free-living cetaceans. Therefore, the cause of stranding based upon available gross and histologic data remains open. A handful of animals did have gross and/or histologic changes that were significant to their health status.

The minke whale calf gross findings of serous atrophy of fat, overall poor body condition, and histologic evidence of poorly developed immune organs (thymus), suggested that it likely separated from its mother, was unable to feed, and had poor immune stimulation. There are five cetaceans, four pilot whales and one dwarf sperm whale, that had evidence of chronic (three pilot whales, one dwarf sperm whale) and peracute (pilot whale) conditions that either contributed to death, caused death, or resulted in debilitation. Specifically, chronic cardiac disease was present in one pilot whale and one dwarf sperm whale. Chronic passive congestion of the liver in both cetaceans and pulmonary interstitial fibrosis, congestion, and hemorrhage in the dwarf sperm whale were further supportive evidence of cardiac disease. In these two animals, a stressful stimulus or simply a spontaneous occurrence could set the stage for cessation of myocardial function. This could have occurred within the water or at the time of stranding. Regardless, these animals had chronic cardiac disease which at some point in time would lead to their demise. One pilot whale had marked changes in the occipital region including fibrosis and osteonecrosis of the occipital bone. An underlying cause was not identified, but considerations include prior trauma, age-related degenerative disease, prior event of rapid and sharp muscle contraction leading to “snapping” of the head and unilateral fracture of the occipital bone (shearing), infection (*i.e.*, *Brucella*), and neoplasia. Since the diagnosis was based upon small fragments of examined bone owing to the lengthy decalcification process of the larger section of bone, complete assessment of the bone is ongoing. Three large intra-abdominal granulomas were observed in one pilot whale associated with the kidney; the inciting cause was not determined with special stains of the kidney sections but could include bacterial or represent sites of parasitic death, and degradation. *Aeromonas hydrophila/caviae* was cultured from the granuloma. There was ongoing inflammation at these sites which may have led to some degree of debilitation as a result of increased release of inflammation-associated cytokines.

Finally, there was subdural hemorrhage in one pilot whale with associated damage to the brain. Temporally, based upon human forensics, the presence of intact erythrocytes and the lack of fibroblasts age this lesion at less than 24 hours (Leetsma 1997). Fractures of the overlying skull and hemorrhage and edema of the overlying musculature were not observed at the time of brain removal which lessens, but does not rule out blunt trauma. Other considerations would include concussive force or contrecoup if this animal was struggling on the beach and striking its head on the bank leading to shearing of vessels. This is considered the likely scenario in this case. Non-acoustic and blast trauma were also considered based upon findings in the Bahamas and Canary Island stranding events of beaked whales, as subdural hemorrhages were observed grossly and histologically (Evans and England 2001, Fernandez *et al.* 2005). Other lesions, including changes within the ears, were observed in these specific cases and other beaked whales (Evans and England 2001) and parenchymal organs (Fernandez *et al.* 2005, Jepson *et al.* 2003, 2005). In those cases, there were hemorrhages within the neuropil which was *not* a component of this case, nor was hemorrhage observed in the brain of other necropsied animals. Post-cranial organs were not available from this case. Thus, non-acoustic and blast trauma are considered unlikely given that it occurred in only one individual and this individual did not have all histologic features previously described.

Metazoans were common in the pterygoid sinuses of pilot whales with some animals exhibiting associated changes including hyperplasia of the mucosal epithelium, submucosal hematomas, and fluid accumulation. Submucosal hematomas were observed in a dwarf sperm whale and one pilot whale without parasites, so it may have other causes including trauma or bleeding diathesis.

Migration of metazoans from the sinuses or peribullar spaces into the brain has been reported in individual and mass strandings (Morimitsu *et al.* 1987). There was no evidence grossly or histologically from examined brain sections of such a migration. Hemorrhage was observed in the intramandibular fat of some pilot whales and a dwarf sperm whale. In many of the cases, this was near the vascular rete. The implication is that because it is a concentrated vascular system, post-mortem leakage may ensue into associated tissue. This does *not* denote a cause, but rather an effect. Causes could include traumatic rupture of vascular rete walls, bleeding diathesis, or post-mortem leakage.

The majority of lesions observed were incidental, that is they did not cause debilitation or lead to stranding. Metazoans within the digestive tract for example, while having associated inflammation in four animals, likely represents background infestation. In some animals, there are very interesting lesions not significant to the stranding but of interest for life history. Included in this is the dwarf sperm whale with cystic endometrial hyperplasia and mucometra and pilot whale with pseudolymphomatous hyperplasia. Encephalitis was observed in four cetaceans, but was very mild and unlikely to result in neurologic deficits. The inflammation is not specific and an etiologic agent was not evident. Prior viral or bacterial infection is a possible cause. Other lesions observed likely occurred at the time of stranding including pulmonary edema and congestion, perivascular edema in the brain, and hypoxic change in the white matter of the brain and spinal cord.

F. Microbiology

Swabs of the blowhole and genital slit were taken from nine pilot whales, stored in Port-a-cul® transport tubes, and transported cold to the Clinical Microbiology Laboratory at the NCSU College of Veterinary Medicine, where aerobic culture was performed. Sample collection was on a Saturday and culture initiation was on a Monday. Because the swabs were taken post-mortem and sand had been forced into orifices, indicating environmental contamination of the culture sites, the results of these bacterial cultures can not be considered representative of the microbiological status of the animals while still living. They also may not be indicative of pathogenic effect, unless an obligate pathogen (*e.g.*, *Brucella* sp. from the genital slit) were cultured. Bacteria cultured from the blowholes (Appendix XIII) included *Aeromonas hydrophila/caviae*, *Aeromonas sobria*, *Burkholderia cepacia*, *Enterobacter aerogens*, *Escherichia coli*, *Klebsiella pneumoniae*, *Pseudomonas fluorescens*, and *Serratia fonticola*. Bacteria cultured from the genital slits (Appendix XIII) included *Aeromonas hydrophila/caviae*, *Aeromonas sobria*, *Enterobacter* sp., *Escherichia coli* and *Pseudomonas fluorescens*. Although these isolates can be facultative pathogens, they represent environmental bacteria or commensal organisms and were not associated with observable pathology. Most cases produced mixed cultures suggestive of environmental contamination. Given the circumstances of the sampling, they can not be ascribed causative effects in the debility of these stranded animals.

A swab was taken aseptically during necropsy from a large abscess (32 cm diameter, *i.e.*, larger than a basketball) from the abdominal cavity from RT103, and transported and processed as above. This culture yielded heavy growth of *Aeromonas hydrophila/caviae* (Appendix XIII). Because this culture was taken from an area not exposed to environmental bacterial contamination, and was directly associated with observable pathology (both gross and histologic), this represents an opportunistic facultative pathogen exerting an adverse effect. The

Table 16. Morbillivirus titers in serum from sampled pilot whales and the minke whale from UMESE0501Sp. Levels of $\geq 1:8$ are considered positive.

Field ID	Canine Distemper Virus (CDV)	Dolphin Morbillivirus (DMV)	Porpoise Morbillivirus (PMV)	Phocine Distemper Virus (PDV)
RT13	6	>256	128	6
RT21	<4	8	8	<4
RT59	<4	<4	<4	<4
RT105	<4	4	4	<4
RT49	6	96	48	6
CTH001	<4	16	6	<4

source of the infection (*e.g.*, traumatic inoculation, gastrointestinal perforation, blood-borne, parasitic) was not evident.

G. Serology

Serum samples for five pilot whales and the minke whale were tested for morbillivirus titers at the Oklahoma Animal Disease Diagnostic Laboratory. The minke whale and three of the pilot whales tested positive (titers of $\geq 1:8$) (Table 16). A single positive titer indicates an exposure to the pathogen which stimulated an immune response. It could represent an infection from which the animal has recovered or an infection which is current. Confirming a current infection would require rising titers from paired serum samples (not possible to have obtained from these animals), pathologic lesions consistent with infection (not present), virus isolation, or detection of morbillivirus antigen (*e.g.*, by immunohistochemistry) or nucleic acid (by PCR) (the latter two not indicated by pathology findings).

Members of the morbillivirus genus cause diseases such as rinderpest and measles, and are highly infectious. They have been documented in marine mammal epizootics of pinnipeds and cetaceans in both the eastern and western Atlantic and adjacent waters (Kennedy 1998), and many species of cetaceans worldwide have been found to be seropositive (Van Bresse *et al.* 2001). Saliki *et al.* (2002) identified four viruses belonging in the *Morbillivirus* genus as significant causes of disease and mortality in marine mammals: canine distemper virus (CDV) in seals and polar bears, dolphin morbillivirus (DMV) and porpoise morbillivirus (PMV) in cetaceans, and phocine distemper virus (PDV) in pinnipeds. Morbillivirus has been identified as a cause of the epizootic of bottlenose dolphins along the Atlantic coast of the U.S. in 1987-88 (Krafft *et al.* 1995, Taubenberger *et al.* 1996). It has been found in both species of pilot whales from the western Atlantic (Duignan *et al.* 1995) and a unique sequence of morbillivirus was identified in a long-finned pilot whale stranded in New Jersey (Taubenberger *et al.* 2000). Pilot whales are thought to be a reservoir for morbillivirus (Kennedy-Stoskopf 2001). Nonetheless, morbillivirus has not been linked to mass stranding of pilot whales.

In the four animals with increased morbillivirus titers, three had brain available for examination, in addition to other tissues. There was no evidence of pathognomonic histologic findings such as bronchointerstitial pneumonia, encephalitis, syncytia, lymphoid depletion, or intranuclear/intracytoplasmic inclusions. Thus, titers reflect prior exposure, but not current

disease. In addition, none of the other examined whales had evidence of active morbillivirus infection.

H. Parasitology

Parasites were collected for identification from 28 animals, including 26 short-finned pilot whales and two dwarf sperm whales. Stomach was the most common source of parasites collected (all 28 animals sampled); additional parasites were collected from the nasal/pterygoid sinuses of two pilot whales, and from an unspecified gastro-intestinal tract location of one pilot whale. Parasites were identified by Dr. James Flowers at the NCSU College of Veterinary Medicine. Although parasite collection was unsystematic and nonquantitative, Dr. Flowers did enumerate the parasites submitted for identification (Appendix XIV).

All stomachs sampled contained *Anisakis* sp. nematodes (range 1 to 290 parasites collected per animal). Other stomach parasites included a single unidentified spirurid nematode from two pilot whales, two immature unidentified trichostrongylid nematodes from one pilot whale, and one *Braunina* sp. trematode from one pilot whale. From an unspecified region of the gastrointestinal tract (but probably the duodenum) of one pilot whale, one *Bolbosoma capitatum* acanthocephalan and one *Trigonocotyle lintoni* tapeworm were collected. An additional seven *Anisakis* sp. were collected from the esophagus of a whale for which the RT identification number was not recorded. Reflux of gastric parasites into the esophagus is common in stranded cetaceans. A pseudoparasite (plant material) was collected from an unidentified location of one pilot whale.

The pterygoid sinus yielded >1000 *Stenurus* sp. nematodes and 10 *Nasitrema* sp. trematodes from one pilot whale, and >200 *Stenurus* sp. from another pilot whale.

During gross necropsies on the beach, *Phyllobothrium* sp. and *Monorygma* sp. tapeworm cysticerci were noted (Appendix XV). *Phyllobothrium* were present in ventral and peduncle blubber of four pilot whales and one dwarf sperm whale, and not present in one pilot whale and one dwarf sperm whale. *Monorygma* sp. tapeworm cysticerci were noted present in the abdominal cavity around urogenital structures or along the inner abdominal wall in 13 pilot whales, and not present in one dwarf sperm whale. During head necropsies of 23 pilot whales and two dwarf sperm whales, metazoan parasites (presumably a combination of *Stenurus* sp. and *Nasitrema* sp.) were noted in peribullar and pterygoid sinuses of 19 pilot whales, usually associated with sinusitis when examined histologically.

In addition to gross observations above, parasite-associated esophagitis in four pilot whales and one dwarf sperm whale, and verminous pneumonia in three pilot whales were noted histologically, but were considered mild.

These parasite species, locations and loads are not unusual to find in cetaceans stranded for other known causes (Abollo *et al.* 1998, Gibson *et al.* 1998, Cornaglia *et al.* 2000, Daily 2001). *Anisakis* nematodes are commonly found in small cetaceans (*e.g.*, Uglund *et al.* 2004) and recently a new species was identified from both species of *Kogia* from the western Atlantic (Mattiucci *et al.* 2005). In a mass stranding of 30 pilot whales in Florida in 1986, Bossart *et al.* (1991) reported nematodes (probably *Stenurus* sp.) and *Nasitrema* in the middle ears in five of

ten whales examined. Although parasite migration into and destruction of parts of the central nervous system have been implicated as causes of some strandings (Walsh *et al.* 2001), no histologic evidence (*e.g.*, parasite cross sections, parasite eggs, migration tracks, associated inflammation) was found in the brains examined to support that possibility in UMESE0501Sp.

I. Toxicology

Toxicology for anthropogenic contaminants and natural biotoxins is pending. As noted earlier, however, there were no harmful algal blooms during the winter of 2004-2005 along the Atlantic coast south of the Chesapeake Bay.

J. CT Scans of Heads

Computerized tomography (CT) scans were conducted on the detached frozen heads of two pilot whales and the two adult dwarf sperm whales at NCSU. Interpretation of the scans is pending.

Comparison of Biomedical Findings

A. Individual and Multiple Strandings of *Globicephala*, *Kogia*, and *B. acutorostrata*

1. Published Reports

We examined peer-reviewed papers on strandings of pilot whales, dwarf sperm whales, and minke whales, single and mass strandings, specifically with reference to causes of stranding or death. Appendix XVI lists the species, location, date, number of animals involved, cause if known, and citation for stranding events.

Pilot Whales

Pilot whale strandings have been reported on both coasts of the United States (Hall *et al.* 1971; Geraci and Aubin, 1977; Higgins *et al.* 1980; Dawson *et al.* 1985; Morimitsu *et al.* 1987; Duigan *et al.* 1995; Mazzuca *et al.* 1999) involving either individual or multiple animals. In most the strandings, the cause was either not determined (Geraci and St. Aubin 1977; Dawson *et al.* 1985) or speculated to involve factors such as geomagnetism (Mazzuca *et al.* 1999) or geophysical and climatic factors (Hall *et al.* 1971). McFee (1990) analyzed historical records of natural and drive-fishery-induced strandings of long-finned pilot whales on Cape Cod, Massachusetts, dating from 1620 to 1990, in relation to weather and topography, and compiled data for 87 natural strandings involving approximately 5670 animals.

Mortality as a result of infectious disease has been less commonly reported and includes verminous cranial nerve eight neuropathy (Morimitsu *et al.* 1987) in a mass stranding and streptococcal pneumonia in a single stranded pilot whale (Higgins *et al.* 1980). In many of the reports, gross and histologic findings were not indicated. In one stranding event (Hall *et al.* 1971), bacterial isolates were obtained from the lung but a description of pathologic changes was not indicated.

There are reports of pathogens that were either isolated or with an indication of exposure via serology. These include Influenza A (Hinshaw *et al.* 1986) without reported histologic lesions, *Brucella* (Jepson *et al.* 1997), and morbillivirus (Duignan *et al.* 1995). The findings of Duignan *et al.* (1995) indicated that morbillivirus infection is enzootic in the western Atlantic and that pilot whales may serve as a reservoir species. In that report, there was a single calf with active viral infection involving the lung; a similar finding to Taubenberger *et al.* (2000) in a female pilot whale with a novel morbillivirus.

Four reports are oriented towards a discussion of clinical pathologic data or gross and histologic findings regarding either multisystemic findings (Cowan 1966; Bossart *et al.* 1991; Walsh *et al.* 1991) or a single system (Moore and Stegeman 1996, Sweeny *et al.* 2005). Three of these papers encompass stranded cetaceans (Bossart *et al.* 1991, Walsh *et al.* 1991; Sweeny *et al.* 2005) and one encompasses animals caught by drive fishery (Cowan 1966).

Cowan (1966) examined 55 long-finned pilot whales (26 females and 29 males). Histologic lesions were identified in all systems. In the cardiovascular system, there was inflammation and fibrosis, basophilic degeneration, and parasitic infection. Inflammatory lesions involved macrophages or granulocytes (neutrophils) and were identified in 11 pilot whales. An infectious agent was not identified. Basophilic degeneration, which was characterized by the presence of irregular basophilic structures within individual cardiomyocytes, was observed in 31 pilot whales examined, predominantly in young animals and with no associated inflammatory reaction. This is considered an age-related change when observed in human hearts (Spencer 1950). Occasional sarcocysts (protozoa) were observed within myocardial fibers. In the respiratory system, there was gross evidence of nematodes within the bronchial tree with reaction ranging from none visible to granulomatous. Non-parasite-associated inflammation was observed in several of the lungs with or without fibrosis. In the digestive system, common gross findings included dental attrition and verminous gastritis. Findings in the liver and pancreas were limited to mild periportal inflammation and pancreatic cysts in two animals. Genitourinary lesions included occasional mineral within the tubules of the kidney and one whale with glomerulosclerosis. A single leiomyoma was found in the myometrium in an old female. In the lymphoreticular system, there was granulomatous splenitis in three pilot whales, and lymph node edema, mild hyperplasia, and granulomatous lymphadenitis in one pilot whale. Endocrine changes were limited to the thyroid gland and included two pilot whales with a granulomatous reaction to colloid and four animals with macrofollicular goiter. Superficial scars and cestodes within the blubber were common. Fibrosed abscesses were observed in the skeletal muscle of occasional animals. Musculoskeletal systems changes included anomalies such as differences in the length of the transverse vertebral process, failure of closure of vertebral arches, and block vertebrae in two pilot whales. Osteoarthritis involving vertebral bodies was also observed. Overall, Cowan (1966) concluded that none of the observations were considered significant, *i.e.*, that the whale would not have exhibited clinical disease at that state of disease progression.

Bossart *et al.* (1991) examined 10 of 33 short-finned pilot whales that stranded off the Atlantic coast of Florida in July 1986. Gross findings presented were limited to the middle ears where trematodes and nematodes were observed in 5 pilot whales. Histologic findings included verminous gastritis, pneumonia, myocarditis, fatty livers, and depletion of lymphoid organs and adrenocortical lipid. Walsh *et al.* (1991) reported medical findings in the same group of animals,

which included increased respiratory and heart rates, hemoglobin, fibrinogen, creatinine, bilirubin, glucose, lactate dehydrogenase, alanine aminotransferase, and aspartate aminotransferase, and decreased WBC (with left shift), alkaline phosphatase, calcium and phosphorus. They concluded that the majority of animals involved in the stranding were clinically ill based upon clinical pathologic and histologic findings.

Moore and Stegeman (1996) examined rate of autolysis in the livers of 18 long-finned pilot whales from four mass strandings on Cape Cod in 1990 and 1991. They found that extreme autolysis occurred in as little as 4 hr post-mortem, but that hepatocyte vacuolation could still be discerned through the autolysis and that degree of vacuolation was independent of autolysis.

Recently, Sweeny *et al.* (2005) described spondylitic changes in long-finned pilot whales stranded off of Cape Cod, Massachusetts. Animals examined included those from 14 reported mass strandings and 56 single strandings in the New England (McFee 1990, Wiley *et al.* 2001). Of these pilot whales, 52 skeletons were examined. Eleven (nine female and two male) of the 52 pilot whales had evidence of osseous changes which included minor osteophytes and ankylosis of vertebral bodies. There was not a predilection for location along the vertebral chain; cervical, thoracic, lumbar, and caudal vertebrae were affected. The authors consider the effect that these vertebral changes would have upon mobility.

Pygmy and Dwarf Sperm Whales

A cardiomyopathy of unknown cause has been described in pygmy and dwarf sperm whales (Bossart *et al.* 1985). Grossly, affected whales have pale, flabby right ventricles and congested livers. Histologic changes observed in the heart included cardiomyocyte disarray, degeneration, and fibrosis. Hepatic changes are the result of chronic cardiovascular disease and included centrilobular congestion and centrilobular hepatocyte loss or atrophy. The only other reported condition was struvite penile urethrolithiasis in a pygmy sperm whale from North Carolina (Harms *et al.* 2004).

Minke Whales

Reports of disease were limited to a single stranding in Italy briefly described as part of a larger discussion of cetacean strandings on the Italian coast between 1990 and 1993 (DiGuardo *et al.* 1995). The minke whale was an adult male that had bronchopneumonia, keratoconjunctivitis, encephalitis, lymphadenitis, and gastroenteritis. This minke whale had a titer for canine distemper virus. While morbillivirus inclusion bodies were not identified, the histologic findings and serology were suggestive of morbillivirus infection.

2. Individual and Mass Strandings: Unpublished Reports

We reviewed unpublished pathology reports for individual and mass strandings of pilot whales, dwarf and pygmy sperm whales, and minke whales, primarily from North Carolina. In addition, we were able to review unpublished cases of pilot whales from Massachusetts. We note that comprehensive examination of cranial structures has not been routinely performed until recently, so these data are generally minimal or lacking in the stranding reports.

Pilot Whales

North Carolina and Virginia Cases. From 2003 to 2004, two pilot whales stranded in North Carolina and one pilot whale stranded in Virginia were examined. Perioral dermatitis with associated ciliates was observed in one pilot whale and may have resulted in diminished feeding. Gross findings of emaciation in another pilot whale suggested maternal separation and starvation. There was glossitis (inflammation of the tongue) which may have contributed to decreased feeding or been the result of ingested food material or foreign body. One pilot whale did not have a determined cause of death, but did have incidental findings, including pterygoid sinusitis and verminous enteritis.

Massachusetts Cases. Reports were examined from eight individual strandings and two mass strandings of long-finned pilot whale responded to by the Cape Cod Stranding Network. Gross findings were available for all cases, but histologic findings for only two of the cases. Bacterial peritonitis was the cause of death in one whale. In the other case, a cause of death was not identified. However, there was an epinephrine-associated necrosis of cardiac muscle fibers. This cardiac lesion has been observed in stranded cetaceans and is believed to be a stress-related response (Turnbull and Cowan 1998) and other species. In remaining cases, no distinct cause of death was identified. Observed gross lesions included verminous gastritis, periorchitis, and pneumonia.

In a July 2000 mass stranding, necropsies were conducted by the New England Aquarium Stranding Program on nine male long-finned pilot whales. Tissues collected for histologic examination were available for eight of them. Samples were processed and then examined in March 2006 (DSR). Grossly, parasitic infestation was observed in the blubber and stomach of three pilot whales. Tracheobronchiolar froth was observed commonly and is consistent with an agonal death. Gastric contents were scant to absent in nearly all of the pilot whales. One pilot whale had an intrabdominal abscess and cardiac pallor (whitening). There were histologic correlates including steatitis (inflammation of the adipose) and myocardial fibrosis and attenuation (atrophy) of fibers. This pilot whale, in contrast to the others in the group that stranded, likely had significant disease which could have contributed to stranding or debilitation. Other common histologic findings included pulmonary edema, mild to moderate lymphoid depletion in the lymph nodes and spleen, and testicular atrophy in all of the males. Other less common lesions included one pilot whale with membranous glomerulopathy, a result of immune complex deposition on glomeruli. It likely did not result in decreased renal function as there was no evidence of protein with tubules, an indicator of decreased glomerular filtration. Additional findings of interest include macrofollicles in the thyroid gland of one pilot whale and myelin degeneration in the spinal cord of another pilot whale. Endocrine and nervous system changes were not described grossly. Overall, only the pilot whale with cardiovascular disease had a pre-existing condition that could have contributed to stranding; other findings in the stranded pilot whales were incidental and not contributory to stranding or clinically significant disease.

Another mass stranding of 57 pilot whales occurred in July 2002. Over the course of several days, some animals were euthanized due to a poor prognosis or were pushed back to sea. Unfortunately, in the end, nearly all of the animals re-stranded and either died naturally or were euthanized. Eleven animals were necropsied. Gross findings were indicated in four animals and included “no visible lesions” in one, verminous gastritis in one, uterine nodules in one, and

lacerations of the tail fluke in one. Histologic findings generated by Armed Forces Institute of Pathology (AFIP) and obtained from animal records from Cape Cod Stranding Network included myocardial fibrosis (n=2), verminous pneumonia (n=1), tortuous uterine vessels (n=1), and intramysial sarcocysts. None of these lesions was considered a cause of stranding or death. Overall, the cause of the stranding was not determined

Dwarf and Pygmy Sperm Whales

Strandings of dwarf and pygmy sperm whales in North Carolina typically have involved individual animals. In pygmy sperm whales, we observed the following: cardiomyopathy or lesions associated with cardiomyopathy (n=3), emaciation (n=4), a uterine leiomyoma (n=1), subdural hemorrhage (n=1), urethrolithiasis (n=1, Harms *et al.* 2004), humeral subluxation and chronic joint disease (1), and gastric abscess (n=1). Among the dwarf sperm whales, granulomatous pneumonia was observed in one animal and acute, terminal heart failure was observed in another, but these were not considered contributing causes to stranding.

Minke Whales

Clinical pathology and necropsy findings from one minke whale calf were examined. This animal was thin, leukopenic, hyperglycemic, and had elevated intra-ocular glucose. Histologically, there was hypoplasia of the adrenal cortex and lymphoid depletion suggesting it may have been premature or had poor immune stimulation. In addition, there was formation of cataracts in both eyes, likely secondary to the hyperglycemia and high intra-ocular glucose concentrations.

3. Comparison of UMESE0501Sp to Published and Unpublished Cases

The purpose of gross and histologic examination of tissues is to determine if there is an underlying cause of the stranding, such as infection, degenerative disease, or toxicity, in concert with other ancillary diagnostics such as virology, toxicology, and microbiology. Comparing findings from UMESE0501Sp to other strandings of these species provides a means of placing our findings in context with other strandings. The findings of Cowan (1966) are of particular interest as they represent examination of non-stranded cetaceans, and therefore, a random selection of animals. Overall, there are difficulties with comparisons of strandings from different locations stemming from variation in descriptions and interpretations of gross and histologic findings among individuals. This does not negate a comparison, but rather indicates where differences may lie.

Pilot Whales. The cause of the stranding could not be determined for the individual cases from North Carolina (perioral dermatitis and possible inanition) mass strandings in Massachusetts (2000 and 2002) and UMESE0501Sp. Population-wide infectious disease was not detected. Individual animals from the July 2000 stranding in Massachusetts and UMESE0501Sp did have evidence of clinically significant disease involving the cardiovascular system or presence of inflammation in the peritoneal cavity stemming from intra-abdominal granulomas. In contrast, the July 1986 stranding in Florida (Bossart *et al.* 1991) was likely associated with systemic disease in chronically ill pilot whales. The Florida stranding, from a pathologic perspective, had

commonality of lesions in many animals, which was not the case for the whales examined from Massachusetts and UMESE0501Sp.

Cardiovascular changes were found in pilot whales from all three locations (Florida, Massachusetts, and North Carolina). Myocardial fibrosis was the common histologic finding in pilot whales with cardiac changes; it ranged from mild to severe. This condition may reflect an age-related change or prior myocarditis. Ages were not available for these cases, so a comparison of age to lesions observed could not be done. Less frequently, intra-abdominal granulomas were observed in pilot whales from the July 2000 Massachusetts stranding and UMESE0501Sp, as well as an individual pilot whale from Massachusetts. These granulomas ranged from incidental lesions observed at necropsy to those resulting in peritonitis and, in the individual stranded pilot whale from Massachusetts, septicemia.

Other findings in stranded pilot whales from Florida, Massachusetts, and North Carolina were considered incidental, that is, not resulting in clinically significant disease. Incidental lesions included thyroid follicular cysts, granulomatous lymphadenitis, periportal hepatitis, lymphoid depletion, verminous pterygoid sinusitis (or grossly, pterygoid sinus metazoans), and cestodes in blubber and the abdominal cavity. Endoparasitism was also a common finding and is expected in free-living whales. Degenerative vertebral disease has recently been described by Sweeny *et al.* (2005) from unearthened pilot whale vertebrae from Massachusetts and by Cowan (1966). While a comparison of this change cannot be made completely because vertebrae from the UMESE0501Sp were buried deeply and have not been examined, there was a single pilot whale with significant occipital condyle osteonecrosis and fibrosis. An effect upon mobility was likely. Sweeny *et al.* (2005) propose that these lesions limit mobility in these animals.

Conditions identified in one or more pilot whales from North Carolina that were not described in the other locations included: endometritis, pituitary gland fibrosis and mineralization, renal infarct, perioral dermatitis, lymphoid hyperplasia (pseudolymphomatous hyperplasia), and mastitis. These conditions are considered incidental findings.

Dwarf Sperm Whales. Findings in the two dwarf sperm whales from UMESE0501Sp did not differ greatly from what has been observed in other dwarf sperm whales and pygmy sperm whales from North Carolina and other locations in the mid-Atlantic. Specifically, cardiac and other systemic changes consistent with a recognized, but currently unexplained, cardiomyopathy were observed in one dwarf sperm whale. Uterine changes that included cystic endometrial hyperplasia, mucometra, and adenomyosis in the female dwarf sperm whale from UMESE0501Sp was an interesting incidental finding. There have been no peer reviewed reports of adenomyosis in marine mammals.

Minke Whale. The minke whale calf from UMESE0501Sp and the unpublished minke whale calf case were similar in that both were in poor nutritional condition. Both of these calves likely represented maternal separation of dependent calves.

B. Strandings Associated with Use of Military Sonar

Military sonar activities immediately preceding UMESE0501Sp emphasized the need for an evaluation of whether the stranding was due to sonar. Tissue sampling and evaluation has been conducted for three recent stranding events associated with use of sonar during military operations: in the Bahama Islands in March 2000, in the Canary Islands in September 2002, and in Puget Sound in May 2003. The first event, in the Bahamas Island in March 2000, involved 17 individuals from four species (nine Cuvier's beaked whales, *Ziphius cavirostris*, three Blainville's beaked whales, *Mesoplodon densirostris*, two unidentified beaked whales, two minke whales, and a spotted dolphin, *Stenella frontalis*) found stranded within a 36-hour period (Evans and England 2001). The strandings were coincident with naval activity involving tactical mid-frequency sonar. At least seven of the animals are known to have died because those carcasses were recovered. Five beaked whales and the spotted dolphin were necropsied. In addition to gross and histopathologic assessment, CT scanning of ears was performed. Hemorrhage was a consistent finding, including periotic, in four beaked whales. Associated auditory structural damage was supported by CT scans and histopathology. In addition, two of the fresher animals had antemortem bilateral intracochlear and unilateral temporal region subarachnoid hemorrhage. The report notes that the hemorrhages would not necessarily have been fatal nor have caused permanent hearing loss in terrestrial mammals. The result of hemorrhage on affected sites could result in compromised hearing or navigational abilities, further resulting in disorientation and possibly the subsequent stranding. Recently, Ketten (2005) released a technical report detailing gross necropsy and CT scan findings in beaked whales stranded in Puerto Rico, Bahamas, and Madiera from 1999-2002. Cases from Madiera had gross lesions and CT findings similar to the Bahamas cases (Ketten 2005). In three beaked whales, small hemorrhages (petechiae and ecchymoses) in the acoustic fats along the jaw and in the melon were present. The preliminary report of the investigation team concluded that the cause of stranding for the beaked whales was the confluence of the Navy tactical mid-range frequency sonar, the physiography of the area where the operations were occurring, intensive active use of multiple sonar over an extended period of time, and beaked whales' sensitivity to the sonar frequencies in use (Evans and England 2001). The spotted dolphin and minke whales were spatially separated from the beaked whales and the acoustic source. In addition, the spotted dolphin was in poor body condition and showed evidence of chronic disease and no auditory trauma. It was considered to have stranded independently of the naval operations. The minke whales were alive when stranded and were returned to the ocean so the cause of stranding was unknown. Minke whale strandings are not common in the Bahamas, however.

The second event, in the Canary Islands in September 2002, involved 14 beaked whales, including Cuvier's beaked whale, Blainville's beaked whale, and Gervais' beaked whale (*M. europaeus*) (Martin *et al.* 2004, Fernandez *et al.* 2005). The stranding was coincident with a naval exercise employing mid-frequency sonar. Ten whales were necropsied and found to have in common hemorrhage or congestion in the central nervous system, acoustic jaw fat, pharyngeal and laryngeal serosae, lungs, kidney, and periocular region. Lymph node lesions included large numbers of erythrocytes within subcapsular and sinusoidal spaces as well as vacuoles in the subcapsular sinuses. Ears were not examined. Fernandez *et al.* (2005) provide evidence that the whales stranded and subsequently died due to a decompression sickness-like disease characterized by systemic microhemorrhages and gas and fat emboli and induced by exposure to mid-frequency sonar.

The third event occurred in May 2003 when an abnormally high number of strandings of harbor porpoise in the eastern Puget Sound coincident with mid-frequency sonar use by the naval vessel *USS SHOUP* (Norman *et al.* 2004). At the time the vessel was transmitting, observers witnessed killer whales (*Orcinus orca*) and a minke whale “porpoising” from the area as the vessel approached. Norman *et al.* (2004) reported that researchers operating hydrophones in Haro Strait recorded acoustic signals identified as mid-frequency tactical sonar and that NMFS received additional reports from witnesses that the sonar sound was audible above water. While 10 of 15 porpoises reported stranded or floating were necropsied, eight were in moderate to advanced states of decomposition, hampering interpretation of cause of death. Still, Norman *et al.* (2004) suggested cause of death for five porpoises, including blunt force trauma in two cases and chronic disease in three cases. All animals had some degree of congestion or red discoloration of the meninges, calvarium or cerebral surface, which they attributed to postmortem autolysis and repeated freeze-thaw effects. The examinations did not reveal definitive signs of decompression sickness-like lesions in any of the porpoises examined, *e.g.*, emboli consistent with *in vivo* nitrogen gas bubble formation (Jepson *et al.* 2003, 2005, Fernandez *et al.* 2005). Thus, there was not a distinct association between pathology findings and sonar as the causal agent for the stranding of harbor porpoises. However, investigators noted that the possibility of sonar activity as a contributory factor could not be ruled out because the moderate to poor condition of carcasses precluded a thorough investigation.

Ante-mortem fat and gas emboli similar to those found in the beaked whales from the Canary Island event were found in post-mortem tissues from cetaceans stranded along British coasts between October 1990 and March 2004 (Jepson *et al.* 2005). Emboli occurred in four of 24 Risso’s dolphins (*Grampus griseus*), four of 393 common dolphins (*Delphinus delphis*), the sole Blainville’s beaked whale, and one of 1,195 harbor porpoise (*Phocoena phocoena*) examined. They noted that the highest prevalence occurred in the deeper diving species, the beaked whale and Risso’s dolphins. These results indicate that the type of lesions associated with gas and fat embolism in beaked whales also occur in small cetaceans, even those not associated with deep diving. Nonetheless, the cause of these lesions has not been established.

In April 2004, the U.S. Marine Mammal Commission convened a technical (scientific) workshop in Baltimore to examine the global phenomenon of beaked whale mass strandings linked to mid-frequency naval sonar activity, and to discuss the potential/hypothetical mechanisms underlying these stranding events. The workshop concluded that a decompression sickness-like mechanism involving gas (and fat) embolism in response to sonar exposure was a particularly plausible mechanism for beaked whale mass strandings linked to sonar exposure (Cox *et al.* in press). Gas embolism in response to active sonar could be induced either behaviorally via acoustically-altered dive profiles leading to excessive nitrogen supersaturation driving *in vivo* bubble formation, or by direct physical expansion of microscopic gas bubble precursors (gas nuclei) in nitrogen supersaturated tissues directly ensonified by acoustic energy of sufficient received sound pressure levels (Houser *et al.* 2001, Fernandez *et al.* 2005, Jepson *et al.* 2005, Cox *et al.* in press). Both (behavioral and direct physical) mechanisms of bubble generation could occur simultaneously, and are likely to induce similar lesions including hemorrhage in sensitive (lipid-rich) tissues and formation of systemic gas or fat emboli. The origin of the gas and lipid is not known, but two proposed sites include nitrogen dissolved in lipid-rich tissues (*e.g.* brain, spinal cord, acoustic fats) and intestinal gas. In the case of the latter, intestinal gases could travel into

the hepatic vasculature resulting in the formation of large gas emboli. Gas emboli can result in an acute exacerbation of clinical signs or, if chronic, can lead to formation of fibrous capsules within or around the affected region (Jepson *et al.* 2005).

Gas emboli lesions similar to those found in the beaked whales (Fernandez *et al.* 2005) or in the small cetaceans (Jepson *et al.* 2005), which were considered consistent with but not diagnostic for sonar-associated strandings, were not found in the whales stranded as part of UMESE0501Sp. An initial assessment of tissues indicated the presence of clear structures within the lymph nodes that could represent normal adipocytes, fat, or gas emboli. Hemorrhage was not associated and these structures were not within subcapsular sinuses. Review of these changes resulted in a consensus opinion that these were resident adipocytes in the lymph node. In two pilot whales, there were small foci of clear spaces associated with inflammation; these are considered to be associated with the inflammatory process likely through gas production by bacteria. Hemorrhage was an uncommon finding, including one animal with moderate subdural hemorrhage (and no evidence of gas or fat emboli) and a few animals with acoustic fat hemorrhage. In the latter animals, the hemorrhage was typically near the vascular rete suggesting a possible site of origin for erythrocyte extravasation. Localization to this site may reflect an antemortem occurrence or post-mortem hypostatic congestion or leakage of erythrocytes. Continued assessment of stranded cetaceans, including position and evidence of struggling prior to death, is needed to determine its significance. In addition, animals with this hemorrhage did not have evidence of laryngeal hemorrhage, subdural hemorrhage, or other hemorrhage. There was no evidence of hepatic emboli and evidence of hemorrhage in the liver was limited to a pregnant female with dilated hepatic sinusoids (early telangiectasia) and dwarf sperm whale with cardiomyopathy and associated chronic passive congestion. Emboli, either acute or chronic, were not observed.

Differential Diagnoses and Final Diagnoses

A. Differential and Final Diagnoses from Clinical and Pathological Results

Overall, commonality of gross and histologic lesions was lacking (*e.g.*, chronic and acute system failure, hemorrhage, infection) that would indicate a single cause for UMESE0501Sp. Infectious disease in the pilot whales included endoparasitism involving the digestive tract and pterygoid sinuses most commonly. However, parasitism is not an uncommon finding in pilot whales and other cetaceans. Bacterial or viral infection that would lead to systemic disease, death, and transmission of infectious agents was not observed. This includes the presence of viral inclusions, viral-associated inflammation, cellular necrosis, neoplasia, or lymphoproliferative conditions, bacterial infection, fungal infection, or protozoal infection. No harmful algal blooms occurred along the east coast south of the Chesapeake during January 2005.

Individual causes of death could be the result of an acute condition, including metabolic and electrolyte imbalances, which is likely in all of the live-stranded cetaceans. Or, in the case of a pregnant female pilot whale (RT24), subdural hemorrhage is considered to have resulted in neurologic dysfunction and death. The subdural hemorrhage, based upon human forensic dating of diatheses, was peracute to acute as fibrocytes and macrophages were absent relegating a chronic response unlikely. The cause of this hemorrhage was considered to be traumatic and

could have occurred on the beach if the animal struggled and repeatedly struck its head. Three adult female pilot whales and one adult male dwarf sperm whale were considered to have clinically significant chronic disease. The disease included chronic cardiac disease in one pilot whale (RT59) and one dwarf sperm whale (KMS379), intra-abdominal granulomas in one pilot whale (largest measuring 31 cm x 32 cm x 32 cm) (RT103), and occipital joint spondylosis and occipital condyle necrosis (RT50). Cardiovascular compromise in a stressed, stranded animal would likely hasten its demise and any stressors in the environment could lead to cardiovascular failure and subsequent stranding of a compromised animal. The minke whale calf likely stranded as a result of starvation and subsequent metabolic derangement associated with separation from its mother. The cause of this separation, *e.g.*, maternally-associated or externally-associated, cannot be determined.

The population of stranded pilot whales was predominantly female (21/27). Of the 21 females, 15 were adults. Of those 15 females, about 25% (4/15) had significant chronic disease, and 6% (1/15) had an acute condition that either were the cause of death or contributed to the cetaceans' overall health status. Overall, however, the pathologic evidence available did not conclusively determine a specific cause of UMESE0501Sp.

B. Conclusions Regarding Active Military Sonar Transmissions

From the information provided to NMFS regarding the presence of high-power acoustic sources in the general vicinity of UMESE0501Sp, several conclusions may be reached. First, it appears that the stranding was not caused by direct exposure or behavioral reaction to construction blasting or military live fire ordinance. Second, it appears extremely unlikely if not impossible given the spatial proximity that active sonar transmissions from the Kearsarge ESG on 13-15 Jan 2005 played any role in UMESE0501Sp; therefore these transmissions should not be considered correlated with it.

Known active sonar transmissions over the three-day period prior to the onset of UMESE0501Sp were generally quite limited in terms of the number of vessels, duration of exposure, and spatial scale of sound propagation. These sonar events involved single ships transmitting for periods of minutes and covering a few tens of kilometers. We also note the general dissimilarity between the operational/environmental characteristics as they were reported to NMFS in these active sonar transmissions and those known to exist in previous incidents in which active sonar played a role in the stranding of marine mammals. For instance, UMESE0501Sp lacked the constricted-channel environmental features and presence of multiple ships transmitting simultaneously over multiple hours as occurred in the Bahamas stranding event in 2000 (Evans and England, 2001). We also note the routine nature of the known active sonar transmissions over the time and area of UMESE0501Sp.

While we view these factors as weakening the evidence for a relationship between the 12-14 Jan 2005 active, mid-frequency tactical sonar transmissions and UMESE0501Sp, it is not possible to conclude definitively that they played no role. The transmissions occurred in an area surrounding the site of the stranding events, over a period of days sufficient for animals reacting behaviorally to sonar transmissions to reach the stranding location. It is likely that active sonar transmissions were detectable during that period, cumulatively, over some hundreds of square kilometers in the vicinity of the stranding location. Again, it is not possible to precisely estimate

the sound levels animals in the area may have received. However, this issue is to some extent a moot point, as animals in the immediate vicinity of the vessels themselves could have traveled to the stranding location by the time they were first reported.

It should be clearly stated that based on the information available regarding active sonar transmissions, it is not possible to state definitively that active sonar played any role whatsoever in UMESE0501Sp. Our interpretation of the available information is that the known active sonar transmissions of individual surface vessels during the 12-14 Jan 2005 timeframe were spatially and temporally associated with UMESE0501Sp and, while the evidence is not particularly compelling in this regard, may not be ruled out as a potential causative factor.

C. Overall Diagnosis

In general, strandings may occur as a result of a single or multiple factors including infectious disease, toxic exposures, anthropogenic activity, climate, physiography, or, most commonly, are without a known cause. It has been speculated that mass strandings may result in social species when the group cohesion causes part or the entire group following one key animal (Robson 1984), probably ill, member to the beach. Observations at mass strandings support the maintenance of group cohesion under the adverse conditions surrounding a stranding, especially for pelagic species that form stable social groups. For example, Dawson *et al.* (1985) described for a mass stranding of 143 long-finned pilot whales in New Zealand that “Throughout our rescue attempts we found it futile to push individuals into deeper water, as they would immediately circle back and rejoin the others on the beach. We found that the whole group had to be moved together.” If the mass stranding of pilot whales during UMESE0501Sp was due to herd sociality, we are unable to demonstrate that was the case because, at the least, the animals were already on the beach dead or in the surf when found. It is possible that one of the compromised animals, such as RT 50, 59, or 103, was the key animal and was followed to the beach. The dwarf sperm whales may also have come ashore together because one animal was compromised. That would have occurred as a distinct event to the pilot whales, resulting in these strandings being simply coincidental. We noted earlier that the probability of these strandings being independent is low. It has also been suggested that strandings occur on gently sloping sandy beaches because these conditions distort the animals’ sonar and they become disoriented (Dudok van Heel 1962). This hypothesis has been disputed (Geraci 1978, Odell 1987) although recent simulations suggest that echolocation signals are distorted by geometric effects due to gently sloping shallow bottom topography producing acoustical “dead zones” (Sundaram *et al.* 2006). Even if true, those beach characteristics are common along the coast of North Carolina and so this explanation does not satisfactorily explain the close proximity of the strandings. Other unsubstantiated or poorly supported possible causes of stranding have been suggested (see discussion in Bradshaw *et al.* 2006). It is possible that oceanographic conditions were largely responsible for disorientation of the pilot whales, and maybe the dwarf sperm whales, and that prevailing currents resulted in the locations of the strandings.

As we have discussed, UMESE0501Sp was associated in time and space with naval activity using mid-frequency active sonar. It also had a number of features in common (*e.g.*, the “atypical” distribution of strandings involving multiple offshore species, all stranding alive, and without evidence of common infectious or other disease process) with other sonar-related cetacean mass stranding events. Given that UMESE0501Sp was the only stranding of offshore

species to occur within a 2-3 day period in the region on record (*i.e.*, a very rare event), and given the occurrence of UMESE0501Sp simultaneously in time and space with a naval exercise using active sonar, the association between the naval sonar activity and the location and timing of UMESE0501Sp could be a causal rather than a coincidental relationship.

It is important to acknowledge that our understanding of the effects of anthropogenic acoustic activity on marine mammals is still in its infancy. Unlike tests for chemical pollutant (*e.g.*, PCBs) exposure, there are no laboratory analyses that can determine the nature and history of anthropogenic acoustic (noise) exposure in any stranded marine mammals. In addition, potential lesions induced by noise exposure are poorly understood and documented in most marine mammal species. If cetacean stranding events can be induced directly by behavioral avoidance of noise exposure (*i.e.*, without secondary lesions such as gas emboli developing in affected individuals), the carcasses of stranded individuals will probably not show any lesions other than those pre-existing before the acoustic exposure together with those generated by the pathophysiological consequences of stranding alive.

In summary, the cause of UMESE0501Sp involving pilot whales, dwarf sperm whales, and a minke whale is not definitively known. As noted above, we did not find commonality in gross and histologic lesions that would indicate a single cause for this stranding event. We do think that even if the pilot and dwarf sperm whale strandings could be related, the minke whale stranding was just coincidental. On the basis of examination of physical evidence in the affected whales, we cannot definitively conclude that there was or was not a causal link between anthropogenic sonar activity or oceanographic conditions (or a combination of these factors) and the strandings. Given the immense effort expended to understand the cause of this event, these non-demonstrable possibilities are unsatisfying.

Further Tests and Investigations Planned

Some additional testing or analysis is planned to investigate factors that may have been involved in the event:

- Analysis of levels of polychlorinated biphenyls, chlorinated pesticides, and brominated diphenyl ether congeners will be conducted by the National Institute of Standards and Technology laboratory in Charleston, SC. Results are expected by the end of 2006;
- Analysis for biotoxins toxicology will be conducted by NOAA's Ocean Service Marine Biotoxin Group in Charleston, SC. Results are expected by the end of 2006.

Following an interpretation of the CT scans, histologic assessment of earbone will be done if warranted (*e.g.*, lesions observed with CT). Reasons for this two step process involve the extensive decalcification process, which will take 1.5 years to complete, and exhaustive sectioning protocols. In addition, given the field necropsy working conditions, number of animals, and available personnel, only two sets of ears were collected during the weekend of the necropsies and those were collected 48 hours or more post-mortem. Remaining ears were collected post-freeze/thaw cycles and after a degree of autolysis had occurred; therefore, histologic evaluation may be marred by significant artifact. Thus, the information that would be yielded may be less than optimal, while the time and cost are high.

Additional analysis are planned to better understand the biology of the individuals that stranded:

- Analysis of stable isotope ratios for feeding strategy and location of the whales in the months prior to the stranding;
- Age estimation from teeth; and
- Blubber analysis at UNC Wilmington.

Impact on Affected Populations

Given the history of strandings of short-finned pilot whales, dwarf sperm whales, and minke whales, if the strandings were due to natural mortality it seems unlikely that UMESE0501Sp had a significant impact on the populations. If the strandings were human-caused, however, they would contribute to mortality that is included under the potential biological removal level (PBR). The Marine Mammal Protection Act defines PBR as “the maximum number of animals, not including natural mortalities, that may be removed from a marine mammal stock while allowing that stock to reach or maintain its optimum sustainable population” (OSP) (MMPA Sec. 3. 16 U.S.C. 1362; Wade and Angliss 1997). PBR is a product of the minimum population size, one half the maximum net productivity rate, and a recovery factor for endangered, threatened, or depleted stocks, or stocks of unknown status relative to optimum sustainable population. PBR is calculated by NMFS for each NMFS-managed species for which there is an acceptable estimate of abundance; PBRs are available in the Stock Assessment Reports.

The mostly recently published PBR for pilot whales for western North Atlantic *Globicephala* sp. is 108 (Waring *et al.* 2002). As noted above, surveys in 2004 resulted in new, higher estimates of abundance that are pending review. The PBR calculated from the new abundance estimate is 249 (NMFS unpub data, provisional pending review). While the PBR will increase as a result in an increase in estimated abundance, estimated mortality in commercial fishing gear also increased to an average of 115 whales annually. A Pelagic Longline Take Reduction Team has been convened to identify ways to reduce takes of pilot whales in longlines in the western Atlantic. It is notable that neither mortality nor abundance can be allocated to species of pilot whales. Impacts on the short-finned pilot whale population await determination of species-specific abundance and human-caused mortality.

The most recently published PBR for western North Atlantic *Kogia* sp. is 4.7 (Waring *et al.* 2003). In contrast to pilot whales, the 2004 surveys resulted in a decrease in estimated abundance with a concurrent decrease in PBR to two (NMFS unpub data, provisional pending review). If the two strandings on 16 Jan 2005 were human caused, the annual PBR was reached. If the calf that was found on 19 Jan 2005 was part of the event, as we assume it was, then PBR was exceeded.

The mostly recent available PBR for the Canadian east coast minke whale is 35 (Waring *et al.* 2003), although NMFS is proposing to reduce it to 26 (provisional pending review) because the minke whale population is of unknown status. As noted above, from 1997 to 2001, the average annual human-caused mortality was 3.6 minke whales per year in the U.S. (Waring *et al.* 2003); a more current estimate is not available. It is unlikely that the status of the stock will change if the stranding on 15 Jan 2006 was due to human causes.

Table 17. Observations and recommendations garnered from this event that might be helpful for enhanced response during other mass-stranding events. Taken from Lovewell and Hohn (2005).

Obstacles

- Rehabilitation, release, or relocation were not an option due to the conditions and location of event
- Weather -- low temperatures, drizzle, strong winds, and wind chill posed hypothermia risk
- Distribution of animals along 10 km of beach required dispersion of people and supplies
- Carcasses below the high tide line required immediate relocation or loss
- Communication among teams was difficult, due to limited cell phone coverage on the Outer Banks
- Extreme weather and narrow beaches hindered response
- Securing and disposing of euthanized carcasses was a major concern

What Worked Well

- Large number of willing participants who dropped everything to travel 4-6 hours for the response
- Establishing necropsy leaders and assigning teams
- Clear, defined goals set for sampling - these goals drove the response
- Distribution of supplies and datasheet packets to each team
- Having extra supplies and food to replenish teams in the onsite coordinator's vehicle as she drove the beach
- Moving the animals to a central location
- Collecting stomachs and heads for later dissection

20:20 Hindsight

- Move animals to centralized location above high tide on Day One
- Include examination of heads for possible acoustic effects
- Ensure ability for communication among teams over long distances
- Assign individual identifiers (*e.g.*, rototag) to every animal immediately
- Don't forget the basics -- completing datasheets, good labeling practices

Recommendations from Dierauf & Gulland 2001 Geraci & Lounsbury 1993, and Touhey *et al.* 2004 (pers. comm.) that we endorse on the basis of this experience

- People first! Do not attempt a response until conditions are safe
- Use the Incident Command System (ICS) -- although we did not need all the roles outlined by ICS, the onsite, offsite and media coordinators were invaluable, allowing responders to focus on the task at hand
- Careful sample labeling is essential, no label equals no sample, yet in the moment of the event it can be overlooked
- Rapidly evaluate live animals and make euthanasia determinations
- Properly dispose of euthanized animals to avoid environmental hazards

Lessons Learned/Recommendations

- Our goal was to conduct a thorough evaluation of each carcass to explain the event; that goal determined our sampling protocols
 - Use of non-controlled substances (sedatives) at high doses was a good alternative to euthanasia if the carcass couldn't be secured from washing away or scavengers
 - If acoustic activity might be a cause of the event, heads should be examined immediately
 - All probable causes of the event need to be considered, regardless of the public pressure to focus on one
 - Ensure key teams or individuals can talk to each other to coordinate, especially if the event is dispersed
 - Teams of 4-5 people per animal was remarkably effective for conducting thorough necropsies
 - Each team systematically walked through data collection needs and protocols, including morphometrics, human interaction and sampling
 - Debrief at the end of each day and develop strategies for the following day
 - Have a system in place to promptly reimburse responders.
-

Recommendations for the Future

Given the magnitude, location, and environmental conditions under which this event occurred, it is easy now to think “if only we’d...” and then add whatever could have been done but wasn’t. From this experience, Lovewell and Hohn (2005) listed obstacles and recommendations that might improve the response to future mass strandings under similar circumstances (Table 17). Additional on-site improvements include making blood smears, the use of a portable centrifuge to separate serum, and the use of a portable clinical chemistry analyzer. Expedient submission of blood samples from live-stranded animals to established analytical laboratories should be a priority. With regard to data collection, we have two specific recommendations. First, it is important to record notes on all tissues examined. When nothing is recorded, it is not possible to know when analyzing results if that means a tissue was not examined or whether that tissue had no visible lesions. Second, review of data sheets on site will help identify incomplete (including not recorded) data fields or samples not collected.

As environmental conditions and stressors become increasingly complex, the ability to interpret their effects becomes concurrently complex. Efforts should focus on ways to improve monitoring, sample collection, development of new techniques, and increased communication between specialists to achieve the most thorough exploration of stranding events. This approach would also benefit analysis of single-stranding events in order to conduct baseline monitoring. One relevant example is that we do not have baseline data on the prevalence of hemorrhaging in acoustic tissues in stranded cetaceans. It is this consistent and constant tabulation and analysis of findings that will provide an understanding of background population diseases, be they infectious or clinically significant chronic debilitating conditions or acoustic-induced affects.

Nonetheless, the response to this event illustrated the dedication of stranding network members and other scientists to responding to strandings with a goal of understanding why these events occur.

Acknowledgments

We are grateful to the many individuals involved in the response, both on the beach and off, to the reviewers of the histology slides for sharing their expertise to ensure our interpretations were corroborated, and to reviewers of the draft report whose comments resulted in substantial improvements to the report. They are listed individually in Appendices I, XVII, and XVIII, respectively.

Members of the Cetacean and Sea Turtle (CAST) Team at the NOAA lab in Beaufort were instrumental throughout the process, from stranding response to finalizing of the report. In particular, Gretchen Lovewell and Emma Jugovich entered and maintained data in spreadsheets, were responsible for dissemination and tracking of the many samples collected, assisted with editing and fact-checking of the report, proof-read the final draft, and assisted with response to a massive FOIA request that required a significant amount of time away from working on the analysis and report. In addition, they were available for many other small, but unending, requests. Annie Gorgone filled in to assist with the above tasks as needed. Eric Griffith helped with the statistical analysis. Barbie Byrd served as media contact on the beach and immediately afterwards, allowing us to focus on the necropsies and sample processing. Patti Haase generated the GIS plots of strandings. Wendy Cluse scanned all datasheets and created PDF files.

Assistance from other NOAA and Agency partners were also necessary for the response and analysis. It was fortuitous that the strandings occurred on a National Park or Seashore because the assistance of the supervisors, rangers, and other staff were crucial in the successful beach response to this event. Overflights to ascertain the spatial extent of the strandings were conducted by the NPS, and by the U.S. Coast Guard and Coast Guard Auxiliary (courtesy of CAPT Roderick Ansley, Air Station Elizabeth City, NC, and RADM Sally Brice-O'Hara, Commander, Fifth Coast Guard District). Trevor Spradlin, NOAA NMFS Office of Protected Resources (OPR), helped get responders reimbursed and served as liaison between our work and the Working Group on Marine Mammal Unusual Mortality Events. Teri Rowles, OPR, provided invaluable suggestions and advice throughout the post-event response and analysis. The NMFS Northeast Regional Office provided information on recent UMEs in the northeast U.S. Laura Engleby, NMFS Southeast Regional Office, assisted with media response during and after the stranding and in preparation for release of the report. John Christianson, Varis Ransi, Alec Richardson, and Susan Dunham from NOAA's NOS Center for Coastal Monitoring and Assessment, and Michael Coyne, from Duke University and seaturtle.org, assisted with SST, current data and plots. Wind data were obtained with assistance from Thomas Kriehn, Meteorologist-in-Charge, NOAA's National Weather Service, Newport, NC. Wind plots were made by Joshua Watson, NOAA's National Weather Service, Scientific Services Division, Eastern Regional Headquarters, Bohemia, NY. Pat Tester and Wayne Litaker, NOAA's National Ocean Service, Beaufort Laboratory, provided information on harmful algal blooms.

Dee Allen, Smithsonian Institution, provided historical stranding data for pilot whale mass strandings from the Smithsonian Cetacean Distribution Database. We appreciate Ridge Microtome and the NCSU Histology Lab for expedient processing of excellent quality slides. We thank the New England Aquarium Stranding Program and Cape Cod Stranding Network for providing information and samples from strandings on the shores of Massachusetts for comparison of our samples. We also appreciate advice during the event from Katie Touhey, Cape Cod Stranding Network, which she gleaned from mass stranding experience in Cape Cod. In addition to the authors, the pilot whale and dwarf sperm whale heads were examined by staff and students from NCSU College of Veterinary Medicine (Terra Kelly, Robert McLean, and Allison Tuttle), UNC Wilmington (Michelle Barbieri, Cally Harper, Heather Koopman, Bill McLellan, Erin Meagher, Ann Pabst, Andrew Westgate, and Zoey Zahorodny, as well as other stranding network volunteers who were able to donate time), Duke University (Ari Friedlaender and Andrew Westgate), and the CAST Team (Gretchen Lovewell and Rachel LoPiccolo). Stomachs were examined by staff and students from Duke University (Caroline Good, Vanessa Jordán Sardi, Vicky Thayer, and Danielle Waples) and the CAST Team (Barbie Byrd, Brandi Biehl, Rachel LoPiccolo, and Gretchen Lovewell). Microbiology was performed by Carol Lemons, NCSU. Parasite identification and counting was performed by James Flowers, NCSU.

Partial support for this stranding response came from the NOAA Fisheries John H. Prescott Marine Mammal Rescue Assistance Grant Program awards to Craig Harms (NA04NMF4390040) and to Ann Pabst and Bill McLellan (NA03NMFS4390411). Support for sample processing and on-site expenses for non-government responders was from the UME fund at the National Fish and Wildlife Foundation.

Literature Cited

- Abollo, E., A. López, C. Gestal, P. Benavente, and S. Pascual. 1998. Macroparasites in cetaceans stranded on the northwestern Spanish Atlantic coast. *Diseases of Aquatic Organisms* 32(3): 227-231.
- Anderson, D., D. McGillicuddy Jr., D. Townsend, and J. Turner. 2005. The ecology and oceanography of toxic *Alexandrium fundyense* blooms in the Gulf of Maine – Preface. *Deep Sea Research Part II: Topical Studies in Oceanography* 52(19-21): 2365-2368.
- Björge, A. 2001. How persistent are marine mammal habitats in an ocean of variability?: Habitat use, home range and site fidelity in marine mammals. pp. 63-92 *In*: P.G.H. Evans and J.A. Raga, eds. *Marine Mammals: Biology and Conservation*. New York, NY, Kluwer Academic. 626 pp.
- Bossart, G.D., D.K. Odell, and N.H. Altman. 1985. Cardiomyopathy in stranded pygmy and dwarf sperm whales. *J. Am. Vet. Med. Assoc.* 187(11): 1137-1140.
- Bossart, G.D., T.H. Reidarson, L.A. Dierauf, and D.A. Duffield. 2001. Clinical pathology. pp. 383-436 *In*: L.A. Dierauf and F.M.D. Gulland, eds. *CRC Handbook of Marine Mammal Medicine*, 2nd ed. Boca Raton, FL, CRC Press. 1063 pp.
- Bossart, G.D., M.T. Walsh, D.K. Odell, J.D. Lynch, D.O. Beuse, and W.G. Young. 1991. Histological findings in a mass stranding of pilot whales (*Globicephala macrorhynchus*) in Florida. pp. 85-90 *In*: J.E. Reynolds and D.K. Odell, eds. *Marine Mammal Strandings in the United States: Proceedings of the Second Marine Mammal Stranding Workshop; 3-5 December 1987*. U.S. Dep. Commer., NOAA Tech. Report NMFS 98. 157 pp.
- Brabyn, M.W. and I.G. McLean. 1992. Oceanography and coastal topography of herd-stranding sites for whales in New Zealand. *J. Mamm.* 73(3): 469-476.
- Bradshaw, C.J.A., K. Evans, and M.A. Hindell. 2006. Mass cetacean strandings – a plea for empiricism. *Conservation Biology*. Only available online at the time of completion of this report. <http://www.blackwell-synergy.com/toc/cbi/0/0>.
- Churchill, J.H. and P.C. Cornillon. 1991. Gulf Stream water on the shelf and upper slope north of Cape Hatteras. *Continental Shelf Research* 11(5): 409-431.
- Cornaglia, E., L. Rebora, C. Gili, and G. Di Guardo. 2000. Histopathological and immunohistochemical studies on cetaceans found stranded on the coast of Italy between 1990 and 1997. *J. Vet. Med. A. Physiol. Pathol. Clin. Med.* 47(3): 129-142.
- Costa, D.P., and T.M. Williams. 2000. *Marine Mammal Energetics*. pp. 176-217. *In*: J. Reynolds and J. Twiss, eds. *The Biology of Marine Mammals*. Washington, DC, The Smithsonian Institution Press.
- Cowan, D.F. 1966. Pathology of the pilot whale. *Arch. Path.* 82: 178-189.
- Cox, T.M., T.J. Ragen, A.J. Read, E. Vos, R.W. Baird, K. Balcomb, J. Barlow, J. Caldwell, T. Cranford, L. Crum, A. D'Amico, G. D'Spain, A. Fernández, J. Finneran, R. Gentry, W. Gerth, F. Gulland, J. Hildebrand, D. Houser, T. Hullar, P.D. Jepson, D. Ketten, C.D. MacLeod, P. Miller, S. Moore, D. Mountain, D. Palka, P. Ponganis, S. Rommel, T. Rowles, B. Taylor, P. Tyack, D. Wartzok, R. Gisiner, J. Mead, and L. Benner. In press. Understanding the Impacts of Anthropogenic Sound on Beaked Whales. *J. Cet. Res. Man.*

- Daily, M.D. 2001. Parasitic diseases. pp. 357-379. *In*: L.A. Dierauf and F.M.D. Gulland, eds. CRC Handbook of Marine Mammal Medicine, 2nd ed. Boca Raton, FL, CRC Press. 1063 pp.
- Dawson, S.M., S. Whitehouse, and M. Williscroft. 1985. A mass stranding of pilot whales in Tryphena Harbour, Great Barrier Island. *Investigations of Cetacea* 17: 165–173
- DiGuardo, G., U. Agrimi, G. Morelli, G. Cardeti, G. Terracciano, and S. Kennedy. 1995. Post mortem investigations on cetaceans found stranded on the coasts of Italy between 1990 and 1993. *Vet. Record* 136: 439-442.
- Dudok van Heel, W.H. 1962. Sound and Cetacea. *Netherlands Journal of Sea Research* 1: 407-507.
- Doucette G.J., A.D. Cembella, J.L. Martin, J. Michaud, T.V.N. Cole, and R.M. Rolland. 2006. Paralytic shellfish poisoning (PSP) toxins in North Atlantic right whales *Eubalaena glacialis* and their zooplankton prey in the Bay of Fundy, Canada. *Marine Ecology Progress Series* 306: 303-313.
- Duignan, P.J., C. House, J.R. Geraci, G. Early, H.G. Copeland, M.T. Walsh, G.D. Bossart, C. Cray, S. Sadove, D.J. St. Aubin, and M. Moore. 1995. Morbillivirus infection in two species of pilot whales (*Globicephala* sp.) from the western Atlantic. *Marine Mammal Science* 11: 150-162.
- Evans, D. and G. England. 2001. Joint Interim Report: Bahamas Marine Mammal Stranding Event of 15-16 March 2000. 59 pp. http://www.nmfs.noaa.gov/pr/pdfs/health/stranding_bahamas2000.pdf
- Evans, P.G.H. and I. Stirling. 2001. Life history strategies of marine mammals. pp. 7-62 *In*: P.G.H. Evans and J.A. Raga, eds. *Marine Mammals: Biology and Conservation*. New York, NY, Plenum Press/Kluwer Academic. 630 pp.
- Fernandez, A., J.F. Edwards, F. Rodriguez, A. Espinosa de los Monteros, P. Herraiez, P. Castro, J.R. Jaber, V. Martin, and M. Arbelo. 2005. Gas and Fat Embolic Syndrome Involving a mass stranding of beaked whales (Family Ziphiidae) exposed to anthropogenic sonar signals. *Vet. Pathol.* 42: 446-457.
- Evans, K., R. Thresher, R.M. Warneke, C.J.A. Bradshaw, M. Pook, D. Thiele, and M.A. Hindell. 2005. Periodic variability in cetacean strandings: links to large-scale climate events. *Biol. Letters* 1:147-150.
- Flagg, C.N., L.J. Pietrafesa, and G.L. Weatherly. 2002. Springtime hydrography of the southern Middle Atlantic Bight and the onset of seasonal stratification. *Deep Sea Research II: Topical Studies in Oceanography* 49(20): 4297-4329.
- Friedlander, A.S., J.G. Mead, C.W. Potter, D. Allen, and V.G. Thayer. 2005. Historic and recent mass stranding events of short-finned pilot whales (*Globicephala macrorhynchus*) on the U.S. Atlantic and Gulf of Mexico coasts. Abstract and Poster for SEAMAMMS conference. Available from Ari Friedlander at Duke University Marine Laboratory, 135 Pivers Island Road, Beaufort, NC 28516, asf7 at duke.edu.
- Garrison, L.P. 2003. Estimated bycatch of marine mammals and turtles in the U.S. Atlantic pelagic longline fleet during 2001-2002. U.S. Dep. Commer., NOAA Tech. Memo. NMFS-SEFSC-515, 52 pp. Available from NMFS, Southeast Fisheries Science Center, 75 Virginia Beach Road, Miami, FL 33149.

- Garrison, L.P., S.L. Swartz, A. Martinez, C. Burks, and J. Stamates. 2003. A Marine Mammal Assessment Survey of the Southeast US Continental Shelf: February – April 2002. NOAA Technical Memorandum NMFS-SEFSC-492. 50pp.
- Garrison, L.P. and P.M. Richards. 2004. Estimated bycatch of marine mammals and turtles in the U.S. Atlantic pelagic longline fleet during 2003. U.S. Dep. Commer., NOAA Technical Memorandum NMFS -SEFSC-527, 57 pp. Available from NMFS, Southeast Fisheries Science Center, 75 Virginia Beach Road, Miami, FL 33149.
- Geraci, J.R. 1978. The enigma of marine mammal strandings. *Oceanus* 21: 38-47.
- Geraci, J.R. and D.J. St. Aubin. 1977. Mass stranding of the long-finned pilot whale, *Globicephala melaena*, on Sable Island, Nova Scotia. *J. Fish. Res. Board Can.* 34: 2196-2199.
- Greer, L.L., J. Whaley, and T.K. Rowles. 2001. Euthanasia. pp. 736-737 *In*: L.A. Dierauf and F.M.D. Gulland, eds. *CRC Handbook of Marine Mammal Medicine*, 2nd ed. Boca Raton, FL, CRC Press. 1063 pp.
- Gibson, D.I., E.A. Harris, R.A. Bray, P.D. Jepson, T. Kuiken, J.R. Baker and V.R. Simpson. 1998. A survey of the helminth parasites of cetaceans stranded on the coast of England and Wales during the period 1990-1994. *Journal of Zoology* 244: 563-574.
- Hamazaki, T. 2002. Spatiotemporal prediction models of cetacean habitats in the mid-western North Atlantic Ocean (from Cape Hatteras, North Carolina, to U.S.A. to Nova Scotia, Canada). *Marine Mammal Science* 18(4): 920-939.
- Hall, J.D., W.G. Gilmartin, and J.L. Mattson. 1971. Investigation of a Pacific pilot whale stranding on San Clemente Island. *J. Wildl. Dis.* 7: 324-327.
- Harms, C.A., R.E. LoPiccolo, D.S. Rotstein, and A.A. Hohn. 2004. Struvite penile urethrolithiasis in a pygmy sperm whale, (*Kogia breviceps*). *J. Wildl. Dis.* 40: 588-593.
- Higgins, R., R. Claveau, and R. Roy. 1980. Bronchopneumonia caused by *Streptococcus equi* in a north Atlantic pilot whale (*Globicephalus melaena*). *J. Wildl. Dis.* 16: 319-321.
- Hinshaw, V.S., W.J. Bean, J. Geraci, P. Fiorelli, G. Early, and R.G. Webster. 1986. Characterization of two Influenza A viruses from a pilot whale. *J. Virol.* 58: 655-656.
- Houser, D.S., R. Howard, and S. Ridgway. 2001. Can diving-induced tissue nitrogen supersaturation increase the chance of acoustically driven bubble growth in marine mammals? *Journal of Theoretical Biology* 213(2): 183-195.
- Jepson, P.D., M. Arbelo, R. Deaville, I.A.R. Patterson, P. Castro, J.R. Baker, E. Degollada, H.M. Ross, P. Herraes, A.M. Pocknell, E. Rodriguez, F.E. Howie, A. Espinosa, R.J. Reid, J.R. Jaber, V. Martin, A.A. Cunningham, and A. Fernandez. 2003. Gas-bubble lesions in stranded cetaceans. *Nature* 425: 575-576.
- Jepson, P.D., S. Brew, A.P. MacMillan, J.R. Baker, J. Barnett, J.K. Kirkwood, T. Kuiken, I.R. Robinson, and V.R. Simpson. 1997. Antibodies to Brucella in marine mammals around the coast of England and Wales. *Vet. Record.* 141: 513-515.

- Jepson, P.D., R. Deaville, I.A.P. Patterson, A.M. Pocknell, H.M. Ross, J.R. Baker, F.E. Howier, R.J. Reid, A. Colloff, and A.A. Cunningham. 2005. Acute and chronic gas bubble lesions in cetaceans stranded in the United Kingdom. *Vet. Pathol.* 42: 291-305.
- Jordán Sardi, V., D.P. Gannon, N.B. Barros, and A.J. Read. 2005. Stomach contents of mass-stranded short-finned pilot whales (*Globicephala macrorhynchus*) from North Carolina. Abstract submitted for the 16th Biennial Conference on the Biology of MM in San Diego, CA Dec 12-16, 2005.
- Kennedy, S. 1998. Morbillivirus infections in aquatic mammals. *J. Comp. Pathol.* 119(3): 201-225.
- Kennedy-Stoskopf, S. 2001. Viral diseases. pp. 285-307. *In:* L.A. Dierauf and F.M.D. Gulland, eds. *CRC Handbook of Marine Mammal Medicine*, 2nd ed. Boca Raton, FL, CRC Press. 1063 pp.
- Ketten, D.R. 2005. Beaked whale necropsy findings for strandings in the Bahamas, Puerto Rico, and Madeira, 1999-2002. WHOI Tech. Report WHOI-2005-09. 34 pp.
- Krafft, A., J.H. Lichy, T.P. Lipscomb, B.A. Klaunberg, S. Kennedy and J.K. Taubenberger. 1995. Postmortem diagnosis of morbillivirus infection in bottlenose dolphins (*Tursiops truncatus*) in the Atlantic and Gulf of Mexico epizootics by polymerase chain reaction-based assay. *J. Wildl. Dis.* 31: 410-415.
- Leestma, J.E. 1997. Forensic Neuropathology. pp. 425-475 *In:* H.H. Garcia, eds. *Neuropathology: The Diagnostic Approach*. St. Louis, MO, Mosby Press. 824 pp.
- Lentz, S.J., R.T. Guza, S. Elgar, F. Feddersen, and T.H.C. Herbers. 1999. Momentum balances on the North Carolina inner shelf. *J. of Geophysical Research* 104: 18205.
- Lovewell, G.N. and A.A. Hohn. 2005. Mass Stranding of Pilot Whales in North Carolina during January 2005: Lessons that may Enhance Collection of Data and Samples during Future Mass Strandings. Abstract and Poster for National Marine Mammal Stranding Network Conference, April 3-7, 2005. Lansdowne, VA. Available from Gretchen.Lovewell at noaa.gov., NOAA Fisheries Service 101 Pivers Island Rd. Beaufort, NC 28516.
- Martin, V., A. Servidio, and S. García. 2004. Mass strandings of beaked whales in the Canary Islands. pp. 33-36 *In:* P.G.H. Evans, and L.A. Miller, eds. *Proceedings of the Workshop on Active Sonar and Cetaceans*. European Cetacean Society Newsletter, No. 42 (Special Issue).
- Mattiucci, S., G. Nascette, M. Dailey, S.C. Webb, N.B. Barros, R. Cianchi, and L. Bullini. 2005. Evidence for a new species of *Anisakis* Dujardin, 1845: morphological description and genetic relationships between congeners (Nematoda: Anisakidae). *Systematic Parasitology* 61: 157-171.
- Mazzuca, L., S. Atkinson, B. Keating, and E. Nitta. 1999. Cetacean mass strandings in the Hawaiian Archipelago, 1957-1998. *Aquat. Mammals* 25: 105-114.
- McFee, W.E. 1990. An analysis of mass strandings of the long-finned pilot whale, *Globicephala melaena*, on Cape Cod. M.S. Thesis. Northeastern University, Boston, MA. 96 pp.
- Medway, W. and J.R. Geraci. 1986. Clinical pathology of marine mammals. pp. 791-797 *In* M.E. Fowler eds. *Zoo and Wild Animal Medicine*, 2nd ed. Philadelphia, PA, WB Saunders. 1127 pp.

- Mitchell, E.D. 1991. Winter records of the minke whale (*Balaenoptera acutorostrata* Lacépède 1804) in the southern North Atlantic. Rep. Int. Whal. Commn. 41: 455-457.
- Moore, M.J. and J.J. Stegeman. 1996. Hepatocyte vacuolation and autolytic changes in the liver of pilot whales, *Globicephala melas*, stranded on Cape Cod, MA, USA. Sci. Tot. Envir. 186: 105-108.
- Morgan, L.W., W. Van Bonn, E.D. Jensen, and S.H. Ridgway. 1999. Effects of in vitro hemolysis on serum biochemistry values of the bottlenose dolphin (*Tursiops truncatus*). J. Zoo. Wild. Anim. Med. 30: 70-75.
- Morimitsu, T., T. Nagai, M. Ide, H. Kawano, A. Naichuu, M. Koonoo, and A. Ishii. 1987. Mass stranding of Odontoceti caused by parasitogenic eight cranial neuropathy. J. Wildl. Dis. 23: 586-590.
- Mullin, K.D. and G.L. Fulling. 2003. Abundance of cetaceans in the southern U.S. North Atlantic Ocean during summer 1998. Fish. Bull. 101: 603-613.
- Norman, S.A., S. Raverty, W. McLellan, D. Pabst, D. Ketten, M. Fleetwood, J.K. Gaydos, B. Norberg, L. Barre, T. Cox, B. Hanson, and S. Jeffries. 2004. Multidisciplinary investigation of stranded harbor porpoises (*Phocoena phocoena*) in Washington State with an assessment of acoustic trauma as a contributory factor (2 May – 2 June 2003). U.S. Dep. Commerce, NOAA Tech. Memo. NMFS-NWR-34, 120 p. <http://www.nmfs.noaa.gov/pr/pdfs/acoustics/porpoise.pdf>.
- Odell, D.K. 1987. The mystery of marine mammal strandings. Cetus 7: 2-6.
- Pietrafesa, L.J., G.S. Janowitz, and P.A. Wittman. 1985. Physical oceanographic processes in the Carolina Cape. pp. 23-32 In: L.P. Atkinson, D.W. Menzel, and K.A. Bush, eds. Oceanography of the southeastern U.S. continental shelf. Washington, DC, American Geophysical Union, Coastal and Estuarine Sciences 2.
- Pietrafesa, L.J., J.M. Morrison, M.P. McAnn, J. Churchill, E. Böhm, and R.W. Houghton. 1994. Water mass linkages between the Middle and South Atlantic Bights. Deep Sea Research 41: 365-389.
- Rennie, S.E., J.L. Largier, and S.J. Lentz. 1999. Observations of a pulsed buoyance current downstream of Chesapeake Bay. J. of Geophysical Research 104: 18227-18240.
- Robson, F.D. 1984. Strandings: Ways to Save Whales. Angus and Robertson Publishers, Sydney, Australia. 199 pp.
- Rutledge, G.K., J. Alpert, and W. Ebisuzaki. 2006. NOMADS: A climate and weather model archive at the National Oceanic and Atmospheric Administration. Bulletin of the American Meteorological Society 87: 327-341. <http://ams.allenpress.com/pdfserv/10.1175%2FBAMS-87-3-327>
- Saliki, J.T., E.J. Cooper and J.P. Gustavson. 2002. Emerging morbillivirus infections of marine mammals. Ann. NY, Acad. Sci. 969: 51-59.
- Scott, M.D., A.A. Hohn, A.J. Westgate, J.R. Nicolas, B.R. Whitaker, and W.B. Campbell. 2001. A note on the release and tracking of a rehabilitated pygmy sperm whale (*Kogia breviceps*). J. Cetacean Res. Manage. 3(1): 87-94.
- Sergeant, D.E. 1963. Minke Whales, *Balaenoptera acutorostrata* Lacépède, of the Western North Atlantic. J. Fish. Res. Bd. Canada, 20(6): 1489-1504.

- Spencer, H. 1950. Mucoïd degeneration of the heart muscle. *J. Path. Bact.* 62: 653.
- Sundaram, B., A.C. Poje, R.R. Veit, and H. Nganguia. 2006. Acoustical dead zones and the spatial aggregation of whale strandings. *J. Theoretical Biology* 238: 764-770.
- Sweeny, M.M., J.M. Price, G.W. Jones, T.W. French, G.A. Early, and M.J. Moore. 2005. Spondylitic changes in long-finned pilot whales (*Globicephala melas*) stranded on Cape Cod, Massachusetts, USA, between 1982 and 2000. *J. Wildl. Diseases* 41(4): 717-727.
- Taubenberger, J.K., M.M. Tsai, T.J. Atkin, T.G. Fanning, A.E. Krafft, R.B. Moeller, S.E. Kodosi, M.G. Mense, and T.P. Lipscomb. 2000. Molecular genetic evidence of a novel morbillivirus in a long-finned pilot whale (*Globicephalus melas*). *Emerging Infectious Diseases* 6 (1). <http://www.cdc.gov/ncidod/eid/vol6no1/taubenberger.htm#10>
- Taubenberger, J.K., M.M. Tsai., A.E. Krafft, J.H. Lichy, A.H. Reid, F.Y. Schulman, and T.P. Lipscomb. 1996. Two different morbilliviruses implicated in bottlenose dolphin epizootics. *Emerg. Infect. Dis.* 2: 213-216.
- Tester, P. and K. Steidinger. 1997. *Gymnodinium breve* red tide blooms: initiation, transport, and consequences of surface circulation. *Limnol. Oceanogr.* 42(5, part 2): 1039-1051.
- Tizard, I.R. 1996. pp. 44-45. *In: Veterinary Immunology*, 5th ed. Philadelphia, PA, WB Saunders.
- Tryland, M. and E. Brun. 2001. Serum chemistry of the minke whale from the northeastern Atlantic. *Journal of Wildlife Diseases* 37: 332-341.
- Turnbull, B.S. and D.F. Cowan. 1998. Myocardial contraction band necrosis in stranded cetaceans. *J. Comp. Pathol.* 118: 317-327.
- Ugland, K.I., E. Strømnes, B. Berland, and P.E. Aspholm. 2004. Growth, fecundity and sex ratio of adult whaleworm (*Anisakis simplex*; Nematoda, Ascaridoidea, Anisakidae) in three whale species from the North-East Atlantic. *Parasitol. Res.* 92: 484-489.
- Van Bresse, M., K.V. Waerebeek, P.D. Jepson, J.A. Raga, P.J. Duignan, O. Nielsen, A.P. Di Benedetto, S. Siciliano, R. Ramos, W. Kant, V. Peddemors, R. Kinoshita, P.S. Ross, A. Lopez-Fernandez, K. Evans, E. Crespo, and T. Barrett. 2001. An insight into the epidemiology of dolphin morbillivirus worldwide. *Vet. Microbiol.* 81(4): 287-304.
- Varela, R.A. and G.D. Bossart. 2005. Evaluation of biochemical analytes in vitreous humor collected after death in West Indian manatees. *J. Am. Vet. Med. Assoc.* 226: 88-92.
- Wade, P.R. and R.P. Angliss. 1997. Guidelines for assessing marine mammal stocks: Report of the GAMMS Workshop April 3-5, 1996, Seattle, Washington. U.S. Dep. Commer., NOAA Tech. Memo. NMFS-OPR-12. 93 pp.
- Walker, R.J., E.O. Keith, A.E. Yankovsky, and D.K. Odell. 2005. Environmental correlates of cetacean mass stranding sites in Florida. *Marine Mammal Science* 21(2): 327-335.
- Walsh, M.T., D. Beuse, W.G. Young, J.D. Lynch, E.D. Asper, and D.K. Odell. 1991. Medical findings in a mass stranding of pilot whales (*Globicephala macrorhynchus*) in Florida. pp. 75-83 *In: J.E.*

Reynolds and D.K. Odell, eds. Marine Mammal Strandings in the United States: Proceedings of the Second Marine Mammal Stranding Workshop; 3-5 December 1987. U.S. Dep. Commer., NOAA Tech. Report NMFS 98. 157 pp.

Walsh, M.T., R.Y. Ewing, D.K. Odell, and G.D. Bossart. 2001. Mass strandings of cetaceans. pp. 83-96
In: L.A. Dierauf and F.M.D. Gulland, eds. CRC Handbook of Marine Mammal Medicine, 2nd ed. Boca Raton, FL, CRC Press. 1063 pp.

Waring, G.T, J.M. Quintal, and C.P. Fairfield eds. 2002. U.S. Atlantic and Gulf of Mexico Marine Mammal Assessments - 2002 . NOAA Technical Memorandum NMFS-NE-169. vii+328.

Waring, G.T, R.M. Pace, J.M. Quintal, C.P Fairfield, and K. Maze-Foley, eds. 2003. U.S. Atlantic and Gulf of Mexico Marine Mammal Stock Assessments NOAA Technical Memorandum NMFS-NE-182 vii + 287 + 4 app.

Wiley, D.N., G. Early, C.A. Mayo, and M.J. Moore. 2001. Rescue and release of mass stranded cetaceans from beaches on Cape Cod, MA, USA, 1990-1999: A review of some responsive actions. *Aquatic Mammals* 27: 162-171.

Appendices

- Appendix I. Individuals who participated in the stranding response on the beach or assisted off-site during or after the event.
- Appendix II. Data, photos, measurements and samples collected for each whale sampled in UMESE0501Sp.
- Appendix III. Tissue samples collected for histopathology from the whales that stranded during UMESE0501Sp.
- Appendix IV. Disposition of samples collected from the whales that stranded during UMESE0501Sp.
- Appendix V. Dates when results were received at the NOAA Beaufort Laboratory or external reviews were conducted..
- Appendix VI. Serum biochemistry and serum electrophoresis results from individual whales from UMESE0501Sp.
- Appendix VII. Ocular fluid biochemistry results from individual whales from UMESE0501Sp.
- Appendix VIII. Urinalysis results from individual whales from UMESE0501Sp.
- Appendix IX. Individual case reports for whales that stranded during UMESE0501Sp. (115 pp).
- Appendix X. Summary of gross findings for 27 pilot whales, 2 dwarf sperm whales, and 1 minke whale calf.
- Appendix XI. Summary of gross and histopathological results of acoustic tissues and brain from pilot whales and dwarf sperm whales that stranding during UMESE0501Sp, including all specimens for which cranial tissues were collected.
- Appendix XII. Summary of histologic findings for 25 pilot whales, 2 dwarf sperm whales, and 1 minke whale calf from UMESE0501Sp.
- Appendix XIII. Bacteria cultured from the whales involved in UMESE0501Sp.
- Appendix XIV. Parasites found in pilot whales (RT) and dwarf sperm whales (KMS) sampled during UMESE0501Sp.
- Appendix XV. Monorygma and Phyllobothrium parasite loads found in pilot whales (RT) and dwarf sperm whales (KMS) sampled during UMESE0501Sp.
- Appendix XVI. Reported individual or multiple strandings of pilot whales, dwarf and pygmy sperm whales, and minke whales.
- Appendix XVII. Reviewers of cases (histology slides).
- Appendix XVIII. Reviewers of the report.

Appendix I. Individuals who participated in the stranding response on the beach or assisted off-site during or after the event. An * indicates a necropy team leader. NCSU CVM = North Carolina State University College of Veterinary Medicine, UNC = University of North Carolina, NPS = National Park Service.

Name	Affiliation	Name	Affiliation
Assistance on the Beach		Assistance on the Beach (continued)	
Dee Allen	Smithsonian Institution	Matt Kelcourse*	Outer Banks DVM
Jon Altman	Stranding network volunteer	Terra Kelly*	NCSU CVM
Michelle Barbieri	UNC Wilmington	Heather Koopman*	UNC Wilmington
Brandi Biehle	Stranding network volunteer	Kelly Kunert	Duke Univ. Marine Lab
Doug Blackmon	NPS Hatteras Island Maintenance	Mac Law	NCSU CVM
Jackie Bort	UNC Wilmington	Nim Lee	Duke Univ. Marine Lab
Nan Bowles	NC Maritime Museum	Greg Lewbart	NCSU CVM
Denise Boyd*	Virginia Aquarium Stranding Program	Rachel Lo Piccolo*	NOAA NMFS SEFSC Beaufort
Shane Boylan	NCSU CVM	Randy Loupe	NPS Hatteras Island Maintenance
Julianna Brush	Maryland Dept Natural Resources	Gretchen Lovewell*	NOAA NMFS SEFSC Beaufort
Olivia Burrus	NC Aquarium in Manteo	Marcia Lyons	NPS Hatteras Island Ranger
Barbie Byrd	NOAA NMFS SEFSC Beaufort	Jennifer Maresh	Duke Univ. Marine Lab
Julie Cavin	NCSU CVM	Keiko Meshida	Smithsonian Inst intern
Miranda Cook	NPS Bodie Island Ranger	Nicole Mihnovets	Duke Univ. Marine Lab
Sally Davis	NCSU CVM	Katie Moore	USCG Atl. Area 5th District Law Enf
Diane Deresienski	NCSU CVM	Carter Morrissette	Virginia Aquarium Strandings
Stephanie Desmarais	NCSU CVM	Tom Ninke	NOAA NMFS SEFSC Beaufort
Mary Doll	NPS Public Relations	Ann Pabst	UNC Wilmington
Dan Dombrowski	NCSU CVM	Bethany Palmer	NPS & Stranding Network Volunteer
Rachel Domenic	NC Aquarium in Manteo	Nathan Plants	NPS Bodie Island Ranger
Chris Duggan	UNC Wilmington	Lia Protopapadakis	Duke Univ. Marine Lab
Michael Ellisor	Nat'l Inst of Science & Technology	Andy Read*	Duke Univ. Marine Lab
Bruce Ferrier	Stranding network volunteer	Taylor Reynolds	NCSU CVM
Kate Freeman	NCSU CVM	Kathryn Rubin	NC Aquarium in Manteo
Ari Friedlaender*	Duke Univ. Marine Lab	John Russell	NC Maritime Museum
Allison Gleason	Duke Univ. Marine Lab	Karen Sayles*	NOAA NMFS SEFSC Beaufort
Kim Goetz	Duke Univ. Marine Lab	Maria Serrano	NCSU CVM
Caroline Good	Duke Univ. Marine Lab	Dennis Stewart	Director, Pea Island Wildlife Refuge
Tyler Greene	NCSU CVM	Vicky Thayer*	Duke Univ. Marine Lab
Chris Guerreri	NC Aquarium in Manteo	Bob Trick	NPS (Pilot)
Christian Guerreri	NC Aquarium in Manteo	Allison Tuttle	NCSU CVM
Patti Haase	NOAA NMFS SEFSC Beaufort	Hope Valentine	NCSU CVM
Aaron Hall	NCSU CVM	Wendy Walton	Virginia Aquarium Stranding Program
Sarah Hargrove	NCSU CVM	Danielle Waples	Duke Univ. Marine Lab
Craig Harms*	NCSU CVM	Lori Watkins	NC Aquarium in Manteo
Cally Harper	UNC Wilmington	Andrew Westgate*	Duke Univ. Marine Lab
C.T. Harry	Virginia Aquarium Strandings	Janet Whaley*	NOAA NMFS Office of Prot. Resources
Elliott Hazen	Duke Univ. Marine Lab	Sarah Wilkin	NOAA NMFS Office of Prot. Resources
Lucie Hazen	UNC Inst of Marine Science	Zoey Zahorodny	UNC Wilmington
Beverly Henson	NPS & Stranding Network Volunteer		
Gary Henson	NPS Hatteras Island Ranger	Assistance Off-the-Beach During or After the Event	
Aleta Hohn	NOAA NMFS SEFSC Beaufort	Connie Barclay	NOAA NMFS Office of Public Affairs
Chuck Houston	NPS Bodie Island Ranger	Susan Barco	Virginia Aquarium Stranding Program
Christy Huy	NCSU CVM	Laura Engleby	NOAA NMFS SERO St. Petersburg
Eileen Jenkins	NCSU CVM	Bob MacLean	NCSU CVM
Lauran Jozik	NC Aquarium in Manteo	Blair Mase	NOAA NMFS SEFSC Miami
Steve Jozik	NC Aquarium in Manteo	William McLellan	UNC Wilmington
Emma Jugovich	NOAA NMFS SEFSC Beaufort	Katie Moore	USCG Atl. Area 5th District Law Enf
Janine Kafourous	Natl Aquarium in Baltimore	Dave Rotstein	University of Tennessee
Michelle Katuna	NCSU CVM	Mark Swingle	Virginia Aquarium Stranding Program

Appendix II. Data, photos, measurements and samples collected for each whale sampled in UMESE0501Sp. For RT47, only the stomach contents (and not the intact stomach) was collected. For RT103, only a tumor was cultured. * indicates specimens for which only head tissues were collected for histopathology. RT89 and 100 washed out before data or samples were collected so they were excluded from this table.

Field ID	Blood for CBC	Serum	Ocular Fluid	Blowhole cultures	Genital cultures	Morphometrics	Standard Blubber Depth	Detailed Blubber Depth	Histopathology	Virology	Epiphyses	Stomach	Gonads	Skin for Genetics	Skin for Isotopes	Blubber for Tox	Muscle for Tox	Liver for Tox	Teeth	Ears	Fetus	Head	Blubber for Contaminants	Blubber for Fat Anal.	Muscle for Fat Anal.	Melon for Fat Anal.	Mandibular Fat	
RT12		x	x	x	x	x	x		x	x		x	x	x	x	x	x	x	x			x				x		
RT13		x	x			x	x		x			x	x	x	x	x	x		x			x		x				
RT19						x	x	x	x	x		x	x	x	x	x	x	x	x			x		x		x		
RT20						x	x	x	x*			x	x		x	x	x	x		x		x		x	x	x	x	x
RT21	x	x	x	Carcass washed out																								
RT22						x	x	x	x			x	x	x	x	x			x			x						
RT24		x	x			x	x		x*			x	x	x	x	x			x		x	x					x	
RT47		x	x	x		x	x		x	x	x	x	x	x	x	x	x	x	x	x	x	x	x	x	x	x	x	x
RT48				x	x	x	x	x	x	x		x	x	x		x	x	x	x	x		x	x	x	x	x	x	x
RT49	x	x	x	x	x	x	x		x	x	x	x	x	x	x	x	x	x	x	x	x	x	x	x	x	x	x	x
RT50		x	x	x	x	x	x		x	x	x	x	x	x	x	x	x	x	x	x		x	x	x	x	x	x	x
RT54				x	x	x	x	x	x			x	x	x	x	x	x	x	x	x	x		x				x	x
RT57						x	x	x	x			x	x	x	x	x			x				x					
RT59		x	x	x	x	x	x		x	x		x	x	x	x	x	x	x					x					
RT63						x	x	x	x			x	x	x		x	x	x	x				x		x	x	x	
RT66						x	x		x			x	x	x	x	x	x		x		x							
RT67		x	x			x	x	x	x			x	x	x		x	x	x	x	x	x				x	x		
RT68	x	x	x	x	x	x	x		x	x		x	x	x	x	x	x	x	x				x					
RT69						x	x	x	x*			x	x	x		x	x	x	x				x					x
RT71						x	x	x	x*			x	x			x	x	x		x			x		x	x	x	x
RT72						x	x	x	x			x	x	x	x	x			x				x					
RT74						x	x					x	x	x	x	x			x				x					
RT101		x	x	Carcass washed out																								
RT102		x	x			x	x	x	x			x	x	x		x	x		x				x					
RT103		x	x	+		x	x	x	x	x		x	x	x	x	x	x	x					x					
RT104		x	x			x	x	x	x	x	x		x	x	x		x	x	x		x							
RT105		x	x			x	x	x	x	x		x	x	x		x	x	x		x			x					
RT106		x	x			x	x	x	x	x		x	x	x	x	x	x	x			x							
RT107			x	x	x	x	x		x	x		x	x	x	x	x	x	x	x				x					
KMS379						x	x		x		x	x	x	x	x	x	x	x	x	x	x		x					
KMS380						x	x		x		x	x	x	x	x	x	x	x	x	x	x		x					
CALO0504						x					x	x	x	x	x	x												
CTH001	x					x			x				x	x														

Appendix III. Tissue samples collected for histopathology from the whales that stranded during UMESE0501Sp. Whales from which no histopathology samples were collected were excluded from this table.

Tissue Samples in Formalin	RT Numbers																											KMS 379	KMS 380	CTH 001
	12	13	19	20	22	24	47	48	49	50	54	57	59	63	66	67	68	69	71	72	102	103	104	105	106	107				
Acoustic periotic fat									x																					
Adipose cavities																					x									
Adrenal gland	x	x	x				x	x	x	x	x	x			x	x	x						x	x	x	x	x			
Aorta	x	x	x				x		x	x					x		x						x	x	x	x	x			
Atrium		x	x				x	x	x	x	x		x			x	x	x					x	x	x	x	x			
Bladder	x	x	x						x	x	x				x	x	x						x	x	x	x	x			
Blubber	x	x					x	x	x	x					x		x						x	x	x	x				
Blubber - fibrous lesion																							x							
Bone marrow	x	x													x												x			
Brain -Cerebellum	x	x		x	x	x	x	x	x	x	x		x		x	x	x	x	x	x			x	x	x	x	x			
Brain -Cerebrum				x	x	x	x	x	x	x	x		x			x	x	x	x	x			x	x	x	x	x			
Brain stem	x	x	x	x	x				x	x	x	x			x		x	x	x	x			x	x	x	x	x			
Bronchi		x	x						x	x	x	x			x		x						x	x	x	x	x			
Colon									x	x	x	x			x									x	x	x	x			
Corpus callosum										x															x	x				
Cranial nerve																											x			
Cyst					x																									
Diaphragm								x			x	x												x	x	x	x			
Duodenal ampulla	x										x																			
Duodenum	x										x																			
Ear Fat																														
Ear junction - soft tissue																											x			
Ears				x					x	x	x	x	x														x			
Esophagus											x	x															x			
Eye											x	x														x	x			
Intraventricular septum		x																												
Kidney		x																												
Laminar area																														
Lesions																														
Liver	x	x	x		x																									
Lung	x	x	x																											
Lymph node - Cardiac																														
Lymph node - Colonic																														
Lymph node - Jejunal																														
Lymph node - Lung	x	x	x																											
Lymph node - Medialstynal																														
Lymph node - Mesenteric		x	x																											
Lymph node - Pancreatic																														
Lymph node - Pericardial																														
Lymph node - Prescapular	x	x	x																											
Lymph node - Pulmonary																														
Lymph node - Retropharyngeal																														
Lymph node - Subscapular																														
Lymph node- Gastric																														
Mammary		x	x																											
Mandibular fat - Inner																														
Mandibular fat - Outer																														

Appendix III Page 2 of 2

Tissue Samples in Formalin	RT Numbers																									KMS 379	KMS 380	CTH 001								
	12	13	19	20	22	24	47	48	49	50	54	57	59	63	66	67	68	69	71	72	102	103	104	105	106				107							
Mandib. fat saponification																						x														
Muscle -skeletal	x	x	x					x	x	x	x		x		x	x							x	x		x	x	x	x	x	x					
Occipetal bone scar										x																										
Optic nerve													x										x				x									
Oral mucosa													x								x		x			x	x									
Ovary	x	x	x		x			x	x	x	x		x	x	x		x					x			x	x	x			x						
Pancreas							x	x	x		x					x							x	x		x	x	x	x	x	x					
Penis																																				
Periotic tissue										x																										
Pharynx							x			x																										
Pituitary									x	x			x				x					x		x			x	x								
Placenta										x																										
Pons								x					x				x					x		x												
Pre-maxillary bone				x																																
Prostate																																				
Pterygoid sinus													x				x							x												
Pterygoid sinus nerve										x																										
Small intestine	x						x		x	x	x		x				x						x	x	x	x				x	x					
Spinal cord - cervical		x					x	x	x	x	x		x				x						x	x	x	x			x			x				
Spinal cord - thoracic							x			x			x																	x						
Spleen		x	x				x	x	x	x	x		x			x	x						x	x		x	x	x	x	x	x	x				
Stomach (Fore)																																				
Stomach (Main)																																	x			
Stomach (Pyloric)																																				
Testes/epidid							x					x							x												x					
Thalamus								x		x			x				x					x		x			x	x								
Thymus	x							x			x		x																				x			
Thyroid	x	x					x	x		x	x						x																x			
Tissue - swollen gum					x																															
Tongue								x					x				x					x				x	x	x	x							
Tonsil	x																																			
Trachea									x															x	x		X		x				x			
Umbilical scar																																				
Umbilicus								x	x	x					x																					
Uterine horn	x	x	x		x			x	x	x	x			x			x	x					x	x	x	x	x	x								
Vent lesion																																		x		
Ventricle		x	x				x	x	x	x	x		x		x	x	x							x	x	x	x	x	x	x	x	x	x			
For fat stains:																																				
Mandibular fat - Inner								x															x													
Mandibular fat - Outer								x																												
Lung																																			x	
Brain								x					x																							
Cerebellum										x																										
Cerebrum										x																										

Appendix IV. Disposition of samples collected from the whales that stranded during UMES0501Sp. All dates are in the format Month/Day and are during 2005. RT numbers are for the pilot whales, CTH is for the minke whale, KMS are for the dwarf sperm whales. "x" indicates samples archived with NMFS at the NOAA Beaufort Laboratory.

Field ID	Blood for CBC to Sentara Lab	Serum to NCSU	Ocular Fluid to NCSU	Serum to Cornell	Ocular Fluid to Cornell	Serum to Oklahoma State	Serum Banked at NMFS	Serum Banked at NCSU	Head left at NPS Maint Yd	Head CT scanned	CT Scans to CA Medical Ctr	Histopath to UT	Histopath Archived	Virology	Epiphyses	Stomachs sorted at Bft Lab	Stomach parasites to NCSU	Stomach contents to Duke	Gonads	Skin for Genetics	Skin for Genetics to NOAA Lafayette Lab	Skin for Isotopes	B lubber for Tox	Muscle for Tox	Liver for Tox	Teeth	Fetus	Abscess for culture - NCSU	Heads worked up at NOAA Beaufort Lab	Heads taken to UNCW	Heads worked up at UNCW	Heads taken to SI	Ears collected on site	Earbones to UT	
RT12					8/10				1/17			1/28	x	x		2/8-9	2/15	2/10	x	x	2/9	x	x	x	x	x					1/20	1/21	1/28	1/17	1/28
RT13	1/16	8/10			8/10	8/11		x	1/17			1/28	x			2/8-9	2/15		x	x	2/9	x	x	x						1/20	1/21	1/28			
RT19									1/17			1/28	x	x		2/8-9	2/15		x	x	2/9	x	x	x	x	x					1/20	1/21	1/28		
RT20																2/8-9	2/15		x			x	x	x	x			2/15	1/20			3/18			
RT21	1/16	8/10						x																											
Carcass Washed out																																			
RT22									1/17			1/28				2/8-9	2/15	2/10	x	x	2/9	x	x			x					1/20	1/21	1/28		
RT24		8/10			8/10				1/17							2/8-9	2/15	2/10	x	x	2/9	x	x			x	x				1/20	1/21	1/28		
RT47					8/10							1/28	x	x	x	2/8-9	2/15		x	x	2/9	x	x	x	x			2/15	1/20			3/18			
RT48	1/16											1/28	x	x		2/8-9	2/15		x	x	2/9		x	x		x				1/20	11/30	Dec			
RT49		8/10		8/10	8/10	8/11		x				1/28	x	x	x	2/8-9	2/15		x	x	2/9	x	x	x	x	x		2/15	1/20			3/18			
RT50		8/10		8/10				x				1/28	x	x	x	2/8-9	2/15	2/10	x	x	2/9	x	x	x	x	x				1/20	11/29	Dec			
RT54										2/1	12/9	1/28	x	x		2/8-9	2/15	2/10	x	x	2/9	x	x	x	x			2/3	1/20			3/18			
RT57									1/17			1/28				2/8-9	2/15	2/10	x	x		x	x			x				1/20	1/21	1/28			
RT59		8/10		8/10	8/10	8/11		x				1/28	x	x		2/8-9	2/15	2/10	x	x	2/9	x	x	x	x	x				1/20	11/30	Dec			
RT63									1/17			1/28	x			2/8-9	2/15		x	x	2/9		x	x	x					1/20	1/21	1/28			
RT66									1/17			1/28	x			2/8-9	2/15	2/10	x	x	2/9	x	x	x		x				1/20	1/21	1/28			
RT67			8/10		8/10				1/17			1/28	x			2/8-9	2/15	2/10	x	x	2/9		x	x	x					1/20	1/21	1/28	1/17	1/28	
RT68		8/10			8/10			x				1/28	x	x		2/8-9	2/15		x	x	2/9	x	x	x	x					1/20	11/30	Dec			
RT69									1/17							2/8-9	2/15		x	x	2/9		x	x	x					1/20	1/21	1/28			
RT71									1/17							2/8-9	2/15	2/10	x				x	x	x			2/15	1/17			1/28			
RT72																2/8-9	2/15		x	x	2/9	x	x			x				1/20	11/30	Dec			
RT74									1/17							2/8-9	2/15		x	x	2/9	x	x			x				1/20	1/21	1/28			
RT101			8/10					x																											
Carcass Washed out																																			
RT102		8/10			8/10			x	1/17			1/28				2/8-9	2/15	2/10	x	x	2/9		x	x		x					1/20	1/21	1/28		
RT103		8/10			8/10			x				1/28	x	x		2/8-9	2/15		x	x	2/9	x	x	x	x		1/20			1/20	11/30	Dec			
RT104					8/10					2/1	12/9	1/28	x	x	x	2/8-9	2/15		x	x	2/9		x	x	x			2/3	1/20			3/18			
RT105		8/10		8/10	8/10	8/11		x				1/28	x	x		2/8-9	2/15	2/10	x	x	2/9		x	x	x			2/15	1/20			3/18			
RT106					8/10							1/28	x	x		2/8-9	2/15	2/10	x	x		x	x	x	x		x			1/20	11/30	Dec			
RT107			8/10		8/10							1/28	x	x		2/8-9	2/15	2/10	x	x	2/9	x	x	x	x	x				1/20	3/29	Dec			
CTH001	1/16	8/10		8/10		8/11		x				2/1																							
KMS379									1/31	12/9	1/28	x		x		2/8-9	2/15	2/10	x	x	2/9	x	x	x	x			2/3				3/18		3/1	
KMS380									1/31	12/9	1/28	x				2/8-9	2/15	2/10	x	x	2/9	x	x	x	x			2/3				3/18		3/1	

Appendix V. Dates when results were received at the NOAA Beaufort Laboratory or external reviews were conducted. All dates are 2005 except where otherwise indicated.

Field ID	Blood for CBC from Sentara Lab	Serum Chemistry from NCSU	Ocular Chemistry from NCSU	Serum Chemistry from Cornell	Ocular Chemistry from Cornell	Morbilivirus titers	Bacterial Cultures	Head necropsy	Preliminary Histopath from UT	Peer Review of Histopath Slides (Bossart)	Peer Review of Histopath Slides (Jepson and Fernandez)	Peer Review of Histopath Slides (Miller and Raverty)	Final Histopath from UT	Genetics from NMFS Lafayette Lab	Stomach parasites ID's from NCSU	Stomach content species identification from Duke
RT12					16-Aug		4-Mar	21-Jan	17-Jun	24-May	5-Dec	16-17 Dec	30-Jan-06	15-Sep	15-Mar	15-Dec
RT13	23-Jan	16-Aug			16-Aug	23-Aug		21-Jan	22-Feb	24-May	5-Dec	16-17 Dec	30-Jan-06	15-Sep	15-Mar	
RT19								21-Jan	23-Feb	24-May		16-17 Dec	30-Jan-06	15-Sep	15-Mar	
RT20								15-Feb	26-Apr	24-May		16-17 Dec	30-Jan-06		15-Mar	
RT21	23-Jan	16-Aug				23-Aug				24-May		16-17 Dec	30-Jan-06			
RT22								21-Jan	15-Jun	24-May	5-Dec	16-17 Dec	30-Jan-06	15-Sep	15-Mar	15-Dec
RT24		16-Aug			16-Aug			21-Jan	16-Jun	24-May	5-Dec	16-17 Dec	30-Jan-06	15-Sep	15-Mar	15-Dec
RT47					16-Aug		4-Mar	15-Feb	25-Apr	24-May		16-17 Dec	30-Jan-06	15-Sep	15-Mar	
RT48	23-Jan						4-Mar	30-Nov	25-Apr	24-May		16-17 Dec	30-Jan-06	15-Sep	15-Mar	
RT49		16-Aug		16-Aug	16-Aug	23-Aug	4-Mar	15-Feb	26-Apr	24-May		16-17 Dec	30-Jan-06	15-Sep	15-Mar	
RT50		16-Aug			16-Aug		4-Mar	30-Nov	16-Jun	24-May	5-Dec	16-17 Dec	30-Jan-06	15-Sep	15-Mar	15-Dec
RT54							4-Mar	3-Feb	26-Apr	24-May	5-Dec	16-17 Dec	30-Jan-06	15-Sep	15-Mar	15-Dec
RT57								21-Jan	28-Jan	24-May	5-Dec	16-17 Dec	30-Jan-06		15-Mar	15-Dec
RT59		16-Aug		16-Aug	16-Aug	23-Aug	4-Mar	30-Nov	17-Jun	24-May	5-Dec	16-17 Dec	30-Jan-06	15-Sep	15-Mar	15-Dec
RT63								21-Jan	28-Jan	24-May		16-17 Dec	30-Jan-06	15-Sep	15-Mar	
RT66								21-Jan	7-Apr	24-May		16-17 Dec	30-Jan-06	15-Sep	15-Mar	15-Dec
RT67			16-Aug		16-Aug			21-Jan	17-Mar	24-May		16-17 Dec	30-Jan-06	15-Sep	15-Mar	15-Dec
RT68		16-Aug			16-Aug		4-Mar	30-Nov	17-Mar	24-May		16-17 Dec	30-Jan-06	15-Sep	15-Mar	
RT69								21-Jan	26-Apr	24-May		16-17 Dec	30-Jan-06	15-Sep	15-Mar	
RT71								15-Feb	26-Apr	24-May		16-17 Dec	30-Jan-06		15-Mar	15-Dec
RT72								30-Nov		24-May		16-17 Dec	30-Jan-06	15-Sep	15-Mar	
RT74								21-Jan		24-May		16-17 Dec	30-Jan-06	15-Sep	15-Mar	
RT101			16-Aug		16-Aug					24-May		16-17 Dec	30-Jan-06			
RT102		16-Aug			16-Aug			21-Jan	17-Mar	24-May		16-17 Dec	30-Jan-06	15-Sep	15-Mar	15-Dec
RT103		16-Aug			16-Aug		4-Mar	30-Nov	17-Mar	24-May	5-Dec	16-17 Dec	30-Jan-06	15-Sep	15-Mar	
RT104					16-Aug			3-Feb	17-Mar	24-May		16-17 Dec	30-Jan-06	15-Sep	15-Mar	
RT105		16-Aug		16-Aug	16-Aug	23-Aug		15-Feb	17-Mar	24-May		16-17 Dec	30-Jan-06	15-Sep	15-Mar	15-Dec
RT106					16-Aug			30-Nov	1-Apr	24-May		16-17 Dec	30-Jan-06		15-Mar	15-Dec
RT107			16-Aug		16-Aug		4-Mar	30-Nov	1-Apr	24-May		16-17 Dec	30-Jan-06	26-Oct	15-Mar	15-Dec
CTH001	23-Jan	16-Aug		16-Aug		23-Aug			6-Apr	24-May		16-17 Dec	30-Jan-06			
KMS379								3-Feb	7-Apr	24-May	5-Dec	16-17 Dec	30-Jan-06			
KMS380								3-Feb	7-Apr	24-May	5-Dec	16-17 Dec	30-Jan-06			

Appendix VI. Serum biochemistry and serum electrophoresis results from individual whales from UMESE0501Sp. An * indicates a value out of range for Tursiops (Bossart *et al.* 2001). n/a = not applicable.

Field ID	Albumin (g/dl)	Alkaline phosphatase (ALP) (U/L)	Alanine aminotransferase (ALT) (U/L)	Aspartate aminotransferase (AST) (U/L)	Amylase	Anion Gap [= (Na + K) - (Cl + HCO3)]	Total bilirubin (mg/dl)	Indirect bilirubin (mg/dl)	Direct bilirubin (mg/dl)	Blood urea nitrogen (BUN) (mg/dl)	Calcium (mg/dl)	Phosphorus (mg/dl)	Creatinine (Cr) (mg/dl)	Creatine kinase (CK) (U/L)	Glucose (mg/dl)	Gamma glutamyltransferase (GGT) (U/L)	Sodium (mmol/L)	Potassium (mmol/L)	Chloride (mmol/L)	Magnesium (mg/dl)	Total Protein (g/dl)	Triglyceride (mg/dl)	Iron (µg/dl)	Albumin/globulin (A/G) ratio	Globulin (g/dl)	Lactate dehydrogenase (LDH) (U/L)	Hemolysis Index	Hemolysis	Lipemia Index	Icteric Index	Bicarbonate HCO3 (mEq/L)	Sorbitol Dehydrogenase (U/L)	Total Iron Binding Capacity (ug/dL)	% SAT
----------	----------------	----------------------------------	--------------------------------------	--	---------	--------------------------------------	-------------------------	----------------------------	--------------------------	-----------------------------------	-----------------	--------------------	-------------------------	----------------------------	-----------------	---------------------------------------	-----------------	--------------------	-------------------	-------------------	----------------------	----------------------	--------------	------------------------------	-----------------	-----------------------------------	-----------------	-----------	---------------	---------------	--------------------------	------------------------------	-------------------------------------	-------

Results from the Abaxis VetScan

CTH001	0	228	53*		125		0			43*	8.6	6.3	1.2		188		164	7.5			7.5						3+	990	0	0					
RT13	3	343	7*		<5*		0.3			37*	8.4	3.1*	1.9		180*		153	4.8*			7.5				4.5	2+		0	0						
RT21	2.8*	241	79*		9		0.3			45	8.4	5.7	2.4*		185*		157	4.2			8				5.2	1+		0	0						
RT24	0	117	57		0		0			45	0	7.2	1		104		<100	11.1			9.2				0	3+	2025	2+	0						
RT49	2.5*	120	16		0*		0.3			40*	9.1	4.3	1.5		126		161*	6.2*			7.2				4.8	3+		0	0						
RT50	2.4*	138	20		0*		0.3			40*	9.5*	5.8	1.4		146*		164*	6.6*			7				4.6	3+		0	0						
RT59	2.7*	31*	24		<5*		0.4			35*	9.8*	14.2*	2.4*		101		168*	>8.5*			8.4				5.7*	2+		0	0						
RT68	1.6*	55	11		0*		0.3			53	8.9	6.3	1.6		138		164*	6.9*			5.5*				3.9	3+		0	0						
RT101	n/a	n/a	n/a		n/a		n/a			n/a	n/a	n/a	n/a		n/a		n/a	n/a			n/a				n/a	n/a	n/a	n/a	n/a	n/a	n/a	n/a	n/a	n/a	
RT102	1.2*	56	15		0*		0.3			37*	7.8*	4.9	1.6		124		161*	7.6*			4.3*				3.1	3+		0	0						
RT103	1.6*	17*	7*		<5*		0.2			48	8.2	5.7	1.1		133		154	6.4*			6.7				5.1	2+		0	0						
RT105	3.1	56	126*		<0.5*		0.5*			37*	11.2*	18.2*	3.0*		131		>170*	6.0*			9.9*				6.8*	2+		0	0						

Results from Cornell Diagnostic Laboratory

CTH001	3.8	223		297		27	0.3	0.3	0	51	9.1	5.4	0.8	730	168	4	156	5.9	110	3.2	7.3	59	271	1.09	3.5	1043						25	<2	299	91
RT49	3.6	133		320		29	0.3	0.3	0	45	9.6	5.9	0.6	430	130	16	159	7.5	123	3.2	7.1	52	171	1.03	3.5	1817						15	<2	196	87
RT59	3.7	26		322		41	0.4	0.4	0	36	9.4	11.2	1.5	1078	111	21	155	12.8	109	2.4	7.8	126	230	0.9	4.1	1827						18	<2	230	100
RT105	4.5	71		1345		67	0.5	0.4	0.1	40	11.7	17	2.8	2559	133	42	150	20.3	97	3.7	9.2	174	543	0.96	4.7	1863						6	10	543	100

Serum Electrophoresis Results from Cornell Diagnostic Laboratory

ID	Albumin g/dL	Alpha 1 g/dL	Alpha 2 g/dL	T Alf g/dL	T Beta g/dL	Gamma g/dL	Tot Glob g/dL	A/G g/dL
CTH001	3.18	0.48	0.9	1.38	1.59	1.15	4.12	0.77
RT105	4.34	0.56	1.24	1.8	0.79	2.27	4.86	0.89

Appendix VII. Ocular fluid biochemistry results from individual whales from UMESE0501Sp. n/a = not applicable (missing a value), QNS = quantity of fluid not sufficient.

Field ID	Albumin/globulin (A/G) ratio	Albumin (g/dl)	Globulin (g/dl)	Total Protein (g/dl)	Alkaline phosphatase (ALP) (U/L)	Amylase	Anion Gap [= (Na + K) - (Cl + HCO3)]	Alanine aminotransferase (ALT) (U/L)	Aspartate aminotransferase (AST) (U/L)	Bicarbonate HCO3 (mEq/L)	Total bilirubin (mg/dl)	Indirect bilirubin (mg/dl)	Direct bilirubin (mg/dl)	Calcium (mg/dl)	Chloride (mmol/L)	Creatine kinase (CK) (U/L)	Creatinine (Cr) (mg/dl)	Gamma glutamyltransferase (GGT) (U/L)	Glucose (mg/dl)	Hemolysis Index	Hemolysis	Icteric Index	Lipemia Index	Iron (µg/dl)	Total Iron Binding Capacity (ug/dL)	% SAT	Lactate dehydrogenase (LDH) (U/L)	Magnesium (mg/dl)	Sodium/Potassium Ratio	Osmolality, C (MOSM/KG)	Phosphorus (MG/DL)	Potassium (mmol/L)	Sorbitol Dehydrogenase (U/L)	Sodium (mmol/L)	Triglyceride (mg/dl)	Blood urea nitrogen (BUN) (mg/dl)																						
Results from NCSU																																																										
RT47	n/a	<1.0	n/a	0.9	3		30.7		366	19	0.1			8.1	118	5042	0.8	<3	49	0			0	5				2.9	16.3	330.7	2.6	9.7			158			45																				
RT49	n/a	<1.0	n/a	0.6	1		22.2		146	17	<0.1			8.7	132	1878	0.6	<3	48	0			0	8				2.8	19.9	337.2	1.5	8.2			163			45																				
RT50	n/a	<1.0	n/a	1.3	3		34.7		259	15	0.1			8.3	121	3114	0.9	<3	59	0			0	6				3.3	13.6	335.4	3.4	11.7			159			41																				
RT59	n/a	<1.0	n/a	0.5	1		14.9		24	22	<0.1			8.2	128	17	1	<3	75	0			0	9				2.4	19.9	323.7	2.1	7.9			157			36																				
RT67	n/a	QNS	n/a	1.1	QNS		n/a		QNS	QNS	QNS			QNS	117	5130	QNS	QNS	48	n/a			n/a	n/a				QNS	15.4	321.7	QNS	9.9			152			50																				
RT71	n/a	<1.0	n/a	0.6	2		20.7		957	23	0.1			7.8	126	17710	0.4	<3	44	0			0	8				3.5	14.9	342.3	2	10.7			159			68																				
RT101	n/a	<1.0	n/a	0.3	4		29.7		44	20	<0.1			10	137	<3	0.9	<3	53	31			0	12				5	21.7	365.3	1.1	8.2			178			45																				
RT103	n/a	<1.0	n/a	1	1		20.4		62	21	<0.1			8.3	126	513	0.6	<3	62	0			0	9				3.4	16.8	332.7	2.7	9.4			158			50																				
RT104	n/a	<1.0	n/a	1.2	7		23.2		51	19	0.1			5.9	129	147	0.7	<3	55	0			0	6				3.1	15.8	337.6	2.6	10.2			161			45																				
RT105	n/a	<1.0	n/a	0.7	1		20.1		55	20	0.1			8.7	126	117	1.2	<3	59	0			0	7				3	17.3	325.1	2	9.1			157			36																				
RT107	n/a	<1.0	n/a	0.8	1		28.2		234	16	<0.1			9.3	147	925	1.5	<3	75	56			0	6				6.5	18.7	375.2	2.6	9.7			182			43																				
Results from Cornell Diagnostic Lab																																																										
RT12	0	<1	0.6	0.6	3		19		262	27	0	0	0	8	116	2769	0.7	<3	77						10	10	100	551	2				0.9	6.4	<2	156	24	49																				
RT13	0.13	1.8	4.8	6.6	2		21		260	34	0	0	0	6	101	371	1	<3	88						21	32	66	4115	3.6			10	26.1	1389	130	18	39																					
RT24	0	<1	0.9	0.9	12		21		261	15	0.1	0.1	0	11.9	169	3833	0.5	<3	58						25	25	100	684	10			2.9	9.5	<2	195	12	44																					
RT47	0	<1	0.9	0.9	3		31		420	20	0	0	0	7.9	118	5962	0.8	<3	51						6	16	38	1577	2.2			2.3	9.7	14	159	<4	47																					
RT59	0	<1	0.6	0.6	2		23		306	17	0	0	0	8.3	129	2229	0.6	<3	48						<5	0	nr	395	2.2			1.3	8.1	15	161	<4	44																					
RT50	0	<1	1.3	1.3	3		34		387	16	0	0	0	7.9	119	3726	0.9	<3	60						6	17	35	1515	2.5			3	11.6	26	157	<4	42																					
RT59	0	<1	0.5	0.5	1		17		38	22	0	0	0	8	126	39	0.9	<3	76						<5	0	nr	36	1.9			1.8	7.9	4	157	<4	36																					
RT67	0	<1	1.1	1.1	1		20		860	25	0.1	0.1	0	8	117	10945	0.2	<3	53						13	13	100	3230	2.8			2	9.9	<2	152	14	52																					
RT68	0	<1	1	1	4		28		62	17	0	0	0	8.5	125	39	0.8	<3	63						5	5	100	234	3.8			2.2	9.5	29	160	<4	53																					
RT101	0	<1	0.3	0.3	4		22		49	21	0	0	0	10.1	142	31	0.1	<3	55						14	14	100	47	4.3			0.9	8.1	<2	177	<4	44																					
RT102	0	<1	0.7	0.7	4		21		212	22	0	0	0	8.5	126	2964	0.9	<3	49						<5	0	nr	637	2.5			1.9	8.8	9	160	<4	43																					
RT103	0	<1	1	1	2		19		87	22	0	0	0	8.4	125	598	0.5	<3	62						<5	0	nr	257	2.7			2.5	9.2	16	157	11	50																					
RT104	0	<1	1.2	1.2	8		22		72	20	0	0	0	8.3	128	143	0.7	<3	57						8	21	38	449	2.6			2.3	10.1	27	160	<4	46																					
RT105	0	<1	0.7	0.7	2		21		75	20	0	0	0	8.4	124	400	1.1	<3	58						<5	0	nr	240	2.4			1.7	9	14	156	<4	39																					
RT106	0	<1	2	2	4		20		467	13	0	0	0	11.5	174	5613	0.9	<3	21						12	12	100	2200	12.5			4.9	13.8	23	193	6	47																					
RT107	0	<1.0	0.8	0.8	2		23		279	17	0	0	0	9.6	149	4282	1	<3	75						6	6	100	774	5.6			2.5	9.5	<2	179	4	44																					
Results from Abaxis VetScan																																																										
RT67		0.0*		1.4*	0*	3		31			0.2			7.8			0.3		52	3+	190										2.2	10.5*		157			51																					
RT101		0.0*		0.4*	6	12		7			0.4			9.9			1.1		56	2+	46										1.2	8.4		178*			45																					
RT107		0.0*	0	0.9*	3*	6		15			0.2			9.3			1.7		76	2+	68										2.7	10.1*		>180*			44																					

Appendix VIII. Urinalysis results from individual whales from UMESE0501Sp. In addition to the results below, notes from RT12 noted hemorrhagic cystitis, with blood clots in bladder lumen, bladder wall leathery, and urine smells like formaldehyde or ketones (although ketones turned out to be negative). DR = did not register. Date collected was in 2005. n/r = not recorded.

Field ID	Date collected	Specific Gravity	Urobilinogen	Protein	pH	Blood	Ketones	Bilirubin	Glucose	Collection method
RT12	15-Jan	DR	DR	DR	8.5	DR	negative	negative	negative	cysto
RT13	15-Jan	1.039	0.2	trace	6	hemolyzed trace	negative	negative	negative	catheter
RT47	15-Jan	1.033	0.2	trace	6	trace	negative	negative	negative	n/r
RT59	15-Jan	1.015	0.2	3+	6.5	3+	trace	negative	negative	catheter
RT66	17-Jan	1.022	0.2	2+	5	3+	negative	negative	negative	n/r
RT68	15-Jan	1.02	0.2	3+	6	negative	negative	negative	negative	n/r
RT71	15-Jan	1.015	0.2	3+	6	negative	negative	negative	negative	n/r
RT107	15-Jan	1.03	0.2	trace	6.5	negative	negative	negative	negative	n/r
RT105	15-Jan	1.023	0.2	3+	6.5	large	small (15 mmol/L)	negative	negative	n/r
RT104	15-Jan	1.031	0.2	negative	6	negative	negative	negative	negative	n/r

Appendix IX. Individual case reports for whales that stranded during UMESE0501Sp.
(115 pp).

CETACEAN NECROPSY REPORT:
Pilot Whale Stranding, NC-15/16 Jan 2005

Field ID: RT12
 Accession Number: 05-2C
 Date: 15 Jan 2005
 Species: Globicephala macrorhynchus
 Location: Bodie Island (Oregon Inlet), NC (lat-35.83323; long-75.55797)
 Sex: F (sub-adult)
 TL: 210.0 cm

GROSS REPORT
 REPORTING INSTITUTION: NOAA Beaufort

Adapted from report received.
 History: Mass stranding; this whale was initially marked "B4" and was moved to higher beach from original position. GIS coordinates reflect final location where necropsy took place. Animal was assigned R-12 although not tagged on dorsal fin.

External Examination. Teeth are barely erupted.

Location	Number	Comment
Upper Left	7	#1 Barely erupted.
Upper Right	8	N/C
Lower Left	5	Starting to erupt
Lower Right	5	1 and 5 at surface

Musculoskeletal System. Scapulohumeral joint-thick viscous fluid.

Cardiovascular System. Dimensions recorded.

Location	Measurement	Comment
Right Ventricular Freewall	7.0mm	
Left Ventricular Freewall	18mm	
Inteentricular Septum	20mm	

Respiratory System. The right lung is dark red.

Hematopoietic/Lymphoreticular System. The pre-scapular lymph node is enlarged and pale. The spleen is 9.5 X 5.5 X 2.5 (cm).

Endocrine System. The right and left adrenal glands measure 4.0 X 2.0 X 0.9 (cm) and 3.5 X 4.5 X 1.0 (cm), respectively.

Digestive System. The intestines measure 1456.5 cm.

Urinary System. The right and left kidney measures 21.0 X 7.5 X 5.5 (cm) and 22.5 X 10.0 X 5.5 (cm), respectively. The urinary bladder was leathery.

Reproductive System. The right and left gonad measure 5.0 X 2.5 X 1.5 (cm) and 4.0 X 1.5 X 1.5 (cm), respectively. The uterine horn is 1.5 cm in width.

Notes: Ears collected. No parasites in pterygoid sinuses.

ANCILLARY FINDINGS

Urinalysis (C. Harms):

Test	Result
Specific Gravity	Does Not Register
Urobilinogen	--
Protein	--
pH	8.5
Blood	--
Ketones	NEG
Bilirubin	NEG
Glucose	Neg
Collection	Cysto

TISSUES/SAMPLES RECEIVED

REPORTING INSTITUTION: UNIVERSITY OF TENNESSEE

Two bags are received. Bag 1 is labeled as RT 12 "B" 1/15/05 10% NBF and contains 25 free tissues and 3 cassettes. Cassettes are labeled as "Lung Lymph Node", "Mesenteric Lymph Node", and "Prescapular Lymph Node" and are placed in Cassettes 1-3 in that order. Remaining tissues are placed in Cassettes 1-12 and an intact eye is placed in a megacassette. The second bag contains two ears in 10%NBF.

MICROSCOPIC FINDINGS

REPORTING INSTITUTION: UNIVERSITY OF TENNESSEE

Lung Lymph Node (slide 1): Primary lymphoid follicles are present. There is moderate medullary edema and mildly increased macrophages and eosinophils within medullary sinuses. Occasional vessels within the perinodal connective tissue and adipose exhibit segmental separation of the endothelium from the tunica media by eosinophilic proteinaceous fluid (suspect artifactual change).

Spleen (slide 1): No significant histological findings (NSF).

Uterus (slide 1): Glandular density is minimal with fewer than 3 linearly arranged glands per HPF. The endometrial columnar epithelium is low cuboidal.

Mesenteric Lymph Node (slide 2): There is diffuse lymphoid hyperplasia. There is a mild increase in macrophages within medullary sinuses. Occasional macrophages contain intracytoplasmic golden brown, granular pigment (hemosiderin).

Kidney (slides 2, 4, and 9): NSF.

Pre-scapular Lymph Node (slide 3): There is diffuse lymphoid hyperplasia. There is a mild increase in macrophages within medullary sinuses.

Blubber (slide 3): NSF.

Intestine (slides 4, 5 and 8): There are increased plasma cells, eosinophils, and lymphocytes within the lamina propria.

Heart (slides 4, 5, and 6): There is multifocal individual to regionally extensive cardiomyocyte necrosis characterized by pyknotic nuclei and hyper eosinophilic cytoplasm.

Lymph Node, NOS (slide 5): There is diffuse lymphoid hyperplasia. Medullary spaces are expanded by small to moderate numbers of macrophages and edema.

Diaphragm (slide 7): NSF.

Adrenal Gland (slide 7): There is moderate congestion.

Spinal Cord (slides 7 and 12): Four sections are examined. There is multifocal, mild, perivascular deposition of globular eosinophilic fluid (proteinaceous transudate). Scattered myelin sheaths are expanded. There is moderate vascular congestion.

Thyroid Gland (slide 7): Nearly 60% of thyroid follicles contain moderate amounts of eosinophilic, homogenous substance (colloid).

Lymph Node, NOS (slide 8): Lymphoid follicles are mildly reactive.

Lung (slides 2 and 8): In slide 8, there is effacement of a bronchiole by a granuloma composed of an inner core of eosinophilic granular substance, cellular, and nuclear debris, and irregular saw-tooth to polygonal structures with a clear cell membrane (suspect tegument) surrounded by large numbers of eosinophils, macrophages, lymphocytes, and plasma cells within a fibrous capsule (Figure 1). Eosinophils and macrophages spread along interstitial septa. Alveolar spaces and bronchiolar spaces are flooded with variable numbers of eosinophils and macrophages. In slide 2, nearly 50% of alveolar spaces are flood within eosinophilic proteinaceous fluid (edema) and mild to moderate numbers of foamy macrophages and granulocytes.

Prescapular Lymph Node (slide 3):

Thymus (slide 9): Cortex and medulla are fairly distinct. There is scattered lymphocytolysis (lymphoid involution).

Tonsil (slide 9): NSF.

Skeletal Muscle (slide 10): NSF.

Liver (slide 10): There is diffuse, moderate congestion. Nearly all hepatocytes contain discrete intracytoplasmic vacuoles (lipid accumulation). Rare hepatic venules contain eosinophilic, homogenous fluid (serum) with marginal to occasionally interspersed discrete vacuoles (retraction artifact). Portal veins and central veins are mildly ectatic. Occasional bile ducts contain inspissated, granular eosinophilic substance (bile).

Brain (slide 11): Three sections encompassing brain stem, cerebrum, and cerebellum are examined. There is multifocal, mild, perivascular deposition of globular eosinophilic fluid (proteinaceous transudate). Scattered myelin sheaths are expanded. Vessels are moderate congested and there is a single region where two small caliber arteries contain fibrillar, lightly eosinophilic material.

Eye (slide 13) (17 June 2005): NSF.

MORPHOLOGIC DIAGNOSES

Respiratory System:

Lung:

- a. Bronchiolitis and alveolitis, granulomatous and eosinophilic, regionally extensive, moderate with intralesional remnants of metazoans.
- b. Pulmonary edema, multifocal.

Cardiovascular System:

Heart: Individual cardiomyocyte necrosis, multifocal, mild.

Hepatobiliary System:

Liver: Congestion, diffuse, moderate.

Digestive System:

Intestine: Enteritis, eosinophilic and lymphoplasmacytic, diffuse, mild to moderate.

FINAL DIAGNOSES/INTERPRETATIVE SUMMARY

Verminous Pneumonia
Enteritis

The cause of stranding is not evident in the examined histologic sections. Verminous pneumonia is not an uncommon finding in free-living cetaceans. The metazoans observed were necrotic and it is difficult to determine with certainty the specific class (cestode, trematode, nematode). Similarly, there is an enteritis and the presence of eosinophils within the infiltrate is suggestive of endoparasitism. Neither finding would be associated with stranding. Cardiomyocyte necrosis is likely antemortem and represents a hypoxic change. In addition, pulmonary edema is a perimortem change. Hepatic congestion represents post-mortem pooling of blood.

FIGURES

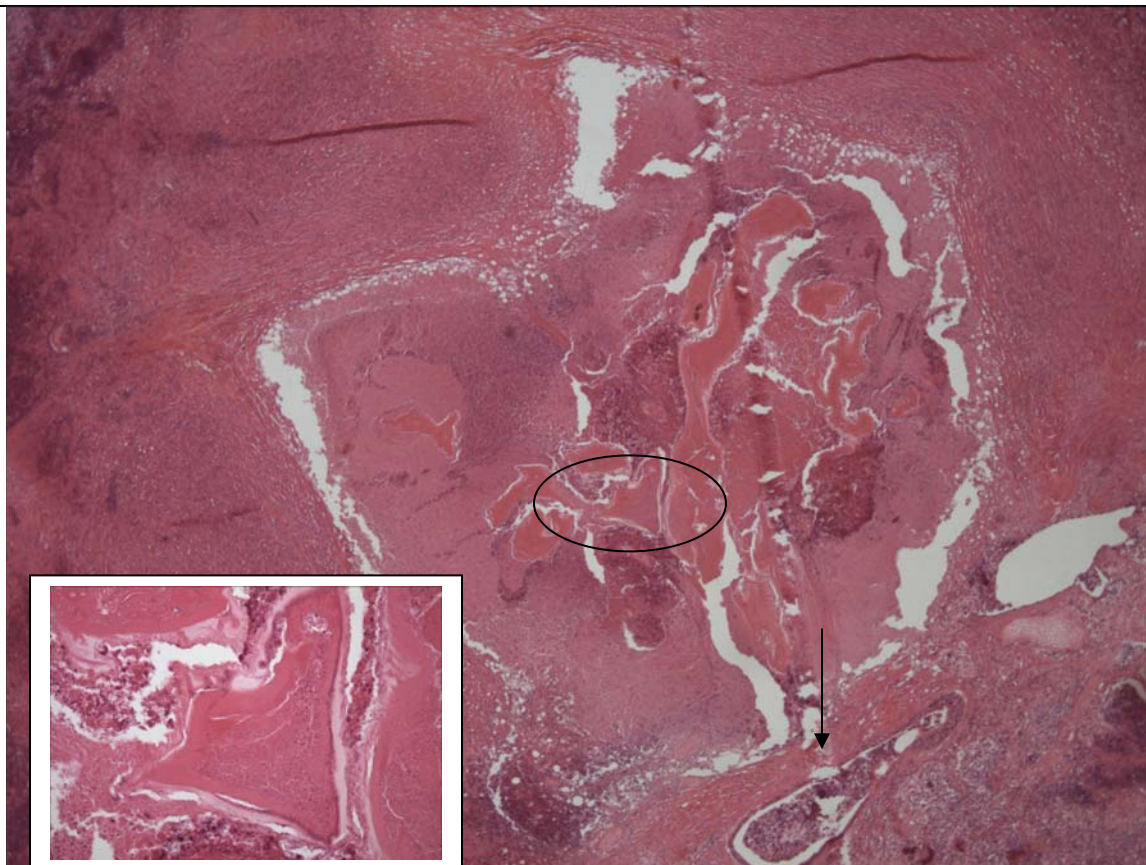


Figure 1. Lung. There is disruption of a bronchiole by large numbers of inflammatory cells surrounding necrotic cellular and nuclear debris, and remnants of metazoans (circle, and inset). Inflammatory cells expand smaller airways (arrow).

DATE:	REPORTING PATHOLOGIST:
22 Feb 05	David S. Rotstein, DVM, MPVM, DACVP

CETACEAN NECROPSY REPORT:
Pilot Whale Stranding, NC-15/16 Jan 2005

Field ID: RT13
 Accession Number: 05-3C
 Date: 15 Jan 2005
 Species: Globicephala macrorhynchus
 Location: Bodie Island, NC (lat-35.79290 long-75.53781)
 Sex: F (adult)
 TL: 297.0 cm

GROSS REPORT
 REPORTING INSTITUTION: NOAA Beaufort

Adapted from report received.
 History: Beached in Oregon Inlet, found 1-15-05, euthanized with Beuathanasia~5:30PM on 1-15-05. Last pilot whale to die.

External Examination. Left eye is eviscerated.

Location	Number	Comment
Upper Left	7	N/C
Upper Right	7	N/C
Lower Left	8	2 nd from front & 2 nd from back-chipped
Lower Right	8	N/C

Cardiovascular System. The pericardial sac is enlarged, lots of blood in there (Cardiac stick, presumptive).

Location	Measurement	Comment
Right Ventricular Freewall	7.0mm	
Left Ventricular Freewall	22mm	
Inteentricular Septum	31mm	

Musculoskeletal System. Joint fluid from the left scapulohumeral joint is yellow and gelatinous.

Respiratory System. There is a white nodule in the left cranial lobe that is approximately 1.0 cm in diameter.

Hematopoietic/Lymphoreticular System. The spleen measures 8.5 X 5.0 x 1.3 (cm). There is a small cleft. The pre-scapular lymph node is edematous, pale, and diffusely enlarged. The mesenteric lymph node is edematous. The lung lymph node is pale. The iliac lymph node is enlarged and edematous with scattered hemorrhagic foci.

Endocrine System. The thyroid gland is soft. The left adrenal gland measures 3.5 X 3.0 X 0.6 (cm).

Digestive System. The intestines measure 1697.0 cm.

Urinary System. The right and left kidneys measure 27.0 X 9.0 X 8.5 (cm) and 28.0 X 11.0 X 7.0 (cm), respectively. There is a handful of Monorogyma around the urinary bladder.

Reproductive System. The mammary gland measures 49 X 5.5 X 1.7 (cm). There is a divot ventrally. Renticles missing about 3.0 cm space. The right and left ovary measure 3.4 X 1.5 X 0.8 (cm) and 4.1 X 1.3 X 0.6 (cm), respectively. Ovaries are underdeveloped (unlikely prior ovogenesis/activity). The left uterine horn is flat and 1.5 cm in diameter.

ANCILLARY FINDINGS

Urinalysis (C. Harms):

Test	Result
Specific Gravity	1.039
Urobilinogen	0.2
Protein	trace
pH	6.0
Blood	Hemolyzed trace
Ketones	NEG
Bilirubin	NEG
Glucose	NEG
Collection	Catheter

TISSUES/SAMPLES RECEIVED
 REPORTING INSTITUTION: UNIVERSITY OF TENNESSEE

One bag labeled as "RT 13 10%NBF" and containing 23 free tissues is received. Representative sections are placed in Cassettes 1-9.

MICROSCOPIC FINDINGS
REPORTING INSTITUTION: UNIVERSITY OF TENNESSEE

Aorta (slide 1): No significant histologic findings (NSF).

Spleen (slide 1): Lymphoid follicles are prominent. There are scattered hemosiderophages.

Lymph Node, NOS (slide 1): Primary lymphoid follicles are present. There are scattered macrophages within intracytoplasmic, variably-sized 1 to 2 micron granular, black pigment (anthracosis).

Liver (slide 1): There is diffuse, moderate expansion of sinusoids by erythrocytes (congestion). There is mild, multifocal infiltration of portal tracts by plasma cells and fewer lymphocytes. There is mild, multifocal biliary hyperplasia.

Blubber (slide 2): There is a linear band of collagen that extends from the dermal/epidermal junction, approximately 1.0 mm (fibrosis) (Figure 1).

Lymph Node, NOS (slide 2): Secondary lymphoid follicles are present. There are increased macrophages and plasma cells within medullary spaces. There are scattered hemosiderophages and macrophages laden with black, granular intracytoplasmic pigment (anthracosis). There are multifocal melanocytes in the capsules (melanosis). There are occasional clear vacuoles within medullary cords.

Bronchus and Lung (slides 2 and 3): There is marked congestion of all vessels. There is diffuse, bronchial submucosal edema with a sprinkling of macrophages and eosinophils within the expanded stroma. Within occasional alveoli, there are increased macrophages. There is multifocal intra-alveolar erythrocyte extravasation (hemorrhage).

Adrenal Gland (slide 3): There is moderate congestion. There is focal, epineurial and endoneurial edema of a nerve bundle within the periadrenal adipose (Figure 2).

Urinary Bladder (slide 3): NSF.

Atrium (slide 4): NSF.

Ventricle (slide 4): NSF.

Lymph Node (slide 4). Secondary follicles are present. Within the center of the follicles, there is hyalinized, globular material (hyalinosis). Macrophages are increased within edematous medullary spaces.

Thyroid Gland (slide 5): Approximately 30% of follicular lumina are expanded by homogenous eosinophilic colloid. Remaining follicles are collapsed and lining cuboidal epithelial cells are sloughed (artifact).

Uterus (slide 5): The endometrium is lined by a single layer of low cuboidal epithelium. There are scattered lymphocytes and plasma cells within the endometrium.

Lymph Node, NOS (slide 5): There is diffuse edema. Lymphocytes are decreased slightly in number. There are increased macrophages and scattered neutrophils within subcapsular sinuses and medullary spaces.

Kidney (slide 5): There are scattered foci of plasmacytic interstitial infiltration with associated loss of tubules (Figure 3).

Mammary Gland (slide 6): Glands are collapsed and lined by a single layer of cuboidal epithelial cells. Ducts contain eosinophilic granular substance and fewer macrophages. There are scattered lymphocytes in the stroma.

Skeletal Muscle (slide 6): NSF.

Brain and Spinal Cord (slides 7-9): Seven sections are examined. There is multifocal myelin sheath swelling. Eosinophilic, proteinaceous fluid accumulates around approximately 50% of vessels.

MORPHOLOGIC DIAGNOSES

Urogenital System:

1. Kidney: Interstitial nephritis, lymphoplasmacytic, multifocal, mild with interstitial fibrosis.

2. Uterus:

a. Anestrus (glandular inactivity).

b. Endometritis, non-suppurative, multifocal, minimal.

Nervous System:

1. Brain Spinal Cord: Myelin sheath swelling, multifocal.

2. Adrenal Gland, Nerve: Edema, epineurial and endoneurial.

Integumentary System:

1. Blubber: Fibrosis, focal.

2. Mammary gland: Atrophy (non-secretory).

Hematopoietic/Lymphoreticular System:

Lymph Node: Edema, moderate.

Hepatobiliary System:

Liver: Congestion, diffuse, moderate.

Respiratory System:

Lung: Congestion, moderate with intra-alveolar hemorrhage.

FINAL DIAGNOSES/INTERPRETATIVE SUMMARY

Interstitial nephritis
Lymph node edema
Myelin sheath swelling

A cause for stranding was not evident in the examined sections. Swelling of myelin sheaths in the central nervous system is likely associated with hypoxia rather than a primary condition. There was mild interstitial nephritis which was unlikely to have result in impaired renal function. There was focal fibrosis in the blubber indicating a prior wound to this site. There was no active inflammation at this region.

FIGURES

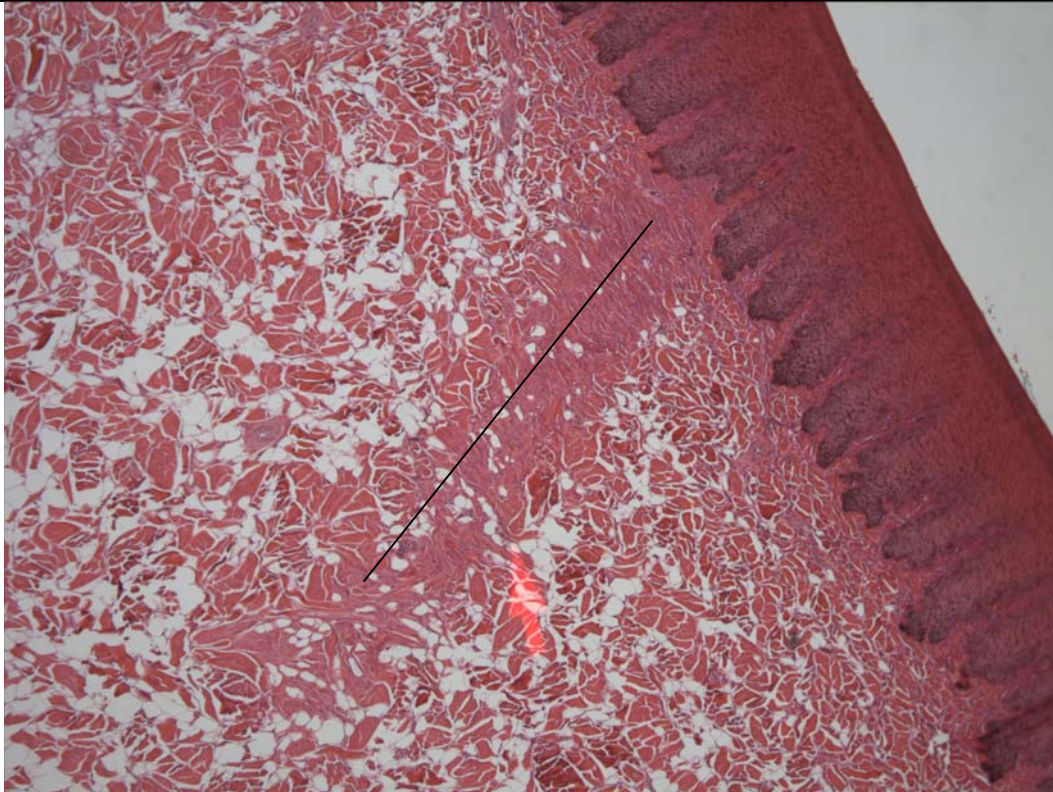


Figure 1. Blubber. There is a focal region where collagen bundles are densely packed indicating fibroplasia. This was likely a prior traumatic site.

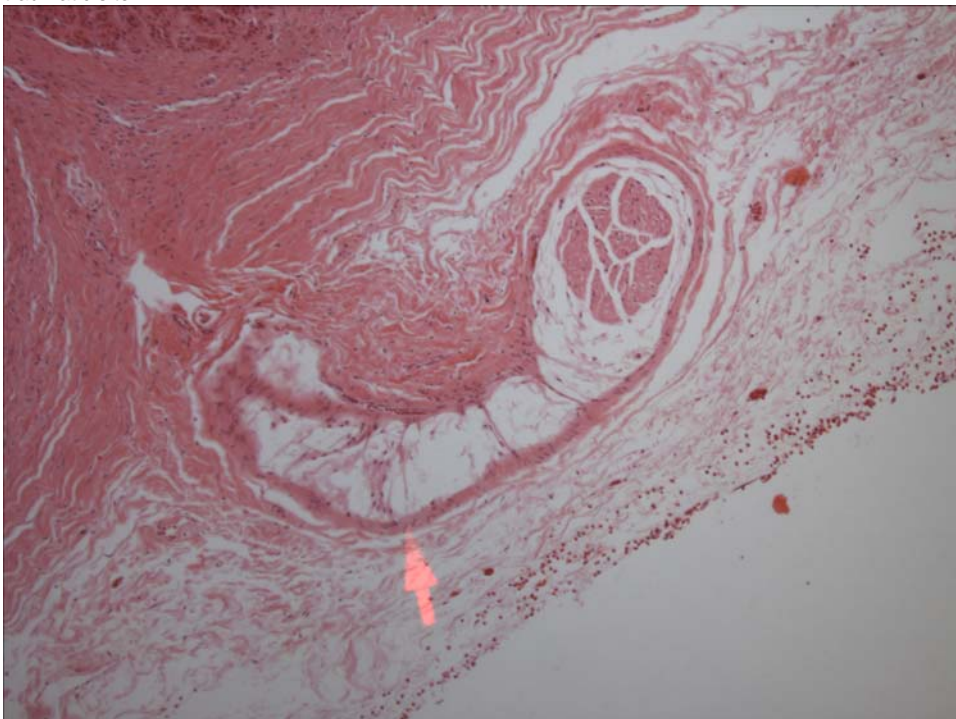


Figure 2. Adrenal Gland. There is swelling (edema) around nerve fascicles.

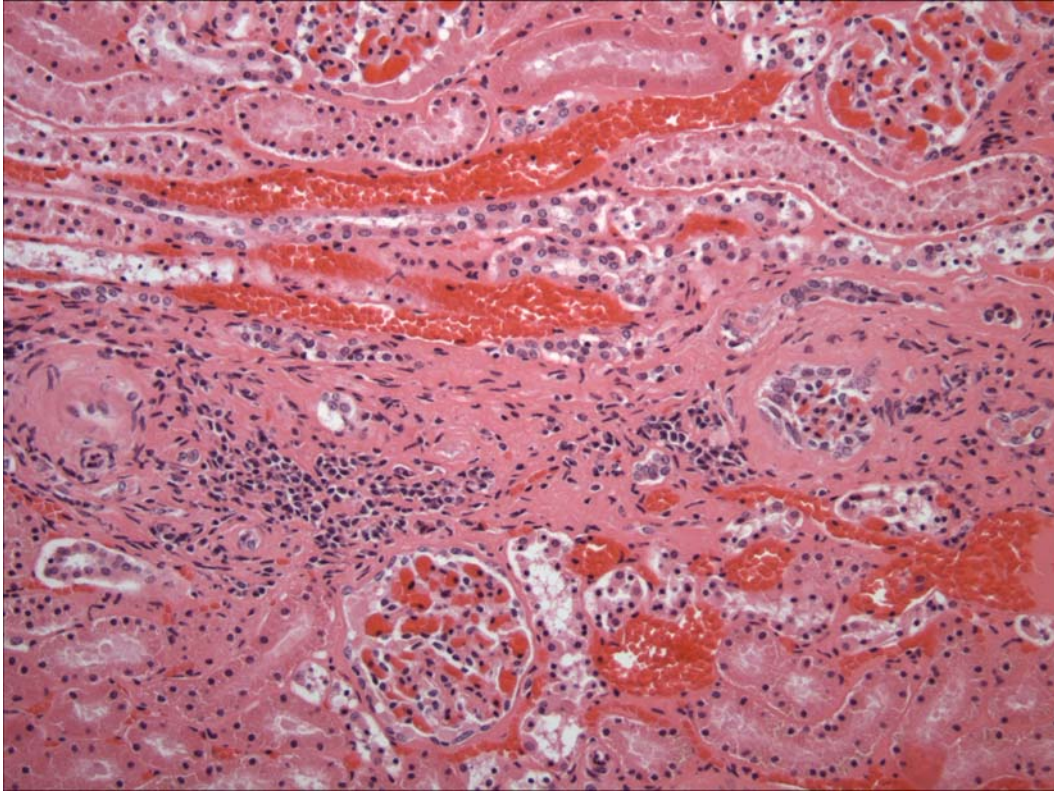


Figure 3. Kidney. There is regional loss of tubules with replacement by fibrous connective tissue and plasma cells.

PENDING			
TEST/HISTO	PURPOSE	SITE	RESULT
Oil Red O	Fat Stain	Lymph Node	6/17/2005: perinodal fat is positive; vacuoles are rare and non-staining in the parenchyma.

DATE: 22 Feb 05 17 June 2005 (Fat Stain)	REPORTING PATHOLOGIST: David S. Rotstein, DVM, MPVM, DACVP
--	---

CETACEAN NECROPSY REPORT:
Pilot Whale Stranding, NC-15/16 Jan 2005

Field ID: RT19
Accession Number: 05-4C
Date: 15 Jan 2005
Species: Globicephala macrorhynchus
Location: Bodie Island, NC (lat-35.79290 long-75.53781)
Sex: F (adult)
TL: 358.0 cm

GROSS REPORT
REPORTING INSTITUTION: NOAA Beaufort

Adapted from report received.

External Examination. Fl marks present, but healed→not cause of death. Marks included:

- a) Two (2) healed scars on upper left lip with associated broken teeth.
- b) Healed marks on leading edge of dorsal fin.

Cardiovascular System. Lots of fat around the heart.

Respiratory System. Blood froth in lungs. There are little (~1cm), white discolored areas on lung surface. Lots of blood in bronchi and lung.

Hematopoietic/Lymphoreticular System. The lung lymph node is discolored and on cut surface has multiple white and dark patches.

Urinary System. The urinary bladder was empty.

Reproductive System. There is a heavy load of Monorymgma in peri-uterine ligaments. There is no evidence of lactation. There are Monorygma in ventral blubber near mammary glands. Copora were present on both ovaries. Not pregnant.

ANCILLARY FINDINGS

N/A

TISSUES/SAMPLES RECEIVED
REPORTING INSTITUTION: UNIVERSITY OF TENNESSEE

One bag labeled as "RT 19 10%NBF" containing 15 free tissues and 3 labeled cassettes is received. Cassettes are labeled as "Prescapular Lymph Node", "Lung Lymph Node", and "Mesenteric Lymph Node" and placed in Cassettes 1, 5, and 6, respectively. Representative sections from remaining tissues are placed in Cassettes 1-8. Received on 2 March 2005 is one bag of tissue labeled as stomach. Representative sections are placed in Cassettes 9 and 10.

MICROSCOPIC FINDINGS
REPORTING INSTITUTION: UNIVERSITY OF TENNESSEE

Prescapular Lymph Node (slide 1): There is moderate lymphoid hyperplasia. There are increased macrophages within medullary spaces. There are increased hemosiderophages.

Liver (slide 1): There is diffuse congestion. Nearly 80% of hepatocytes contain intracytoplasmic, granular, golden pigment (ceroid-lipofuscin vs. hemosiderin).

Blubber (slide 1): No significant histologic findings (NSF).

Heart (slide 2): NSF.

Lung (slide 2): Approximately 70% of alveoli are flooded with eosinophilic, proteinaceous fluid with interspersed macrophages (pulmonary edema).

Aorta (slide 2): NSF.

Urinary Bladder (slide 3): NSF.

Spleen (slide 3): Periarteriolar lymphoid sheaths are mildly hyperplastic.

Uterus (slide 3): There are diffuse vascular changes. Focally, there is aneurismal dilatation of a venule which is 2.0 cm in diameter and filled with blood (Figure 1). Arteries exhibit mild to moderate medial degeneration, and segmental perivascular fibrosis (Figure 2). Within the endometrium, there are scattered lymphocytes and plasma cells. Glandular density is markedly reduced. The endometrium is lined by a single layer of low cuboidal epithelium. In the myometrium, there is vascular ectasia and a single vessels contains a segmentally, focally adherent thrombus.

Atrium (slide 3): NSF.

Adrenal Gland (slide 4): NSF.

Kidney (slide 4): There is diffuse, mild to occasionally moderate thickening of Bowman's capsule.

Lung Lymph Node (slide 5): Lymphoid follicles are moderately cellular. There is a mild sinus histiocytosis and expansion of medullary spaces by lightly eosinophilic and granular fluid (edema).

Bronchus and Lung (slide 5): There is multifocal intra-alveolar erythrocyte extravasation (hemorrhage).

Mesenteric Lymph Node (slide 6): Lymphocytes are in adequate numbers. There are increased plasma cells and macrophages within medullary spaces.

Spinal Cord (slide 6): NSF.

Unidentified Tissue (slide 7): Two sections of an autolyzed tissue are present.

Epaxial Muscle (slide 8): NSF.

First Stomach (slides 9 and 10): There is focally extensive mucosal epithelial hyperplasia flanking a 1.5 cm segment of epithelial loss. There is intracytoplasmic swelling (hydropic degeneration) of the adjacent superficial mucosal epithelium. There is an absence of inflammatory cells underlying the defect.

MORPHOLOGIC DIAGNOSES

Reproductive System:

Uterus:

1. Endometritis, lymphoplasmacytic, diffuse, mild.
2. Angiopathy (medial degeneration).
3. Focal endometrial aneurismal dilatation.

Hematopoietic/Lymphoreticular System:

Mesenteric Lymph Node: Edema and histiocytosis, diffuse, moderate.

Respiratory System:

Pulmonary edema, diffuse, moderate.

Digestive System:

Stomach: Ulcer, focal.

FINAL DIAGNOSES/INTERPRETATIVE SUMMARY

Endometritis

Histologic findings do not indicate a cause of death in this cetacean. Pulmonary edema likely represents a perimortem event. Uterine lesions were interesting. Vascular changes suggest chronic degenerative changes. In horses, this is associated with decreased ability to maintain a conceptus.¹ The focal vascular aneurismal dilatation in the endometrium is reminiscent of that observed in rabbits.² In rabbits, there may be bleeding from the site. The reproductive effects in this cetacean are speculative.

References:

1. Gruninger et al. 1998. J Comp Pathol 119: 293-309.
2. Bray, M. V. et al. 1992. Lab Anim Sci 42: 360-362.

FIGURES

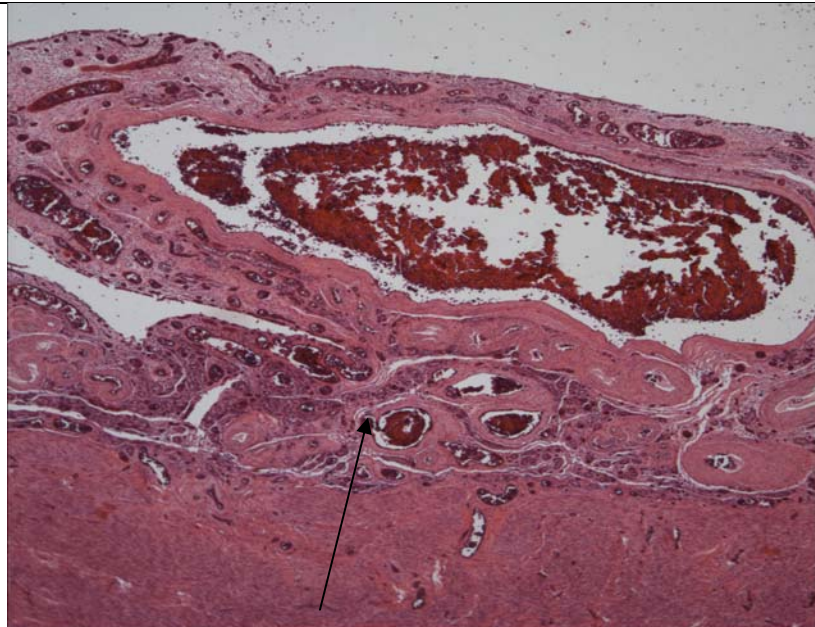


Figure 1. Uterus. Vascular dilatation within the endometrium (arrow).

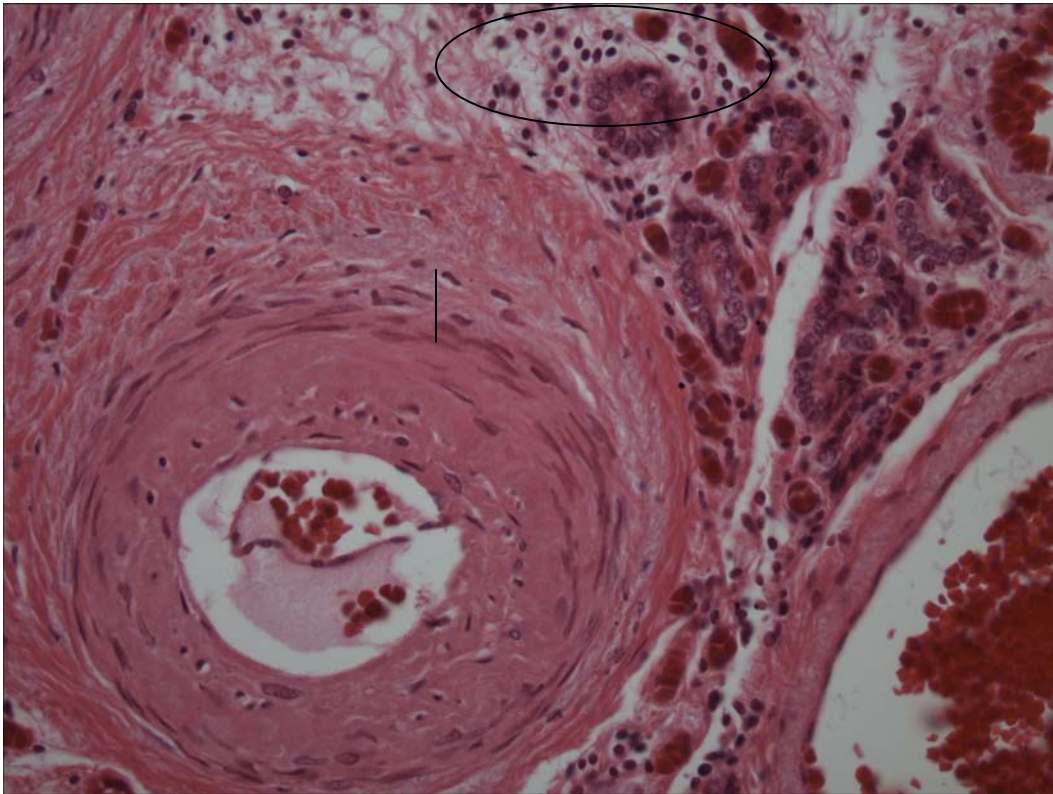


Figure 2. Endometrium. There are mononuclear cells within the endometrial stroma (circle). There is perivascular proliferation of fibrocytes (line).

DATE:

REPORTING PATHOLOGIST:

23 Feb 05 / 25 April 05

David S. Rotstein, DVM, MPVM, DACVP

**CETACEAN NECROPSY REPORT:
Pilot Whale Stranding, NC-15/16 Jan 2005**

Field ID: RT20/NC05-009
 Accession Number: 05-31C
 Date: 15 Jan 2005
 Species: Globicephala macrorhynchus
 Location: Bodie Island, NC (lat-35.82, long-75.55)
 Sex: M
 TL: 251.0 cm

GROSS REPORT

REPORTING INSTITUTION: NOAA Beaufort

Adapted from hard copy of necropsy field notes.

FI (fishery interaction) marked present, but healed→not cause of death. Marks include: line mark on head (near angle of mouth) that is 1.5 X 1 cm. Puncture wounds on left peduncle-healed (2.5 cm diameter).

Reproductive: The left testis is 10.2 X 2.4 X 1.4 cm and right testis is 12.1 X 2.1 X 1.4 cm.

Healed fishery interaction.

Head Dissection completed 15 Feb 2005. Findings reported by C. Harms:

Additional head necropsies on five short-finned pilot whales. All part of mass stranding from 15 January 2005. Four heads started thawing on 13 February and one small head on 14 February for necropsy today, performed at NMFS Beaufort Laboratory.

Both eyes are eviscerated and right eye is proptosed. There is a dermal abrasion caudodorsal to right eye (9 x 4 cm) from being dragged on beach. There is a scar (3.2 x 2 cm) ventrally, just to left of midline at level of gape. There is a small (7 x 3 mm) trilobular raised (1 mm) area of epithelial hyperplasia just left of midline, rostrally on the lower goose-beak. There is a sublingual lymph node noted, uniformly dark pink on cut surface with a few light mottled areas.

Subcutis: no bruising is noted.

Musculoskeletal and connective tissue: rostral/premaxilla bone is fractured bilaterally, possibly during melon removal. Extramandibular fat is white and nonhemorrhagic bilaterally. There is hemorrhage in caudally in the mandibular fossae, associated with vascular plexus, more pronounced on right.

Ears: Left external auditory meatus is missing completely. Blubber section of right auditory meatus is missing, no hemorrhage near base.

Brain: There is mild to moderate congestion on surface of cerebrum, worse on left.

Brain weight 2469 g

There is a light load of nematodes in both pterygoid sinuses. there is a medial hematoma in both pterygoid sinuses.

Major gross findings: parasitic sinusits.

Collected Samples:

In formalin: both periotic bones, premaxilla fracture, sections of brain.

UNC-W collected mandibular fat.

Stomach Contents Data Sheet:

Site	Full	Empty	Contents
Esophagus	308g	300g	8g
Forestomach	748g	725g	23g
Main	546g	527g	19g
Pyloric	182g	164g	18g

Comment:

Pyloric: No ulcers, <5 nematodes, has extra pouch

Esophagus: No ulcers, <10 nematodes

Main: light nematode load, 3 granulated ulcers: 21 x 244mm, 18 X 15mm, and 28 X 29mm

Fore: No ulcers. Light nematode load, empty stomach

ANCILLARY FINDINGS

N/A

TISSUES/SAMPLES RECEIVED

REPORTING INSTITUTION: UNIVERSITY OF TENNESSEE

Received is one bag of formalin labeled as "RT20 10% Formalin". There are seven labeled cassettes and both ears. Cassettes are labeled as "Cerebellum" (2), "Cerebrum" (2), "Brainstem" (2), and "Pituitary Gland". Representative sections of cerebellum are placed in Cassettes 1-2, cerebrum in Cassettes 3-4, brainstem in Cassettes 5-6, and pituitary gland in Cassette 7.

MICROSCOPIC FINDINGS

REPORTING INSTITUTION: UNIVERSITY OF TENNESSEE

Cerebellum (slides 1-2): No significant histologic findings (NSF).

Cerebrum (slides 3-4): NSF.

Brainstem (slides 5-6): NSF.

Pituitary Gland (slide 7): NSF.

MORPHOLOGIC DIAGNOSES

Brain and Pituitary Gland: No significant histologic findings.

FINAL DIAGNOSES/INTERPRETATIVE SUMMARY

Open

The cause of this cetacean's stranding was not evident in the examined section of central nervous system. Systemic disease cannot be excluded.

DATE:
26 Apr 05

REPORTING PATHOLOGIST:
David S. Rotstein, DVM, MPVM, DACVP

Cetacean Necropsy Report
Pilot Whale Stranding, NC-15/16 Jan 2005

Field ID: RT22
Accession Number: 05-5C
Date: 15 Jan 2005
Species: Globicephala macrorhynchus
Location: Cape Hatteras, NC (lat-35.23412, long-75.53443)
Sex: F
TL: 218.0 cm (Sub-Adult)

GROSS REPORT

REPORTING INSTITUTION: NOAA Beaufort

Report adapted from necropsy notes and Pilot Whale Head Necropsy Data Sheet for 1/15/2005 Bodie Island Mass Stranding.

General Examination. There are healed FI (fishery interaction) marks; these are not considered as a cause of death. Marks include healed scars on upper lip with associated broken teeth.

Hepatobiliary System. There are firm, hard nodules in the liver.

Sinuses: There is a very light Nasitrema load in the left and right pterygoid sinuses.

Nervous System. The brain weighs 2.75 kg.

ANCILLARY FINDINGS

N/A

TISSUES/SAMPLES RECEIVED

REPORTING INSTITUTION: UNIVERSITY OF TENNESSEE

Received are two bags of formalin-fixed tissues labeled as "RT22 10% Formalin". One bag is received 25 Jan 2005 and the second bag is received 1 Feb 2005. In the first bag, there are 3 sagittal sections of the brain including cerebrum, cerebellum, and brainstem. Representative sections 6-14. The second bag contains 3 free tissues. Representative sections are placed in Cassettes 1-5.

MICROSCOPIC FINDINGS

REPORTING INSTITUTION: UNIVERSITY OF TENNESSEE

Liver (slide 1): Two sections are examined. Random to portal, 0.5 to 1.0 cm nodules efface the hepatic parenchyma (Figure 1). The nodules are composed of a central core of laminated acellular collagen. Adjacent hepatocytes are mildly attenuated (compression atrophy) and in regions involving portal tracts, there are peripheral bile ducts. Multifocally, there is moderate to occasionally marked portal fibrosis with associated biliary hyperplasia and mild arteriolar medial hypertrophy (Figure 2). There is mild, diffuse sinusoidal expansion by erythrocytes (congestion). In one section, there are multiple, submarginal, 40 to 100 micrometer, irregular round to oval cavities of clearing with occasional scant intra-cavitary granular eosinophilic material and few extravasated erythrocytes (Figure 3) adjacent to the nodules. Adjacent hepatocytes are mildly compressed. Dilated foci do not have an endothelial lining.

Firm, White Tissue (slide 2): There is a sagittal section of two metazoans that are 1.0 cm in width. The metazoans have a dense tegument and solid parenchymatous body cavity. Gonads are abundant and a digestive tract absent.

Cyst (slides 3-5): The examined sections consist of a well-demarcated, densely encapsulated, unlined chronic granuloma. The central core is composed of eosinophilic and basophilic cellular debris admixed with granular to irregular round and variably-sized mineral (dystrophic mineralization). Within the wall of the capsule, there are moderate numbers of plasma cells, lymphocytes, fewer eosinophils, and multifocal aggregates of macrophages. Macrophages contain intracytoplasmic, golden-brown granular pigment (ceroid-lipofuscin vs hemosiderin).

Brain (slides 6-14): There is diffuse, mild to moderate congestion. Occasional neurons contain intracytoplasmic, brown granular pigment (ceroid-lipofuscin). Within the brainstem and spinal cord, there are occasional myelin sheaths that are swollen.

MORPHOLOGIC DIAGNOSES

Hepatobiliary System:

Liver:

- a. Hepatitis, granulomatous, random to portal, multifocal, chronic.
- b. Portal fibrosis, multifocal, moderate with biliary hyperplasia and vascular medial hypertrophy.

Abdominal Cavity: Peritonitis, granulomatous.

Location, NOS: Cestodiasis.

FINAL DIAGNOSES/INTERPRETATIVE SUMMARY

Hepatic granulomas (chronic)
Intra-abdominal granuloma

Parenchymal organs and structures examined in this case were limited to the liver, and an intra-abdominal "cyst". However, hepatic lesions proved extremely interesting in this case.

Granulomas were chronic and had associated portal fibrosis and formation of pockets that either were devoid of contents or contained eosinophilic granular material. The granulomas indicate a site of prior bacterial, fungal, or parasitic infection. While, an inciting agent was not present, parasitic migration is favored as it is believed the route of travel was via the biliary tree.

The cavities within the liver were near the granulomas and likely represent sites of hepatic loss, vascular dilatation, or bacterial gas production, though bacteria were not observed. Chronic and acute gas emboli were considered but designated unlikely in this case given the association of these cavities to the inflammatory foci. These likely represents sites of either parenchymal loss or, if the granulomas are bacterial in origin, gas production. An acute air embolus is considered less likely as there was no evidence of associated hemorrhage; in addition, chronic air embolism is unlikely given the lack of a fibrous capsule. Cavities did not stain with immunohistochemical stains for endothelium (Factor VIII), nor was there evidence of a fibrous capsule.

The intra-abdominal "cyst" is a well-encapsulated granuloma. Contents are composed of debris, necrotic cellular material, and mineral. Causes would include bacterial, fungal, foreign body, or necrotic fat (lipoma). There was no evident causative agent.

It is possible that the abdominal granulomas and hepatic granulomas stem from a similar cause.

FIGURES

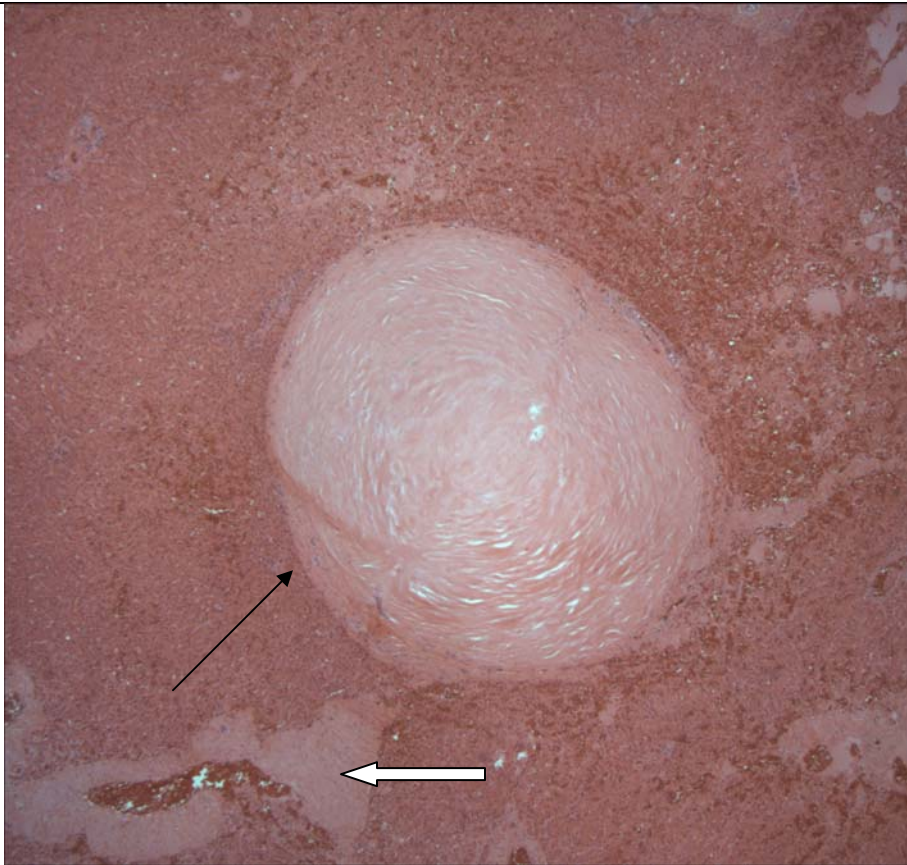


Figure 1. Liver. There is a granuloma compressing adjacent hepatocytes. The granuloma has a central core of mature collagen (arrow). An adjacent vessel exhibits medial hypertrophy (block arrow).

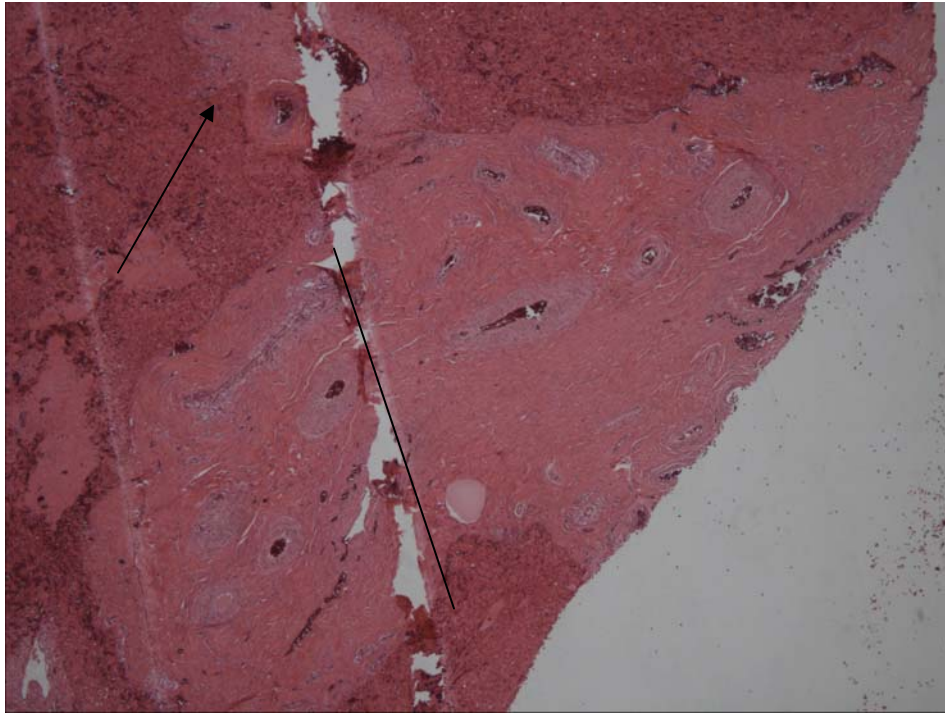


Figure 2. Liver. There is a wide swath of mature collagen in this portal tract. Bile ducts are hyperplastic and vessels have thickened tunica media. The clear space is artifact (arrow).

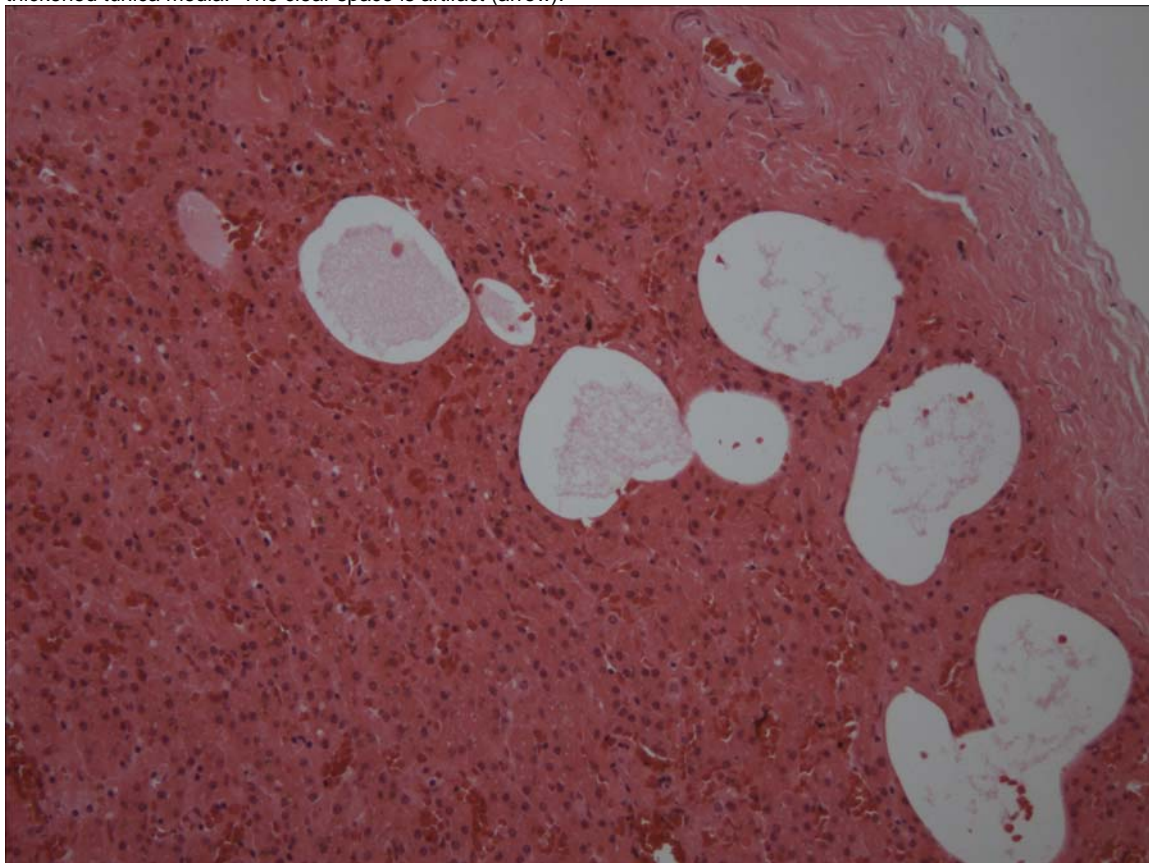


Figure 3. Liver. There are numerous, occasionally interconnecting cavities compressing adjacent hepatic parenchyma adjacent to granulomas. A lining is not evident.

PENDING			
TEST/HISTO	PURPOSE	SITE	RESULT
Oil Red O	Fat Stain	Liver	Negative for lipid

DATE: 14 April 2005	REPORTING PATHOLOGIST: David S. Rotstein, DVM, MPVM, DACVP
------------------------	---

CETACEAN NECROPSY REPORT:
Pilot Whale Stranding, NC-15/16 Jan 2005

Field ID: RT24
Accession Number: 05-6C
Date: 15 Jan 2005
Species: Globicephala macrorhynchus
Location: Bodie Island, NC (lat-35.78347, long-75.534157)
Sex: F (adult)
TL: 330.0 cm

GROSS REPORT

REPORTING INSTITUTION: NOAA Beaufort

Adapted from report received. All other organs are moderately autolyzed.

External Examination. Fl marks present, but healed → not cause of death. Marks include:
Line Marks on upper lip and mandible.

Musculoskeletal System. Normal scapulohumeral joint fluid.

Respiratory System. White foam in trachea.

Digestive System. About five (5) nematodes found in esophagus. Stomach collected whole.

Reproductive System. Pregnancy in left horn. Fetus is 54.5 cm female. The fetus is frozen whole.

Nervous System. Cranial third melon sample obtained. In the left pterygoid sinus, the epidermis is thickened, green and there are small numbers of parasites (Etiologies: Nasitrema sp. and Stenurus sp.). In the right pterygoid sinus, the epidermis is extremely thickened (1cm). There is a mild load of parasites (Nasitrema sp.). There is patchy subdural hemorrhage (Figure 1).

ANCILLARY FINDINGS

N/A

TISSUES/SAMPLES RECEIVED

REPORTING INSTITUTION: UNIVERSITY OF TENNESSEE

Received is one bag of formalin labeled as "RT24 10% Formalin". Submitted are three sections of brain. There is patchy, multifocal subdural hemorrhage ranging from 3 X 3 (cm) to 5 X 5 (cm). Received on 2 March 2005 is one bag of tissue labeled as stomach. Representative sections are placed in Cassettes 13 and 14.

MICROSCOPIC FINDINGS

REPORTING INSTITUTION: UNIVERSITY OF TENNESSEE

Brain (slides 1-12): Multifocally, in the cerebral cortex and to a lesser degree, cerebellum, there is moderate to marked expansion of the arachnoid and pia mater (leptomeninges) by large numbers of extravasated, intact erythrocytes (hemorrhage) (Figure 2) within scattered, small pools of eosinophilic, proteinaceous fluid (serum) (Figure 3). Erythrocytes track into sulci. Meningeal vascular channels are moderately to markedly ectatic and filled with erythrocytes (Figure 4). Subjacent to the hemorrhage, there is regional vacuolation of the cortical neuropil. Multifocally, there is spongiosis of the gray matter (Figure 5) and multifocal, perivascular accumulation of eosinophilic, globular substance (serum). There is multifocal hemorrhage within the neuropil of the gray and white matter in all regions of the brain.

Spinal Cord (slide 2): There is multifocal myelin sheath swelling within the dorsal and lateral funiculi.

Stomach, First (slides 13 and 14): Within the submucosa, there are cross-sections of three metazoans (Figure 6). The metazoans are 60 to 100 microns in width with a 6 to 8 micron cuticle, polymyarian/coelomyarian musculature, pseudo-coelom, and a complete digestive tract lined by a single layer of irregular cuboidal cells. There is an exceedingly sparse inflammatory cell reaction.

MORPHOLOGIC DIAGNOSES

Nervous System:

Brain:

1. Leptomeningeal (arachnoid, pia) hemorrhage, multifocal to coalescing, severe with vascular ectasia, serum exudation, and peripheral cerebral cortical vacuolation.
2. Spongiosis, multifocal.

Spinal Cord:

1. Myelin sheaths swelling, multifocal.

Digestive System:

Stomach, Main, Submucosa: Nematodiasis, mild.

FINAL DIAGNOSES/INTERPRETATIVE SUMMARY

Leptomeningeal Hemorrhage

The most striking feature of this brain grossly and histologically was the severe hemorrhage within the meninges. Hemorrhage was present on the parietal, occipital and temporal lobes (see [Figure 1](#)). Based upon human forensic studies, the presence of erythrocytes that are intact, absence of macrophages and fibroblasts (clean-up and repair) place this occurrence at less than 24 hours.¹ A subdural hematoma occurs when a fibroblastic membrane is formed. This was not observed in the examined sections. The amount of blood present and associated cerebral changes likely contributed to debilitation in this animal and to its demise.

The cause of hemorrhage is likely traumatic associated with vascular shearing with other possible etiologies include coagulative disorders, or spontaneous hemorrhage. There was no evidence of vasculitis or fibrinoid necrosis of vessels. Unfortunately, sections from other organs were not available to determine if this was a systemic process. This seems less likely given the lack of such findings on gross necropsy.

Trauma is a fairly loose term to describe injuries that may have been direct (calvarium fracture, concussive force) or those that may be secondary to blasts, sonic booms, etc. Calvarial fractures were not described in the gross report, and thus, this is an unlikely cause of the hemorrhage. Concussive force (contrecoup) could occur if the animal was struggling on the beach. Acoustic or blast trauma are additional considerations in this case as subdural hemorrhage has been observed in stranded cetaceans in the Bahamas² and Canary Islands³. However, in the beaked whales from the Canary Islands, hemorrhage within the neuropil of the brain was also observed. This was not in evidence in this case. Other considerations for hemorrhage include arteriovenous fistula, aneurysm, and space occupying mass (neoplasia). Evidence to support these was not identified. Spongiotic changes in the gray matter were likely hypoxia/ischemia related. Myelin sheath swelling of spinal cord white matter funiculi is likely of similar causation. Fat emboli are not observed in the brain with special stains for fat (Oil Red O).

Nematodes are present within the submucosa and likely represent a recent migration of parasites as there is not an appreciable inflammatory response.

References:

1. Leestma, J. E. Forensic neuropathology. In *Neuropathology: The Diagnostic Approach*. Ed. Garcia, J.H. Mosby Press. Pp: 475-425.
2. Evans, D. L. and England, G. R. 2001. Joint Interim Report-Bahamas Marine Mammal Stranding Event of 15-16 March 2000.
3. Fernandez, A. et al. 2005. "Gas and fat embolic syndrome" involving a mass stranding of beaked whales 9family Ziphiidae) exposed to anthropogenic sonar signals. *Vet Pathol* 42: 446-457.

FIGURES

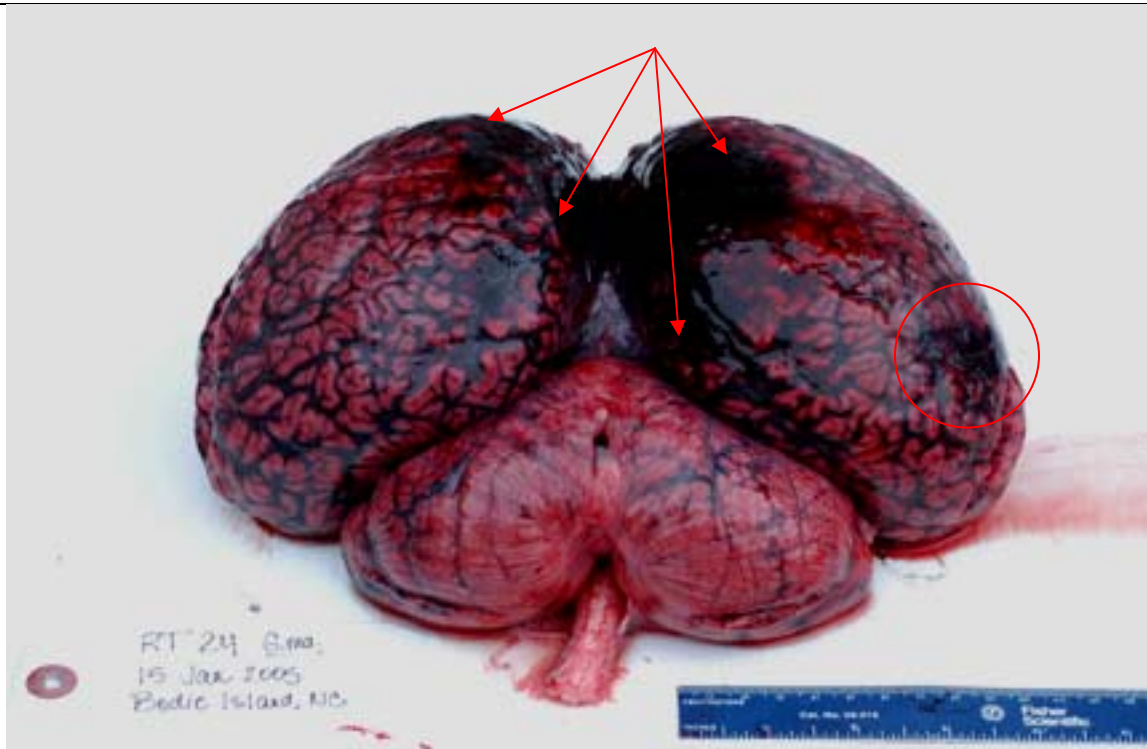


Figure 1. Brain. There is subdural hemorrhage involving the parietal lobes (arrow) and the temporal lobe (circle). Gross Photo by W A McLellan.

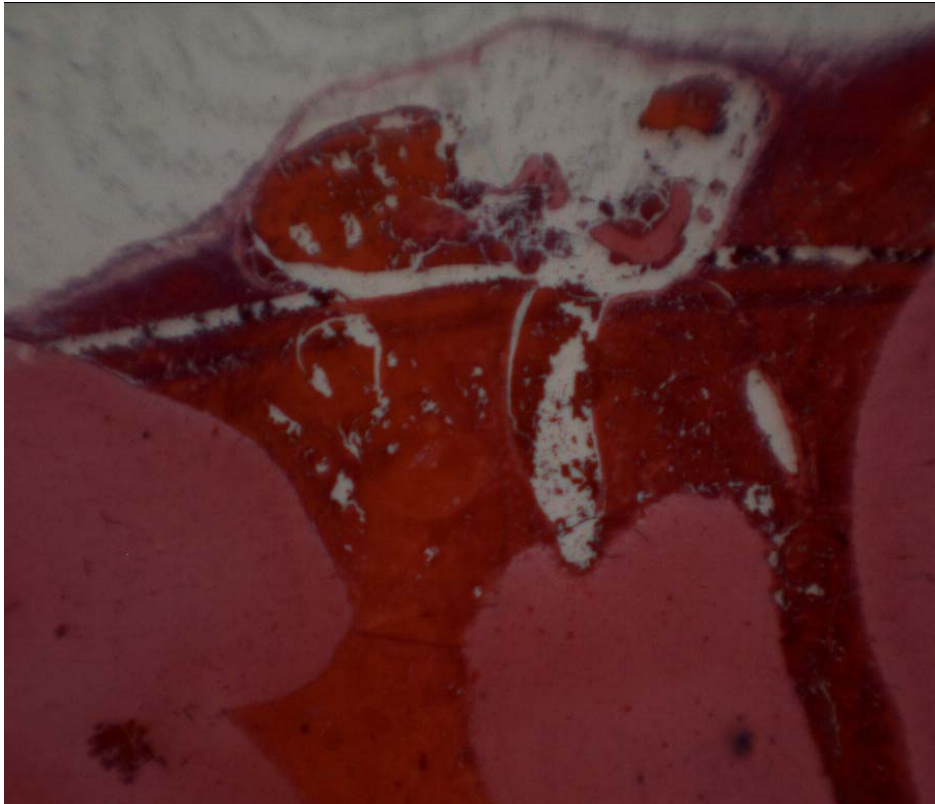


Figure 2. Subgross of hemorrhage within the meninges that extends into sulci. Vessels are dilated. Haziness is an artifact of subgross photo procedure.

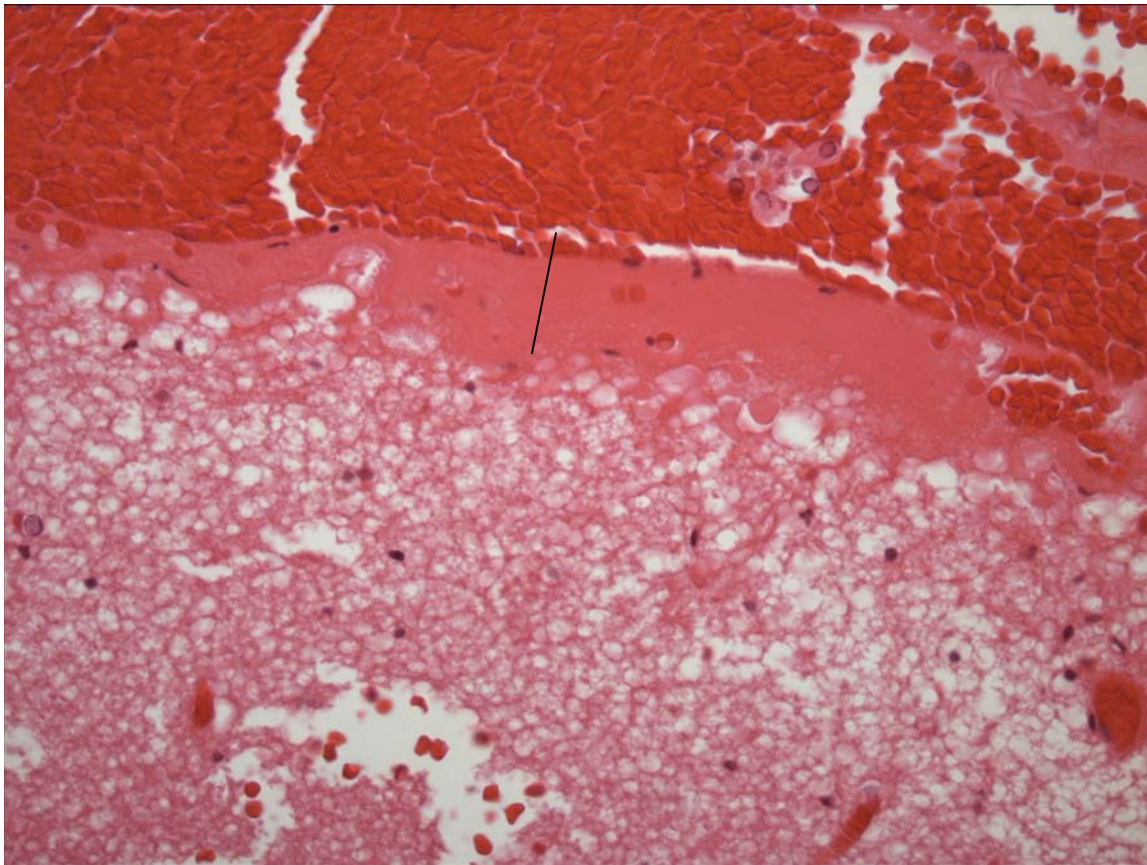


Figure 3. Brain. There is a rim of proteinaceous transudate (line) between the hemorrhage and superficial cerebral cortex which is vacuolated.

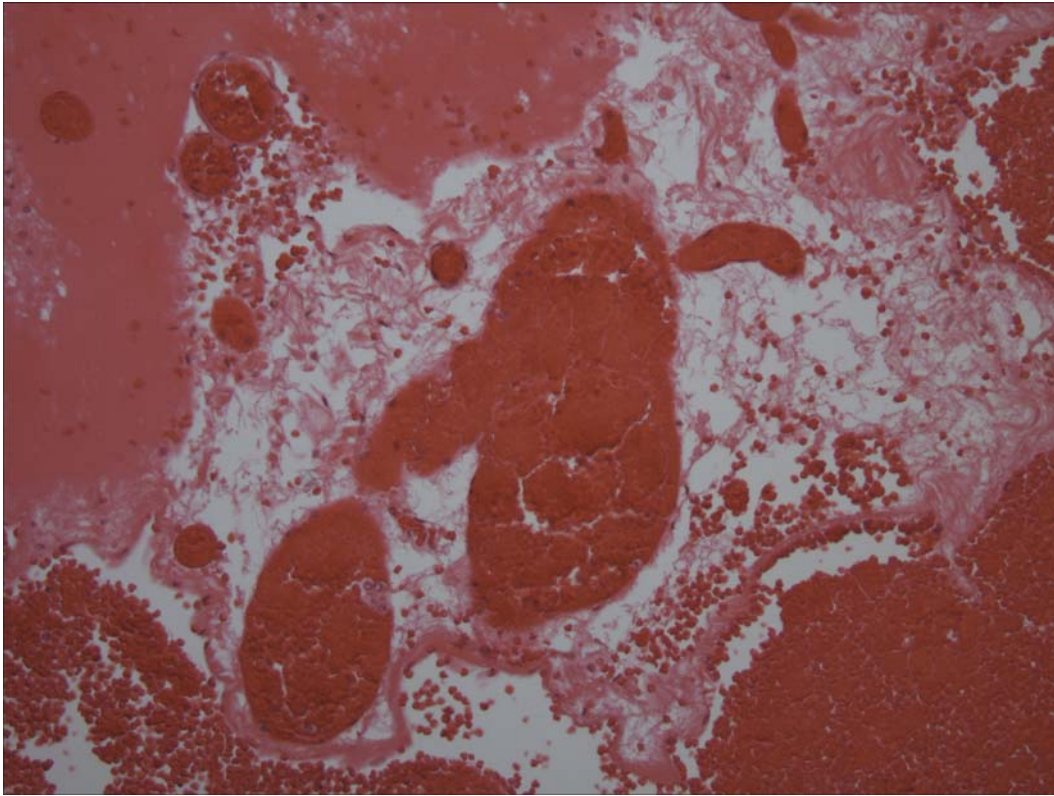


Figure 4. Meninges. Vascular channels are ectatic and packed with erythrocytes. Erythrocyte extravasation extends into the meninges.

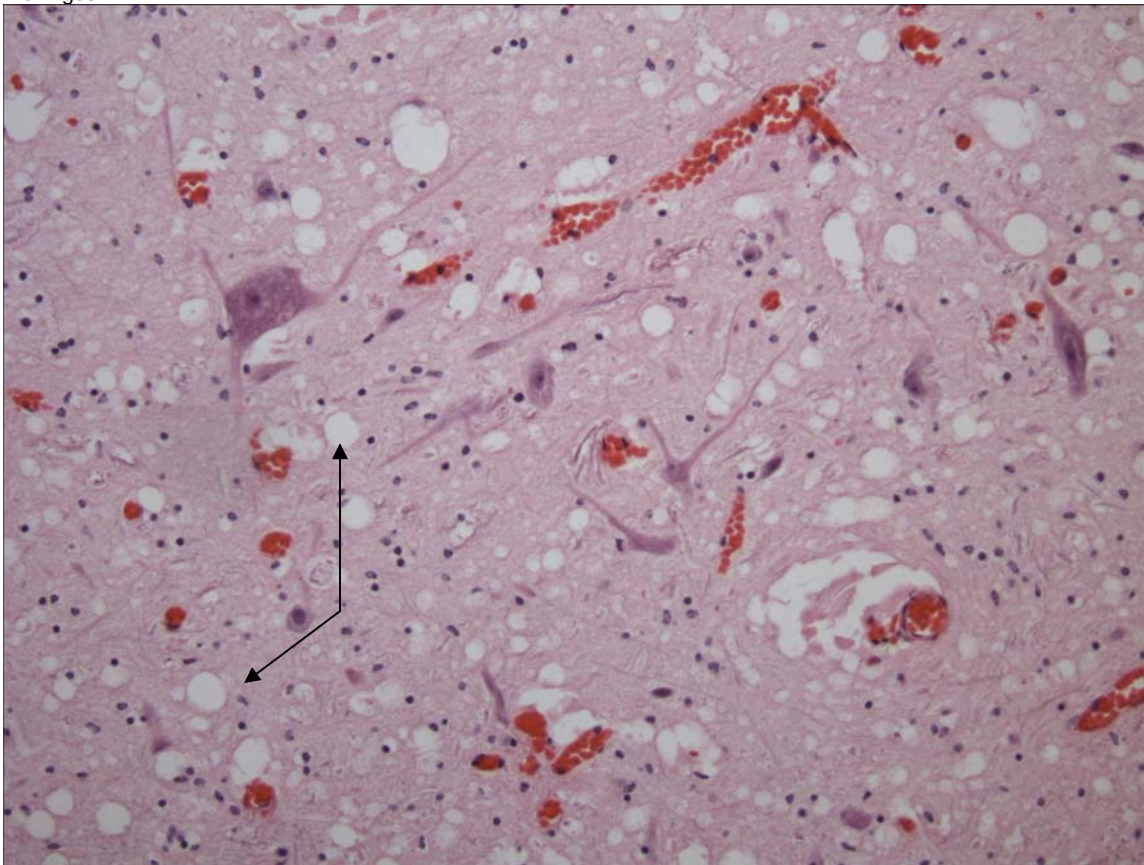


Figure 5. Brain, Gray Matter. There is spongiosis of the neuropil (arrow).

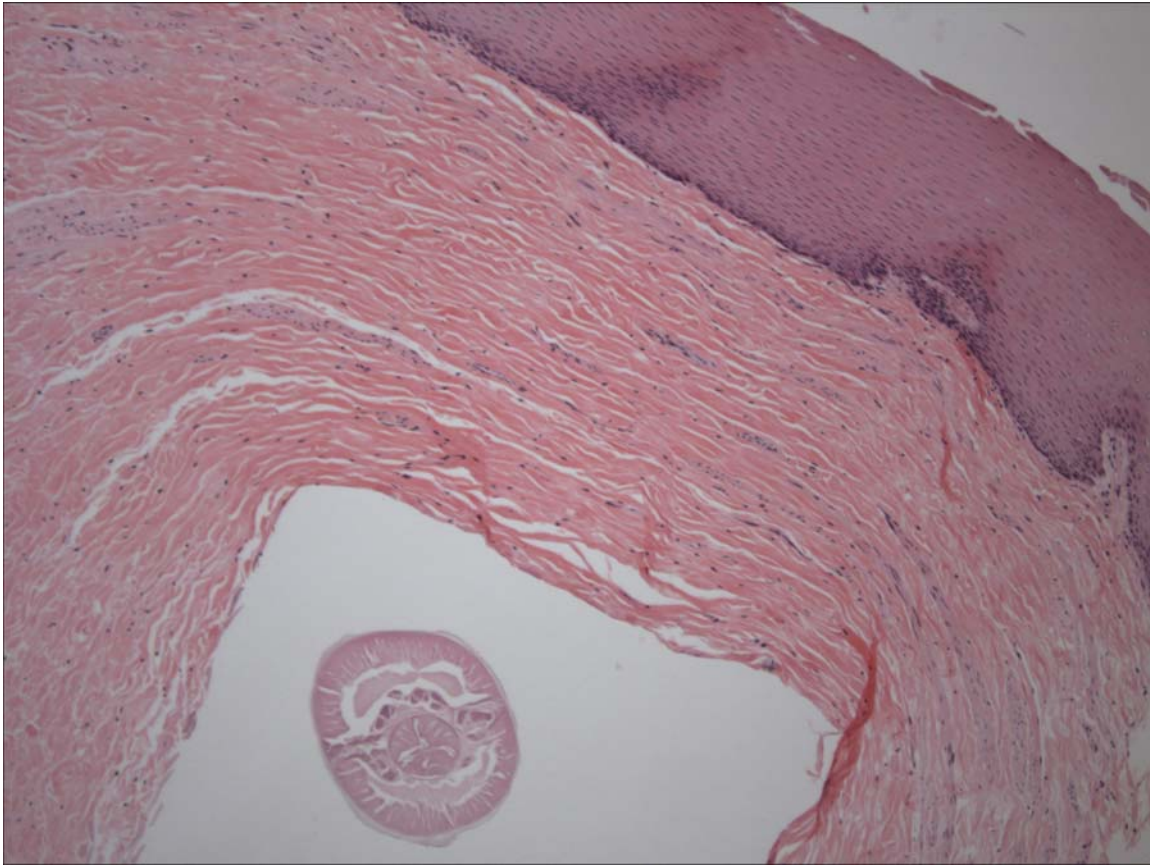


Figure 6. Stomach. Within the submucosa, there is a nematode (cross-section).

PENDING			
TEST/HISTO	PURPOSE	SITE	RESULT
Oil Red O	Fat (lipid) stain	Brain	NEG

DATE: 25 Feb 05 25 April 05 16 June 2005	REPORTING PATHOLOGIST: David S. Rotstein, DVM, MPVM, DACVP
---	---

**CETACEAN NECROPSY REPORT:
Pilot Whale Stranding, NC-15/16 Jan 2005**

Field ID: RT47
Accession Number: 05-7C
Date: 15 Jan 2005
Species: Globicephala macrorhynchus
Location: Bodie Island, NC (lat-35.83009, long-75.55695)
Sex: M (subadult)
TL: 177.0 cm

GROSS REPORT

REPORTING INSTITUTION: NOAA Beaufort

Adapted from hard copy of necropsy field notes.

External Exam: Minor notching caudal to dorsal fin ~ 1 X 1 cm. Rake marks right dorsal just caudal to dorsal fin. Small notch (dorsal?) cranial to caudal peduncle. Booby tooth, lower 3rd, right. Sand in blowhole and connection to nasopharynx. Genital swab obtained.

Internal Exam. Phyllobothrium cysts in blubber. Within pericardial sac, there is 2.0 ml of straw-colored fluid.

Musculoskeletal: Yellow viscous fluid is present within the right and left scapulohumeral joint and occipital joint.

Respiratory and Circulatory: The left lung is severely congested; bulla (middle?) 3 cm diam, more severe caudal lung field. Right lung is severely congested, fluid in airways, yellow foam. More severe in caudal lung field. There is foam inside the trachea, bronchi, and terminal airways.

Lymphatic: Right bronchial lymph node is congested and mottled tan and purple.

Digestive System: There are nematodes within the esophagus. No food in intestines. Stomach bagged for gastric contents. Green bile is present within the hepatopancreatic duct. Parasites from esophagus are saved for potential id.

Urinary: The bladder is full and urine is obtained.

Reproductive: There is sand in prepuce and genital slit. No calculi.

Head Necropsy:

Head Dissection completed 15 Feb 2005. Findings reported by C. Harms:

Additional head necropsies on five short-finned pilot whales. All part of mass stranding from 15 January 2005.. Four heads started thawing on 13 February and one small head on 14 February for necropsy today, performed at NMFS Beaufort Laboratory.

Left ventral mandibular fat is missing from beach necropsy. 3 x 5 cm abrasion rostral to left eye (probably from being dragged on beach). Distal tongue cut off and right eye removed during beach necropsy, left eye intact.

One nematode in esophagus and one in mouth (refluxed from stomach prior to decapitation).

There are indentations of the mandibular labia (2 on right, one on left) consistent with previous line injuries (HI form completed).

Teeth: right mandibular 2, 3 and 4, and right maxillary 2 and 3 were removed previously.

Small amount of sand in blowhole.

Subcutis: no bruising noted.

Musculoskeletal and connective tissue: Left occipital condyle is pink, right is white. There is emphysema under the periosteum of the mandible. There is edema and emphysema in the left temporalis muscle. There are two small focal areas of hemorrhage in tissue surrounding the left mandible dorsally associated with small vessels exiting the mandible. The left hyomastoid joint is clean, while the right has a small amount of thin brown fluid in adjacent vessels. There is mild hemorrhage at the insertion of cervical muscle on the left hyoid, and left of nuchal crest, possibly exertional. Acoustic fat in mandibular fossa is congested for about 1 cm at the caudal extremity, associated with vascular plexus.

Ears: Entire external auditory meatus present bilaterally. Cartilage at base of EAM where it enters skull is sigmoid-shaped and surrounded by a muscle bundle. Left external auditory meatus, nsf. Right external auditory meatus has a slight pink discoloration surrounding the base at the entry to the skull. Soft tissue light pink all around ears, There is no evidence of hemorrhage near periotic bones or adjacent acoustic fat. There is autolysis and mild congestion in soft tissues dorsal to left periotic bone. There are nematodes dorsal to left periotic bone, and fluid and trematodes dorsal to right ear.

Brain: mild to moderate congestion over occipital lobes bilaterally. Lining of ventricles is autolyzed. NSF on cut surfaces. Brain weight 2582 g

Left pterygoid sinus contains ice crystals (indicative of free fluid prior to freezing), a moderate load of nematodes and a light load of trematodes (4 g of parasites). Mild soft tissue hemorrhage is present medially but is not hemorrhagic. The right pterygoid sinus contains a heavy load of long thin nematodes and two trematodes (6 g of parasites), and a slight soft tissue swelling dorsally.

Major gross findings: parasitic sinusitis, possible exertional hemorrhage at insertion of cervical muscles. Autolysis and emphysema indicate degraded quality of head.

Collected Samples:

In formalin: both petriotic bones, and two sections each from cerebellum, cerebrum and brain stem. In ethanol: sinus nematodes.

ANCILLARY FINDINGS

Test	Result
Specific Gravity	1.033
Urobiliongen	0.2
Protein	trace
pH	6.0
Blood	trace
Ketones	NEG
Bilirubin	NEG
Glucose	Neg
Collection	N/I

TISSUES/SAMPLES RECEIVED

REPORTING INSTITUTION: UNIVERSITY OF TENNESSEE

Received is one bag of formalin labeled as "RT47 10% Formalin". There are four labeled cassettes and 21 free tissues. Cassettes are labeled as "Prescapular Lymph Node", "Bronchial Lymph Node", "Lung Lymph Node", and "Mesenteric Lymph Node" and representative sections are placed in Cassettes 3-6, respectively. Representative sections of remaining tissues are placed in Cassettes 1-12. Received on 2nd March 2005 is one bag containing ears, pterygoid sinus, and sections of brain. Representative sections of brain are placed in Cassettes 15-20 and pterygoid sinus, Cassettes 21-23.

MICROSCOPIC FINDINGS

REPORTING INSTITUTION: UNIVERSITY OF TENNESSEE

Testis (slide 1): Diffusely, there is a single layer of germ cells lining small seminiferous tubules without evident spermatogenesis. There is an increased stroma separating tubules.

Penis (slide 2): Nearly diffusely, there are small to occasionally moderate infiltrates of lymphocytes and plasma cells at the stromal/epithelial interface.

Prescapular Lymph Node (slide 3): Secondary lymphoid follicles are present. There is a mild increase in macrophages within medullary sinuses.

Aorta (slide 3): No significant histologic findings (NSF).

Kidney (slides 3 and 12): There is moderate interstitial congestion. Multifocally, superficial cortical tubules are lined by a basement membrane with lining cells partially or completely sloughed (suspect artifact).

Bronchial Lymph Node (slide 4): Secondary lymphoid follicles are present. There is a mild increase in macrophages within medullary sinuses.

Tonsil/Laryngeal Region (slide 4): A mildly hyperplastic layer of epithelium overlies a dome-shaped proliferation of lymphoid follicles (normal finding).

Lung Lymph Node (slide 5): NSF.

Spleen (slide 5): Periarterolar lymphoid sheaths are prominent.

Atrium (slide 5): NSF.

Mesenteric Lymph Node (slide 6): Lymphocytes are reduced in number and follicles are poorly formed. There are increased hemosiderophages.

Spinal Cord (slide 6): There is diffuse congestion.

Diaphragm (slide 7): NSF.

Thyroid Gland (slide 7): Nearly 60% of follicular lumina are filled with colloid. Remaining follicles are collapsed and lined by a single layer of cuboidal epithelial cells with clear cytoplasm.

Tongue (slide 7): NSF.

Liver (slide 8): There is diffuse, moderate congestion. Around random portal tracts, there is a mild increase in lymphocytes, plasma cells, and fewer eosinophils. There is diffuse, mild biliary hyperplasia.

Spinal Cord (slide 8): There is occasional, random hemorrhage. There is moderate vascular congestion.

Intestine (slides 9-11): NSF.

Vas Deferens (slide 9): NSF.

Brainstem (slide 9): There is mild spongiosis of the gray matter and multifocal perivascular clearing (edema).

Bronchus (slide 10): There is a mild, diffuse, sprinkling of plasma cells within the submucosa.

Pancreas (slide 10): NSF.

Lung (slide 10): NSF.

Blubber (slide 11): NSF.

Lymph Node, NOS (slide 11): There is moderate lymphoid hyperplasia.

Adrenal Gland (slide 12): NSF.

Ventricle (slide 12): NSF.

Brain (slides 15-23): There is freeze artifact. There is occasional, random, mild perivascular cuffing by lymphocytes and plasma cells.

Pituitary Gland (slide 20): NSF.

Pterygoid Sinus (slides 21-23): Within the stroma, there are numerous plasma cells and fewer lymphocytes. Occasionally the infiltrates extend around glands. Glands are mildly ectatic.

MORPHOLOGIC DIAGNOSES

Nervous System:

1. Brain: Encephalitis, non-suppurative, random, minimal.
2. Spinal Cord/Brainstem: Spongiosis and perivascular edema.

Reproductive System:

1. Testis: Aspermatogenesis (age-related).
2. Penis, Balanitis, lymphoplasmacytic, diffuse, mild.

Respiratory System:

Pterygoid Sinus: Sinusitis, lymphoplasmacytic, diffuse, mild to moderate.

FINAL DIAGNOSES/INTERPRETATIVE SUMMARY

Hypoxic/Ischemic Changes-brainstem & spinal cord

There is no evident cause of this subadult's stranding. Lesions in the central nervous system are ischemic/hypoxic changes that would not be unexpected in a stranded animal. Inflammation in the brain is very mild and unlikely to result in significant clinical effect (e.g. nervous system derangements). The inflammation is not specific and could be due to viral, bacterial, or protozoal infection. Infectious agents and viral inclusions were not observed. Inflammation in the pterygoid sinus is chronic and not specific for an etiologic cause. However, parasitic infection would be a consideration such as Nasitrema or Stenurus.

DATE:

25 Feb 05/25 Apr 05

REPORTING PATHOLOGIST:

David S. Rotstein, DVM, MPVM, DACVP

**CETACEAN NECROPSY REPORT:
Pilot Whale Stranding, NC-15/16 Jan 2005**

Field ID: RT48
 Accession Number: 05-8C
 Date: 15 Jan 2005
 Species: Globicephala macrorhynchus
 Location: Bodie Island, NC (lat-35.82875, long-75.55585)
 Sex: F
 TL: 352.0 cm

GROSS REPORT

REPORTING INSTITUTION: NOAA Beaufort

Adapted from hard copy of necropsy field notes.

Pregnant-fetus collected whole. Full term-120 cm to fluke notch; took sample of uterus and umbilical cord

Teeth-24 (6 upper, 6 lower on both sides); 1 broken lower left

Found Parasites: Phyllobothrium in peduncle blubber; Monorygma in posterior abdominal cavity

Left Lung: Froth in lung; margins rounded; cream to light pink/beige in color; upon cross-section brick red in color; thickened pleura

Esophagus: worms, bile in the gut

Left Ovary: 6.5 X 1.5 X 1.2 cm-not active

Right Ovary: Corpora luteum has scars from previous ovulations-active 7.9 X 2.7 X 6.9 cm

Luteum: 5.6 X 4.9 X 3.2

Stomach Contents Data Sheet:

Site	Full	Empty	Contents
Esophagus	1065g	1050g	15g
Forestomach	2123g	2183g	~60
Main	1193g	1147g	46g
Pyloric	492	490	2g

Comment:

Pyloric: Brown pus-filled nodule on pyloric wall, 38 X 24 mm, granulated ulcer, 1 dime size healed ulcer; 40 to 50 nematodes

Esophagus: 10 to 15 nematodes

Main: 2 granulated ulcers, 38 X 28 mm and 37 X 29 mm; 10 to 15 nematodes; piece of ulcer saved in 10% formalin for histo

Fore: Empty, 5+ nematodes

ANCILLARY FINDINGS

N/A

TISSUES/SAMPLES RECEIVED

REPORTING INSTITUTION: UNIVERSITY OF TENNESSEE

Received is one bag of formalin labeled as "RT48 10% Formalin". There are six labeled cassettes and 16 free tissues. Cassettes are labeled as "Prescapular Lymph Node", "Bronchial Lymph Node", "Lung Lymph Node", "Lung Lymph Node", "Colonic Lymph Node", and "Gastric Lymph Node" and representative sections are placed in Cassettes 1-5 and 7, respectively. Representative sections of remaining tissues are placed in Cassettes 1-8. An additional sample labeled as "Stomach Ulcer" is received 2 March 2005. Representative sections are placed in Cassette 9 and 10. On 29th and 30th November, 2005, the head was examined (please see full report in the "ADDENDUM").

MICROSCOPIC FINDINGS

REPORTING INSTITUTION: UNIVERSITY OF TENNESSEE

Prescapular Lymph Node (slide 1): Diffusely, follicular centers have increased macrophages. Lymphocytes are decreased in the mantle zone. There are increased macrophages and plasma cells within the medullary spaces.

Spleen (slides 1 and 6): Periarteriolar lymphoid sheaths are mildly hyperplastic.

Urinary Bladder (slide 1): No significant histologic findings (NSF).

Bronchial Lymph Node (slide 2): Sections consists of lung. There is diffuse, mild congestion and within alveolar lumina, there are small numbers of foamy macrophages (pulmonary edema).

Liver (slide 2): There is diffuse, mild congestion. Nearly 80% of hepatocytes contain variable amounts of intracytoplasmic, golden-brown pigment (ceroid-lipofuscin vs. hemosiderin).

Aorta (slide 2): NSF.

Kidney (slide 2): NSF.

Lung Lymph Node (slide 3): There is diffuse lymphoid depletion with scattered apoptotic lymphocytes and macrophages containing intracytoplasmic nuclear debris (tingible bodies). There is edema of the medullary sinus and increased foamy macrophages within the sinus.

Skin (slide 3): NSF.

Atrium (slide 3): NSF.

Skeletal Muscle (slide 4): NSF.

Spinal Cord (Cervical) (slide 4): There is mild, multifocal artifactual (tearing) and true swelling of myelin sheaths.

Lung Lymph Node 2 (slide 4): Lymphocytes are mildly depleted. There is a moderate increase in eosinophils within the edematous medullary spaces. There are small, irregular aggregates of degranulated eosinophils and fewer macrophages. There are scattered hemosiderophages.

Colonic Lymph Node (slide 5): There is a single, discrete, but unencapsulated aggregate of epithelioid macrophages surrounding a core of eosinophilic debris (Splendore-Hoeppli material) and fewer eosinophils (Figure 1).

Intestine (slide 5): NSF.

Mammary Gland (slide 5): Scattered ducts contain eosinophilic, proteinaceous fluid.

Thyroid Gland (slide 5): Approximately 40% of follicular lumina are expanded by eosinophilic, homogenous colloid. Remaining follicles are collapsed.

Heart (slide 6): NSF.

Gastric Lymph Node (slide 7): There is moderate congestion.

Uterine Horn (slide 7): The endometrium is lined by a single layer of low cuboidal epithelium. There are scattered lymphocytes within the submucosa.

Adrenal Gland (slide 7): NSF.

Lung (slide 8): There is regional interstitial fibrosis.

Stomach, Main (slides 9 and 10): Focally, there is a dome-shaped proliferation of the submucosa that is expanded by numerous individual to coalescing granulomata. Granulomas have a central core of eosinophilic substance (Splendore-Hoeppli material) or remnants of nematodes with only the cuticle and musculature remaining (Figure 2). Surrounding the central core are numerous epithelioid macrophages, occasional multinucleated giant cells, and aggregates of lymphocytes and plasma cells.

MORPHOLOGIC DIAGNOSES

Lymphoreticular/Hematopoietic System:

Colonic Lymph Node: Lymphadenitis, granulomatous and eosinophilic, focal with intralesional Splendore-Hoeppli material.

Respiratory System:

Lung:

1. Pulmonary edema, multifocal, mild.
2. Interstitial fibrosis, focal.

Digestive System:

Stomach, Main: Gastritis, granulomatous, coalescing, severe with intralesional, degenerating nematodes.

FINAL DIAGNOSES/INTERPRETATIVE SUMMARY

Granulomatous lymphadenitis

Histologic findings in this case do not indicate a cause of stranding. There is a single granuloma in the colonic lymph node which likely represents a site of parasite migration. Pulmonary edema is likely a perimortem occurrence and not a cause of respiratory dysfunction. Gastric changes, while very inflammatory, were unlikely to have resulted in the stranding of this cetacean.

ADDENDUM: 8 Dec 2005

History: Eight heads obtained from pilot whales stranded on Bodie Island, NC were examined November 29 and 30th, 2005. Heads were collected from the beach, the site of gross necropsy of the stranded population within (3) days, transported to University of North Carolina at Wilmington and frozen. Heads were thawed for the necropsy procedure.

Sample Disposition: A necropsy data collection was utilized for the procedure to denote samples collected, gross findings, examiners, and acquisition of photos if done. The following samples were collected:

Tissue	Disposition	Comment	Analysis—Individual and Institution
Brain	½ Formalin	Histopath back-up	Rotstein, UT
	Subsamples-Cassette: Cerebrum, Cerebellum, brainstem, pons, thalamus, corpus callosum, spinal cord, pituitary gland, and any observed lesions	Histopath immediate examination	Rotstein, UT
	Freeze	Biotoxin, Viral, or other ancillary diagnostics	Stored at UNCW
	Formalin	Fat Stains	NCSU
	Weight	Body Mass Studies	Pabst/McLellan, UNCW; indicated in gross report
Mandibular (Jaw Fats)	Subsamples: External, internal, and any lesions	Histopath	Rotstein, UT
	Formalin	Fat Stains	NCSU
	In toto	Lipid Analyses	Koopman, UNCW
Ears	Formalin	Histopath	Stored at UT
Parasites	Ethyl Alcohol	ID	Flowers, NCSU
Teeth	Frozen	Age Determination	Hohn, NOAA-NMFS, Beaufort
Melon/CTs	Frozen (?)	CT	Pabst, McLellan, Harper, UNCW
	Formalin	Histopath	Rotstein, UT
Mouth Scars; Other Lesions	Formalin	Histopath	Rotstein, UT
Occipital Condyle (RT50)	Swab Tissue	Culture(swab) Brucellosis*	Rotstein, UT

*At discretion of Larry Dunn at Mystic Aquarium.

General: On 30 Nov 2005, a whole pilot whale head is examined labeled as RT48.

Nervous System:

The pituitary gland is diffusely red-brown. There are no observable lesions. Representative sections are placed in a labeled tissue cassette and the remaining pituitary gland is placed in retained in formalin. The surface of the brain is reddened diffusely. Vessels in the ventral cerebrum and cerebellum and engorged with blood (congestion). Representative sections of brain are collected in cassettes for histopath including fat stains. The brain is bisected with one half placed in formalin and the other half frozen at -70C.

Brain Weight	
Field ID	Weight (g)
RT107	2865
RT50	3569
RT68	2625

RT103	2415
RT106	2563
RT48	2826
RT59	2892
RT72	2317

Sensory System:

The right and left eye exhibit umbilication of the cornea. In the periotic soft tissue of the left and right ear, directly subjacent to the tympanic bone, there is a 2.0 X 1.2 X 0.2 cm (left) and 1.4 X 0.7 X 0.2 cm (right), focal, slightly raised, reddening of the soft tissue that extends less than 0.2 cm on cut surface and not into the underlying fat and soft tissue. In the caudal right inner mandibular fat, there is a 1.5 X 1.0 X 0.2 irregular, inverse pyramidal, reddening of the adipose. The remaining adipose is tawny superficially and red-tinged on cut surface. In addition, within the avascular inner fat, there are numerous tortuous vessels. On cut surface, one vessel exhibits extravasation of erythrocytes (perivascular hemorrhage). Representative sections are obtained. There is a mild infestation of metazoans within the pterygoid sinus. The right ear is retained.

Tongue and Oral Cavity: There are no observed lesions. Representative sections are obtained.

GROSS DIAGNOSES:

Nervous System:

Brain:Vascular congestion, ventral.

Sensory System:

- 1.Peritympanic fibrous connective tissue and adipose: Focal superficial hemorrhage.
- 2.Inner Mandibular Fat, Avascular Region: Vascular tortuosity and focal hemorrhage.

Comment-Gross Necropsy: Superficial vessels in the cerebrum and cerebellum are congested. This is likely post-mortem hypostatic congestion. There is superficial, focal hemorrhage in the periotic soft tissue. This is directly adjacent to a mildly, rounded and slightly jutting portion of tympanic bone. The superficial nature of this lesion and lack of overt hemorrhage into the periotic space, suggests that pressure upon localized vessels may result in hemorrhage as an antemortem event or that there is postmortem pressure resulting in vessel tearing and localized blood pooling. Finally, a region of inner mandibular fat has evident vascular supply. Vessels are tortuous (irregular) suggesting that there was vascular proliferation into this region. An underlying cause was not evident. There was hemorrhage associated with one vessel that was localized. Histopathology is pending.

MICROSCOPIC FINDINGS

Slide 9

Left Ear Fat: One section is examined and consists of dense fibrous connective tissue, vessels, and adipose. There are no significant histologic findings (NSF).

Slide 10

Right Ear Fat: One section is examined and consists of dense fibrous connective tissue, vessels, and adipose. There are no significant histologic findings (NSF).

Slide 11

Tongue: NSF.

Oral Mucosa: Within the submucosal glands, there are scattered lymphocytes and plasma cells. Eosinophilic, wispy proteinaceous fluid is present within acinar and ductular lumina. There are small aggregates of lymphocytes and plasma cells subjacent to the mucosal epithelium.

Slide 12

Right Inner Mandibular Fat: Vessels are congested. Vascular luminal contents are brightly eosinophilic (ruptured erythrocytes and serum). There are occasional foci of hemorrhage with erythrocytes tracking around the margins of intact adipocytes.

Slide 13

Left Inner Mandibular Fat: Vessels are congested. Vascular luminal contents are brightly eosinophilic (ruptured erythrocytes and serum). There are occasional foci of hemorrhage with erythrocytes tracking around the margins of intact adipocytes.

Slide 14

Left Outer Mandibular Fat: Vessels are congested. Vascular luminal contents are brightly eosinophilic (ruptured erythrocytes and serum). There are occasional foci of hemorrhage with erythrocytes tracking around the margins of intact adipocytes.

Slide 15

Mandibular Fat-Fat Stain-Pending.

Slides 16 & 17

Inner Mandibular Fat, "Avascular Region": Two sections are examined. In one section (slide 16), there is a tract of erythrocytes outside of a vessel (Figure 3). Vascular supply to this region is less than other regions of mandibular fat examined.

Slides 13, 18, 19, 21

Brain: Nine sections are examined and include spinal cord, brainstem, pons, cerebrum, cerebellum, and thalamus. In all sections, there is fragmentation of the neuropil (freeze artifact). There are occasional neurons with increased surrounding microglial cells ranging from 3 to 5 (satellitosis).

Slide 21

Pituitary Gland: NSF.

DIAGNOSIS

Inner Mandibular Fat: Perivascular hemorrhage, multifocal, mild with occasional tracking.

COMMENT

There is occasional hemorrhage around vessels that tracks around adipocytes. Adipocytes are intact. The cause of increased vascularity to the avascular region of inner mandibular fat was not evident. This could represent a response due to a prior insult. However, inflammatory cells were not observed. Grossly, there was a raised, reddened region subjacent to the tympanic bone. The reddened region was not evident histologically, and there was no evidence of hemorrhage in this region. Special stains for fat (Oil Red O) are negative within the brain and in the mandibular fat are present as coalescing globules.

FIGURES

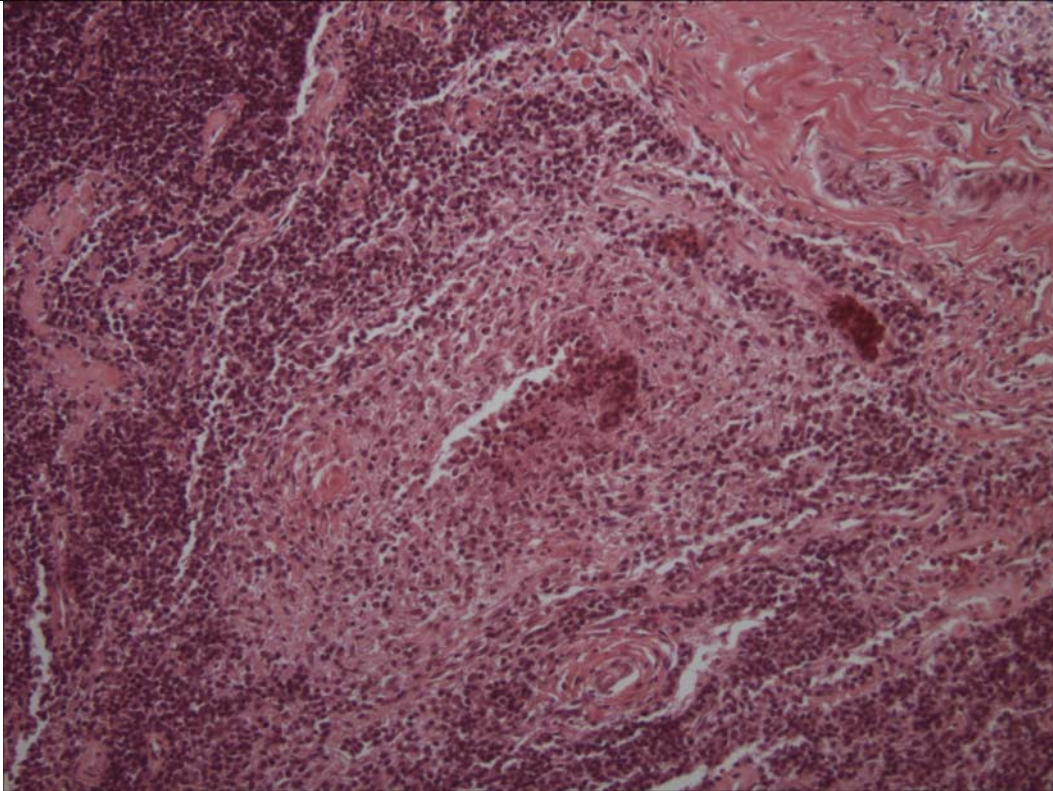


Figure 1. Colonic Lymph Node. There is a focal granuloma composed of epithelioid macrophages and a central of eosinophilic granular debris.

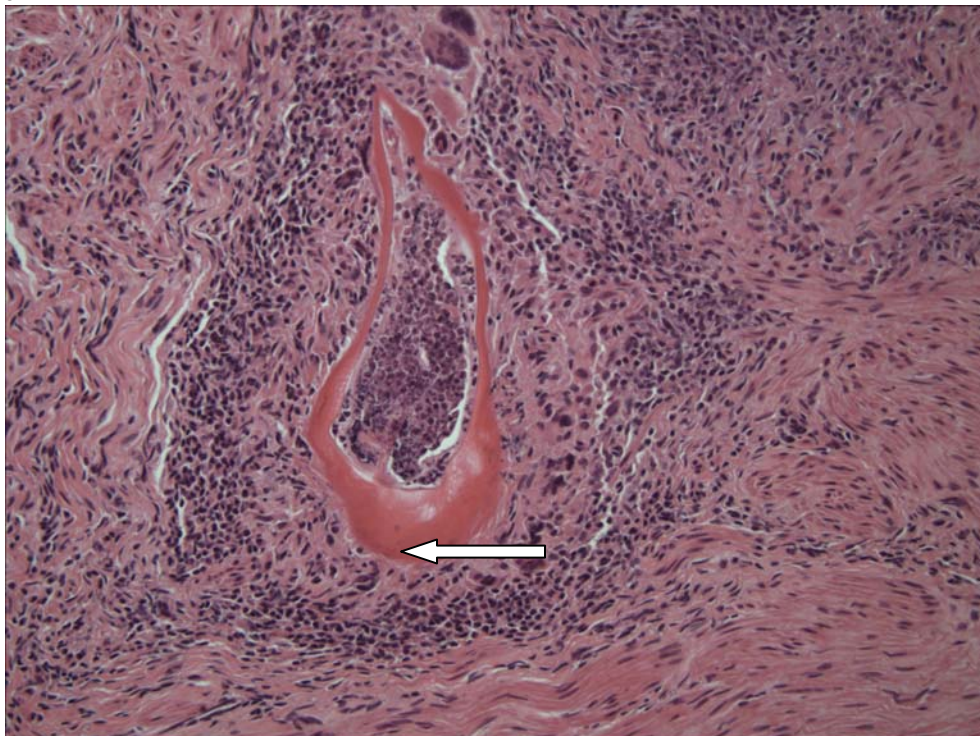


Figure 2. Stomach. Within occasional granulomas, there are remnants of nematodes with only the cuticle (solid arrow) and musculature (open arrow), remaining.

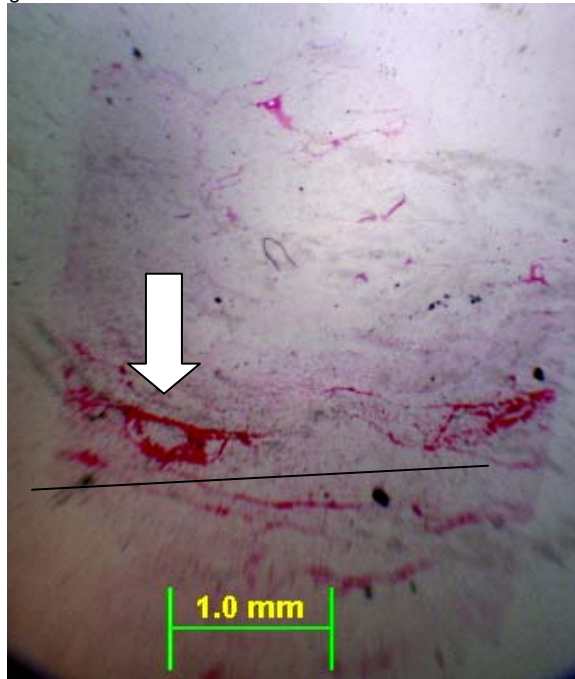


Figure 3. Inner Mandibular Fat, Avascular Region. There is perivascular hemorrhage (arrow) forming a tract (line) within this region of inner mandibular fat.

PENDING			
TEST/HISTO	PURPOSE	SITE	RESULT
Fat Stains	Presence of fat	Mandibular fat (control)	NEG
		Brain	NEG
DATE:		REPORTING PATHOLOGIST:	
3Mar 05/25Apr 05/5 Dec 05		David S. Rotstein, DVM, MPVM, DACVP	

CETACEAN NECROPSY REPORT:
Pilot Whale Stranding, NC-15/16 Jan 2005

Field ID: RT49
Accession Number: 05-9C
Date: 15 Jan 2005
Species: Globicephala macrorhynchus
Location: Bodie Island, NC (lat-35.8344, long-75.55828)
Sex: F
TL: 375.0 cm

GROSS REPORT
REPORTING INSTITUTION: NOAA Beaufort

Report adapted from necropsy notes.

General Examination. No visible lesions, robust, intestines protruding from left abdomen due to scavenger. There is slight wear on L caudal lower 3 teeth. All points of teeth intact. No froth observed in blowhole; swab obtained.

Integumentary System. Nuchal fat layer is 1.5 cm in depth.

Abdominal Cavity. Eight Monorygma observed.

Thoracic Cavity. Abundant serosanguineous fluid in pleural cavity. Sand in bronchi of left lung. Bronchi, aorta, and pericardium sampled.

Cardiovascular System. There is moderate amounts of ventricular adipose.

Musculoskeletal System. Muscle is dark red. Synovial fluid in the left scapulohumeral joint is red-tinged and clear. The skull and two (2) thoracic vertebrae are collected.

Respiratory System. The left lung is smooth and light red with sharp margins. There is bloody froth and sand in bronchi. The lung is heavy and wet.

Lymphoreticular/Hematopoietic Systems. There is a layer of fat around the edges of the pre-scapular and retropharyngeal lymph nodes.

Digestive System. Parasites (suspect Trematodes) and sands present in the lumen of the esophagus. All three (3) compartments of the stomach do not have palpable contents. The liver is mildly friable and has sharp margins. Bile is bright green.

Reproductive System. There is a corpus luteum in the right ovary. No milk is expressed from the mammary gland. There is a 4 to 5 mo fetus present. The fetus is female and measures 115.3 cm.

Head necropsies on 2 dwarf sperm whales and two short-finned pilot whales. All part of mass stranding from 15 (pilot whales) and 16 (Kogia) January 2005. The Kogia heads were frozen within half a day of stranding; the pilot whale heads were frozen the evening of the day after the stranding (Sunday). These animals were selected based on quick transfer of the heads to freezer at time of stranding, and relatively small size (pilot whales, possibly more prone to acoustic trauma). All 4 heads were imaged by CT at the NCSU College of Veterinary Medicine on 31 January (Kogia) and 1 February (pilot whales) while still frozen (stored in walk-in freezer overnight). They were then thawed for necropsy starting on 1 February. The necropsies were performed at NMFS Beaufort Laboratory 3 February. At the time of necropsies the Kogia heads were fully thawed and the pilot whale heads were still cold internally.

There are perilibial squid sucker marks on left side. NSF on goosebeak.

Musculoskeletal and connective tissue: NSF on cut surface of melon. Both left and right extramandibular fat exhibit no hemorrhage. Intramandibular fat has hemorrhage around the caudal vascular plexus, more pronounced on right than left. There is a vascular pattern in the cut surface of the intramandibular fat on cross section.

Ears: The right external auditory meatus is clean through blubber. There are a few nematodes dorsal to right periotic bone, no congestion. No parasites and no congestion dorsal to left periotic bone. There is no hemorrhage in the acoustic fat adjacent to the periotic bones.

Brain: brainstem core missing from beach necropsy, emphysema in left cerebrum.

Brain weight: N/A (core of brain stem and cerebellum taken during beach necropsy)

Left pterygoid sinus contains a moderate trematode and light nematode load. The epithelium is pale pink with no soft tissue swelling. The right pterygoid sinus contains a light nematode load and 3 trematodes. The epithelial lining is dark red, with minimal soft tissue swelling medially.

Major gross findings: parasitic sinusitis.

Collected Samples:

In formalin: both periotic bones, cerebellum.

Summation: autolysis is more extensive in this set of heads than in previous frozen-thawed heads. No glaring cause of death evident in gross necropsies of heads. Most consistent finding is parasitic sinusitis.

ANCILLARY FINDINGS

N/A

TISSUES/SAMPLES RECEIVED

REPORTING INSTITUTION: UNIVERSITY OF TENNESSEE

Received is one bag of formalin labeled as "RT49 10% Formalin". There are three labeled cassettes and 27 free tissues. Cassettes are labeled as "Prescapular Lymph Node", "LA Lymph Node", and "Retropharyngeal Lymph Node"; representative sections are placed in Cassettes 1, 2, and 5 respectively. Representative sections of remaining tissues are placed in Cassettes 1-10. Two cassettes could not be trimmed due to the presence of particulates-Cassette 1 (Pre-scapular lymph node) and 3. One bag is received 2 March 2005 and includes ears and sections of brain and pituitary gland. Representative sections of brain are placed in Cassettes 11-12 and pituitary gland, Cassette 13.

MICROSCOPIC FINDINGS

REPORTING INSTITUTION: UNIVERSITY OF TENNESSEE

Lung Lymph Node (slide 2): There is moderate lymphoid depletion and apoptosis. Eosinophils are increased and there is moderate edema within the medullary sinuses and gently separating collagen bundles surrounding vessels.

Lung (slide 2): Multifocally, larger alveolar lumina are filled with eosinophilic proteinaceous substance with interspersed granulocytes and sloughed epithelial cells (Figure 1).

Liver (slide 2): Sinusoids are mildly expanded by erythrocytes. Approximately 50% of hepatocytes and Kupffer cells contain intracytoplasmic, brown granular pigment (hemosiderin, presumptive).

Uterus (slide 4): There is diffuse, mild submucosal edema. Scattered glands are ectatic and contain eosinophilic proteinaceous material.

Intestine (slide 4): No significant histologic findings (NSL).

Diaphragm (slide 4): NSL.

Trachea (slide 4): NSL.

Intestine (slide 5): There is a multifocal, mild increase in plasma cells within the lamina propria.

Mammary Gland (slide 6): Acini have small lumina with nearly 50% containing small amounts of eosinophilic, homogenous material (protein). Ducts are mildly dilated and contain macrophages laden with golden brown intracytoplasmic pigment (ceroid-lipofuscin) (Figure 2).

Atrium (slide 6): There is focal nodular proliferation of collagen displacing cardiomyocytes (Figure 3).

Pancreas (slide 6): Lobules are separated by adipocytes. There is mild zymogen granule depletion.

Cerebellum (slide 6): There is focal hemorrhage (artifact).

Spinal Cord (slide 7): Vessels are moderately congested. There is multifocal swelling of myelin sheaths. Occasional neutrophils contain intracytoplasmic, brown, granular pigment (ceroid-lipofuscin). There is artifactual fragmentation of the spinal cord.

Blubber (slide 7): NSL.

Bronchus (slide 7): There is diffuse, mild to occasionally moderate expansion of the submucosa by plasma cells and fewer lymphocytes. There is peribronchial hemorrhage within the adipose.

Intestine (slide 8): There is autolysis of the mucosa.

Spleen (slide 8): Periarteriolar sheaths are mildly depleted.

Urinary Bladder (slide 8): There is a sprinkling of plasma cells in the submucosa. There is single intracytoplasmic, eosinophilic, globular structure within one urothelial cell (Figure 4).

Amnion (slide 8): NSL.

Kidney (slide 9): NSL.

Adrenal Gland (slide 9): NSL.

Esophagus (slide 9): There is focal ulceration of the mucosal epithelium with associated hemorrhage.

Heart (slide 10): There is extravasation of erythrocytes within the pericardial adipose.

Brain (slides 11-12): NSF.

Pituitary Gland (slide 13): NSF.

MORPHOLOGIC DIAGNOSES

Respiratory System:

- 1.Lung: Alveolitis, neutrophilic and exudative, multifocal, mild to moderate.
- 2.Bronchitis, lymphoplasmacytic, diffuse, mild.

Hematopoietic/Lymphoreticular System:

Lung Lymph Node: Lymphocytolysis (lymphoid depletion), diffuse, moderate.
Integumentary System:
Mammary Gland: Intraductular histiocytosis with intrahistiocytic ceroid-lipofuscin.
Cardiovascular System:
Heart: Atrial fibrosis, focal.
Urinary System:
Urinary Bladder: Cystitis, plasmacytic, minimal.

FINAL DIAGNOSES/INTERPRETATIVE SUMMARY

Alveolitis (2nd to decreased clearance)
Lymphoid depletion

A cause for this animal's stranding and death is not evident. The alveolitis is likely the result of decreased respiratory clearance and perhaps inhalation of foreign material (grossly described sand in airways). The eosinophilic material is likely a combination of mucous and fibrin. Bacteria, fungi or other infectious agents were not evident with routine Hematoxylin and Eosin stains. Lymphoid depletion is attributed to increased cortisol (stress response). The atrial fibrosis is very mild and unlikely to have result in significant changes in cardiac function. Other changes observed in the urinary bladder, mammary gland, and bronchus is considered incidental and not contributory to this cetacean's condition.

FIGURES

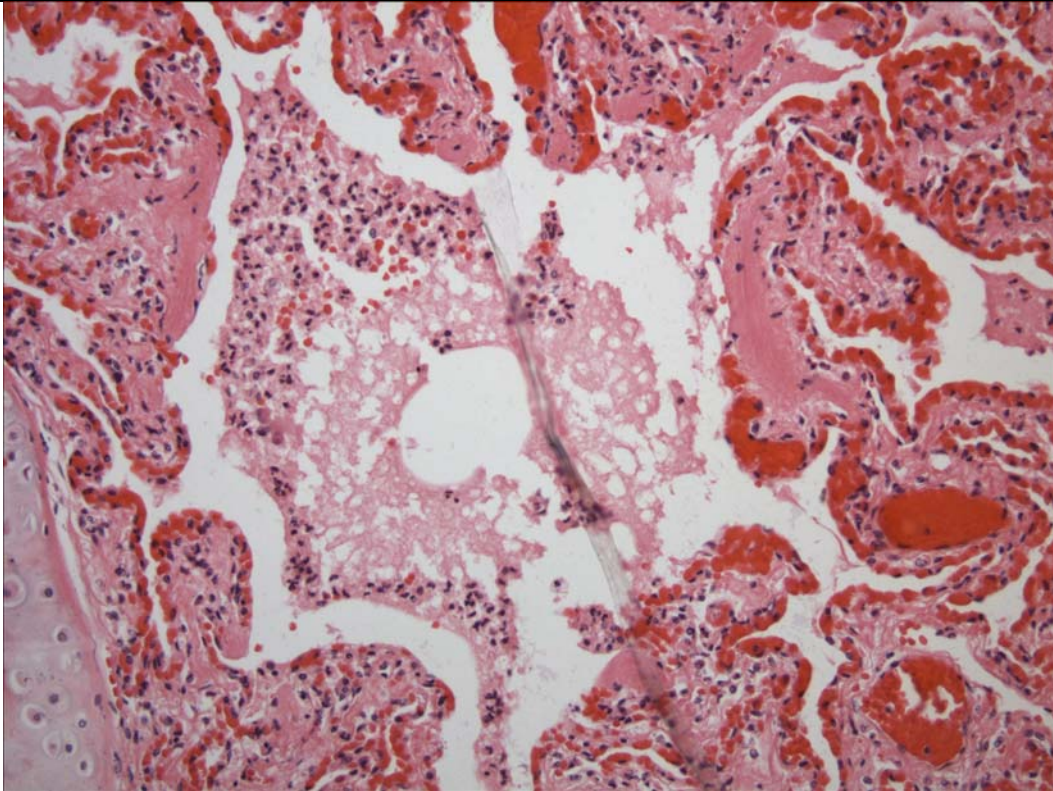


Figure 1. Lung The airway contain proteinaceous exudate and inflammatory cells.

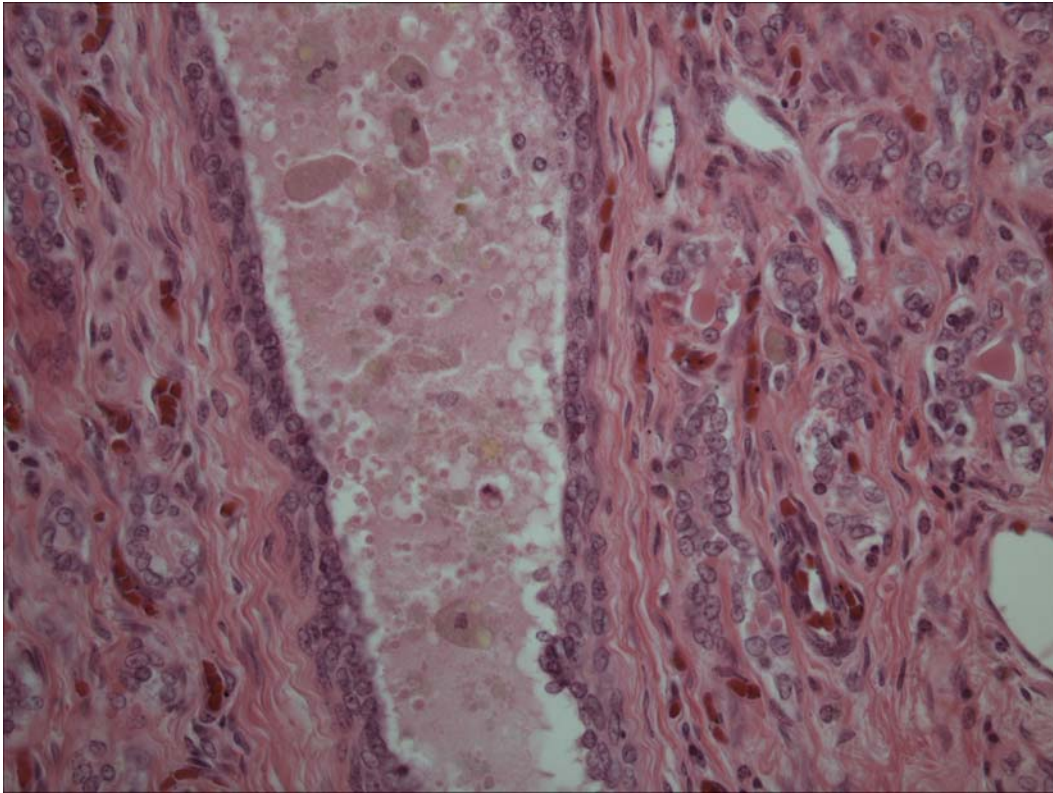


Figure 2. Mammary Gland. There are macrophages within the duct that contain intracytoplasmic brown granular pigment (ceroid-lipofuscin).

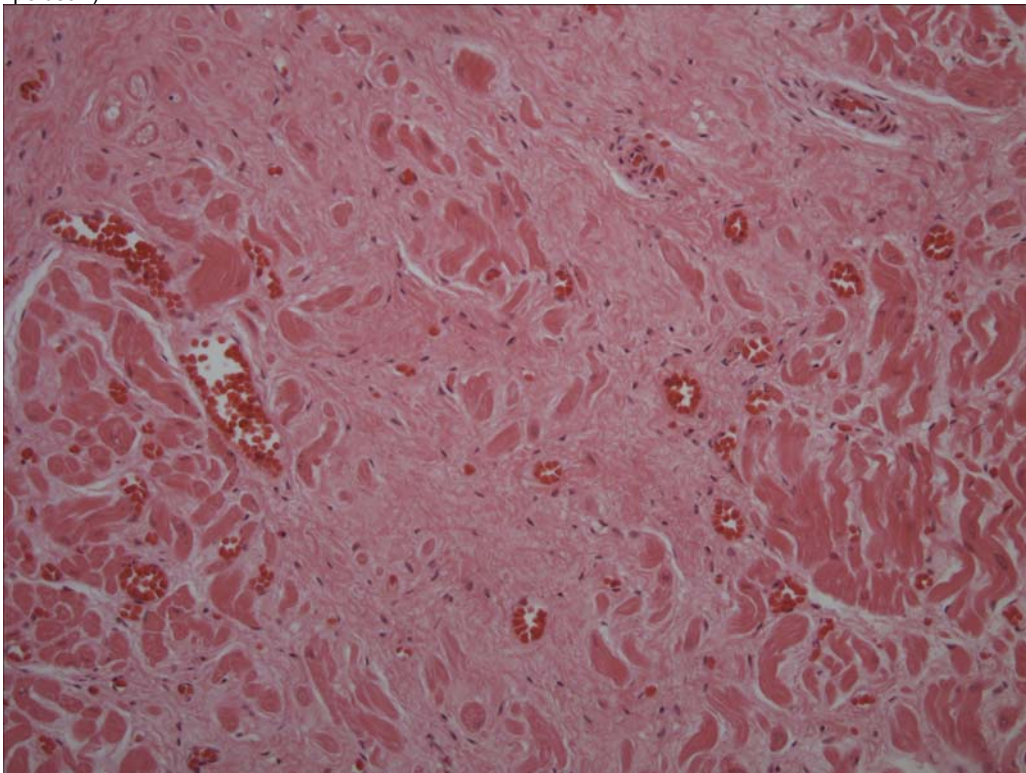


Figure 3. Atrium. There is focal fibrosis with cardiomyocytes forming small islands of individual to few cells.

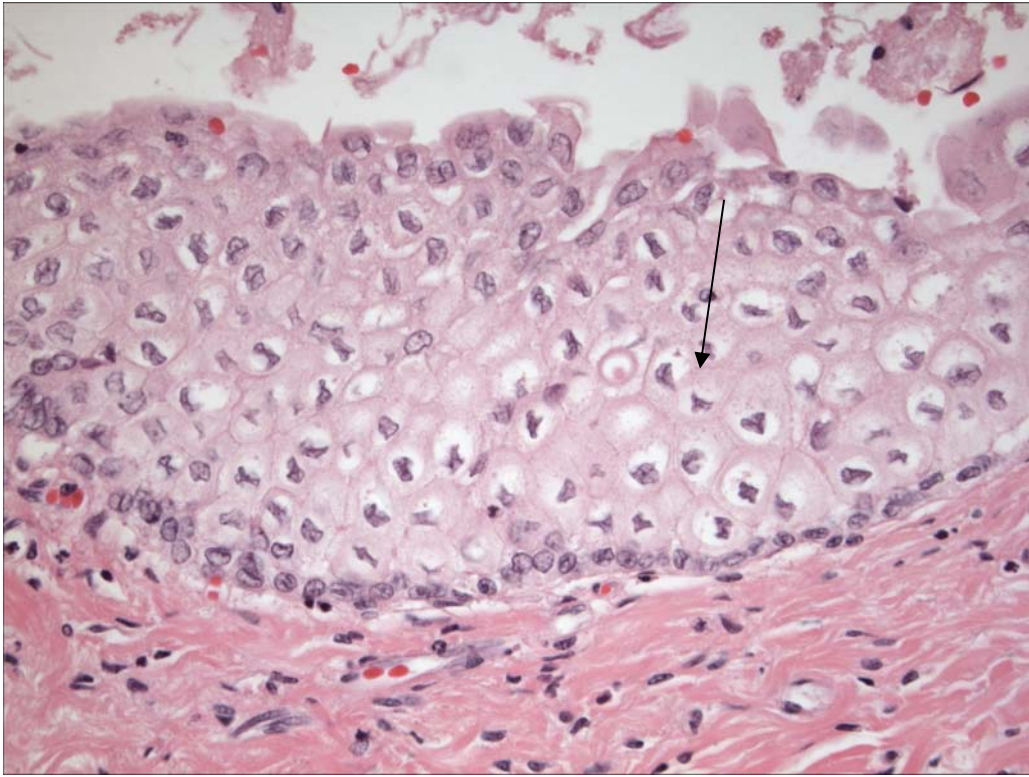


Figure 4. Urinary Bladder. There is a single cell with an eosinophilic intracytoplasmic inclusion (not viral).

DATE:

REPORTING PATHOLOGIST:

9 Mar 05/26 Apr 05

David S. Rotstein, DVM, MPVM, DACVP

CETACEAN NECROPSY REPORT:
Pilot Whale Stranding, NC-15/16 Jan 2005

Field ID: RT50
 Accession Number: 05-10C
 Date: 15 Jan 2005
 Species: Globicephala macrorhynchus
 Location: Bodie Island, NC (lat-35.83312, long-75.55778)
 Sex: F
 TL: 380.0 cm

GROSS REPORT
 REPORTING INSTITUTION: NOAA Beaufort

Report adapted from necropsy notes.

General Examination. Good to excellent body condition. The number of teeth are detailed below. There is extensive abdominal adipose.

Location	Number	Comment
Total Upper	16	N/C
Total Lower	14	N/C

Musculoskeletal System. Left scapulohumeral joint fluid is blood tinged and tenacious. The right half of the occipital joint exhibits extensive fibrosis (scar tissue formation) and hemorrhage with adhesions and irregularity of the bone (possible boney necrosis, ankylosing spondylosis). Approximately 33.0 mls of CSF was collected from the occipital condyle region.

Cardiovascular System. Measurements are as follows.

Location	Measurement	Comment
Right Ventricular Freewall	1.1 cm	
Left Ventricular Freewall	2.3 cm	
Inteentricular Septum	2.6 cm	

Endocrine System. The left adrenal gland is 6.5 X 4.5 X 0.5 (cm). On cut surface, there is hemorrhage. The thyroid gland is surrounded by adipose.

Digestive System. Parasites collected and whole stomach collected for evaluation of contents. The intestinal tract is 77 cm with 31 loops.

Abdominal Cavity. Monorygma are observed near the uterus.

Thoracic Cavity. Abundant serosanguineous fluid in pleural cavity. Sand in bronchi of left lung. Bronchi, aorta, and pericardium sampled.

Genitourinary System. The right kidney measures 45 X 18 X 7 (cm). The urinary bladder is empty. There was vaginal mucus. A fetus was present in the uterus. Mammary glands were devoid of milk.

ANCILLARY FINDINGS

8 Dec 2005. Aerobic Culture—Occipital Condyle:
 Result: >100 colonies Serratia liquefaciens, ~ 100 colonies Enterococcus, ~50 colonies gram + coccus, & ~100 colonies alpha hemolytic Streptococcus

TISSUES/SAMPLES RECEIVED
 REPORTING INSTITUTION: UNIVERSITY OF TENNESSEE

Received is one bag of formalin labeled as "RT50 10% Formalin". There are six labeled cassettes and 33 free tissues including an eye. Cassettes are labeled as "Pre-scapular Lymph Node", "LA (lung associated) Lymph Node", "Mesenteric Lymph Node", "Cervical Spinal Cord", "Thoracic Spinal Cord", and "Occipital Scar Tissue". The eye is placed in a megacassette and is being processed at North Carolina State University. Pre-scapular lymph node, lung associated lymph node, mesenteric lymph node, cervical spinal cord, thoracic spinal cord, and occipital scar tissue are placed in Cassettes 2-7, respectively. Representative sections of remaining tissues are placed in Cassettes 2-16.

MICROSCOPIC FINDINGS
 REPORTING INSTITUTION: UNIVERSITY OF TENNESSEE

Eye (slide1): No significant histologic findings (NSF).

Pre-scapular Lymph Node (slide 2): There is moderate edema and congestion of medullary spaces. There are increased macrophages within medullary spaces that have foamy eosinophilic cytoplasm or granular, intracytoplasmic, 1 to 2 micron, round, brown granules (hemosiderin).

Adrenal Gland (slide 2): There is multifocal congestion.

Pharynx (slide 3): No significant histologic findings (NSF).

Lung-Associated Lymph Node (slide 3): There is moderate lymphoid depletion. Medullary spaces are expanded by eosinophilic, homogenous, proteinaceous fluid (edema). There are increased foamy macrophages within medullary spaces.

Kidney (slides 3 and 15): There is diffuse, mild to moderate congestion. Scattered renal tubular epithelial cells contain intracytoplasmic, brown granular pigment (hemosiderin). In slide 15, there is occasional basophilic, globular mineral within collecting ducts (Figure 1).

Mesenteric Lymph Node (slide 4): The section is composed of mature adipose with a small, focal region of lymphocytes, plasma cells, and hemosiderophages.

Trachea (slide 4): NSF.

Intestine (slides 4, 5): There is autolysis of the mucosa. In slide 5, there are occasional intraluminal nematode ova and larvae (Figure 2). Ova are 20 microns in width with a 2 to 4 micron cuticle and a central amphophilic ball of cells. Larvae are 15 microns in width. There is no associated inflammation.

Cervical Spinal Cord (slide 5): There is diffuse congestion of vessels. There is multifocal swelling of myelin sheaths in the white matter. Neurons contain small to occasionally abundant perikaryonal brown pigment (ceroid-lipofuscin).

Liver (slides 5 and 6): There is moderate congestion. Multifocally, centrilobular hepatocytes are mildly attenuated in these regions of sinusoidal distention (Figure 3). In slide 6, there is moderate distention of venules subjacent to the capsule which are approximately 2 to 3 mm in diameter (Figure 4). The endothelium is disrupted and the space contains small numbers of erythrocytes and serum. There is mild, multifocal biliary hyperplasia.

Thoracic Spinal Cord (slide 6): There is diffuse congestion of vessels. There is multifocal swelling of myelin sheaths in the white matter. Neurons contain small to occasionally abundant perikaryonal brown pigment (ceroid-lipofuscin).

Heart (slide 6): No significant histologic findings.

Occipital Scar Tissue (slides 7 and 15): Two sections are examined and consist of mature fibrous connective tissue with scattered fibrocytes present within the wide swath of collagen. Interspersed in the stroma are vascular channels lined by plump endothelial cells packed with erythrocytes and surrounded by moderate numbers of lymphocytes and plasma cells (Figure 5). There is focal fibrin exudation with interspersed degenerate neutrophils.

Atrium (Suspect Thrombosis) (slide 8): There is an accumulation of serum with few interspersed cells (post-mortem clot).

Spleen (slide 8): There is moderate congestion. There is an increase in hemosiderophages with occasional erythrophagocytosis evident.

Thyroid Gland (slide 9): Nearly 65% of follicular lumina are expanded by homogenous, eosinophilic colloid. Remaining follicles are collapsed and lined by vacuolated epithelial cells.

Placenta (slide 10): There are multifocal polypoid structures on the amnion ("caruncles").

Umbilicus (slide 10): There are multifocal polypoid structures on the outside of the umbilicus ("caruncles").

Skeletal Muscle (slides 11 and 14): No significant histologic findings.

Atrium (slide 11): There are scattered lymphocytes and plasma cells within the epicardium (Figure 6). There is focal endocardial fibrosis.

Aorta (slide 12): NSF.

Ventricle (slide 12): NSF.

Mammary Gland (slide 13): Approximately 20% of acini contain eosinophilic, proteinaceous fluid. Remaining acini contain no cellular product and have diminished luminal diameters.

Lung (slides 13 and 15): In slide 15, there is moderate interstitial and perivascular expansion by lymphocytes, plasma cells, macrophages, and hemosiderophages. Multifocally, bronchiolar and alveolar lumina are filled with abundant granular eosinophilic, proteinaceous fluid and numerous foamy macrophages and fewer eosinophils. There is mild, multifocal anthracosis.

Intestine (slide 13): There is focal fibrosis of the lamina propria with replacement of glands. There are increased plasma cells and eosinophils in the fibrous stroma.

Diaphragm (slide 14): NSF.

Uterus (slide 14): Nearly 60% of glands are lined by a single to occasionally bilayer of high cuboidal epithelial cells. Glandular lumina are distended by eosinophilic, proteinaceous, inspissated fluid. There is mild endometrial edema. There is diffuse, moderate congestion.

Lymph Node, NOS (slide 14): There is moderate lymphoid depletion. Hemosiderophages are scattered throughout.

Blubber (slide 15): NSF.

Bronchi (slide 15): NSF.

Occipital Joint Bone (slide 16): PENDING.

MORPHOLOGIC DIAGNOSES

Hepatobiliary System:

Liver:

- a. Congestion, diffuse, moderate with occasional centrilobular hepatocellular atrophy (early telangiectasia).
- b. Supcapsular venular ectasia with endothelial disruption.
- c. Biliary hyperplasia, multifocal, mild.

Cardiovascular System:

Atrium: Epicarditis, lymphoplasmacytic, multifocal, mild.

Respiratory System:

Lung:

- a. Interstitial pneumonia and perivascularitis, lymphoplasmacytic and mildly eosinophilic, regionally extensive, moderate.
- b. Histiocytosis, alveolar and bronchiolar, multifocal, moderate with pulmonary edema.

Musculoskeletal System:

Occipital Joint: Fibrosis and lymphoplasmacytic inflammation.

Urinary System:

Kidney, Collecting Ducts: Intraluminal mineral, multifocal, minimal.

Digestive System:

Intestine: Intralumina nematode ova and larvae.

FINAL DIAGNOSES/INTERPRETATIVE SUMMARY

Hepatic congestion and venular ectasia
 Interstitial pneumonia
 Occipital joint fibrosis
 Endoparasitism (mild)

The exact cause of death and stranding in this animal is not evident. Lesions were observed in several systems. Of concern is the grossly reported ankylosing spondylosis (histologic samples of bone are pending) which is supported by associated fibrosis and inflammation. The inflammation is chronic indicating that this was a long term problem and not an acute occurrence. Joint function was likely affected and may have resulted in pain, but neurologic dysfunction may have not been significant. Demyelination of the cervical spinal cord (site obtained not indicated) was not observed; swelling of myelin sheaths which has been observed in other cetaceans including pilot whales in this mass stranding event are likely the result of hypoxia rather than a result of compression by the affected bone.

The liver was congested and there were central veins predominantly beneath the capsule that were dilated with evident disruption of the lining endothelium. These ectatic venules were less than 3 mm and there was no evidence of associated hepatocellular necrosis, but there was exudation of proteinaceous fluid in one dilated vessel. The cause of ectasia may include increased pressure (portal hypertension) or early telangiectasia. Telangiectasia may be observed during pregnancy in women, and thus, this may represent such a change. Special stains for fat (Oil Red O), fibrin (PTAH), and elastin (VVG) were negative or did not indicate disruption of vascular walls or increased elastin deposition (VVG); in addition, immunohistochemical stains for vascular endothelium (Factor VIII) highlighted endothelial walls in regions of sinusoidal distention.

Other lesions including endoparasitism, mineral in renal collecting ducts, and atrial epicarditis are considered incidental. Lung lesions indicate two different lesions. The interstitial pneumonia is likely parasite related, whereas the fluid in alveolar lumina is likely a peri-mortem occurrence in this stranded cetacean.

ADDENDUM: 8 Dec 2005

History: Eight heads obtained from pilot whales stranded on Bodie Island, NC were examined November 29 and 30th, 2005. Heads were collected from the beach, the site of gross necropsy of the stranded population within (3) days, transported to University of North Carolina at Wilmington and frozen. Heads were thawed for the necropsy procedure.

Sample Disposition: A necropsy data collection was utilized for the procedure to denote samples collected, gross findings, examiners, and acquisition of photos if done. The following samples were collected:

Tissue	Disposition	Comment	Analysis—Individual and Institution
Brain	½ Formalin	Histopath back-up	Rotstein, UT
	Subsamples-Cassette: Cerebrum, Cerebellum, brainstem, pons, thalamus, corpus callosum, spinal cord, pituitary gland, and any observed lesions	Histopath immediate examination	Rotstein, UT
	Freeze	Biotoxin, Viral, or other ancillary diagnostics	Stored at UNCW
	Formalin	Fat Stains	NCSU
	Weight	Body Mass Studies	Pabst/McLellan, UNCW; indicated in gross report
Mandibular (Jaw Fats)	Subsamples: External, internal, and any lesions	Histopath	Rotstein, UT
	Formalin	Fat Stains	NCSU
	In toto	Lipid Analyses	Koopman, UNCW

Ears	Formalin	Histopath	Stored at UT
Parasites	Ethyl Alcohol	ID	Flowers, NCSU
Teeth	Frozen	Age Determination	Hohn, NOAA-NMFS, Beaufort
Melon/CTs	Frozen (?)	CT	Pabst, McLellan, Harper, UNCW
	Formalin	Histopath	Rotstein, UT
Mouth Scars; Other Lesions	Formalin	Histopath	Rotstein, UT
Occipital Condyle (RT50)	Swab Tissue	Culture(swab) Brucellosis*	Rotstein, UT

*At discretion of Larry Dunn at Mystic Aquarium.

General: On 29 Nov 2005, a whole pilot whale head is examined. Eyes have been previously removed.

Nervous System:

The pituitary gland is diffusely red-brown. There are no observable lesions. Representative sections are placed in a labeled tissue cassette and the remaining pituitary gland is placed in retained in formalin. The surface of the brain is reddened diffusely. Vessels in the ventral cerebrum and cerebellum and engorged with blood (congestion). Representative sections of brain are collected in cassettes for histopath including fat stains. The brain is bisected with one half placed in formalin and the other half frozen at -70C.

Brain Weight

Field ID	Weight (g)
RT107	2865
RT50	3569
RT68	2625
RT103	2415
RT106	2563
RT48	2826
RT59	2892
RT72	2317

Digestive System/Oral Cavity:

The tongue and oral cavity have no observable lesions. Representative sections are placed in cassettes. On the upper jaw, there are several squid sucker lesions.

Sensory System:

Mandibular fats are light yellow. Representative sections of intra- and extramandibular fats are collected. There is cloudy, dark brown fluid in the left periotic space with associated metazoans. Melon fat is homogenous and representative sections are collected.

Musculoskeletal System: The periosteal surface of the left and right occipital condyle are markedly eroded with the right more severely affected than the left. There is abundant, dense fibrous connective tissue adhered to both condyles. On cut surface, there is a 5 X 4 X 3 cm region of bony loss and cortical thinning with the medullary space expanded by a tan, rubbery tissue with small portions of bone present within the tissue. Representative sections are collected in a cassettes and larger sections are placed in formalin. A swab and fragment of tissue are collected for potential culture including Brucella sp.

GROSS DIAGNOSES:

Musculoskeletal System:

Occipital Condyle, Right: Osteomyelitis, presumptive with associated condylar erosion and fibrosis and bony loss.

Nervous System:

Brain: Vascular congestion, ventral.

Sensory System;

Ears: Periotic trematodiasis, moderate.

COMMENT-GROSS NECROPSY: At the initial whole body necropsy, occipital condyle changes and increased fibrous connective tissue at this site were observed leading to a consideration of early spondylosis. However, the space occupying tissue and bony loss in the right occipital condyle indicate a more insidious process. While inflammation and bony loss are provisional diagnoses, neoplasia, specifically osteosarcoma or chondrosarcoma must be strongly considerations. Histologic examination of this bone will be paramount in this case to rule out a more insidious process such as neoplasia. Superficial vessels in the cerebrum and cerebellum are congested. This is likely post-mortem hypostatic congestion.

MICROSCOPIC FINDINGS

Slides 17 & 17A

Tongue: No significant histologic findings.

Oral Mucosa: Three sections are examined. There is marked hyperplasia of submucosal lymphoid aggregates. Plasma cells are increased and rarely there are plasma cells with abundant amphophilic, round cytoplasmic globules (Russell bodies) (Figure 7). There is a mild to moderate periglandular infiltrate of lymphocytes and plasma cells. Occasionally, submucosal glands are diminished in luminal diameter and surrounded by variable amounts of fibrous connective tissue.

Slides 18 & 19

Pterygoid Sinus: Three sections are examined. Within the submucosa, surrounding connective tissue, and with glands, there are moderate numbers of lymphocytes, plasma cells, fewer macrophages, and eosinophils. Occasionally within these inflammatory infiltrates or within the fibrous stroma, there are cross-sections of metazoans and rare ova. The metazoans are 80 to 100 microns in

diameter with polymyarian/coelomyarina musculature, complete digestive tract lined by a single to occasionally clumped layer or irregular cuboidal cells (nematode) (Figure 8). Ova are 50 microns in diameter, pyramidal with a golden 2 to 5 micron shell and an internal miracidium (trematode) (Figure 9).

Acoustic Periotic Fat and Connective Tissue: There are scattered lymphocytes and plasma cells within the fibrous stroma.

Slides 21 and 22

Periotic Exudate, Left: Two sections are examined and consist of fibrous connective tissue and adipose. There are numerous nematodes present as described in Slides 18 and 19. One nematode has internal larva (Figure 10). Multifocally, adipocytes are necrotic characterized by disruption of adipocytes with accumulation of eosinophilic granular material and scattered macrophages. Lymphocytes and plasma cells are present within the fibrous stroma.

Slides 22 & 23

Brain: Four sections are examined. There is freeze artifact characterized by jagged, clear clefts separating the neuropil.

Pituitary Gland: One section is examined. No significant histologic findings.

Slide 24

Occipital Condyle: Ten sections and fragments are examined and consist of fibrous connective tissue and necrotic bone. Necrotic bone is eosinophilic with an absence of nuclei. There are scattered lymphocytes. There are numerous mixed bacteria without an associated inflammatory reaction.

DIAGNOSES

Musculoskeletal System:

Occipital Condyle: Osteonecrosis and fibrosis.

Sensory:

Pterygoid Sinus and Peribullar Soft Tissue: Sinusitis and peribullitis, lymphoplasmacytic, multifocal to coalescing, moderate with intralesional nematodes and trematode ova.

Digestive System:

Oral Mucosa: Stomatitis, lymphoplasmacytic, multifocal with periadenitis and adenitis, lymphoid hyperplasia and plasmacytosis.

COMMENT: While the bulk of the occipital condyle will be decalcified to provide a more global view of the changes, sections and fragments obtain indicate necrosis of bone and increased fibrous connective tissue deposition. This may indicate a site of fracture at this site with necrotic bone within the center (sequestrum). Neoplasia and infectious/inflammatory conditions cannot be completely ruled out based upon the fragments as the necrotic region may not represent the entire changes to the bone. Aerobic culture of the tissue indicates the growth of post-mortem bacteria which is substantiated by histologic findings of bacteria without an associated inflammatory reaction. Metazoans were observed in the pterygoid sinus and peribullar spaces. Nematodes are most common, but a trematode (fluke) egg was observed. Inflammation present was chronic.

FIGURES

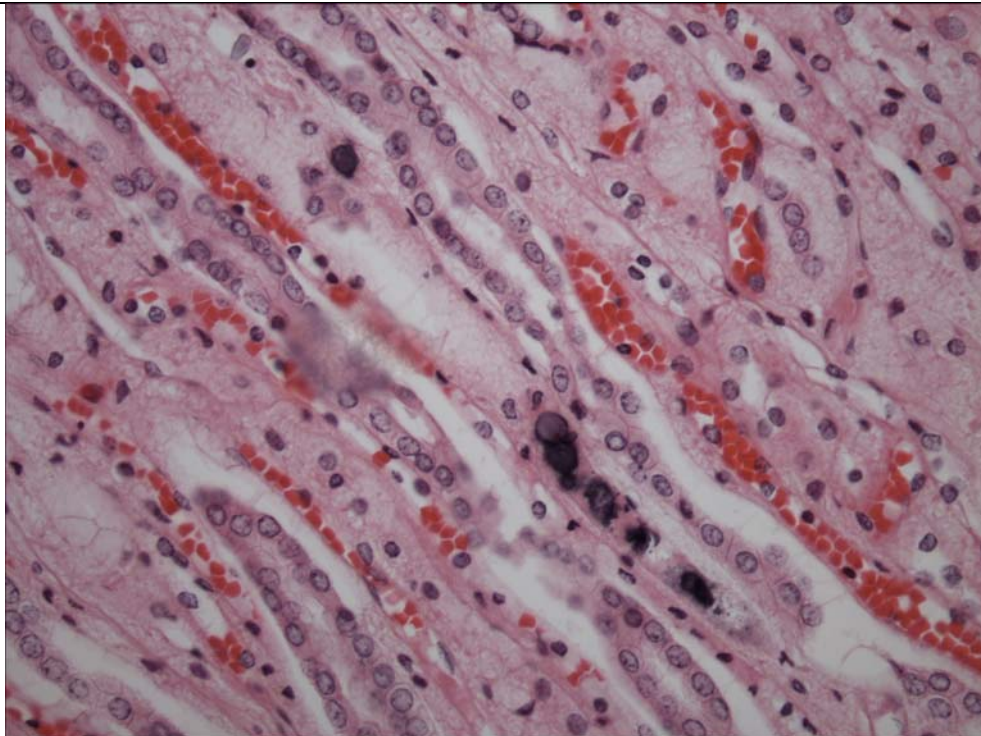


Figure 1. Kidney. There is mineral within collecting duct lumina.

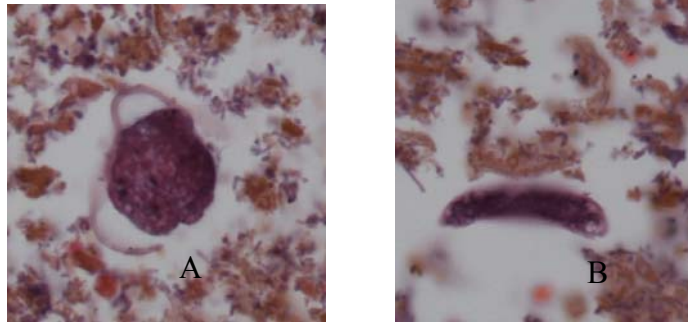


Figure 2. Intestine. Nematode ova (a) and larva (b) are present within the lumen.

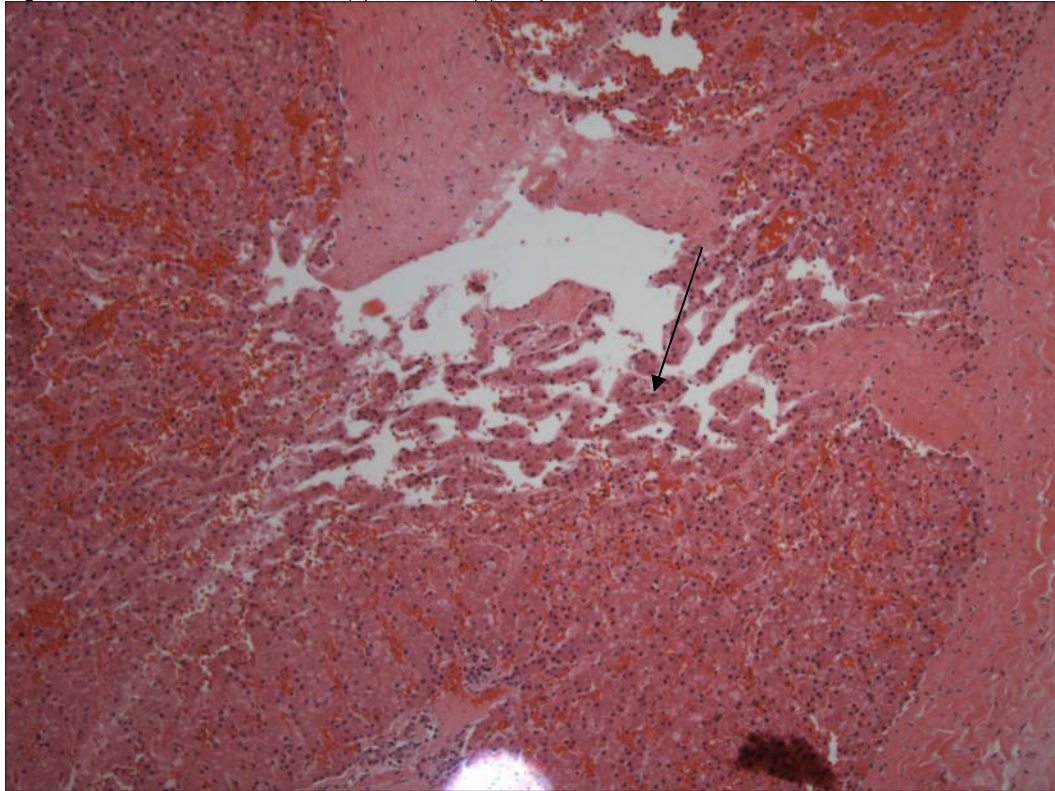


Figure 3. Liver. There is expansion of sinusoids (arrow). Hepatocytes are mildly atrophied in these regions. There is moderate congestion in the remaining hepatic parenchyma.

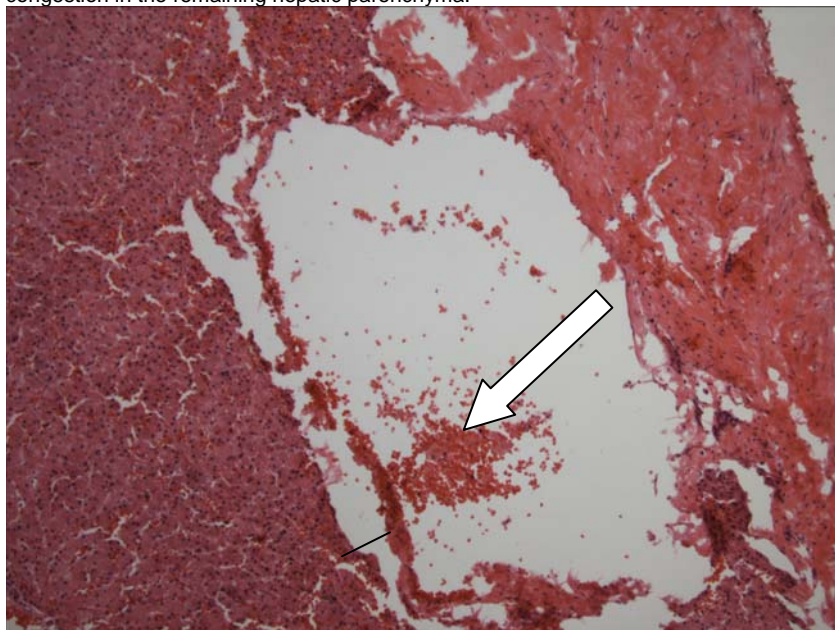


Figure 4. Liver. The hepatic vein is dilated (approximately 3mm). The endothelium is lifted off the hepatic plates (arrow and line). Red cells are limited in these ectatic vessels.

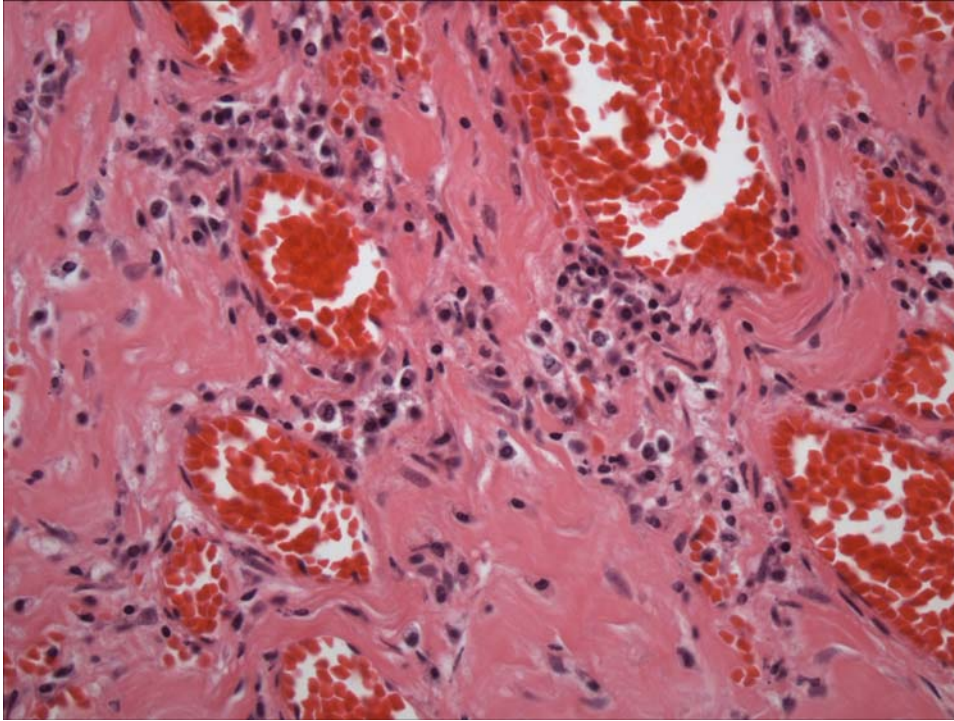


Figure 5. Occipital "Scar" Tissue. There is moderate fibrosis and inflammatory cell infiltrates composed primarily of plasma cells indicating that this is a chronic change.

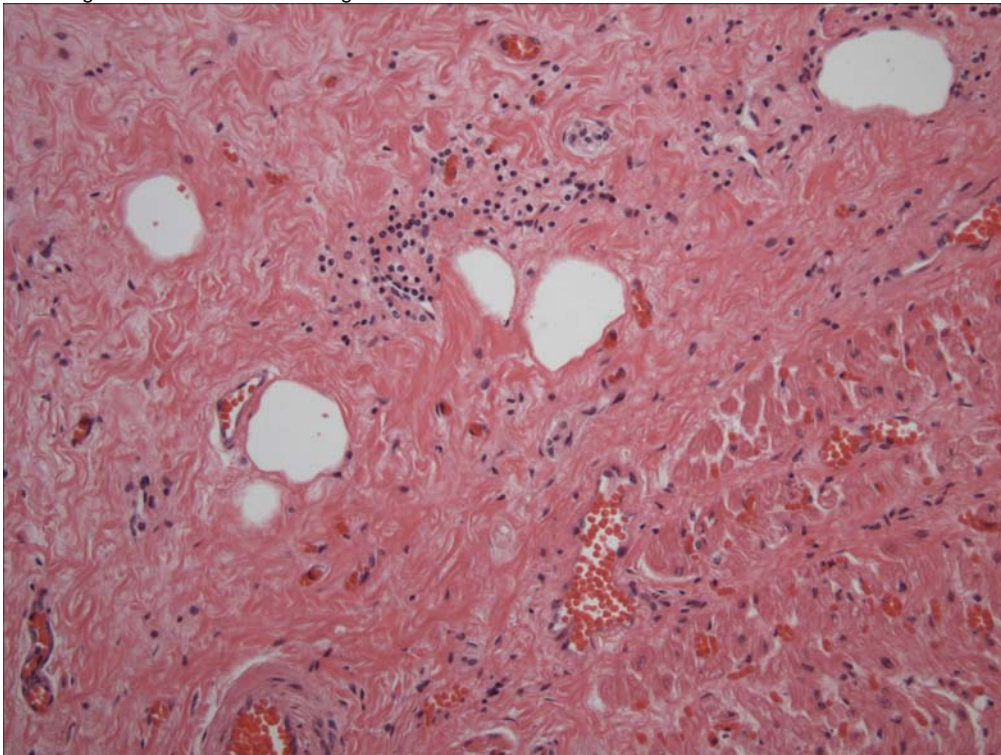


Figure 6. Atrial epicardium. There are scattered lymphocytes and plasma cells.

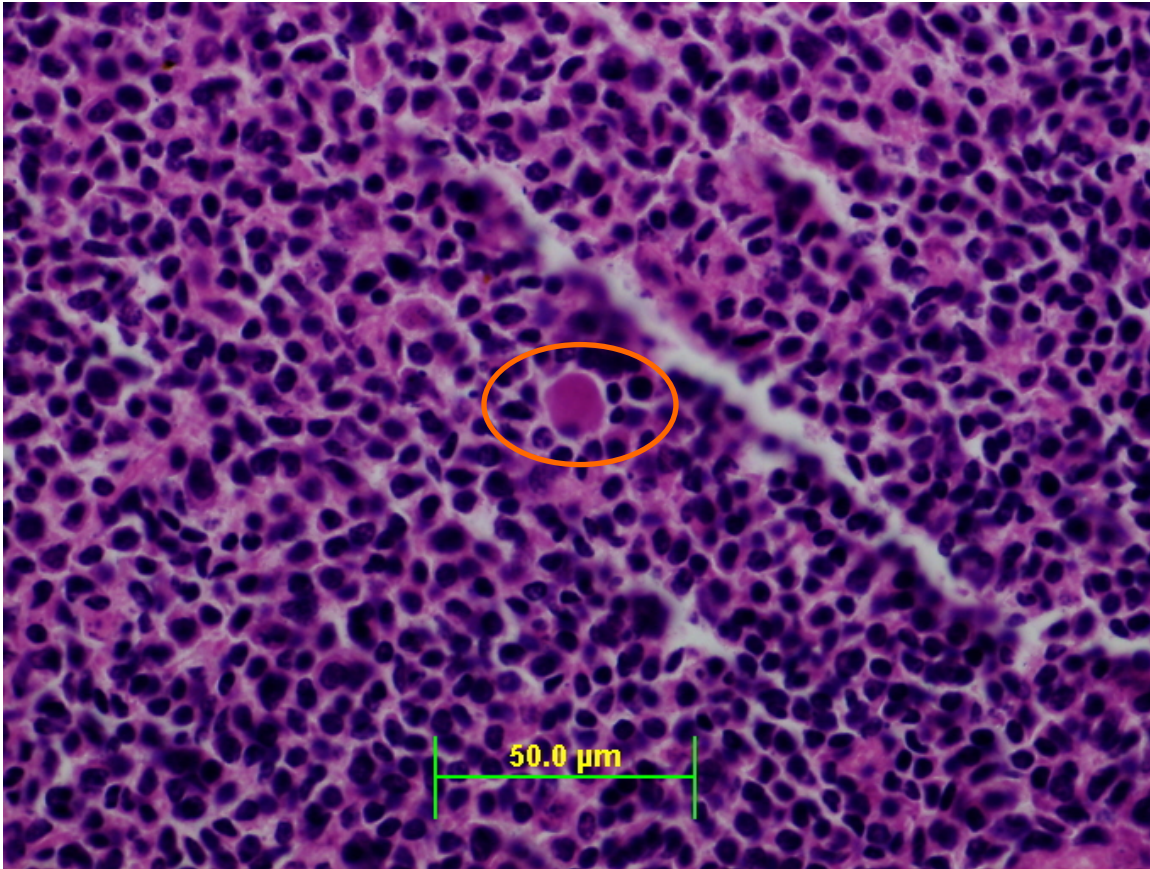


Figure 7. Oral Mucosa. There are increased plasma cells in this lymphoid aggregate. Occasional Russel bodies (plasma cells with abundant rough endoplasmic reticulum) are occasionally observed (circle).

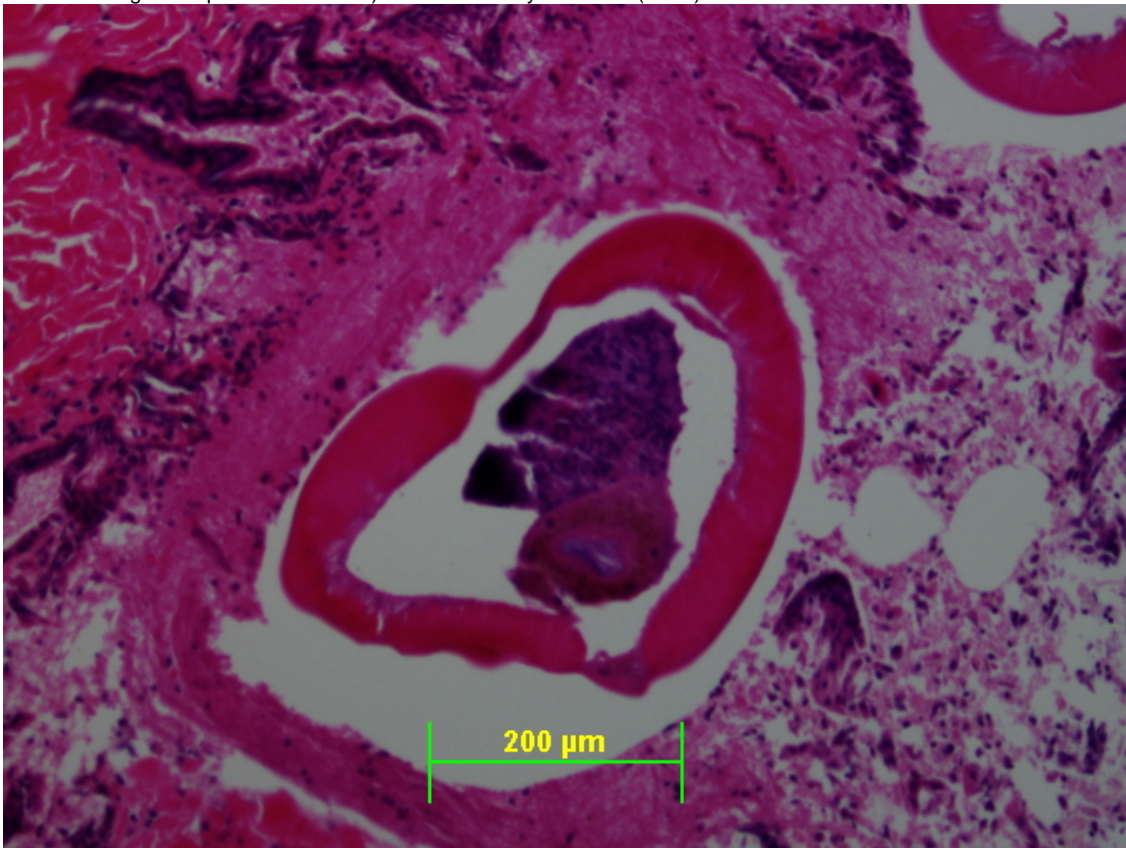


Figure 8. Pterygoid Sinus. There is a cross-section of nematode.

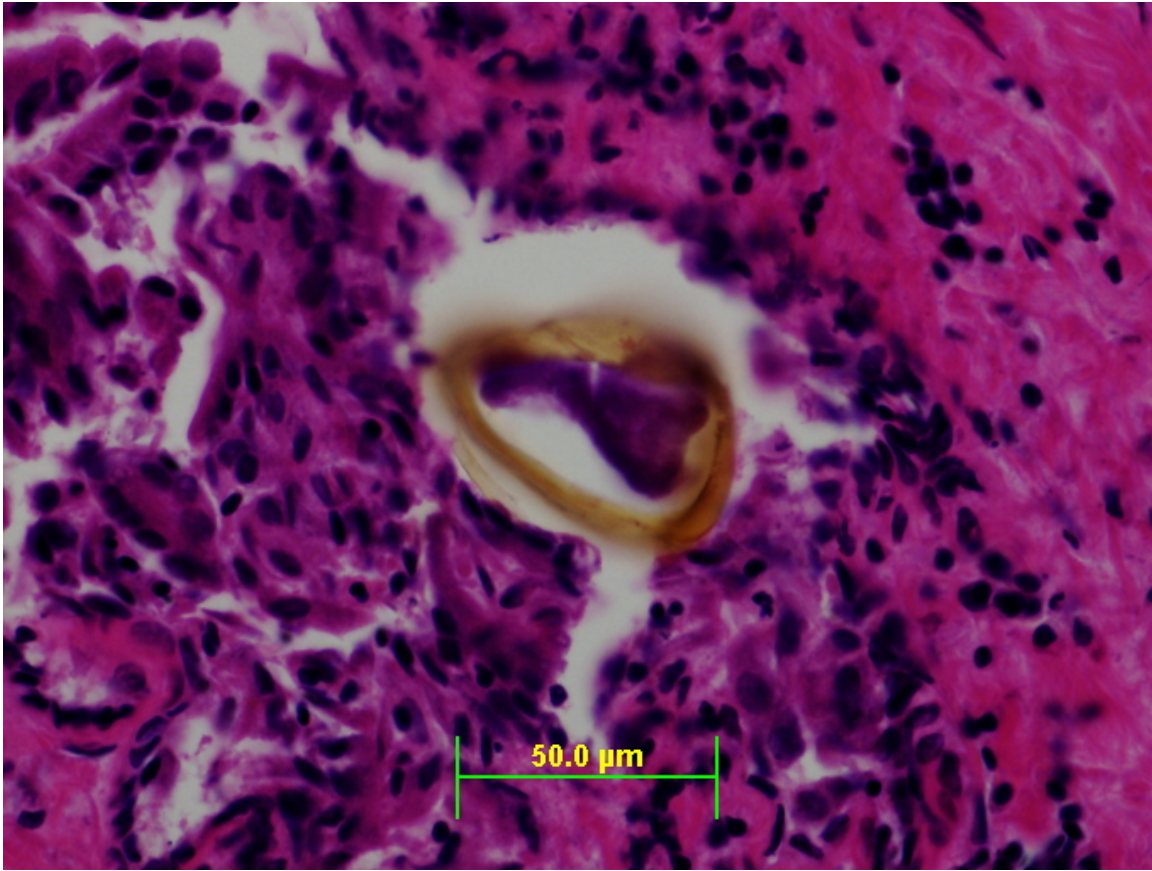


Figure 9. Pterygoid sinus. There is a trematode ova that is pyramidal and has a golden shell.

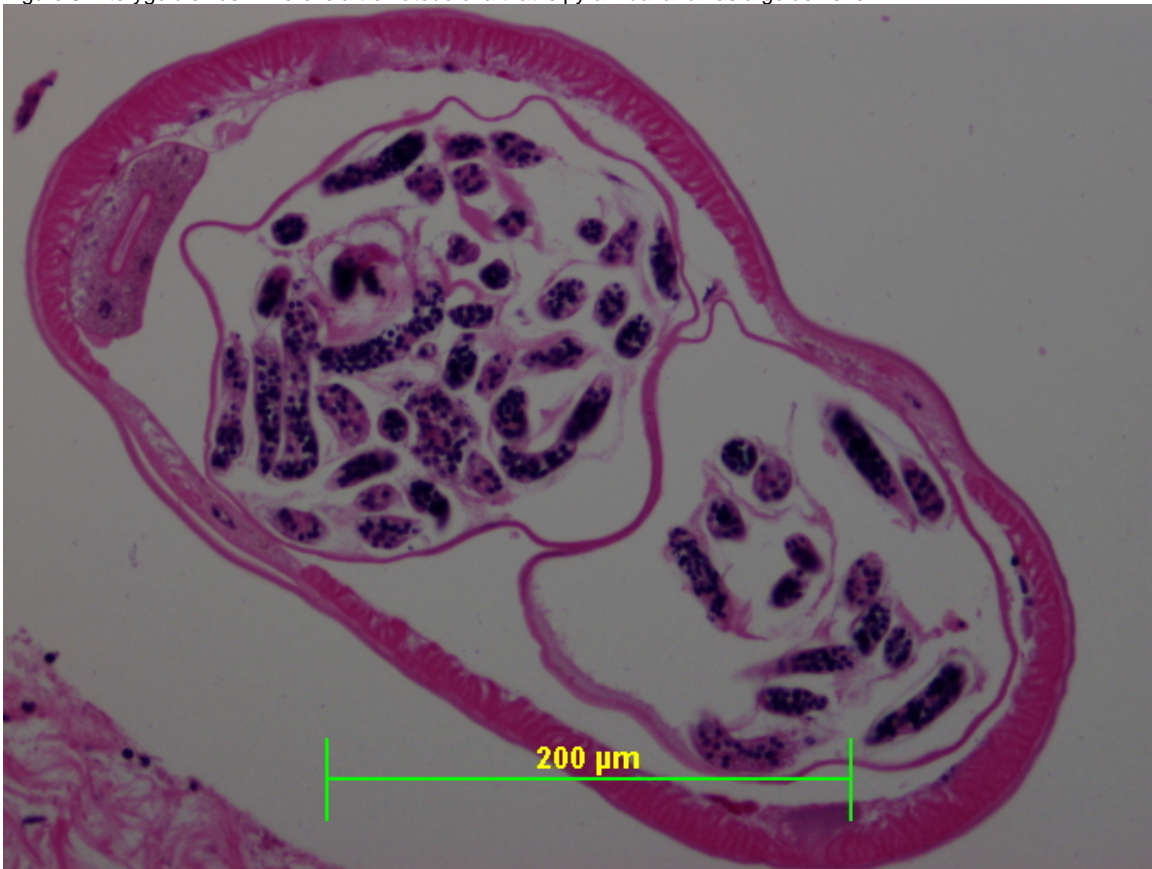


Figure 10. Peribullar Space (Exudate). There is a nematode with larvae present within the reproductive tract.

PENDING			
TEST/HISTO	PURPOSE	SITE	RESULT
Eye			6/17/2005: NSF.
Oil Red O Factor VIII VVG PTAH	Fat Stain Vessel Immunohistochemistry Elastin Stain Fibrin	Liver " "	6/17/2005: NEG 6/17/2005: Please see comment NEG
Decalcification	Examine Tissue	Occipital Bone	Pending

DATE: 15 Mar 05 16 June 2005 05 Dec 2005	REPORTING PATHOLOGIST: David S. Rotstein, DVM, MPVM, DACVP
---	---

CETACEAN NECROPSY REPORT:
Pilot Whale Stranding, NC-15/16 Jan 2005

Field ID: RT54
Accession Number: 05-11C
Date: 15 Jan 2005
Species: Globicephala macrorhynchus
Location: Bodie Island, NC (lat-35.82411, long-75.55324)
Sex: F
TL: 275.0 cm (Sub-adult)

GROSS REPORT
REPORTING INSTITUTION: NOAA Beaufort

Report adapted from necropsy notes.

Abdominal Cavity. One (1) Monorygma cyst in ventral abdominal wall.

Digestive System. There are many living nematodes in the distal esophagus. There are multifocal (n = 5 to 8), circular, slightly raised ulcerated regions with rounded edges in the caudal esophagus that range from 5 to 7 mm in diameter. Many nematodes are present in the distal pylorus. There are multifocal, irregular, white nodules ranging from 1 to 4mm in diameter in the cortex and medulla of the jejunal lymph nodes. There are 10 to 15 nodules per lymph node. There is a pearly metazoan in the wall of the duodenum.

Urogenital System. The right and left ovaries measure 4.2 X 0.8 X 0.8 (cm) and 3.8 X 1.2 X 0.5 (cm), respectively. The left and right uterine horn diameters are 1.8 and 1.9 cm, respectively. Portions of the uterus are discolored. There is no evidence of milk production. No urine is present within the urinary bladder.

Respiratory System. The lungs are inflated with no evident consolidation. On cut section, the caudodorsal lungs lobes contain abundant foamy fluid (~500-600 ml).

Lymphoreticular/Hematopoietic Systems. There is multifocal, splenic capsular fibrosis encompassing 5% of the surface. There is moderate edema of the lung lymph node. There is moderate edema of the cranial mediastinum (thymic region?).

Endocrine System. There is cortical hemorrhage of the right and left adrenal glands encompassing 70% and 60% of the adrenal cortex, respectively.

Head necropsies on 2 dwarf sperm whales and two short-finned pilot whales. All part of mass stranding from 15 (pilot whales) and 16 (Kogia) January 2005. The Kogia heads were frozen within half a day of stranding; the pilot whale heads were frozen the evening of the day after the stranding (Sunday). These animals were selected based on quick transfer of the heads to freezer at time of stranding, and relatively small size (pilot whales, possibly more prone to acoustic trauma). All 4 heads were imaged by CT at the NCSU College of Veterinary Medicine on 31 January (Kogia) and 1 February (pilot whales) while still frozen (stored in walk-in freezer overnight). They were then thawed for necropsy starting on 1 February. The necropsies were performed at NMFS Beaufort Laboratory 3 February. At the time of necropsies the Kogia heads were fully thawed and the pilot whale heads were still cold internally.

Right rostral mandible has squared off defect where tissue was excised on the beach during primary necropsy to sample scar tissue from HI line mark. External auditory meatus is missing on right side from decapitation.

Small amount of sand in pharynx and blowhole.

Subcutis: no hemorrhage or congestion noted.

Ears: Left external auditory meatus, nsf. Peripheral half of right external auditory meatus missing. Soft tissue light pink all around ears, no evidence of hemorrhage near periotic bones or acoustic fat.

Brain: Dura and pia mater both dark red, more so dorsally than ventrally; gyri darker red dorsally. Brain weight 2104 g

Left pterygoid sinus contains a large mass of thin nematodes, particularly concentrated rostrally and dorsally, and to a lesser extent caudally along sinus walls. Mild soft tissue hemorrhage is present rostrally in the left pterygoid sinus. There is a similar distribution but smaller load of nematodes in right pterygoid sinus. Aggregate of nematodes in left pterygoid sinus 8 g, in right pterygoid sinus 3 g,

Collected Samples:

In formalin: both periotic bones, and two sections each from cerebellum, cerebrum and brain stem. In ethanol: sinus nematodes.

ANCILLARY FINDINGS

N/A

TISSUES/SAMPLES RECEIVED
REPORTING INSTITUTION: UNIVERSITY OF TENNESSEE

Received is one bag of formalin labeled as "RT54 10% Formalin". There are four labeled cassettes and 30 free tissues. Cassettes are labeled as "Sub-scapular Lymph Node", "Lung associated Lymph Node", "Mesenteric Lymph Node", and "Peri-renal Lymph Node". Sub-scapular lymph node, lung lymph node, mesenteric lymph node, and peri-renal lymph node are placed in Cassettes 1-4, respectively. Representative sections of remaining tissues are placed in Cassettes 1-9. Received on 3/5/2005 is one bag of formalin fixed tissues labeled as "RT54 Head Tissues 10% Formalin". This includes both ears (free tissue) and six cassettes labeled as "Cerebellum" (2), "Cerebrum" (2), and "Brainstem" (2). Representative sections are placed in Cassettes 10-15 and have been submitted for processing 3/14/2005. Results will follow as an addendum to this preliminary report.

MICROSCOPIC FINDINGS

REPORTING INSTITUTION: UNIVERSITY OF TENNESSEE

Sub-scapular Lymph Node (slide 1): There is mild lymphoid hyperplasia. Macrophages are increased within the edematous medullary spaces. There is scattered mineral.

Heart (slides 1, 4, and 5): No significant histologic findings (NSF).

Kidney (slides 1, 2 and 5): There is moderate congestion. Occasional vessels are moderately dilated.

Lung Lymph Node (slide 2): There is diffuse moderate lymphoid depletion and medullary edema.

Liver (slides 2 and 7): There is diffuse, moderate, congestion with regions of more pronounced sinusoidal distention. There is multifocal, mild to rarely moderate biliary hyperplasia. There is a mild increase in lymphocytes, plasma cells, and fewer hemosiderophages within periportal tracts.

Mesenteric Lymph Node (slide 3): Lymphoid follicles are prominent. There are increased macrophages within medullary spaces.

Skeletal Muscle (slide 3): There is a single degenerate myofiber.

Aorta (slide 3): NSF.

Myometrium (slide 4): NSF.

Peri-renal Lymph Node (slide 4): Secondary follicles are present. There is medullary edema and increased macrophages within medullary spaces. Macrophages have foamy eosinophilic cytoplasm, or less commonly, contain intracytoplasmic brown granular pigment (hemosiderin).

Lung (slide 5): There are scattered alveolar lumina filled with foamy macrophages. There is focally extensive interstitial fibrosis.

Tongue (slide 5): NSF.

Epaxial Muscle (slide 6): NSF.

Uterus (slide 6): The endometrium is lined by a single layer of low cuboidal epithelial cells. There is a paucity of glands which are arranged in straight rows.

Intestine (slides 6, 9): NSF.

Spleen (slide 6): There is mild, diffuse, depletion of periarterolar sheaths. There are scattered hemosiderophages.

Thyroid Gland (slides 6 and 9): Approximately 70% of follicular lumina are filled with homogenous, eosinophilic colloid. Remaining follicles are collapsed and lined by vacuolated cuboidal epithelial cells. There is scattered mineral.

Intestine (slide 7): NSF.

Thymus (slide 7): There is moderate lymphocytolysis and poor distinction between cortex and medulla (thymic involution).

Adrenal Gland (slide 7): There is moderate congestion at the interface of cortex and medulla.

Cervical Spinal Cord (slide 8): There is multifocal myelin sheath swelling.

Pancreas (slide 9): There is focal accumulation of histiocytes within the adipose.

Cerebellum (slides 10 and 11): There is autolysis and freeze artifact.

Cerebrum (slides 12 and 13): There is autolysis and freeze artifact with formation of post-mortem emphysematous pockets.

Brainstem (slides 14 and 15): In one section, slide 14, there are rare vessels with a sprinkling of lymphocytes in Virchow-Robbin's spaces.

MORPHOLOGIC DIAGNOSES

Hematopoietic/Lymphoreticular System:

Lymph Node, Multiple: Congestion and histiocytosis.

Urinary System:

Kidney: Congestion, diffuse, moderate with occasional venular ectasia.

Hepatobiliary System:

Liver:

a. Congestion, diffuse, moderate.

b. Biliary hyperplasia, diffuse, mild with mild, lymphoplasmacytic periportal hepatitis.

FINAL DIAGNOSES/INTERPRETATIVE SUMMARY

Congestion-liver, kidney
Periportal hepatitis and biliary hyperplasia

Lesions are very mild in this case and do not provide a reason for this cetacean's demise. Biliary hyperplasia and periportal hepatitis may indicate a site of parasite migration or prior ascending infection from the digestive tract.. Congestion is observed in the liver and kidney.

FIGURES

N/A

PENDING

TEST/HISTO	PURPOSE	SITE	RESULT
Brain			Complete-26Apr05

DATE:
15 Mar 05/26 Apr 05

REPORTING PATHOLOGIST:
David S. Rotstein, DVM, MPVM, DACVP

CETACEAN NECROPSY REPORT:
Pilot Whale Stranding, NC-15/16 Jan 2005

Field ID: RT57
Accession Number: 05-12C
Date: 15 Jan 2005
Species: Globicephala macrorhynchus
Location: Bodie Island, NC (lat-35.81844, long-75.55070)
Sex: M
TL: 506.0 cm (Adult)

GROSS REPORT

REPORTING INSTITUTION: NOAA Beaufort

Report adapted from necropsy notes and Head Necropsy data sheet.

This was a human interaction case.

External Examination. There were healed line marks on head and on mouth. There were associated broken teeth. There was a healed puncture wound on fluke. (*Note Bene: Old lesions, not attributed to cause of death.*)

Abdominal Cavity. Monorygma observed on abdominal wall.

Musculoskeletal System. The right scapulohumeral joint was clean.

Respiratory System. The left lung lobe is blood filled on cut section (dependent side).

Cardiovascular System.

Location	Measurement	Comment
Right Ventricular Freewall	1.5 cm	
Left Ventricular Freewall	4.0 cm	
Inteentricular Septum	3.5 cm	

Lymphoreticular/Hematopoietic System. The pre-scapular lymph node is dark red on cut surface and slightly mottled.

Digestive System. There were nematodes in the main stomach. The forestomach was collected whole. The intestines are 21 meters.

Genitorurinary System. The right kidney measures 70 X 25 X 7 (cm). Urine is saved. Gonads are regressed with the right and left gonads measuring 44 X 12 X 3 cm and 42 X 10 X 3 cm, respectively. Gonads are collected whole. Cranial to the bladder, there is a 5 X 2.5 cm reniform abscess which is full of purulent exudate and calcified debris. PHOTO obtained.

HEAD NECROPSY DATA: The skull is flensed and frozen with brain still inside. The right pterygoid sinus contains Nasitrema and Stenurus. No parasites were observed in the left pterygoid sinus. Nasitrema observed in internal nares.

ANCILLARY FINDINGS

N/A

TISSUES/SAMPLES RECEIVED

REPORTING INSTITUTION: UNIVERSITY OF TENNESSEE

Received is one bag of formalin labeled as "RT57 10% Formalin". There is one labeled cassettes and two free tissues. Cassette is labeled as "Pre-scapular Lymph Node" and representative sections are placed in Cassette 1. Representative sections of remaining tissues are placed in Cassettes 1 and 2.

MICROSCOPIC FINDINGS

REPORTING INSTITUTION: UNIVERSITY OF TENNESSEE

Pre-Scapular Lymph Node (slide 1): There is marked autolysis with bacterial overgrowth. Determination of lymphocyte populations is not possible due to the autolytic changes.

Testis (slide 1 and 2): Seminiferous tubules are lined by germ cells diffusely. There is spermatid maturation in 60% of tubules.

MORPHOLOGIC DIAGNOSES

Reproductive System:

Testis:

- a.Active spermatogenesis (see comment).
- b.Regression (atrophy).

FINAL DIAGNOSES/INTERPRETATIVE SUMMARY

Unfortunately, sampling from this animal was limited and of the two tissues received, lymph node and testis, only the testis had excellent preservation. A cause of stranding is not evident. Parasites in the pterygoid sinus are not unexpected given results of other pilot whale head dissections.

There is active spermatogenesis in the testis, but only involving a little over half of the seminiferous tubules. Other tubules are inactive suggesting regression has also taken place.

FIGURES

N/A

PENDING

TEST/HISTO	PURPOSE	SITE	RESULT

DATE:
15 Mar 05

REPORTING PATHOLOGIST:
David S. Rotstein, DVM, MPVM, DACVP

**CETACEAN NECROPSY REPORT:
Pilot Whale Stranding, NC-15/16 Jan 2005**

Field ID: RT59
 Accession Number: 05-13C
 Date: 15 Jan 2005
 Species: Globicephala macrorhynchus
 Location: Bodie Island, NC (lat-35.83323, long-75.55797)
 Sex: F
 TL: 383.0 cm

GROSS REPORT
 REPORTING INSTITUTION: NOAA Beaufort

Report adapted from necropsy notes.

External Exam: Multifocal nodules ranging in size from 2-5 cm concentrated caudal to dorsal fin; less dense on trunk. Two sets rake marks caudal to dorsal, mid-lateral, small ulcer/possibly abscess underneath (not fresh). There are five teeth present in the upper right with 2 broken and 1 missing. There are eight present in the lower right with 6 loose. Three left upper teeth are present and 6 left lower teeth are present.

Internal Exam:

Blubber: Moderate amounts of Phyllobothrium around the vent. There is a small amount of pale, straw colored fluid in the abdominal cavity. There is approximately 30ml of pale, straw colored fluid within the pericardial sac.

Musculoskeletal System: There is dark, grey fluid at the base of the hyoid bone.

Respiratory/Circulatory: Monorygma are associated within the margin of the left lung lobe. The bronchus is full of white foam. There is abundant sand in the pharynx and the tips of the arytenoids are swollen, red, and edematous. There is serous atrophy of fat around the heart. There are regions of suspect cardiac fibrosis and ventricles are enlarged and flabby. Ventricular wall thickness is as follows: right ventricular free wall-9mm, left ventricular free wall-2.8 cm, and interventricular septum-3.4 cm.

Lymphatic: The spleen measures 11 X 8.5 X 2.5 cm. There is irregular fingerlike scarring along margins. On cut surface, mesenteric lymph nodes contain chalky fluid and one mesenteric lymph node had an attached mineralized cyst.

Endocrine: The right adrenal gland measures 11.2 X 3.3 X 1.3 cm.

Digestive: The lining of the esophagus is sloughing and there are writhing ascarids in the lower esophagus. The intestines measure 449 cm. The liver is steel gray.

Urinary: There are abundant Monorygma around the urogenital region. The right kidney measures 49.0 X 18.0 X 8.0 cm and the left kidney measures 49.0 X 15.0 X 9.0 cm.

Reproductive: The right and left ovary measure 5.0 X 2.5 X 1.0 cm and 5.0 X 2.5 X 1.5 cm, respectively. The mammary gland measures 55 X 7.1 X 2.7 cm. On cut surface the mammary gland is pale pink and there is a small amount of thin, viscous fluid within the duct.

Stomach Contents Data Sheet:

Site	Full	Empty	Contents
Esophagus	None	None	None
Forestomach	6420g	5187g	233g
Main	1459g	1468g	Scale error?
Pyloric	1166g	1124g	37g

Comment:

Pyloric: 1 granulated ulcer, 35 X 24 mm. 2 dime-sized healed ulcers, some ice, 60 to 80 nematodes.

Main: 1 granulated ulcer, 43 X 35 mm, 1 quarter-sized ulcer, otoliths and beaks collected; light load of nematodes.

Fore: Heavy load of nematodes. 4 granulated ulcers, 60 X 28 X 18mm, 45 X 65 X 10 mm, and 52 X 60 X 12 mm.

ANCILLARY FINDINGS

Urinalysis. Conducted by C. Harms

Test	Result
Specific Gravity	1.015
Urobilinogen	0.2
Protein	3+
pH	6.5
Blood	3+
Ketones	trace
Bilirubin	NEG
Glucose	NEG
Collection	Catheter

TISSUES/SAMPLES RECEIVED
 REPORTING INSTITUTION: UNIVERSITY OF TENNESSEE

Received is one bag of formalin labeled as "RT59 10% Formalin". There are four labeled cassettes and 32 free tissues including an eye. Cassettes are labeled as "Pre-scapular Lymph Node", "Lung Lymph Node", "Mediastinal Lymph Node", and "Mesenteric Lymph Node". The eye is placed in a megacassette (#12) and is being processed at North Carolina State University. Pre-scapular lymph node, lung lymph node, mediastinal lymph node, and mesenteric lymph node are placed in Cassettes 1-4, respectively. Representative sections of remaining tissues are placed in Cassettes 1-11.

MICROSCOPIC FINDINGS

REPORTING INSTITUTION: UNIVERSITY OF TENNESSEE

Blubber (slides 1 and 2): Three sections are examined. In one section (Slide 2), there is regionally extensive fibrosis with scattered fibrocytes and occasional vascular channels lined by plump endothelial cells within the collagenous stroma (Figure 1).

Aorta (slide 1): No significant histologic findings (NSF).

Pre-scapular Lymph Node (slide 1): There is mild lymphoid hyperplasia. There are multiple, variably-sized vacuoles within the center of follicles and within occasional medullary cords (adipocytes) without associated erythrocyte extravasation (hemorrhage). Vacuoles are 20 to 40 microns.

Adrenal Gland (slides 1,8, and 10): There is thinning of the cortex and dilation of vascular channels.

Lung Lymph Node (slide 2): There is moderate loss of lymphoid follicles with associated fibroplasia. Eosinophils are increased in number.

Kidney (slide 2): Within occasional tubules, there is an accumulation of eosinophilic homogenous to granular fluid (Figure 2). Approximately 45% of glomeruli have thickened Bowman's capsule with associated plump parietal epithelial cells. Glomerular tufts are segmentally thickened in these affected glomeruli (Figure 3). Tubular epithelial cells contain variable amounts of golden-brown intracytoplasmic pigment (hemosiderin vs. ceroid-lipofuscin).

Mammary Gland (slides 2, 8, 9 and 10): Acini are collapsed with little to no proteinaceous product. Ducts contain granular eosinophilic fluid with interspersed macrophages and globular to acicular mineral. There are scattered lymphocytes, plasma cells, and macrophages laden with golden brown pigment (ceroid-lipofuscin vs hemosiderin).

Mediastinal Lymph Node (slide 3): Lymphoid follicles are minimally depleted. There is moderate edema of the medullary spaces with associated increases in foamy macrophages. There are scattered macrophages with intracytoplasmic black granular pigment (anthracosis).

Lung (slide 3): There are occasional foamy macrophages within alveolar lumina (pulmonary edema).

Urinary Bladder (slide 3): NSF.

Mesenteric Lymph Node (slide 4): There is depletion of lymphocytes. Hemosiderophages and eosinophils are increased. There is regionally extensive fibroplasia with associated loss of follicles.

Skeletal Muscle (slides 4 and 6): NSF.

Liver (slide 5): Diffusely, Kupffer cell cytoplasm and portal macrophage cytoplasm are swollen with brown granules (hemosiderin). There is a mild increase in plasma cells and lymphocytes in portal tracts. There is mild to moderate biliary hyperplasia with regions of increased portal fibrous connective tissue which occasionally bridges to adjacent portal tracts and disrupts hepatocellular cords (Figure 4). Approximately 45% of hepatocytes contain intracytoplasmic brown granular pigment (hemosiderin vs. ceroid-lipofuscin). There is subendothelial edema of occasional hepatic veins (Figure 5) and increased collagen surrounding central and hepatic veins (Figure 6). There is moderate congestion.

Heart (slides 5, 7, 9, and 10): There is multifocal, mild to moderate cardiomyocyte loss and fibrosis (Figures 7a and b). There are occasional cardiomyocytes which exhibit a loss of cross-striations and contain globular basophilic material (mineralization vs. degenerating parasite). Multifocally cardiomyocytes are mildly attenuated and wavy. There are scattered lymphocytes and plasma cells within the interstitium.

Bronchi (slide 6): There are scattered lymphocytes and plasma cells within the submucosa. Vascular channels are moderately to markedly ectatic.

Thyroid Gland (slide 7): There is a focal, 1.0 cm in diameter follicular cyst lined by a single layer of attenuated cuboidal epithelial cells (Figure 8). There are smaller, 2.0 to 3.0 mm cysts adjacent to the larger cyst.

Spleen (slide 9): Periarteriolar sheaths are mildly reactive. There are scattered hemosiderophages.

Intestine (slide 10): There is a mild increase in plasma cells within the lamina propria.

Spinal Cord (slide 11): Two sections are evaluated. There is mild to moderate accumulation of golden, granular pigment within the neuronal perikaryon. Within the spinal roots, there is a single degenerate neuron surrounded by a few lymphocytes (Figure 9).

Eye (slide 12) (17 June 2005): NSF.

MORPHOLOGIC DIAGNOSES

Cardiovascular System:

Heart: Fibrosis and cardiomyocyte, loss, multifocal, mild to moderate with occasional myofibers mineralization.

Hepatobiliary System:

Liver:

- a. Periportal fibrosis, multifocal to occasionally bridging portal to portal, moderate with lymphoplasmacytic periportal hepatitis, biliary hyperplasia, and periportal hemosiderosis.
- b. Hemosiderosis, sinusoidal and hepatocellular, diffuse, moderate.
- c. Centrilobular and hepatic venular fibrosis, diffuse, moderate.

Urogenital System:

1. Kidney: Glomerulopathy, membranous, segmental, multifocal, moderate with Bowman's capsule thickening and multifocal tubuloproteinosis.

2. Mammary Gland:

- a. Mastitis, interstitial, lymphoplasmacytic, multifocal, mild.
- b. Glandular regression (atrophy).

Integumentary System:

Blubber: Fibrosis, regionally extensive.

Hematopoietic/Lymphoreticular System:

1. Lung and Mesenteric Lymph Node:

- a. Fibrosis, regionally extensive, moderate.
- b. Lymphadenitis, eosinophilic, diffuse, mild.

2. Mediastinal Lymph Node: Anthracosis.

Respiratory System:

Bronchi: Bronchitis, submucosal, lymphoplasmacytic, diffuse, mild.

Endocrine System:

Thyroid Gland: Follicular cysts, multiple.

Nervous System:

Spinal Cord: Neuronal ceroid-lipofuscinosis, diffuse, mild to moderate with focal, minimal lymphocytic perianglioneuritis.

FINAL DIAGNOSES/INTERPRETATIVE SUMMARY

Cardiac fibrosis with secondary hepatic chronic passive congestion.
Membranous glomerulopathy.

The cause of stranding and death in this animal is likely associated with underlying chronic cardiac disease. This is supported by multiple regions of cardiac fibrosis. Inflammation is very mild, and thus, whether this condition resulted from prior myocarditis of unknown etiology (viral, bacterial, toxic, protozoal) or an underlying cardiomyopathy is speculative. Hepatic changes are supportive of cardiac disease as there are increased hemosiderophages indicating either stasis of blood (congestion) or increased erythrocyte breakdown. The absence of bile within canaliculi makes this less likely. In addition, fibrosis of venules, portal tract fibrosis, and biliary hyperplasia may be associated with portal hypertension in cardiac disease; in addition, fibrosis and hyperplasia of bile ducts could be the result of prior ascending infection from the digestive tract or migration of parasites, though inflammation was limited in these regions..

There is evidence of a membranous glomerulopathy which may be the result of immune complex deposition or may relate to systemic hypertension which may have resulted in increased fluid load upon the heart. There is an indication of at least some effect upon glomerular function based upon the presence of protein within tubules. The number of tubules affected is not large, and thus, the protein in the urine likely reflects a great contribution from erythrocytes rather than the kidney itself. There was no evidence of a cystitis.

Mastitis was mild and unlikely to have resulted in significant effect upon this cetacean. Lymph node fibrosis is likely the result of prior migration of parasites or bacterial/fungal infection in the lymph node. Fibrosis of the blubber indicates a site of prior trauma. The overlying epithelium was intact. Neuronal ceroid-lipofuscinosis is likely an age-related change in neurons (rather than an indicator of a storage disease). Inflammation in the spinal root is very mild and limited to a degenerating neuron. Viral inclusions are not evident in the nervous system. Thyroid follicular cysts are an incidental finding.

Finally, there are vacuoles within the prescapular lymph node without associated hemorrhage. These likely represent resident adipocytes.

FIGURES

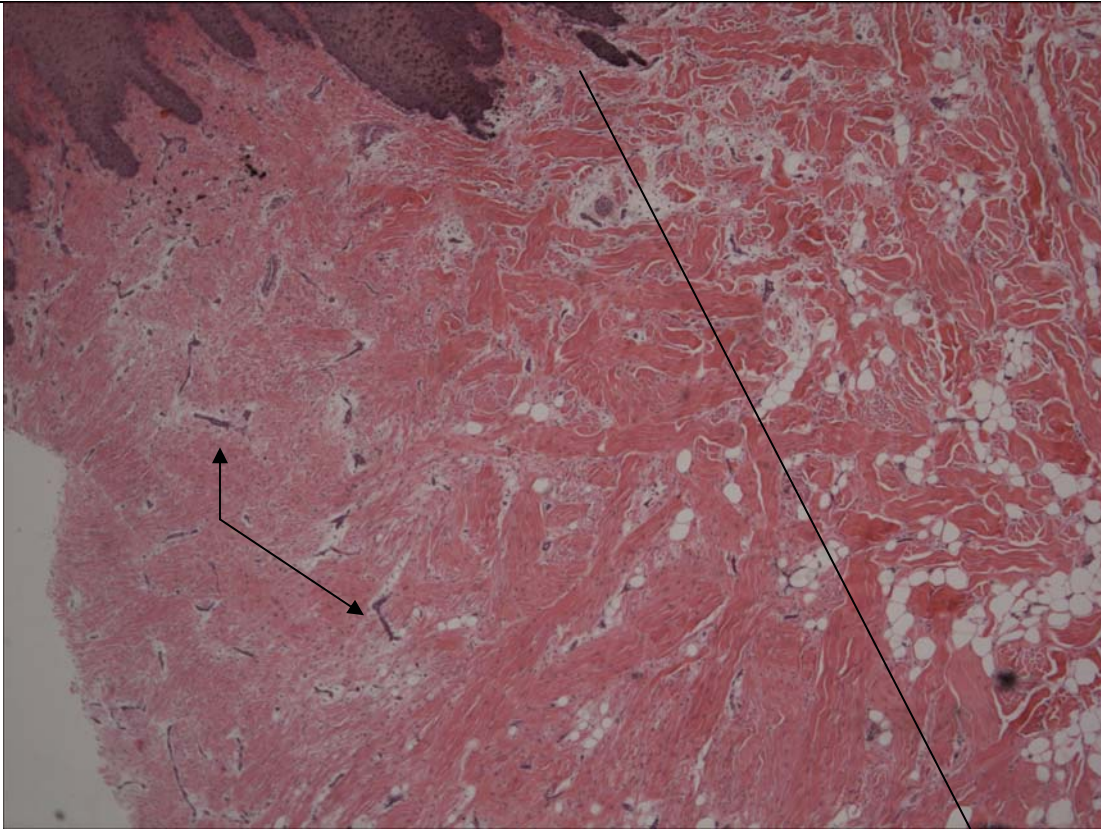


Figure 1. Blubber. There is a demarcation between normal bundles of collagen in the fibroadipose and the region of fibroplasia (line) with interspersed vascular channels (arrow).

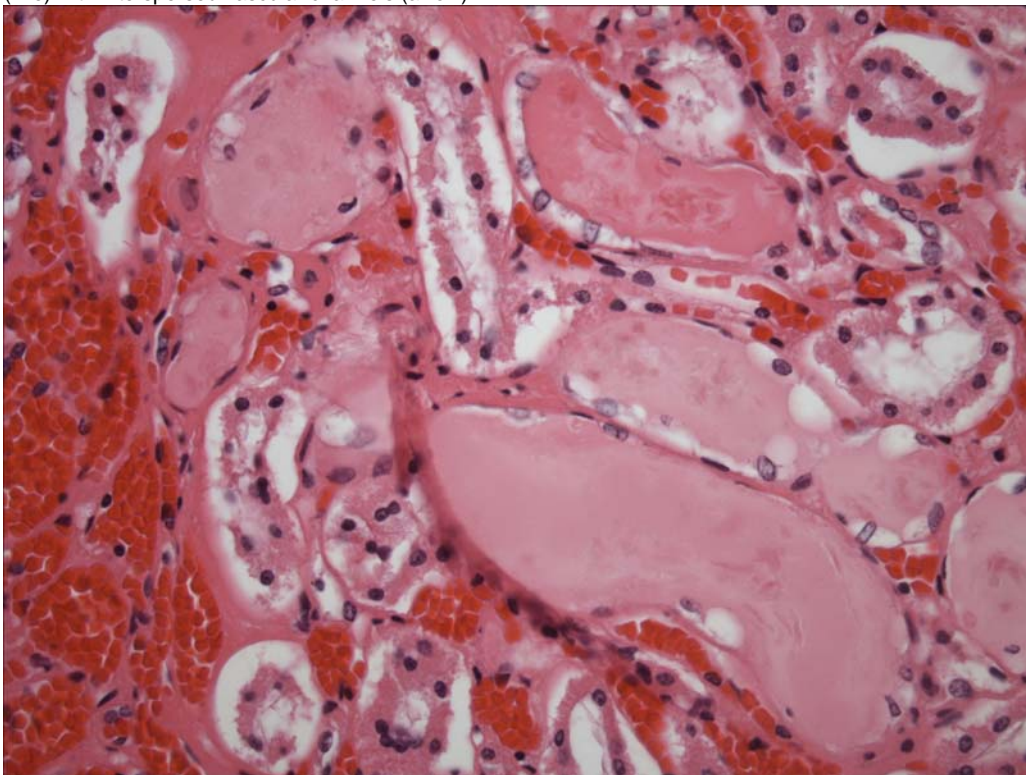


Figure 2. Kidney. There is proteinaceous fluid within tubules (tubuloproteinosis).

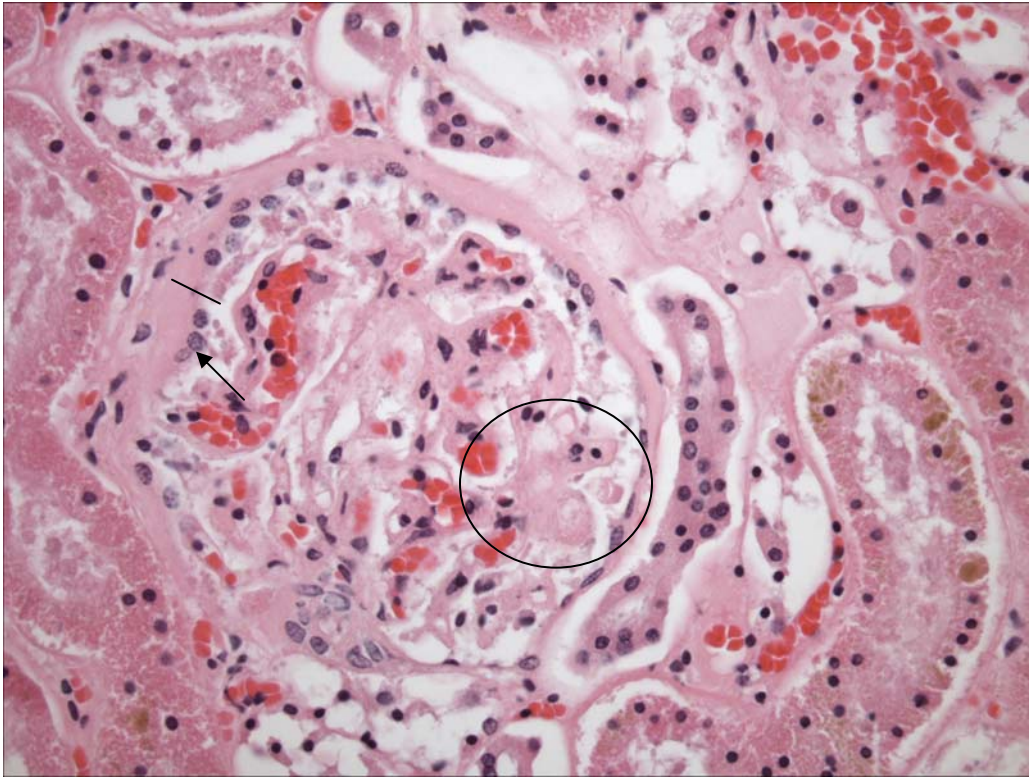


Figure 3. Glomerulus. There is thickening of Bowman's capsule (line). Bowman's capsule parietal epithelium is prominent (arrow). There is segmental thickening of a glomerular capillary tuft (circle). Adjacent tubular epithelial cells contain intracytoplasmic pigment.

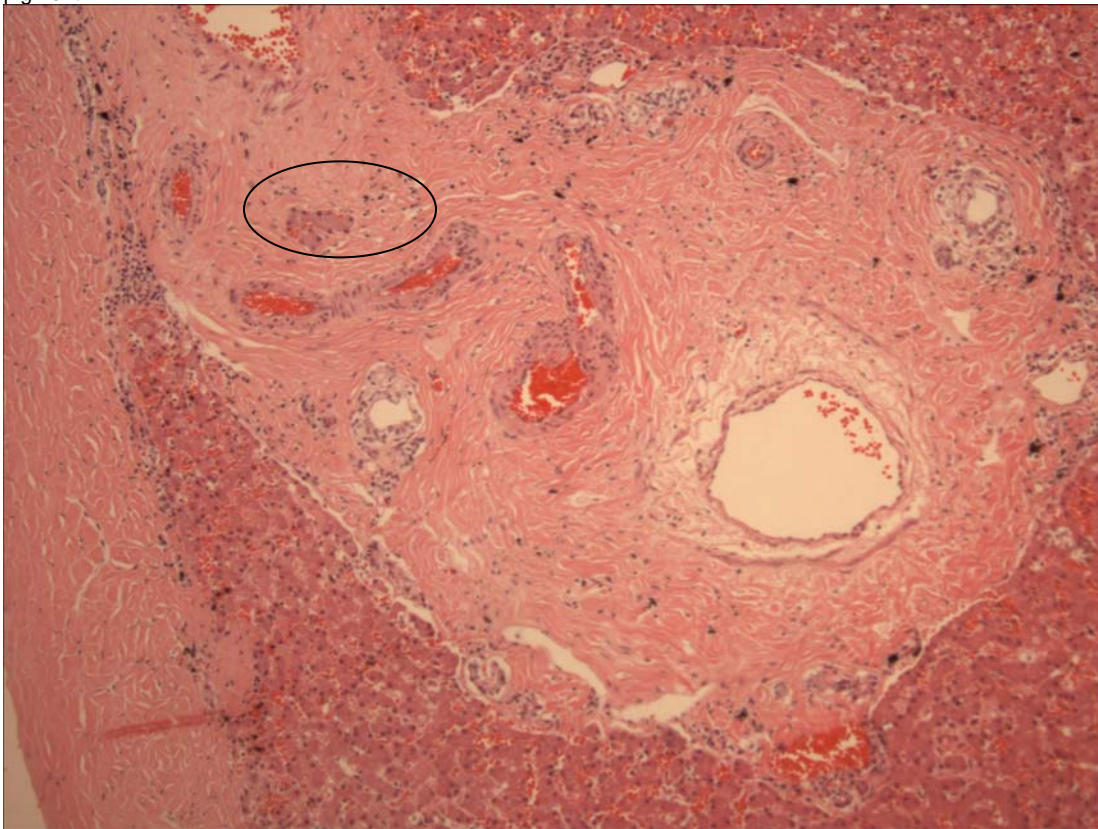


Figure 4. Liver. There is moderate portal fibrosis with fibrous connective tissue extending beyond the hepatic plate leaving occasional small islands of hepatocytes (circle). There is hyperplasia of biliary tracts.

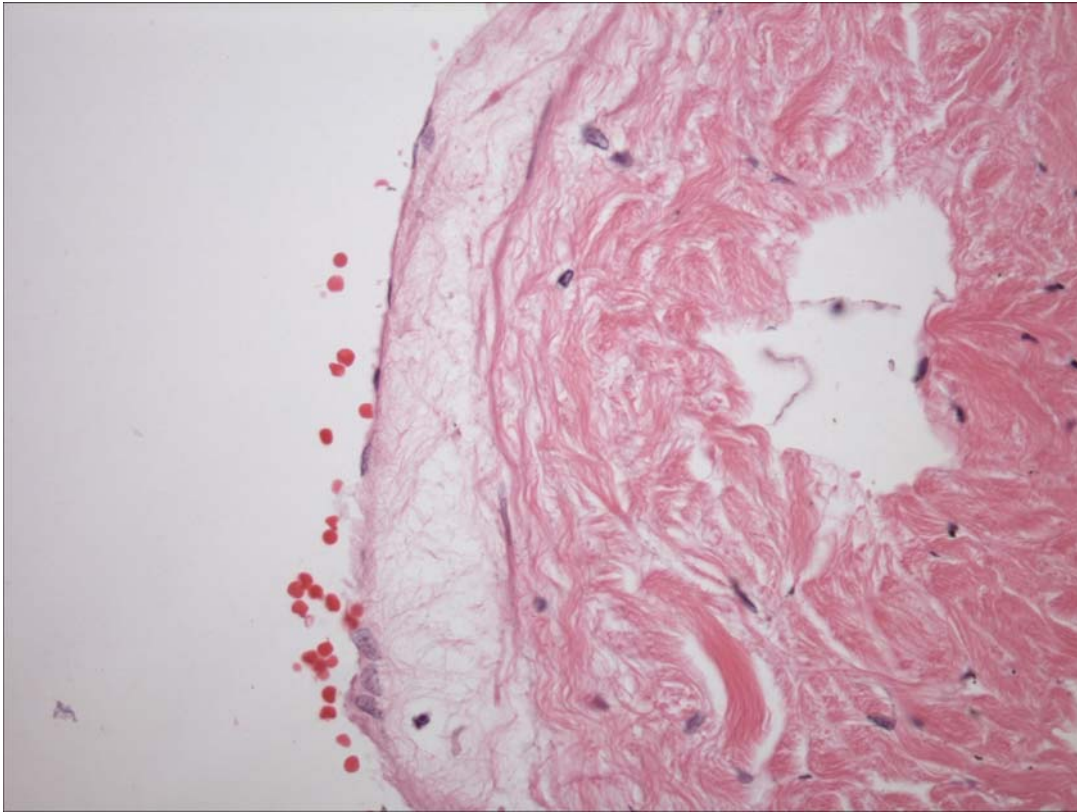

Figure 5. Liver. There is expansion of the sub-intima by edema. Endothelial cells are prominent.

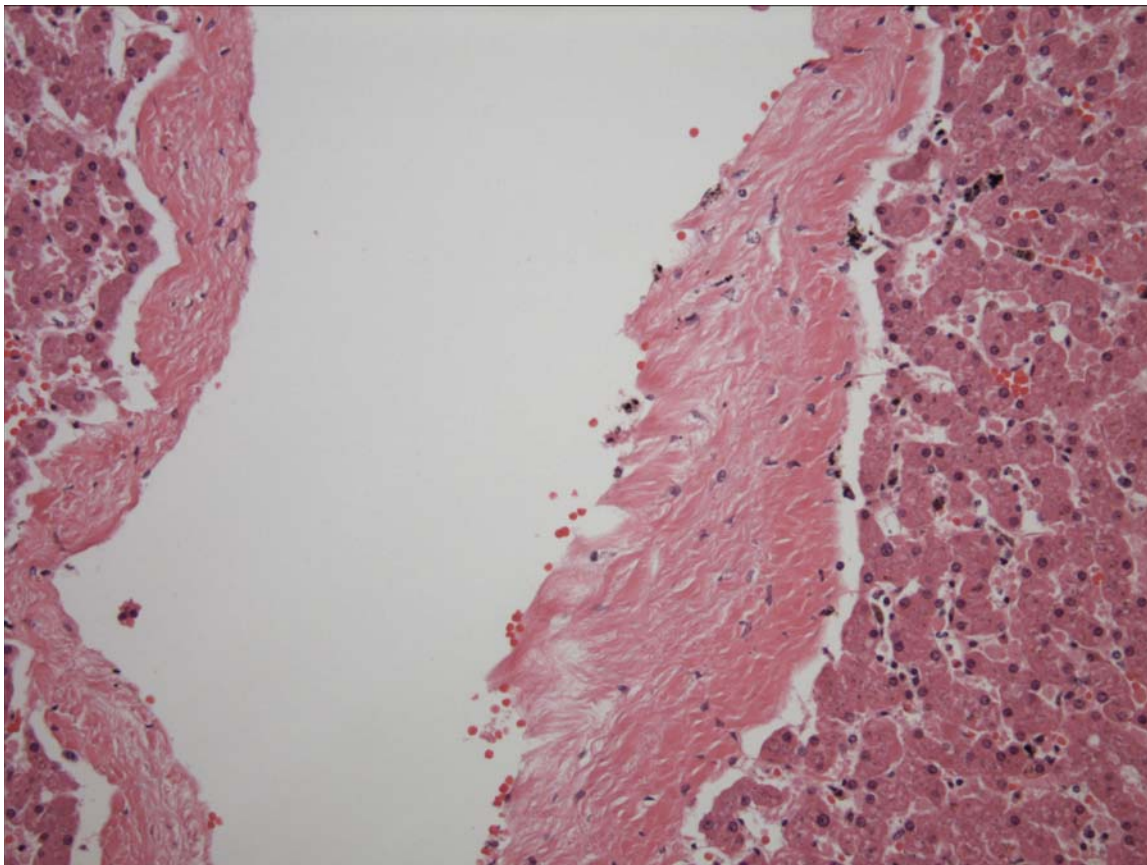
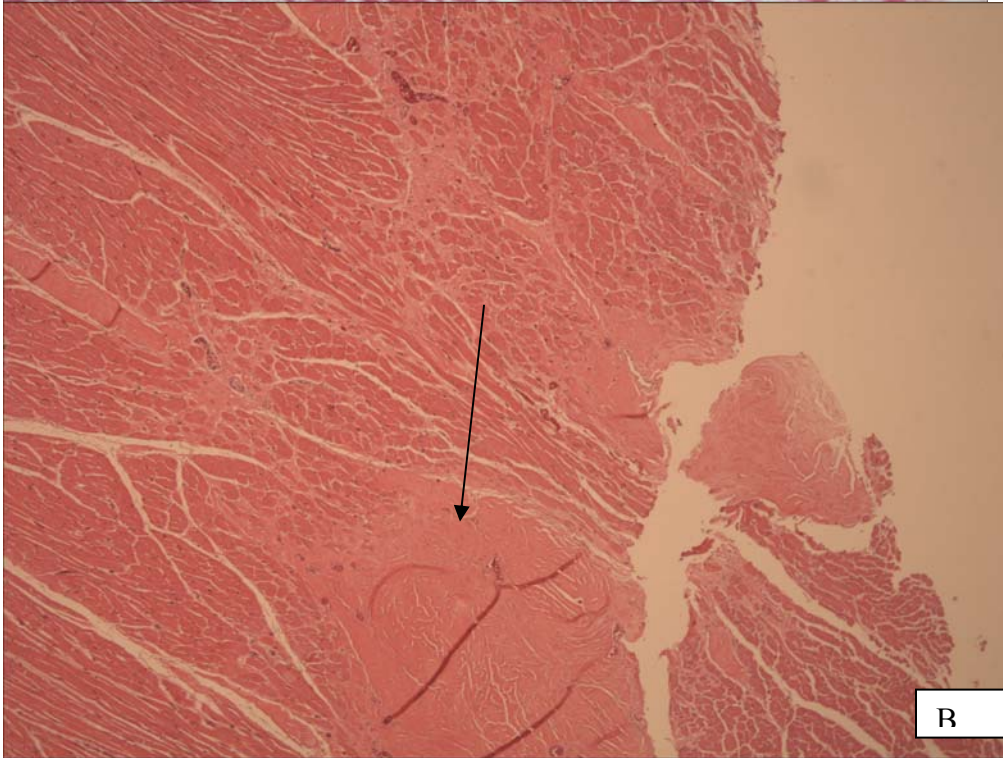
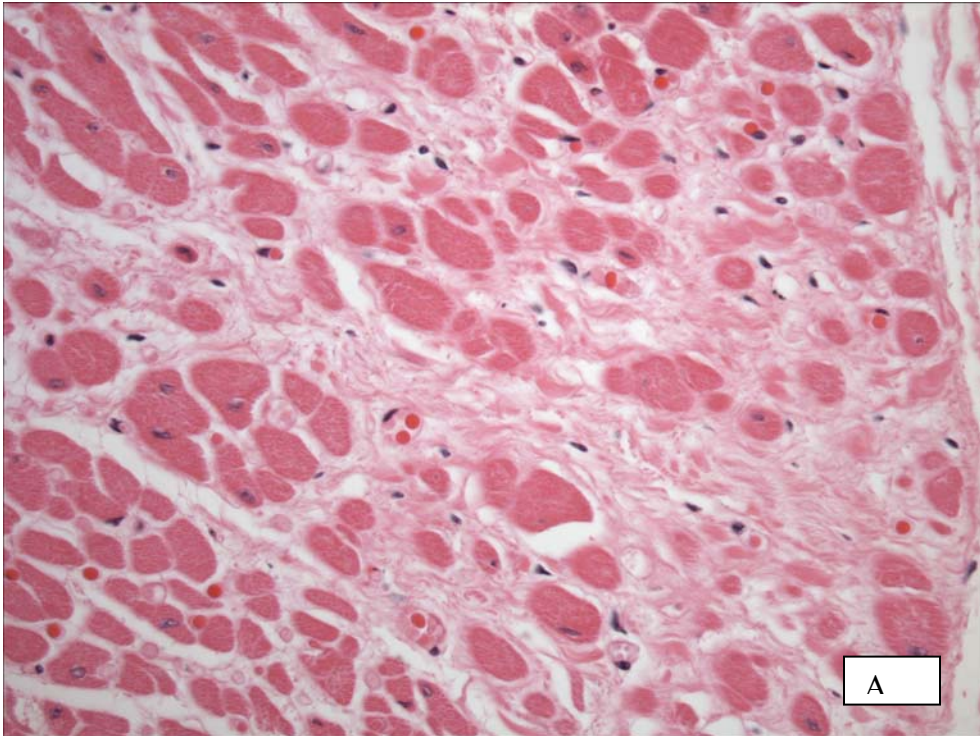


Figure 6. Liver. There is fibrosis of central veins and hepatic veins indicating increased vascular pressure (hypertension).



Figures 7 a and b. Heart. Cardiac fibrosis ranges from mild to more pronounced (arrow).

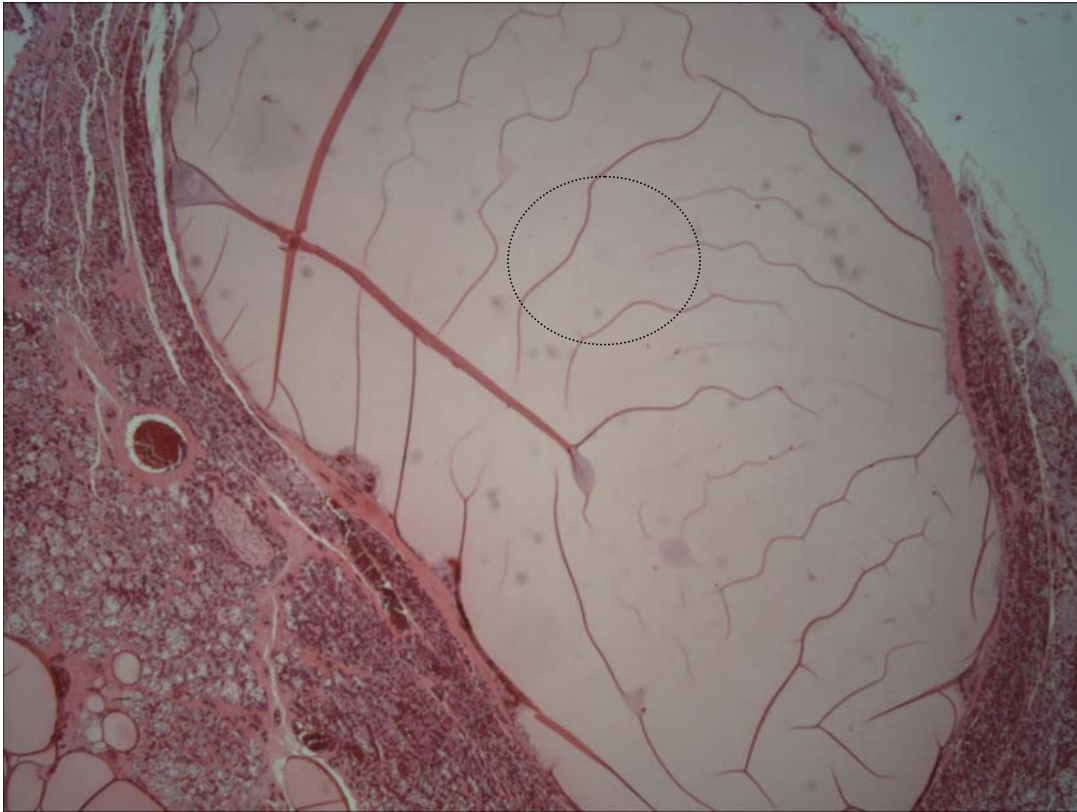


Figure 8. Thyroid gland. There is a large follicular cyst and smaller follicular cysts.

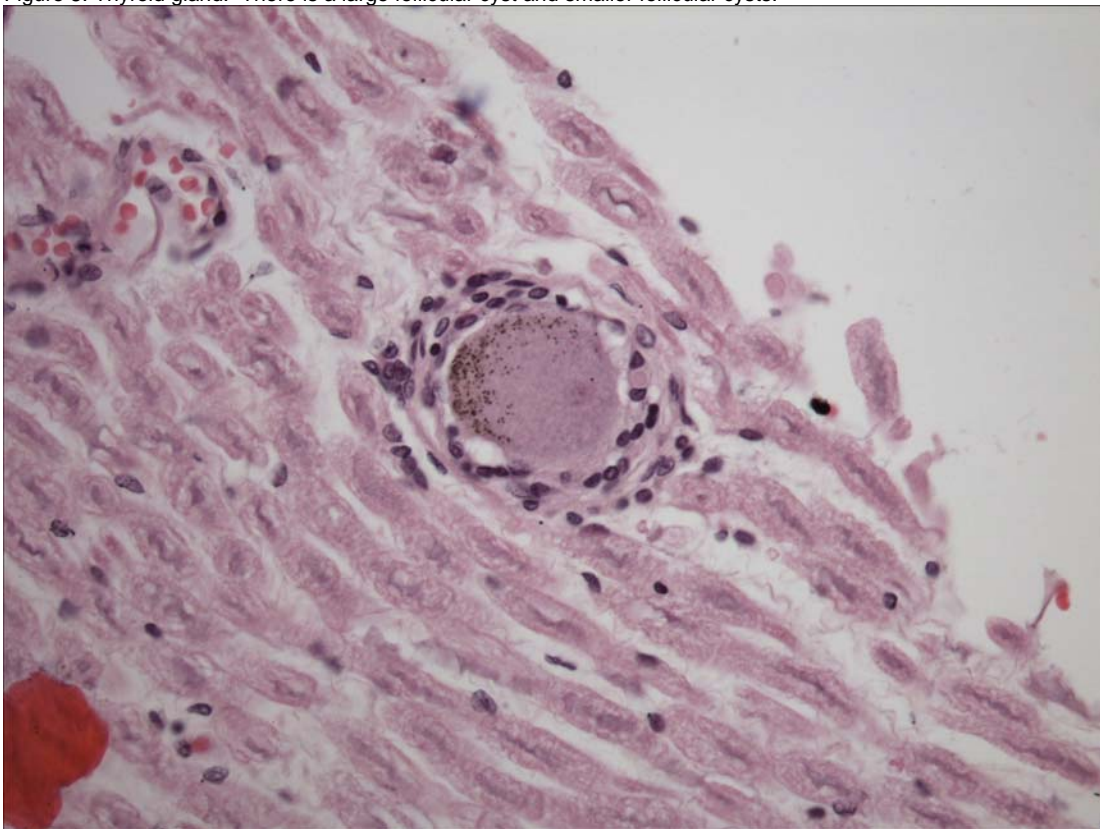


Figure 9. Spinal Root. There is degeneration of a neuron which contains increased pigment (ceroid-lipofuscin) within the perikaryon. There are few, associated lymphocytes.

PENDING			
TEST/HISTO	PURPOSE	SITE	RESULT
Fat Stain	Oil Red O	Prescapular Lymph Node	Internal perinodal adipose positive
Eye			6/17/2005: NSF.

Comments, Special Stains

17 June 2005. Perinodal adipocytes stain positively for adipose, but typically form scattered globules rather than distinct filling of adipocytes. This may represent a degree of autolysis. Similar staining is occasionally observed within the lymph node and likely represents normal adipocytes within the lymph node.

ADDENDUM: 8 Dec 2005

History: Eight heads obtained from pilot whales stranded on Bodie Island, NC were examined November 29 and 30th, 2005. Heads were collected from the beach, the site of gross necropsy of the stranded population within (3) days, transported to University of North Carolina at Wilmington and frozen. Heads were thawed for the necropsy procedure.

Sample Disposition: A necropsy data collection was utilized for the procedure to denote samples collected, gross findings, examiners, and acquisition of photos if done. The following samples were collected:

Tissue	Disposition	Comment	Analysis—Individual and Institution
Brain	½ Formalin	Histopath back-up	Rotstein, UT
	Subsamples-Cassette: Cerebrum, Cerebellum, brainstem, pons, thalamus, corpus callosum, spinal cord, pituitary gland, and any observed lesions	Histopath immediate examination	Rotstein, UT
	Freeze	Biotoxin, Viral, or other ancillary diagnostics	Stored at UNCW
	Formalin	Fat Stains	NCSU
	Weight	Body Mass Studies	Pabst/McLellan, UNCW; indicated in gross report
Mandibular (Jaw Fats)	Subsamples: External, internal, and any lesions	Histopath	Rotstein, UT
	Formalin	Fat Stains	NCSU
	In toto	Lipid Analyses	Koopman, UNCW
Ears	Formalin	Histopath	Stored at UT
Parasites	Ethyl Alcohol	ID	Flowers, NCSU
Teeth	Frozen	Age Determination	Hohn, NOAA-NMFS, Beaufort
Melon/CTs	Frozen (?)	CT	Pabst, McLellan, Harper, UNCW
	Formalin	Histopath	Rotstein, UT
Mouth Scars; Other Lesions	Formalin	Histopath	Rotstein, UT
Occipital Condyle (RT50)	Swab Tissue	Culture(swab) Brucellosis*	Rotstein, UT

*At discretion of Larry Dunn at Mystic Aquarium.

General: On 30 Nov 2005, a whole pilot whale head is examined.

Nervous System:

The pituitary gland is diffusely red-brown. There are no observable lesions. Representative sections are placed in a labeled tissue cassette and the remaining pituitary gland is placed in retained in formalin. The surface of the brain is reddened diffusely. Vessels in the ventral cerebrum and cerebellum and engorged with blood (congestion). Representative sections of brain are collected in cassettes for histopath including fat stains. The brain is bisected with one half placed in formalin and the other half frozen at -70C.

Brain Weight

Field ID	Weight (g)
RT107	2865
RT50	3569
RT68	2625
RT103	2415
RT106	2563
RT48	2826
RT59	2892
RT72	2317

Sensory System:

The left ear is collected whole. There is 9.5 ml of red tinged fluid within the left pterygoid sinus. The mucosa of the sinus is dark red and smooth. Clots are not present. Scant amounts of red-tinged fluid are present in the right pterygoid sinus; the mucosa is dark red and smooth. There is a mild infestation of metazoans within the pterygoid sinuses.

Tongue and Oral Cavity: In the oral cavity, 5.0 cm caudal to the base of the tongue on the left side, there is a raised, superficially black mass that is 2.6 X 1 X 0.3 cm in the oral mucosa. On cut surface, it is tan and homogenous. There is an additional, nodule within the right oral mucosa approximately 10.0 cm from the base of the right tongue that is 1.0 X 0.7 X 0.5 cm. It is tan and well demarcated. Representative sections are retained.

GROSS DIAGNOSES:

Nervous System:

Brain: Vascular congestion, ventral.

Sensory System:

Left Pterygoid Sinus: Intra-sinus fluid deposition.

Oral Cavity:

Lymphoid Aggregate: Lymphoid hyperplasia, multifocal (presumptive).

COMMENT-GROSS NECROPSY: Superficial vessels in the cerebrum and cerebellum are congested. This is likely post-mortem hypostatic congestion. Fluid is present within the left pterygoid sinus that is red-tinged and likely represents free blood. This may indicate antemortem hemorrhage or post-mortem vascular tearing. Clots are not observed. However, fibrin, an essential component of clot formation will breakdown over time. Thus, the absence of a clot does not aid in distinguishing ante-mortem from mortem accumulation of free blood. There are two nodules within the oral mucosa that grossly are consistent with lymphoid tissue. The enlargement may be the result of hyperplasia (reactive) or less likely neoplasia. Histopathology is pending.

MICROSCOPIC FINDINGS

Slides 13-16

Brain: Six sections are examined. There is artifactual, jagged cleaving of the neuropil (freeze artifact). Multifocal neurons exhibit expansion of the perikaryon by golden brown granules (ceroid-lipofuscin). There are occasional perivascular accumulations of dark brown-black, non-birefringent, pigment (suspect hemosiderin) (Figure 10).

Slide 17

Brain-Fat Stains: NEGATIVE

Slide 18

Pituitary Gland: At the margin of the posterior pituitary gland, there is regionally extensive loss of cells with replacement by fibrous connective tissue leaving only small islands cells within the collagenous stroma (Figure 11). Within the periglandular connective tissue, there are multifocal, well-demarcated, mineralized foci that are irregular round to oval and surrounded by cells with clear cytoplasm (macrophages) (Figure 12).

Slide 19

Left Pterygoid Sinus: There are increased plasma cells subjacent to the mucosal epithelium and extending into the collagenous stroma. There are multiple bands of fibrous connective tissue lined by endothelial cells (vascular plexus).

Slide 20

Right Pterygoid Sinus: Findings are similar to Slide 19. There is a single trematode ova within the collagenous stroma. The ova is 50 microns in diameter, pyramidal and has a 4 to 5 micron, golden shell.

Slide 21

Oral Mucosa: There is regionally extensive mucosal epithelial necrosis and sloughing. Large numbers of viable and degenerate neutrophils and fewer macrophages fill the defect and extend into underlying collagen bundles which are separated and displaced by inflammatory cells and clear spaces (edema). Collagen fibers are hypereosinophilic (collageneolysis). In the remaining intact mucosal epithelium, there are occasional epithelial cells with perinuclear clearing and chromatin margination.

Tongue: There is a focal mucosal defect with degenerate neutrophils scattered within the underlying stroma. Adjacent epithelial cells are mildly hyperplastic.

DIAGNOSES

Nervous System:

A. Brain: Perivascular hemosiderin accumulation, multifocal, mild.

Sensory System:

Pterygoid Sinus: Sinusitis, lymphoplasmacytic, diffuse, moderate with rare intralumenal trematode ova.

Digestive System:

A. Oral Cavity: Stomatitis, necro-ulcerative, regionally extensive, moderate.

B. Tongue: Glossitis, ulcerative, neutrophilic, focal, mild.

Endocrine System:

Pituitary Gland: Fibrosis, regionally extensive and periglandular fibrosis and mineralization.

COMMENT

The nodule observed in the oral cavity is a site of inflammation and necrosis. While an agent was not identified, the presence of neutrophils suggests bacterial infection. This may be a primary or secondary event. A few mucosal epithelial cells in the region adjacent to the inflammation exhibited large perivascular clearing and margination of chromatin. This could represent viral infection (e.g. herpes or papillomavirus). However, this may also be artifact (freezing). Inflammation was observed in the pterygoid sinus. Parasites were observed grossly and rarely histologically. The presence of fluid in the sinus may reflect leakage from the sinus or perhaps at the time of head removal. Perivascular hemosiderin indicates a prior, focal hemorrhage in the brain. It is not an acute lesion and there were no additional changes in the adjacent neuropil to indicate infarction at this site. Pituitary gland changes are interesting in that there is fibrosis involving the pars distalis. It is unlikely to have resulted in functional changes as the majority of the pituitary gland is unaffected. The mineral within the surrounding fibrous stroma is dystrophic rather than metastatic in cause. Based upon the oval to round shape, mineral may represent sites of parasitic migration and death.

FIGURES-ADDITIONAL

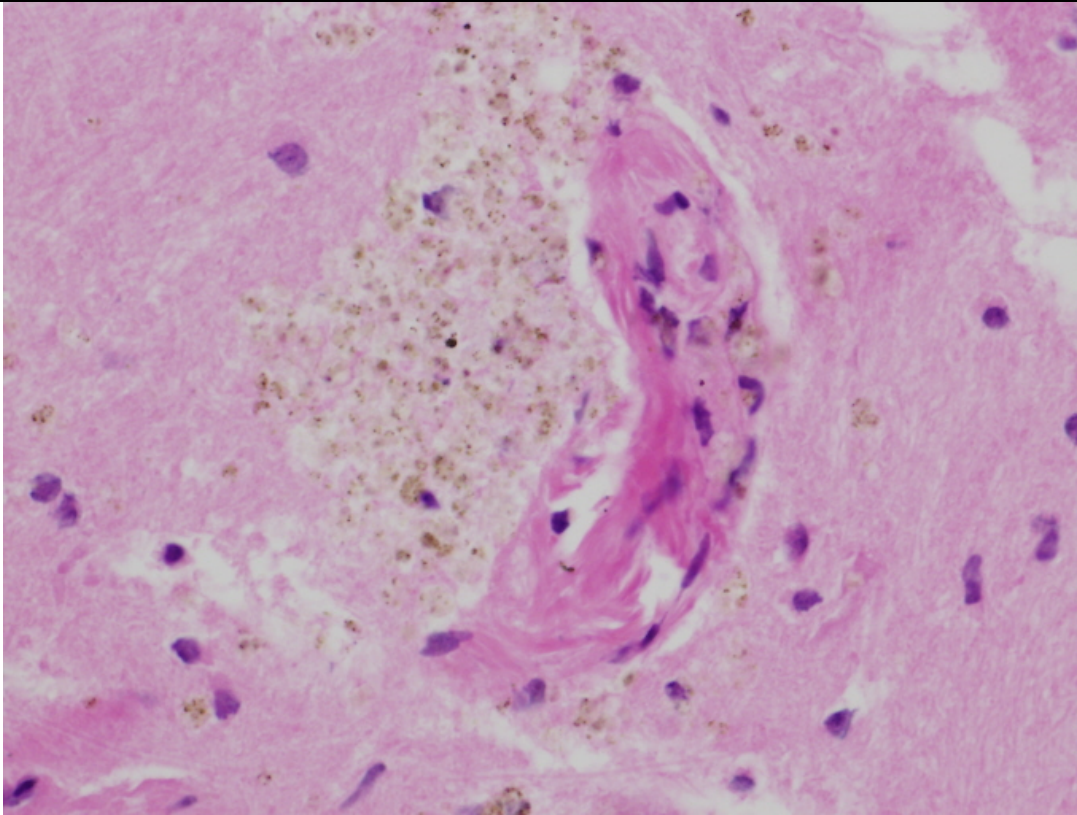


Figure 10. Brain. There is accumulation of hemosiderin around occasional vessels.

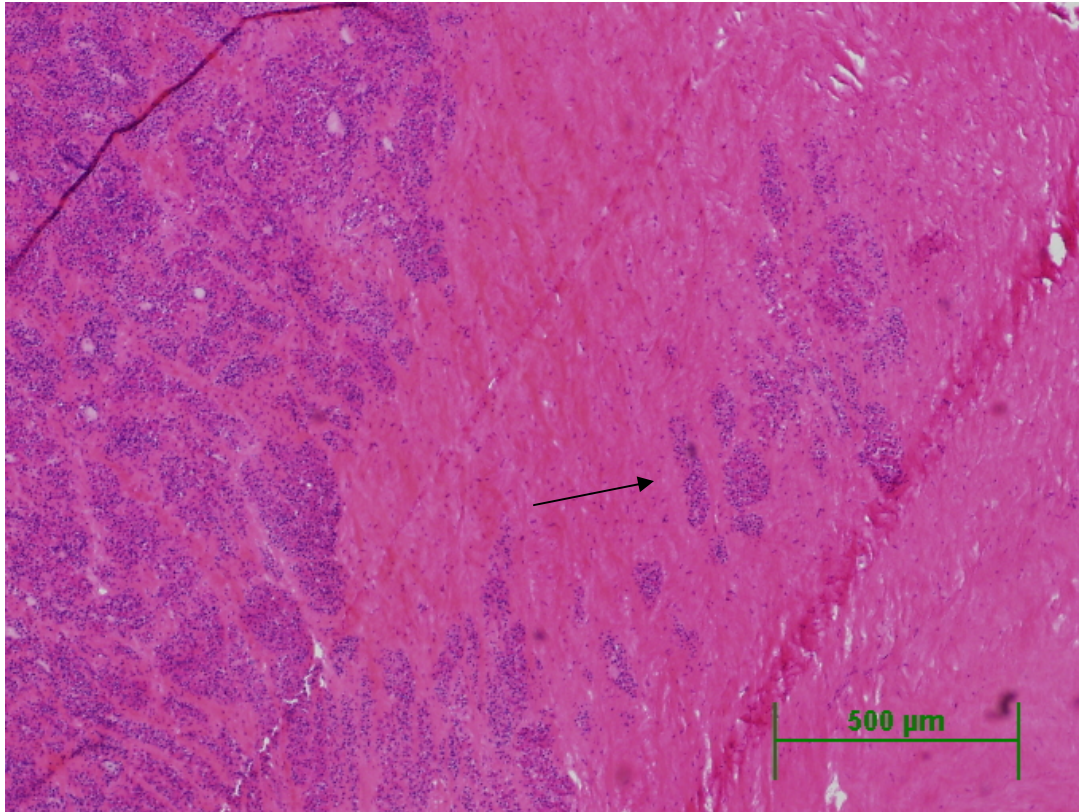


Figure 11. Pituitary Gland. There is fibrosis involving the pituitary gland. Rafts of cells are present within the fibrous stroma (arrow).

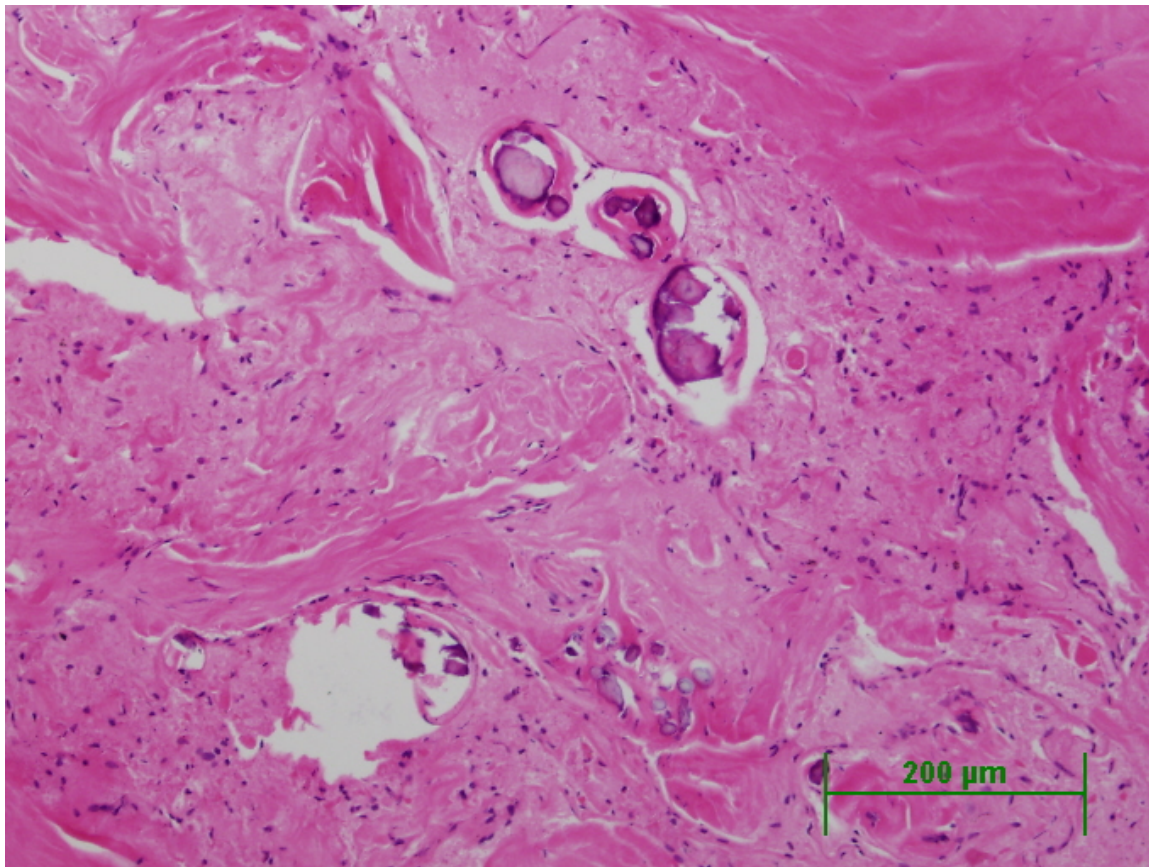


Figure 12. Pituitary Gland. Within the periglandular connective tissue, there are well defined round to oval foci of mineralization.

DATE:

15 Mar 05

17 June 2005

09 Dec 2005

REPORTING PATHOLOGIST:

David S. Rotstein, DVM, MPVM, DACVP

CETACEAN NECROPSY REPORT:
Pilot Whale Stranding, NC 15/16 Jan 2005

Field ID: RT66
 Accession Number: 05-25C
 Date: 15 Jan 2005
 Species: Globicephala macrorhynchus
 Location: Bodie Island, NC (lat-35.80728, long-75.54500)
 Sex: F
 TL: 350.0 cm (Adult)

GROSS REPORT

REPORTING INSTITUTION: NOAA Beaufort

Report adapted from necropsy notes.

History: Stranded 1/15/2005. Pregnant female.

General Examination. Dentition as follows:

Location	Number	Comment
Upper Left	7	--
Upper Right	7	--
Lower Left	7	3 rd back is cracked
Lower Right	7	--

Respiratory System. The lung is full of foam. There are multiple firm, white nodules on the surface. Red-tinged fluid in the trachea.

Cardiovascular System: Cardiac measurements are as follows:

Location	Measurement	Comment
Right Ventricular Freewall	9.0mm	--
Left Ventricular Freewall	17mm	--
Inteentricular Septum	31mm	--

Hematopoietic/Lymphoreticular System: On cut surface, the pre-scapular lymph node is edematous and hemorrhagic.

Endocrine System: The right and left adrenal glands measure 5.9 X 3.2 X 0.8 (cm) and 7.6 X 3.6cm X 0.9 (cm), respectively.

Sinus Systems: There is Stenurus in the right pterygoid sinus in low to moderate numbers and Nasitrema in low numbers.

Digestive System. The length of the intestines is 2375.0 cm. There is a light load of Monorygma in the abdominal wall.

Genitourinary System. The right and left kidneys measure 38 X 18 X 3.5 (cm) and 42 X 14 X 6 cm, respectively. Twenty ml of urine are retained. The urothelium is smooth and white. The left and right ovary measure 5.1 X 2.3 X 1.3 (cm) and 5.0 X 4.0 X 3.0 (cm). Mammary glands are poorly developed. Pregnant female with a 105.0 cm male fetus.

ANCILLARY FINDINGS

N/A

TISSUES/SAMPLES RECEIVED

REPORTING INSTITUTION: UNIVERSITY OF TENNESSEE

Received are two bags of formalin-fixed tissues labeled as "RT 66 10% Formalin". One bag is received 1 Feb 2005 and the second bag is received 2 March 2005. In the first bag, there are 17 free tissues. Representative sections of tissues are placed in Cassettes 1-6. The second bag contains 1 labeled cassette. The cassette is labeled stomach and grossly, there are multifocal, punctate ulcerations. Representative sections are placed in Cassettes 7 and 8.

MICROSCOPIC FINDINGS

REPORTING INSTITUTION: UNIVERSITY OF TENNESSEE

Blubber (slide 1): No significant histologic findings (NSF).

Urinary Bladder (slide 1): There are scattered lymphocytes and plasma cells within the submucosa.

Kidney (slide 1): NSF.

Lung (slide 1): Within an effaced bronchiole, there is a focal granuloma effacing the pulmonary parenchyma (Figure 1). The granuloma is composed of epithelioid macrophages and multinucleated giant cells surrounding a central core of eosinophilic, granular material surrounding necrotic metazoans in tangential and cross-section (Splendore-Hoeppli material) (Figure 2). There is associated granular necrotic debris. Fibroblasts and lymphocytes and plasma cells surround the granuloma. Metazoans are 80 to 100 microns in width with a 10 micron cuticle, polymyarian/coelomyarian musculature, pseduocoelom, and digestive tract lined by a single layer of irregular cuboidal epithelial cells. There is multifocal dystrophic mineralization within the granuloma and within the dense fibrous capsule. Within the remaining parenchyma, there is mild, multifocal interstitial fibrosis.

Ovary (slide 2): There are follicles in all stages of development. There are scattered corpora albicans and small foci of pigment-laden macrophages (ceroid-lipofuscin).

Skeletal Muscle (slide 2): NSF.

Trachea (slide 2): NSF.

Atrium (slide 3): NSF.

Adrenal Gland (slide 3): Multifocally, the cortex is effaced by increased fibrous connective tissue with resultant separation of cortical epithelial cells.

Lymph Node, NOS (slide 3): There is focal effacement of the lymph node by a mature granuloma with a central collagenous core surrounded by fibrous connective tissue. There are increased macrophages within the medullary spaces which are foamy or contain brown granular, intracytoplasmic pigment (hemosiderin).

Aorta (slide 4): NSF.

Ventricle (slide 4): NSF.

Lymph Node, NOS (slide 4): There is expansion of medullary spaces by clear fluid (edema) and macrophages. Macrophages have a granular eosinophilic cytoplasm or contain intracytoplasmic, brown granular pigment (hemosiderin).

Brain (slide 5): There is vacuolation of occasional neurons.

Umbilicus (slide 6): NSF.

Stomach, 1st Compartment (slides 7 and 8): There is multifocal loss of mucosal epithelium. Within the underlying submucosa, there are a few scattered neutrophils, lymphocytes, and plasma cells.

MORPHOLOGIC DIAGNOSES

Respiratory System:

Lung: Bronchiolitis and bronchiolectasis, granulomatous, focal, with intralesional nematodes.

Hematopoietic/Lymphoreticular System:

Lymph Node, NOS: Lymphadenitis, histiocytic to focally granulomatous, moderate.

Digestive System:

Stomach, 1st Compartment: Gastritis, erosive/ulcerative, multifocal, mild.

Urinary System:

Urinary Bladder: Cystitis, chronic-active, diffuse, mild.

Reproductive System:

Ovary: Folliculogenesis.

FINAL DIAGNOSES/INTERPRETATIVE SUMMARY

Verminous pneumonia

Granulomatous lymphadenitis

A cause of stranding and death was not evident. There is a verminous pneumonia, however this is localized and not diffuse. Based upon the morphology of the dead and degenerating metazoans, morphologic features are most consistent with nematodes.

Halocercus would be an example of a possible species. Speciation is difficult in histologic sections and further impeded by the degree of organism degeneration. The granuloma in the lymph node is likely a site of prior parasitic, bacterial, or even fungal infection. Evidence of an infectious agent was not found. The cystitis was mild and non-specific. There may have been a prior cystitis or, less likely given the mild inflammation, cystic calculi that resulted in urinary bladder irritation.

FIGURES

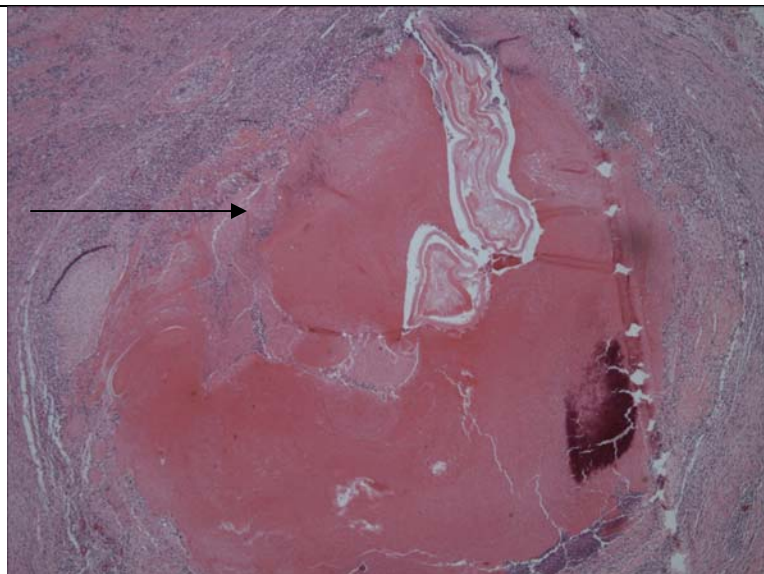


Figure 1. Lung, Bronchiole. There is complete obliteration of the bronchiole by a granuloma with nematodes within the central core (arrow).

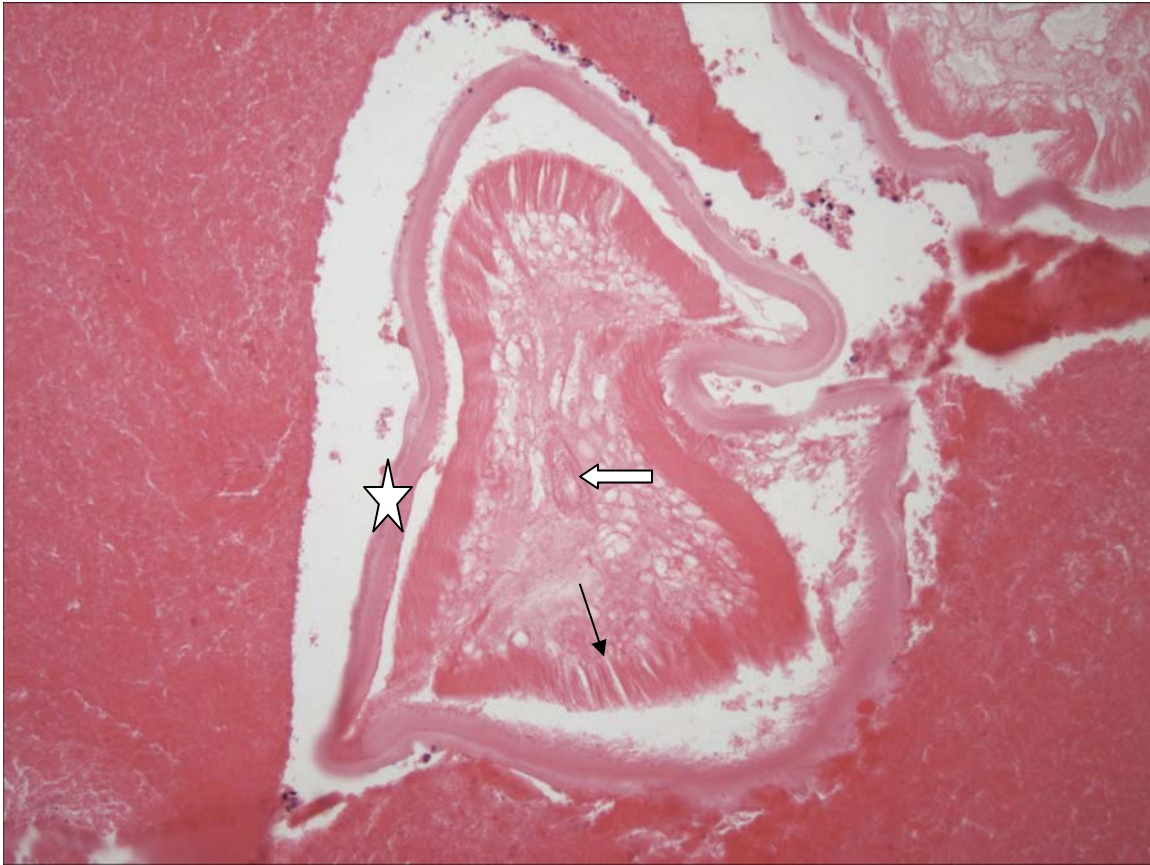


Figure 2. Lung, Granuloma. The nematode has a cuticle (star), musculature that encircles the entire pseudocoelom (polymyarian/coelomyarian) (arrow) and a digestive tract (block arrow).

PENDING			
TEST/HISTO	PURPOSE	SITE	RESULT

DATE: 8 April 2005	REPORTING PATHOLOGIST: David S. Rotstein, DVM, MPVM, DACVP
-----------------------	---

CETACEAN NECROPSY REPORT:
Pilot Whale Stranding, NC-15/16 Jan 2005

Field ID: RT67
Accession Number: 05-14C
Date: 15 Jan 2005
Species: Globicephala macrorhynchus
Location: Bodie Island, NC (lat-35.79415, long-75.53866)
Sex: F
TL: 212.0 cm (sub-adult)

GROSS REPORT
REPORTING INSTITUTION: NOAA Beaufort

Report adapted from necropsy notes and Head Necropsy data sheet.

General Examination. There is post-mortem mutilation. The dorsal fin is removed and "Boo" is carved on the inside of the abdominal cavity. The tip of the right fluke was removed. Ears removed 17 Jan 2005. Head dissected 21 Jan 2005.

Musculoskeletal System. There were 6 double ribs, 4 single ribs, and 1 floater.

Head Necropsy Data Sheet. Flensed head; examined on beach. Ears had been removed at beach. Samples of cerebrum and cerebellum were fixed. Teeth were frozen.

ANCILLARY FINDINGS

N/A

TISSUES/SAMPLES RECEIVED
REPORTING INSTITUTION: UNIVERSITY OF TENNESSEE

Received are three (3) bags of formalin labeled as "RT67 10% Formalin". Two bags are received on 1 Feb 2005 and one bag was received on 25 Jan 2005 (brain). In bag one, there are four labeled cassettes and 14 free tissues. Cassettes are labeled as "Pre-scapular Lymph Node", "Pulmonary Lymph Node", "Mesenteric Lymph Node", and "Colonic Lymph Node". Pre-scapular lymph node, pulmonary lymph node, mesenteric lymph node, and colonic lymph node sections are placed in Cassettes 1-4, respectively. Representative sections of remaining tissues are placed in Cassettes 1-8. The second bag received 1/25/2005 is labeled as brain and contains 3 sagittal sections of brain. Representative sections are placed in Cassettes 9-16. The third bag is labeled as ear is maintained in formalin pending further work-up.

MICROSCOPIC FINDINGS
REPORTING INSTITUTION: UNIVERSITY OF TENNESSEE

Pre-scapular Lymph Node (slide 1): There is moderate lymphoid hyperplasia. Macrophages are mildly increased within medullary spaces.

Liver (slide 1): There is moderate congestion.

Heart (slides 1 and 5): No significant histologic findings (NSF).

Pulmonary Lymph Node (slide 2): There is diffuse, moderate lymphoid hyperplasia.

Uterus (slides 2 and 3): The endometrium is lined by a single layer of low cuboidal epithelium. Glandular density is decreased and glands have reduced luminal diameters with an absence of cellular product.

Lung (slide 2): Multifocally, alveolar spaces contain increased numbers of foamy macrophages.

Mesenteric Lymph Node (slide 3): There is diffuse, mild lymphoid hyperplasia.

Spleen (slide 3): Periarteriolar lymphoid sheaths are adequate in number.

Colonic Lymph Node (slide 4): There is diffuse, moderate lymphoid hyperplasia.

Urinary Bladder (slide 5): NSF.

Adrenal Gland (slide 5): There are small nodules of cortical hyperplasia.

Kidney (slide 6): NSF.

Skeletal Muscle (slide 6): NSF.

Ovary (slides 7 and 8): There are numerous primary follicles at 4 to 8 per hpf, and fewer secondary and tertiary follicles.

Fimbria (slide 7): NSF.

Brain (slides 9-16): There is moderate, diffuse, congestion. In slide 16, there is accumulation of perivascular proteinaceous globules (serum and edema leakage). In some of these perivascular regions, there are macrophages with similar intracytoplasmic proteinaceous fluid.

MORPHOLOGIC DIAGNOSES

Brain: Perivascular edema, multifocal, mild.

FINAL DIAGNOSES/INTERPRETATIVE SUMMARY

The cause of stranding is not evident. There is evidence protein (edema) leakage in the brain; the presence of macrophages indicates that this process was sub-acute. Perivascular edema has been observed in many pilot whales in this stranding, but also in many uninvolved cetaceans.

FIGURES

n/a

PENDING

TEST/HISTO	PURPOSE	SITE	RESULT

DATE:
17 Mar 05

REPORTING PATHOLOGIST:
David S. Rotstein, DVM, MPVM, DACVP

**CETACEAN NECROPSY REPORT:
Pilot Whale Stranding, NC-15/16 Jan 2005**

Field ID: RT68
 Accession Number: 05-15C
 Date: 15 Jan 2005
 Species: Globicephala macrorhynchus
 Location: Bodie Island, NC (lat-35.80923, long-75.54725)
 Sex: F
 TL: 334.0 cm (Adult)

GROSS REPORT
 REPORTING INSTITUTION: NOAA Beaufort

Report adapted from necropsy notes.

General Examination. There is a 4 cm ulceration on the ventral surface of the mandible. There is a 2.0 cm single, linear rake. There is white foam and sand within the blowhole. There is sand in the vagina.

Respiratory System. There is white foam in the trachea. There is congestion of the caudal lung lobes. Yellow foam is present in terminal areas of both lungs.

Musculoskeletal System: Left scapulohumeral joint fluid is yellow and viscous.

Lymphatic: There is edema of the mesenteric lymph node which also has a green tinge.

Endocrine: Right adrenal cortices are thin and there is a ratio of 1:2:1. The left adrenal gland measures 6.5 X 4.1 X 0.8 cm. Cortices are thin and the ratio is 1:2:1.

Digestive System: There are numerous roundworms and sand within the lumen of the esophagus.

Reproductive: The uterine horn width is 3.5 cm. Monorygma are present below the left ovary.

Stomach Contents Data Sheet:

Site	Full	Empty	Contents
Esophagus	None	None	None
Forestomach	1935g	2188g	Error scale??
Main	1048g	1046g	2g
Pyloric	594g	586g	8g

Comment:

Pyloric: 1 granulated ulcer, 25 X 21mm. 2 hard nodules, non-ulcerated approximately pea-sized.

Main: light nematode load, 1 granulated ulcer: 31 X 24 mm. Four dime-sized healed ulcers.

Fore: No ulcers. Light nematode load. No content.

ANCILLARY FINDINGS

Urinalysis by C. Harms.

Test	Result
Specific Gravity	1.020
Urobilinogen	0.2
Protein	3+
pH	6.0
Blood	NEG
Ketones	NEG
Bilirubin	NEG
Glucose	NEG
Collection	N/I

TISSUES/SAMPLES RECEIVED
 REPORTING INSTITUTION: UNIVERSITY OF TENNESSEE

Received is one bag of formalin labeled as "RT68 10% Formalin". There are six labeled cassettes and 20 free tissues. Cassettes are labeled as "Pre-scapular Lymph Node", "Lung Lymph Node", "Mesenteric Lymph Node", "Mammae?", "Left Adrenal Gland", and unlabeled tissue and representative sections are placed in cassettes 1-6, respectively. Representative sections of remaining tissues are placed in Cassettes 1-11.

MICROSCOPIC FINDINGS
 REPORTING INSTITUTION: UNIVERSITY OF TENNESSEE

Pre-scapular Lymph Node (slide 1): There is moderate congestion and accumulation of eosinophilic, proteinaceous fluid (edema) within the medullary spaces. There are increased macrophages within the medullary spaces.

Aorta (slide 1): NSF.

Heart (slides 1 and 8): In the atrium (slide 8), there is multifocal fibrosis and fatty infiltration.

Right Ovary (slides 2 and 6): There are follicles in varying stages including primary, secondary, and tertiary. Rarely, there are ruptured follicles containing abundant foamy cells (early corpora lutea).

Lung Lymph Node (slide 2): There is moderate lymphoid hyperplasia. There are increased plasma cells, macrophages and hemosiderophages within medullary spaces.

Mesenteric Lymph Node (slide 3): There is moderate lymphoid hyperplasia. There are increased plasma cells and hemosiderophages within medullary spaces.

Pancreas (slide 3): NSF.

Uterus (slide 3): The endometrial lining is artifactually absent. Glandular density is reduced with glands lined by a single layer of low cuboidal epithelium and no luminal product. There are scattered lymphocytes and plasma cells within the submucosa.

Esophagus (slide 3): NSF.

Mammary Gland ("Mammae") (slide 4): Acini are lined by a single layer of cuboidal epithelium with clear cytoplasm. Luminal product is limited with approximately 30% of lumina packed with basophilic granular to mineralized material. There are scattered lymphocytes and plasma cells within the interstitium.

Lymph Node, NOS (slide 4): There is mild lymphoid hyperplasia.

Lymph Node, NOS (slide 5): There is mild lymphoid hyperplasia.

Left Adrenal Gland (slide 5): NSF.

Lung (slide 5): There is a single nematode ova within the lumen of an alveolus without an associated inflammatory reaction.

Tongue (slide 6): NSF.

Bronchi (slide 6): Lymphocytes and plasma cells are scattered throughout the mildly edematous submucosa. Bronchial-associated lymphoid tissue is mildly hyperplastic.

Lymph Node, NOS (slide 6): There is diffuse lymphoid hyperplasia.

Intestine (slide 7): There are increased plasma cells within the lamina propria.

Liver (slide 7): Multifocally, there are increased lymphocytes, plasma cells, and hemosiderophages within portal tracts. There is a single channel that is devoid of epithelium and infiltrated by viable and degenerate neutrophils (Figure 1). There is moderate fibrosis of the portal tract in which the affected channel is present. Small arteriolar sprouts are present within the fibrous stroma.

Kidney (slide 7): Near the pelvis, there is focal loss of renal tubules with associated fibrosis (Figure 2). The basement membrane of one tubule is hyalinized and there are sloughed pigmented tubular epithelial cells sloughed into the lumen. There is sclerosis of a glomerulus.

Diaphragm (slide 8): NSF.

Urinary Bladder (slide 9): There are scattered lymphocytes and plasma cells within the submucosa.

Spinal Cord (slides 10 and 11): There is multifocal swelling of myelin sheaths in the dorsal and lateral funiculi. Rarely, there are formation of spheroids (axonal degeneration) and digestion chambers with foamy macrophages with shrunken, pyknotic nuclei (Figure 3). There is fragmentation of the spinal cord sections (artifact).

MORPHOLOGIC DIAGNOSES

Cardiovascular System:

Atrium: Fibrosis and fatty infiltration, focally extensive.

Hematopoietic/Lymphoreticular System:

Pre-scapular Lymph Node: Edema and congestion, diffuse, moderate.

Nervous System:

Spinal Cord: Myelin sheath swelling and axonal degeneration, multifocal.

Hepatobiliary System:

Liver:

a. Phlebitis, leukocytoclastic (neutrophilic), focal, severe with perivascular fibrosis and vascular proliferation.

b. Periportal hepatitis, plasmacytic and lymphocytic, multifocal, mild to moderate.

Urogenital System:

1. Kidney: Fibrosis and tubular loss, focal, mild (chronic infarct).

2. Mammary Gland: Mastitis, interstitial, plasmacytic, multifocal, mild.

FINAL DIAGNOSES/INTERPRETATIVE SUMMARY

Cardiac Fibrosis
Myelin Sheath Swelling

While there is evidence of disease in several systems including nervous system, hepatobiliary system, urogenital system, and cardiovascular system, none of the lesions is severe enough or wide spread enough to have resulted in death. Myelin sheath swelling has been observed in other cetaceans and other pilot whales in this stranding and is attributed to hypoxia/ischemia.

Vascular necrosis in the single portal tract in the liver is an interesting finding. An underlying cause was not evident. This was not a wide spread finding and there was not associated thrombosis. The perivascular fibrosis and sprouting of small vessels in this region indicates chronicity. Periportal hepatitis is a non-specific finding and may be associated with bacterial infection, prior parasite migration, or ascending infection from the digestive tract. The region of fibrosis and glomerulosclerosis in the kidney is likely a site of prior infarction or prior pyelonephritis.

FIGURES

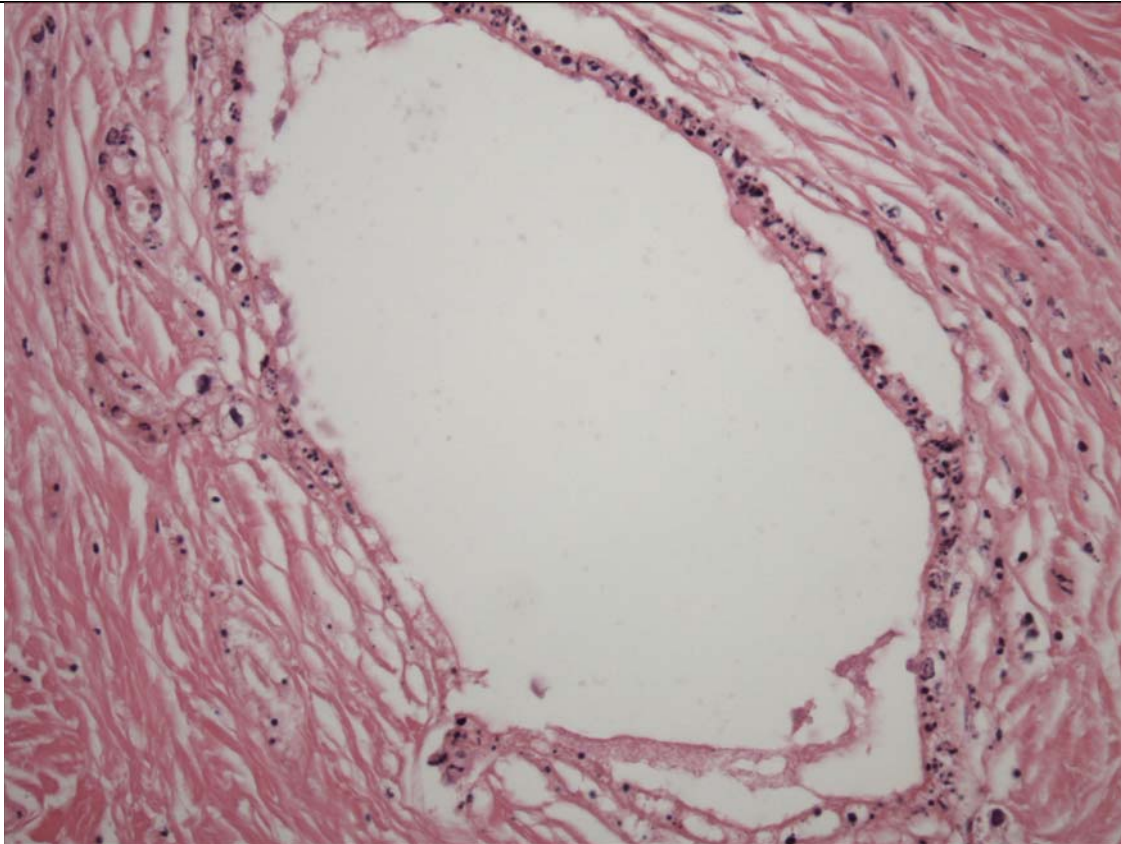


Figure 1. Liver. This vessel is infiltrated by neutrophils (leukocytoclastic vasculitis).

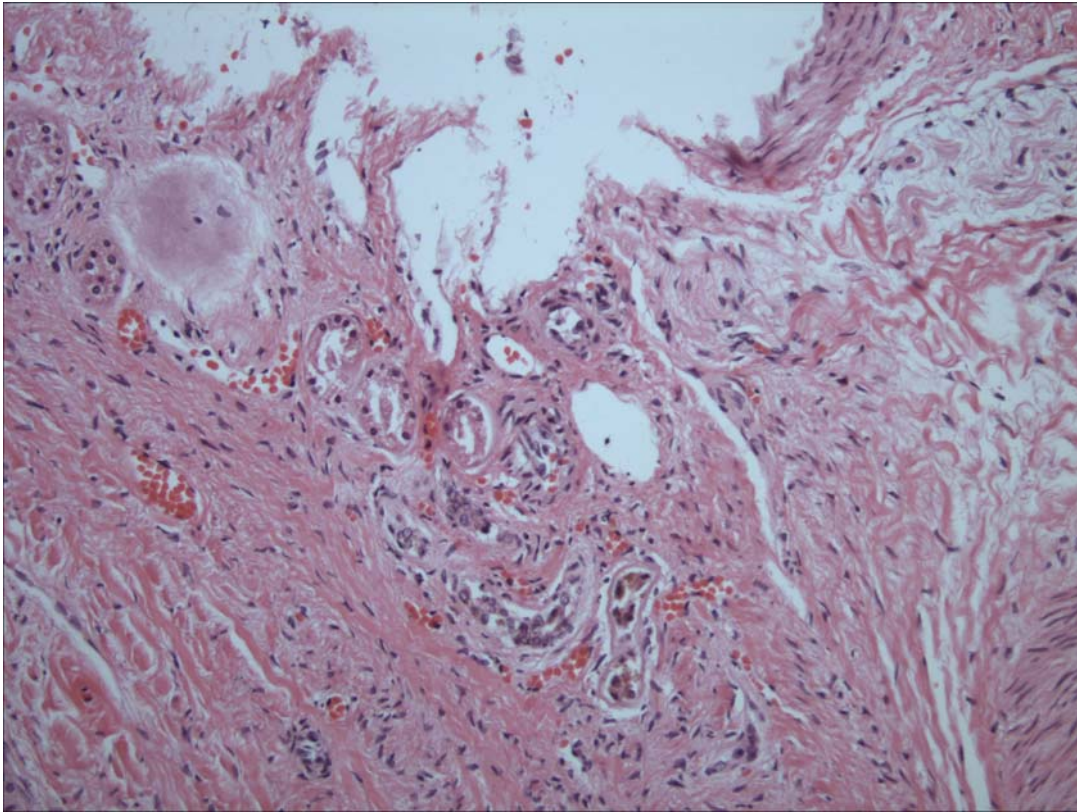


Figure 2a. Kidney. There is loss of tubules with replacement by fibrous connective tissue.

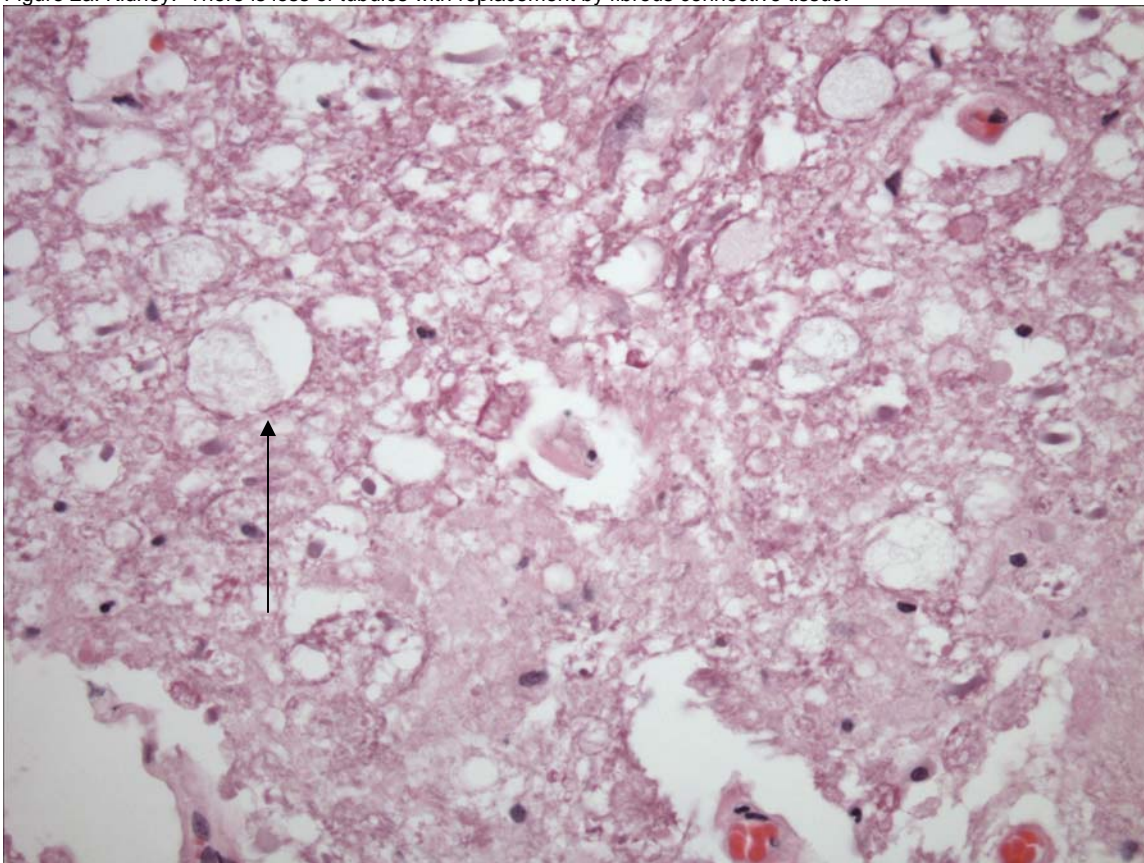


Figure 3. Spinal Cord. There is swelling of myelin sheaths and occasional axonal degeneration (arrow).

PENDING			
TEST/HISTO	PURPOSE	SITE	RESULT

ADDENDUM: 8 Dec 2005

History: Eight heads obtained from pilot whales stranded on Bodie Island, NC were examined November 29 and 30th, 2005. Heads were collected from the beach, the site of gross necropsy of the stranded population within (3) days, transported to University of North Carolina at Wilmington and frozen. Heads were thawed for the necropsy procedure.

Sample Disposition: A necropsy data collection was utilized for the procedure to denote samples collected, gross findings, examiners, and acquisition of photos if done. The following samples were collected:

Tissue	Disposition	Comment	Analysis—Individual and Institution
Brain	½ Formalin	Histopath back-up	Rotstein, UT
	Subsamples-Cassette: Cerebrum, Cerebellum, brainstem, pons, thalamus, corpus callosum, spinal cord, pituitary gland, and any observed lesions	Histopath immediate examination	Rotstein, UT
	Freeze	Biotoxin, Viral, or other ancillary diagnostics	Stored at UNCW
	Formalin	Fat Stains	NCSU
	Weight	Body Mass Studies	Pabst/McLellan, UNCW; indicated in gross report
Mandibular (Jaw Fats)	Subsamples: External, internal, and any lesions	Histopath	Rotstein, UT
	Formalin	Fat Stains	NCSU
	In toto	Lipid Analyses	Koopman, UNCW
Ears	Formalin	Histopath	Stored at UT
Parasites	Ethyl Alcohol	ID	Flowers, NCSU
Teeth	Frozen	Age Determination	Hohn, NOAA-NMFS, Beaufort
Melon/CTs	Frozen (?)	CT	Pabst, McLellan, Harper, UNCW
	Formalin	Histopath	Rotstein, UT
Mouth Scars; Other Lesions	Formalin	Histopath	Rotstein, UT
Occipital Condyle (RT50)	Swab Tissue	Culture(swab) Brucellosis*	Rotstein, UT

*At discretion of Larry Dunn at Mystic Aquarium.

General: On 30 Nov 2005, a whole pilot whale head is examined. Approximately 4 mm from the left medial canthus of the eye, there is a raised 1.0 cm, white and black speckled, dome-shaped mass. On cut section the mass is soft and tan. There are multiple squid sucker marks on the upper jaw.

Nervous System:

The pituitary gland is diffusely red-brown. There are no observable lesions. Representative sections are placed in a labeled tissue cassette and the remaining pituitary gland is placed in retained in formalin. The surface of the brain is reddened diffusely. Vessels in the ventral cerebrum and cerebellum and engorged with blood (congestion). Representative sections of brain are collected in cassettes for histopath including fat stains. The brain is bisected with one half placed in formalin and the other half frozen at -70C.

Brain Weight

Field ID	Weight (g)
RT107	2865
RT50	3569
RT68	2625
RT103	2415
RT106	2563
RT48	2826
RT59	2892
RT72	2317

Sensory System:

Mandibular fats are light yellow. Representative sections of inner and outer mandibular fats are collected. Within the left pterygoid sinus, there is 9.0 ml of red-tinged fluid. At the caudal margin, there is a 5 X 3 X 2 cm region of off-white proliferative tissue (suspect vascular plexus). Melon fat is homogenous. There are moderate metazoans in the pterygoid sinus.

GROSS DIAGNOSES:

Nervous System:

Brain: Vascular congestion, ventral.

Sensory System:

Left Pterygoid Sinus: Intra-sinus fluid deposition.

COMMENT-GROSS NECROPSY: Superficial vessels in the cerebrum and cerebellum are congested. This is likely post-mortem hypostatic congestion. Fluid is present within the left pterygoid sinus that is red-tinged and likely represents free blood. This may indicate antemortem hemorrhage or post-mortem vascular tearing. Clots are not observed. However, fibrin, an essential component of clot formation will breakdown over time. Thus, the absence of a clot does not aid in distinguishing ante-mortem from mortem accumulation of free blood.

MICROSCOPIC FINDINGS

Slide 12

Medial Canthus Mass: There is a dome shaped proliferation of hyperplastic epithelium with an underlying, poorly demarcated, nodular increase in collagen bundles with loss of adipocytes (Figure 4). There is a transition from epithelium that has thin, uniform, parallel rete pegs with abundant melanin within basal cells to irregular, broad and arborizing rete pegs with decreased melanin with basal cells (Figure 5). Within the papillary dermis of this region, there are multiple macrophages containing intracytoplasmic, black, granular pigment (pigmentary incontinence) (Figure 5). There are two to three layers of fibrocytes flanking rete pegs in the affected regions. Within the superficial epithelium, there is vacuolation of epithelial cells and large expanses of interepithelial spaces expanded by eosinophilic fluid (serum). Few lymphocytes and plasma cells are scattered within the stroma.

Slide 13

Pituitary Gland: No significant histologic findings (NSF).

Optic Nerve: NSF.

Slide 14-17

Brain: Six sections are examined. There is artifactual jagged clefting of the neuropil (freeze artifact). Approximately 65% of neurons exhibit expansion of the perikaryon by golden brown granules (ceroid-lipofuscin).

Slide 18

Brain-Fat Stains-NEGATIVE.

Slide 19

Pterygoid Sinus-Proliferative Region: No significant findings. There are numerous mixed bacterial colonies without an associated inflammatory response (post-mortem bacterial overgrowth).

External Mandibular Fat: There is mild, multifocal, perivascular leakage of serum with dissects around adjacent adipocytes.

Slide 20

Inner Mandibular Fat: There is multifocal, mild perivascular hemorrhage.

Slide 21

Mandibular Fat-Fat Stains (control)-Fat globules are observed without respect to adipocyte membranous borders (thermal-related artifact).

Slide 22

Pterygoid Sinus: There are numerous metazoans within the lumen. Parasites are 40 to 100 microns in width with a 4 to 5 micron cuticle, coelomyarian/polymyarian musculature, complete digestive tract lined by a single layer of irregular cuboidal cells, and reproductive tract containing variable numbers of larvae (nematode). There are moderate numbers of lymphocytes and plasma cells subjacent to the mucosal epithelium.

DIAGNOSES

Sensory Sytem:

Pterygoid Sinus: Sinusitis, lymphoplasmacytic, diffuse, moderate with intralesional nematodes.

Integumentary System:

Left Medial Canthus: Dermal fibrosis and epithelial hyperplasia, regionally extensive, moderate with pigmentary incontinence.

COMMENT

The nodule at the medial canthus of the left eye is a site of prior traumatic insult. The result of tissue damage was epithelial hyperplasia and pigmentary loss (incontinence). This leukoderma (whitening of the skin) is not unusual at a site of prior damage. The inciting cause was not evident. Inflammation observed in the pterygoid is not surprising given the parasitic population present.

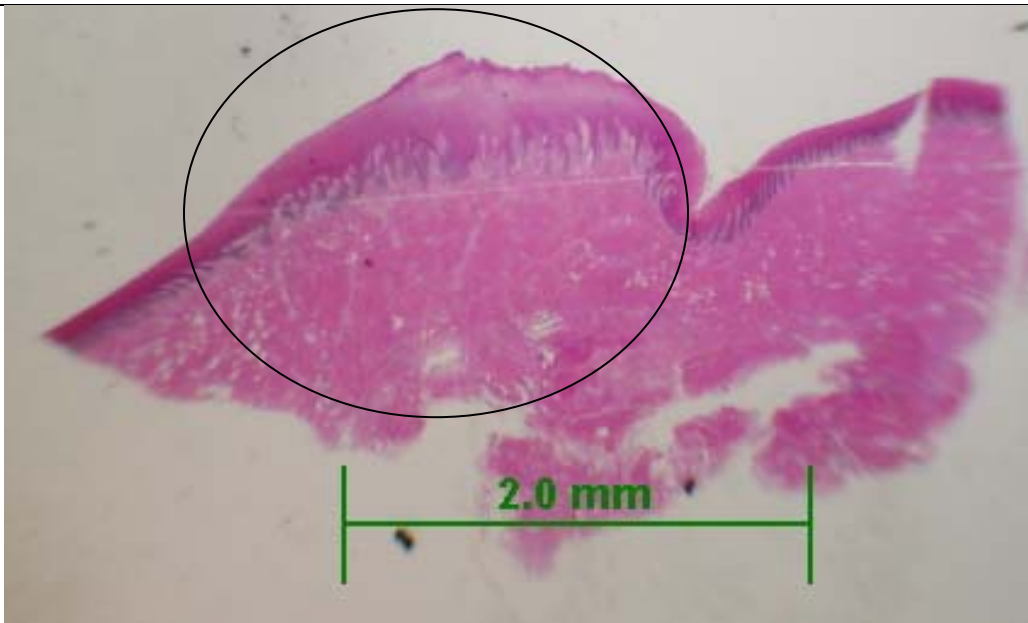


Figure 4. Medial Canthus. There is a dome-shaped, proliferative mass (circle). Epithelial hyperplasia is evident as well as the increased collagen.

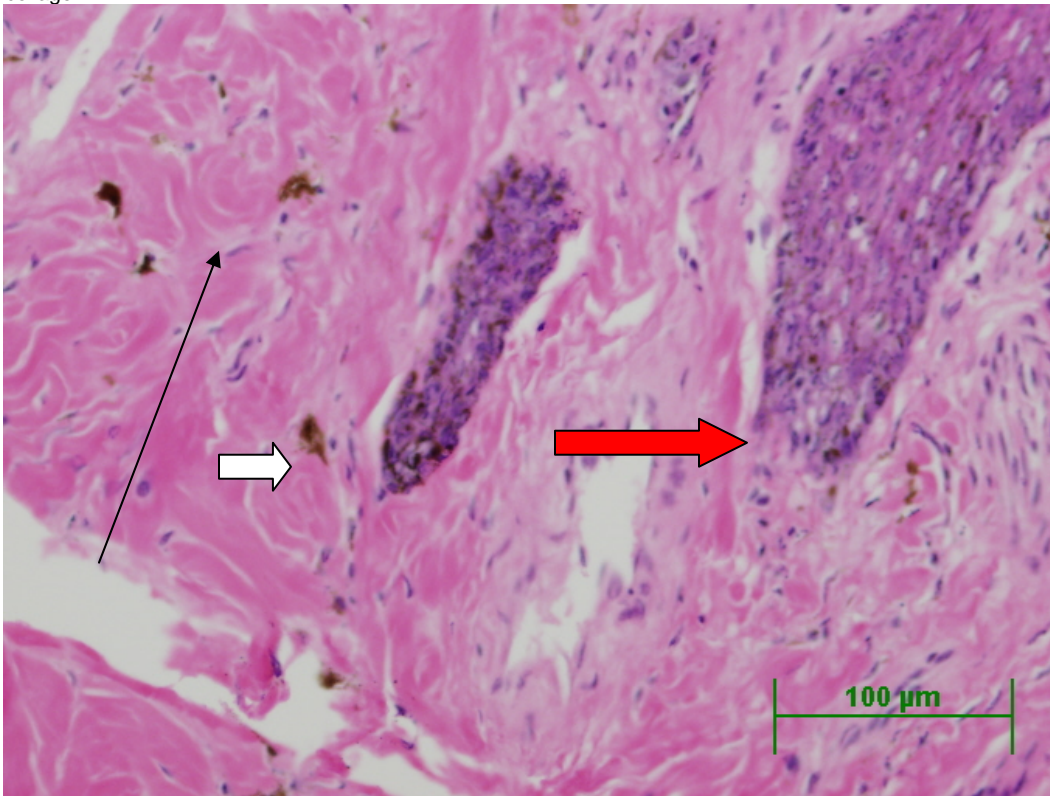


Figure 5. Medial Canthus. There is loss of pigment from basal cells (pigmentary incontinence) (arrow). Affected epithelium has decreased pigment in the basal layer (open red arrow) compared to unaffected (open white arrow).

DATE:
17 Mar 05
09 Dec05

REPORTING PATHOLOGIST:
David S. Rotstein, DVM, MPVM, DACVP

**CETACEAN NECROPSY REPORT:
Pilot Whale Stranding, NC 15/16 Jan 2005**

Field ID: RT69/NC05-023
Accession: 05-34C
Date: 15 Jan 2005
Species: Globicephala macrorhynchus
Location: Bodie Island, NC (lat-35.81, long-75.55) (est.)
Sex: F
TL: 334.0 cm

GROSS REPORT
REPORTING INSTITUTION: NOAA Beaufort

Report adapted from necropsy notes.

Healed scar on mid-right lower jaw, healed notch low on dorsal fin. Healed notch near tip of left flipper, 22 cm long healing superficial wound (not cause of death).

Reproductive. The right and left ovary measure 11.5 X 2.5 X 1.5 and 12.6 X 2.7 X 1.4 cm, respectively.

Digestive. There are nematodes in the esophagus.

Head Necropsy, 21 Jan 2005. UNCW. There is a light load of nematodes in both pterygoid sinuses. Nasal cavities are clear.

Stomach Contents Data Sheet:

Site	Full	Empty	Contents
Esophagus	541g	539g	2g
Forestomach	2190g	2165g	25g
Main	965g	925g	40g
Pyloric	2 kg	325g	Scale error?

Comment:

Pyloric: 1 ulcer in pyloric, 23 X 34 mm with granulated surface. Nematodes present (~50).

Main: 6 healed ulcers (dime size), 12 nematodes.

Esophagus: Nematodes present

Fore: Nematodes <10. No ulcers

ANCILLARY FINDINGS

N/A

TISSUES/SAMPLES RECEIVED

REPORTING INSTITUTION: UNIVERSITY OF TENNESSEE

Received is one bag of formalin labeled as "RT 69 10% Formalin" containing a whole brain. The brain weighs 2.540 kg. Representative sections are placed in Cassettes 1-10.

MICROSCOPIC FINDINGS

REPORTING INSTITUTION: UNIVERSITY OF TENNESSEE

Brain (slides 1-10): Occasional vessels have perivascular eosinophilic globular accumulations (serum) and rarely, hemosiderophages ([Figure 1](#)).

MORPHOLOGIC DIAGNOSES

Brain: Perivascular serum accumulation and rare hemosiderophages accumulation.

FINAL DIAGNOSES/INTERPRETATIVE SUMMARY

Open

The cause of stranding is not evident in the examined section of brain; however, systemic disease cannot be excluded. Of interest in this case are occasional vessels with small numbers of hemosiderophages. This is a rare finding that indicates hemorrhage and erythrocyte degradation by macrophages. This is a process that likely took several days to occur. Its significance in this case given the paucity of occurrence is not considered great.

FIGURES

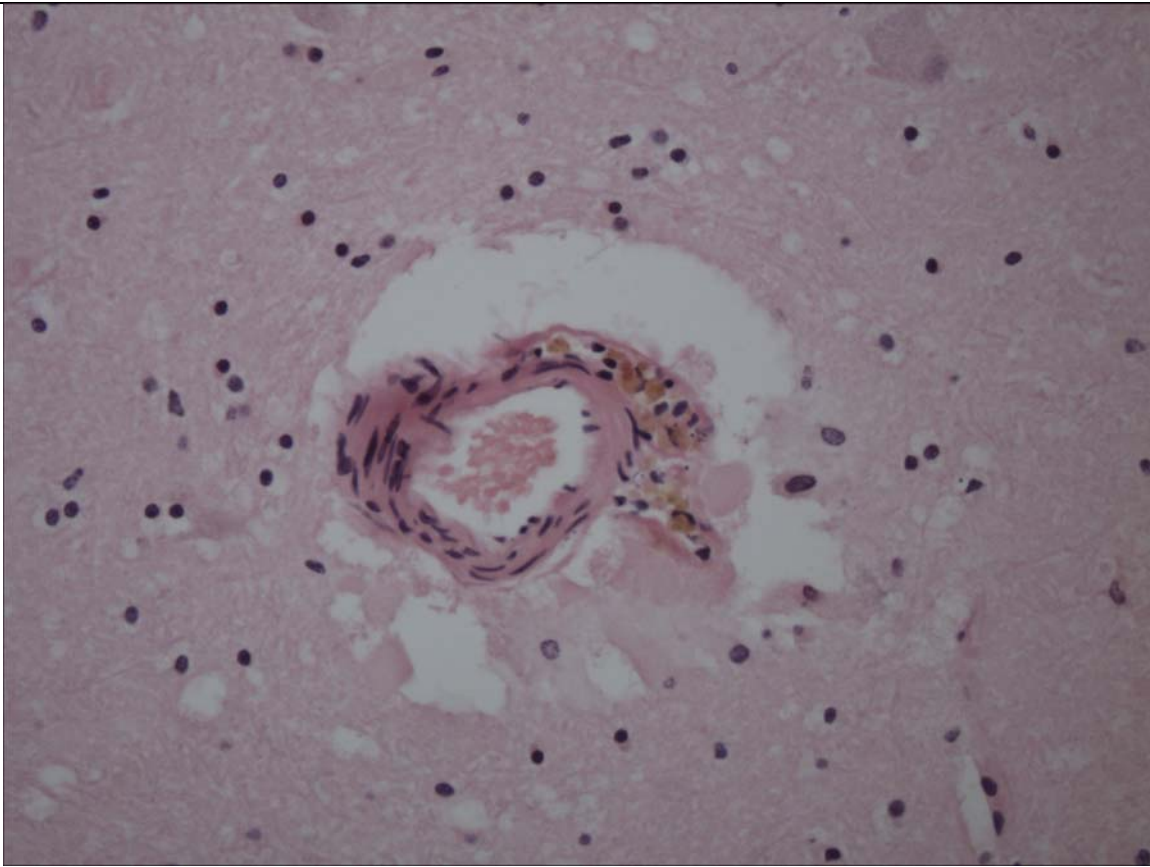


Figure 1. Brain. Virchow-Robbins space is expanded by eosinophilic globular material (serum) and a small number of hemosiderophages indicating a site of mild erythrocyte extravasation (hemorrhage) and erythrocyte senescence and degradation by macrophages.

DATE:
26 Apr 05

REPORTING PATHOLOGIST:
David S. Rotstein, DVM, MPVM, DACVP

**CETACEAN NECROPSY REPORT:
Pilot Whale Stranding, NC 15/16 Jan 2005**

Field ID: RT71/NC05-024
Accession Number: 05-32C
Date: 15 Jan 2005
Species: Globicephala macrorhynchus
Location: Bodie Island, NC (lat-35.78, long-75.53)
Sex: M
TL: 156.0 cm

GROSS REPORT
REPORTING INSTITUTION: NOAA Beaufort

Report adapted from necropsy notes.

No post-cranial histologic samples collected.

Lymphatic: Pulmonary and cardiac lymph nodes-NVL

Respiratory: Left lung is soppy and brick red; color is uniform. There are multifocal, randomly distributed nodules ranging from 3 to 18mm in diameter in the right lung. They range from yellow to pale pink.

Rib Count: 6 double and 4 single.

Reproductive: The left and right testis measure 6.8 X 1.3 x 0.6 cm and 5.6 X 1.2 X 0.9 cm, respectively.

All other organs have NVL.

Head Dissection completed 15 Feb 2005. Findings reported by C. Harms:

Additional head necropsies on five short-finned pilot whales. All part of mass stranding from 15 January 2005.. Four heads started thawing on 13 February and one small head on 14 February for necropsy today, performed at NMFS Beaufort Laboratory.

Right eye removed, left eye eviscerated (both scavenger damage). Only two teeth partially erupted. There are extensive lingual papillae (6 mm maximum length). No rostral hairs are visible but there are 6 follicles on the right (10 – 14 mm apart). The blowhole is asymmetrical. The tip of the epiglottis is congested.

Musculoskeletal and connective tissue: the right jugal bone is fractured. There is no hemorrhage in muscle ventral to tongue. The outer mandibular fat is clean, white and nonhemorrhagic bilaterally. The intramandibular acoustic fat in both fossae caudally is stained red where the fat meets the bone, associated with vascular plexus (3 x 1.5 cm on left, 4 x 2 cm on right, darker on right); hemorrhage extends onto the surface of the bone at both locations. The right and left intramandibular fat is hemorrhagic in a gradient from lateral to medial, more intense caudally.

Ears: left side external auditory meatus is missing from prior flensing. There is grey thin fluid where the left meatus meets the skull. The left peribullar sinus dorsal to periotic bone contains a pink-tan fluid. There are small petechiae surrounding the right external auditory meatus. There is mild congestion deep to auditory meatus. There is no hemorrhage in the acoustic fat adjacent to the periotic bones.

Brain: There is mild congestion on the surface of the right cerebral hemisphere, less so on left. Frontal section of dura mater is irregularly hemorrhagic (about 4 x 6 cm area). This feature was noted to a lesser degree in some of the other heads from today. NSF on cut surfaces. Brain weight 1449 g

The right pterygoid sinus epithelium is dark red, and extensively swollen medially with underlying blood. The left pterygoid sinus is lighter pink, without soft tissue swelling. There are no parasites noted in the pterygoid sinuses.

The left dorsal orbital sinus is filled with blood

Major gross findings: right pterygoid sinus medial hematoma, congested epithelium. No pterygoid sinus parasites noted.

Collected Samples

In formalin: both periotic bones, brain sections, pituitary, petechiated soft tissues surrounding right external auditory meatus, sigmoid loop of cartilage of right external auditory meatus, epiglottis, optic nerve.

3 teeth from left mandible collected.

UNC-W collected melon, inner and extramandibular fat.

Stomach Contents Data Sheet:

Site	Full	Empty	Contents
Esophagus	43g	38g	5g
Forestomach	95g	67g	28g
Main	Not obtained	Not obtained	--
Pyloric	Not obtained	Not obtained	--

Comment:

Pyloric: No ulcers, no parasites

Main: 1 nematode. Plant material. Plastic 111 X 32 mm

Esophagus: No parasite. No ulcers. Some sand.

Fore: Some sand. No ulcer. No nematodes. Plants present.

Plant ID: Duke—broad, straplike leaves→*Thalassia testudinum* (tropical)

---thin, straplike→*Zostera marina*

---all the rootlike material looks like *Filiforme syringodium*

ANCILLARY FINDINGS

N/A

TISSUES/SAMPLES RECEIVED

REPORTING INSTITUTION: UNIVERSITY OF TENNESSEE

Received is one bag of formalin labeled as "RT 71 10% Formalin". There are seven labeled cassettes, five free tissues, and both ears. Cassettes are labeled as "Cerebellum" (2), "Cerebrum" (2), "Brainstem" (2), and "Pituitary Gland". Representative sections of cerebellum are placed in Cassettes 1 and 4, cerebrum in Cassettes 2 and 3, brainstem in Cassette 5, and pituitary gland in Cassette 4. Free tissues are placed in Cassettes 5-8.

MICROSCOPIC FINDINGS

REPORTING INSTITUTION: UNIVERSITY OF TENNESSEE

Cerebellum (slides 1, 4): No significant histologic findings (NSF).

Cerebrum (slides 2-3): NSF.

Brainstem (slides 5): NSF.

Pituitary Gland (slide 4): NSF.

Acoustic Fat (slide 6): NSF.

Larynx (slide 7): NSF.

Pterygoid sinus (slide 7): There is congestion of the vascular rete.

Oral Cavity (slides 7 and 8): NSF.

MORPHOLOGIC DIAGNOSES

Brain, Pituitary Gland, Pterygoid Sinus, Acoustic Fat: No significant histologic findings.

FINAL DIAGNOSES/INTERPRETATIVE SUMMARY

Open

There is no evidence of significant changes within the brain, oral cavity, pterygoid sinus, or acoustic fats.

DATE:
26 Apr 05

REPORTING PATHOLOGIST:
David S. Rotstein, DVM, MPVM, DACVP

CETACEAN NECROPSY REPORT:
Pilot Whale Stranding, NC 15/16 Jan 2005

Field ID: RT72
 Accession Number: 05-212C
 Date: 15 Jan 2005
 Species: Globicephala macrorhynchus
 Location: Bodie Island, NC (lat-35.80923, long-75.54725)
 Sex: M
 TL: 269.0 cm

GROSS REPORT
 REPORTING INSTITUTION: NOAA Beaufort
 n/a

ANCILLARY FINDINGS
 N/A

TISSUES/SAMPLES RECEIVED
 REPORTING INSTITUTION: UNIVERSITY OF TENNESSEE

History: Eight heads obtained from pilot whales stranded on Bodie Island, NC were examined November 29 and 30th, 2005. Heads were collected from the beach, the site of gross necropsy of the stranded population within (3) days, transported to University of North Carolina at Wilmington and frozen. Heads were thawed for the necropsy procedure.

Sample Disposition: A necropsy data collection was utilized for the procedure to denote samples collected, gross findings, examiners, and acquisition of photos if done. The following samples were collected:

Tissue	Disposition	Comment	Analysis—Individual and Institution
Brain	½ Formalin	Histopath back-up	Rotstein, UT
	Subsamples-Cassette: Cerebrum, Cerebellum, brainstem, pons, thalamus, corpus callosum, spinal cord, pituitary gland, and any observed lesions	Histopath immediate examination	Rotstein, UT
	Freeze	Biotoxin, Viral, or other ancillary diagnostics	Stored at UNCW
	Formalin	Fat Stains	NCSU
	Weight	Body Mass Studies	Pabst/McLellan, UNCW; indicated in gross report
Mandibular (Jaw Fats)	Subsamples: External, internal, and any lesions	Histopath	Rotstein, UT
	Formalin	Fat Stains	NCSU
	In toto	Lipid Analyses	Koopman, UNCW
Ears	Formalin	Histopath	Stored at UT
Parasites	Ethyl Alcohol	ID	Flowers, NCSU
Teeth	Frozen	Age Determination	Hohn, NOAA-NMFS, Beaufort
Melon/CTs	Frozen (?)	CT	Pabst, McLellan, Harper, UNCW
	Formalin	Histopath	Rotstein, UT
Mouth Scars; Other Lesions	Formalin	Histopath	Rotstein, UT
Occipital Condyle (RT50)	Swab Tissue	Culture(swab) Brucellosis*	Rotstein, UT

*At discretion of Larry Dunn at Mystic Aquarium.

GROSS NECROPSY FINDINGS

General: On 30 Nov 2005, a whole pilot whale head is examined.

Nervous System:

The pituitary gland is diffusely red-brown. There are no observable lesions. Representative sections are placed in a labeled tissue cassette and the remaining pituitary gland is placed in retained in formalin. The surface of the brain is reddened diffusely and there are occasional white, miliary (less than 1mm) constellatory foci (euthanasia precipitant vs. fat autolysis) Vessels in the ventral cerebrum and cerebellum and engorged with blood (congestion). There is scant free blood in the ventricles with an aggregate amount of less than 0.15 ml. Representative sections of brain are collected in cassettes for histopath including fat stains. The brain is bisected with one half placed in formalin and the other half frozen at -70C.

Brain Weight

Field ID	Weight (g)
RT107	2865
RT50	3569
RT68	2625
RT103	2415
RT106	2563
RT48	2826
RT59	2892
RT72	2317

Sensory System:

There is mild umbilication of the cornea of the right eye which is retained whole and marked scavenging damage to the left eye which was not collected. Peri-optic nerve fat was diminished compared to other animals examined. Abundant metazoans are present in the peribullar space on the right side. The right tympanic bone is focally roughened to a degree greater than the left and in comparison to another animal (RT48). There is slight, focal, 1.1 X 0.5 cm reddening of the fat and soft tissue of the left periotic soft tissue. The intramandibular fat on the right side is tawny brown superficially. There are multifocal, while, miliary foci on cut surface (suspect fatty saponification). Caudally, on cut surface, there is a 1.3 cm laminar, dark red-brown region subjacent to the surface of the adipose that is wet and glistening. Caudal to this, there are multiple, 2 to 4 mm air-filled cavities within the adipose (suspect post-mortem putrefaction). On the left side, the external fat is creamy and glistening. The inner fat is superficially brown-red with deeply red-tinged striping caudally. On cut surface, in the avascular region, there is a 1.0 cm or reddening.

Tongue and Oral Cavity: There are no observed lesions. Representative sections are obtained.

GROSS DIAGNOSES:

Nervous System:

Brain: Vascular congestion, ventral.

Sensory System:

1. Intramandibular Fat, Avascular Region: Focal hemorrhage/vascular congestion.
2. Right Ear: Peribullar metazoans and mild roughing of tympanic bone.

COMMENT-GROSS NECROPSY: Superficial vessels in the cerebrum and cerebellum are congested. This is likely post-mortem hypostatic congestion. There is reddening of the intramandibular fat which may represent overt hemorrhage, freeze/thaw artifact, or congestion. Peribullar metazoans were observed in association with the right ear. Brain sections will be examined for any evidence of migration into the brain. The tympanic bone was roughened, but in comparison to the left ear and to another animal (RT48), was only mildly rougher than the same region on contralateral ear and comparison ear.

MICROSCOPIC FINDINGS

REPORTING INSTITUTION: UNIVERSITY OF TENNESSEE

Slides 2 and 3

Right Intramandibular Fat-Reddened Region (slide 2) and "cavities" (slide 3): In slide 2, there is multifocal perivascular erythrocyte extravasation and serum exudation. In slide 3, there is occasional separation of adipocytes forming a central clear region. In slide 3, there is a single, large caliber vessel that is 100 times as large as neighboring vessels (vascular rete).

Slide 4

Right External Mandibular Fat: No significant histologic findings (NSF).

Slide 5

Mandibular Fat-Fat Stains-Fat globules are observed without respect to adipocyte membranes (temperature related artifact).

Slide 6

Left Intramandibular Fat: There is multifocal perivascular erythrocyte extravasation and serum exudation.

Slide 7

Pituitary Gland: NSF.

Brainstem: NSF.

Slides 8-10

Brain: Five sections are examined. There is artifactual cleaving of the neuropil (freeze artifact). In one section, there is a focal infiltrate of lymphocytes and microglial cells within the neuropil and lymphocytes and plasma cells around an adjacent vessel.

Slide 11

Brain-Fat Stains: NEGATIVE.

MORPHOLOGIC DIAGNOSES

1. Right and Left Intramandibular Fat: Perivascular hemorrhage and serum exudation, mild, multifocal.

2. Brain: Encephalitis, lymphoplasmacytic, focal, moderate.

INTERPRETATIVE SUMMARY

There is evidence of perivascular hemorrhage and serum exudation. It is mild and does correspond to the grossly observed region of reddening in the intramandibular fat. There is no evidence of clots or fibrin exudation. The hemorrhage may be a perimortem or terminal event. The overall cause of the grossly observed tawny intramandibular fat is suspected to be the result of hemoglobin imbibition and its predominantly one-sided presence associated with hypostatic congestion (dependent side).

There is focal encephalitis. This was not observed throughout the brain. The cause was not evident and while this was a moderate inflammatory response, the effect upon the animal was likely not debilitating. Lymphocytic infiltrates may be observed with viral, some bacterial, protozoal, and parasitic infections.

PENDING

TEST/HISTO	PURPOSE	SITE	RESULT

DATE:
09 Dec05

REPORTING PATHOLOGIST:
David S. Rotstein, DVM, MPVM, DACVP

CETACEAN NECROPSY REPORT:
Pilot Whale Stranding, NC 15/16 Jan 2005

Field ID: RT102
Accession Number: 05-16C
Date: 15 Jan 2005
Species: Globicephala macrorhynchus
Location: Bodie Island, NC (lat-35.79410, long-75.53953)
Sex: F
TL: 387.0 cm (Adult)

GROSS REPORT

REPORTING INSTITUTION: NOAA Beaufort

Report adapted from necropsy notes and Head Necropsy Data Sheet.

Head Necropsy Data Sheet: Small amount of worms in epiglottis. Both *Stenurus* and *Nasitrema* in left (minimal) and right pterygoid (light to moderate) sinuses. Teeth collected at beach.

External Examination. There is a light load of *Diphyllobothrium* in blubber.

Hepatobiliary System. There are hard nodules in the liver.

Respiratory System. In the right lung, There is a 6 inch, tendon-like object in a duct. In the left lung, there is a white nodule on the surface of lung that extends into the cut surface.

Integumentary System. Colostrum spilling out of mammary gland.

ANCILLARY FINDINGS

N/A

TISSUES/SAMPLES RECEIVED

REPORTING INSTITUTION: UNIVERSITY OF TENNESSEE

Received is one bag of formalin labeled as "RT102 10% Formalin" containing 9 free tissues. Representative sections are placed in cassettes 1-3.

MICROSCOPIC FINDINGS

REPORTING INSTITUTION: UNIVERSITY OF TENNESSEE

Lung (slides 1 and 2): There is moderate post-mortem bacterial overgrowth and autolysis. There is regionally extensive fibrosis replacing alveoli and bronchioles (slide 1).

Clot (slide 1): There is a post-mortem clot with numerous cadaver bacilli present.

Heart (slides 1 and 3): NSF.

Lung-Associated Lymph Node (slide 2): There is mild lymphoid depletion (apoptosis vs necrosis) and increased plasma cells in medullary spaces. There is regionally extensive fibrosis with plasma cells scattered within the collagenous stroma.

Uterus (slide 3): The endometrium is artifactually absent. Endometrial glands are reduced in number and are compact with no luminal product. Glands are present singly. There are mild to moderate plasmacytic and fewer lymphocytic infiltrates within the submucosa.

Heart (slides 1 and 3): NSF.

MORPHOLOGIC DIAGNOSES

Respiratory System:

Lung: Fibrosis, regionally extensive.

Hematopoietic/Lymphoreticular System:

Lung-Associated Lymph Node: Lymphoid depletion, diffuse, mild.

FINAL DIAGNOSES/INTERPRETATIVE SUMMARY

Pulmonary fibrosis

Stress-induced lymphoid depletion

The cause of death and stranding in this case is not evident. Pulmonary fibrosis likely indicates a prior site of infection (bacterial, protozoal, fungal, etc). An inciting cause was not evident. Lymphoid depletion is likely the result of increased cortisol, associated with the stress of stranding.

FIGURES

n/a

DATE:
17 Mar 05

REPORTING PATHOLOGIST:
David S. Rotstein, DVM, MPVM, DACVP

CETACEAN NECROPSY REPORT:
Pilot Whale Stranding, NC 15/16 Jan 2005

Field ID: RT103
Accession Number: 05-17C
Date: 15 Jan 2005
Species: Globicephala macrorhynchus
Location: Bodie Island, NC (lat-35.81559, long-75.55010)
Sex: F
TL: 349.0 cm (Adult)

GROSS REPORT

REPORTING INSTITUTION: NOAA Beaufort

Report adapted from necropsy notes.

Internal Examination (Thoracic and Abdominal Cavities). Within the retroperitoneal space of the ventro-dorsal body wall, there is caseous necrosis and fibrin exudation. Within the abdominal cavity, there are three large fluctuant masses. One mass is 31 X 32 X 32 (cm) with a thick fibrous wall. The second mass is carnial to the first mass and has multiple layers separated by fibrin and edema. The third mass is caudal to the kidney. The wall is 0.5 cm and contains opaque, watery fluid. Abdominal Monorygma load is heavy.

Musculoskeletal System. The rib count is as follows-6 double, 4 single, and 1 floating.

Reproductive System. The right uterine horn is 4.5 cm.

ANCILLARY FINDINGS

N/A

TISSUES/SAMPLES RECEIVED

REPORTING INSTITUTION: UNIVERSITY OF TENNESSEE

Received is one bag of formalin labeled as "RT103 10% Formalin" containing 5 labeled cassettes and 20 free tissues. Cassettes are labeled as "Pre-scapular Lymph Node", "Lung Lymph Node", "Cardiac Lymph Node", "Mesenteric Lymph Node", and "Abdominal Abscess" and representative sections are placed in Cassettes 1-5, respectively. Representative sections of remaining tissues are placed in Cassettes 1-10 with a renal cyst placed in Cassette 6.

MICROSCOPIC FINDINGS

REPORTING INSTITUTION: UNIVERSITY OF TENNESSEE

Pre-scapular Lymph Node (slide 1): Lymphoid follicles are present. There are increased plasma cells and macrophages within medullary spaces. There are increased hemosiderophages.

Blubber (slide 1): No significant histologic findings (NSF).

Bronchus (slides 1 and 8): In slide 8, there is a mild to moderate increase in lymphocytes and plasma cells. Plasma cells extend into associated submucosal glands. There is moderate hyperplasia of bronchiolar-associated lymphoid tissues.

Liver (slide 1): There is a diffuse, mild increase in lymphocytes and plasma cells in portal tracts. There is mild, multifocal biliary hyperplasia.

Lung Lymph Node (slide 2): Lymphoid follicles are present. There are increased plasma cells and macrophages within medullary spaces. There are increased hemosiderophages.

Adrenal Gland (slide 2): NSF.

Cardiac Lymph Node (slide 3): Lymphoid follicles are present. There are increased plasma cells and macrophages within medullary spaces. There are increased hemosiderophages.

Spleen (slide 3): Segmentally, within the capsule, there is multifocal granular basophilic material (mineral) and scattered plasma cells and lymphocytes.

Heart (slide 3): NSF.

Aorta (slide 3): Multifocal small vessels have a few sprinkled lymphocytes (Figure 1).

Mesenteric Lymph Node (slide 4): There is a marked plasmacytosis and histiocytosis. Hemosiderophages are increased in number.

Lung (slide 4): NSF.

Abdominal Abscess (slides 5-7): Five sections and three fragments are examined. There is a dense proliferation of fibrous connective tissue forming a capsule surrounding large numbers of macrophages, lymphocytes, plasma cells, and neutrophils (Figure 2). Macrophages have foamy cytoplasm or contain basophilic cellular and nuclear debris. There is multifocal dystrophic mineralization and cholesterol deposition (slide 7). Scattered within the collagenous stroma are plasma cells and lymphocytes. In slide 6, collagen fibrils extend into adjacent myofibril connective tissue with resultant myofibers loss and atrophy. There are occasional degenerate myofibers characterized by granular sarcoplasm and partial to complete loss of cross-striations.

Kidney (slide 6): The peri-renal adipose, renal capsule and subcapsular spaces is expanded and infiltrated by moderate numbers of lymphocytes, plasma cells, and macrophages (Figure 3). Within the renal interstitium, there are scattered lymphocytes and plasma cells. Multifocally, there is mild to moderate thickening of Bowman's capsule. Scattered renal tubular epithelia contain intracytoplasmic golden brown pigment (hemosiderin versus ceroid-lipofuscin). There is occasional mineral within collecting duct lumina.

Skeletal Muscle (slides 6 and 8): In slide 8, there are contraction bands present within 30% of the myofibers (Figure 4). The nuclei of some affected fibers are centralized and form chains or rows.

Urinary Bladder (slide 8): NSF.

Atrium (slide 9): NSF.

Intestine (slide 9): NSF.

Spinal Cord (slide 10): Approximately 45% of neurons contain small to moderate amounts of golden, granular pigment within the perikaryon.

MORPHOLOGIC DIAGNOSES

Abdominal Cavity:

Abdomen: Granulomatous peritonitis, regionally extensive, moderate with capsule formation and adhesion to body wall.

Urinary System:

Kidney:

1. Capsulitis, lymphoplasmacytic and histiocytic, regionally extensive, moderate.
2. Nephritis, interstitial, lymphoplasmacytic, multifocal, mild.

Cardiovascular System:

Aorta: Aortitis, perivascular, lymphocytic.

Hematopoietic/Lymphoreticular System:

Lymph Node, Multiple Sites: Plasmacytosis and histiocytosis.

Musculoskeletal System:

Skeletal Muscle, NOS: Contraction band formation.

FINAL DIAGNOSES/INTERPRETATIVE SUMMARY

Abdominal Granulomas Formation, Chronic
Plasmacytosis, Lymph Node

The cause of death was not evident in this case. Grossly, granulomas were found in the abdominal cavity and near the kidney. Likely, inflammation extended into the renal capsule and subcapsular space from the granuloma. The inciting cause of the granulomas was not evident, but prior bacterial infection or a response to degrading parasites are strong considerations. Increased plasma cells within lymph nodes is likely a response to the chronic granulomata. While these abscess resulted in a peritonitis and may have contributed to a degree of debilitation in this animal, they were unlikely to have resulted in this animal's demise. There was no evidence to suggest septicemia.

Aortitis is very mild and involves small capillaries within the aorta rather than dissecting through the connective tissue. Contraction bands in skeletal muscle fibers may form as a result of artifactual contraction, however, the presence of nuclear rowing (chains) suggests that this is a myopathic change (necrosis). This may be the result of reperfusion of the muscle or increased calcium. While contraction band necrosis is described more commonly in cardiac muscle, it does occur in skeletal muscle fibers.

FIGURES

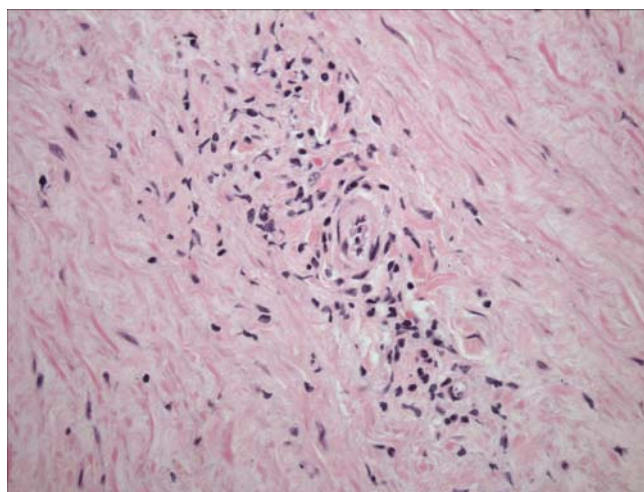


Figure 1. Aorta. Lymphocytes and plasma cells surround vascular channels, but do not infiltrate the vessel wall (i.e. vasculitis).

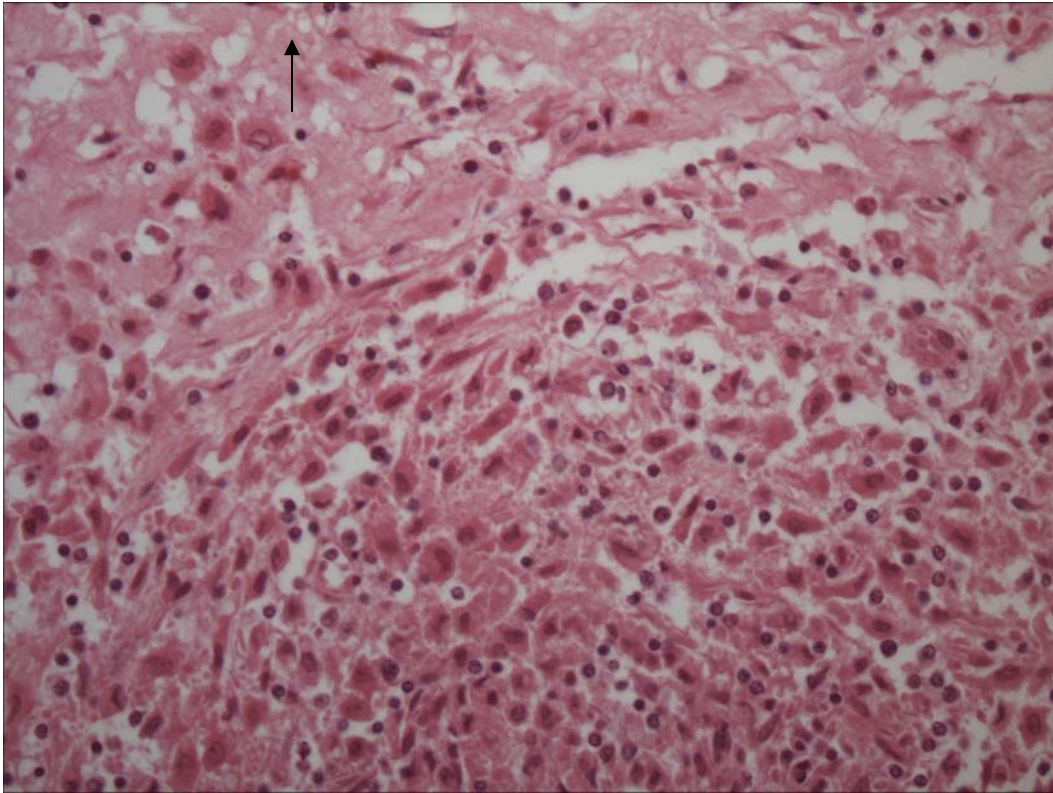


Figure 2. Abdominal Granuloma. Lymphocytes, plasma cells, and foamy macrophages comprise the central core surrounded by dense fibrous tissue (arrow).

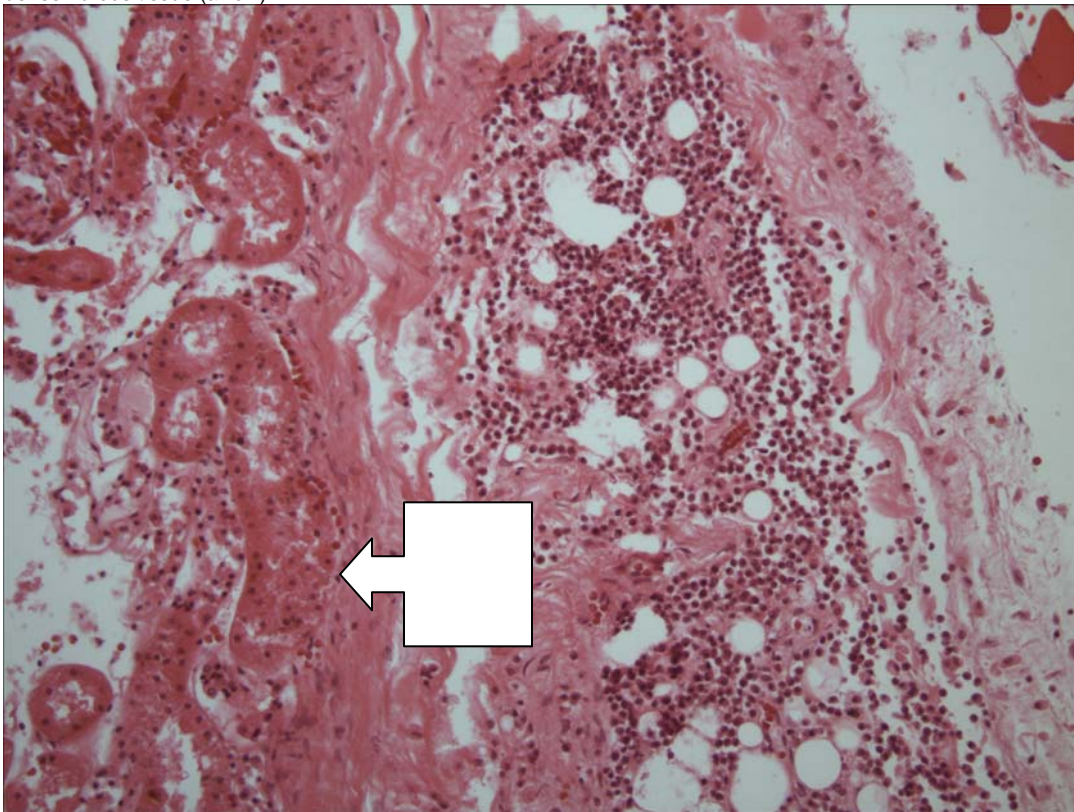


Figure 3. Kidney. The capsule, peri-renal adipose, and subcapsular spaces are expanded by lymphocytes, plasma cells, and macrophages. The kidney parenchyma is on the left (block arrow).

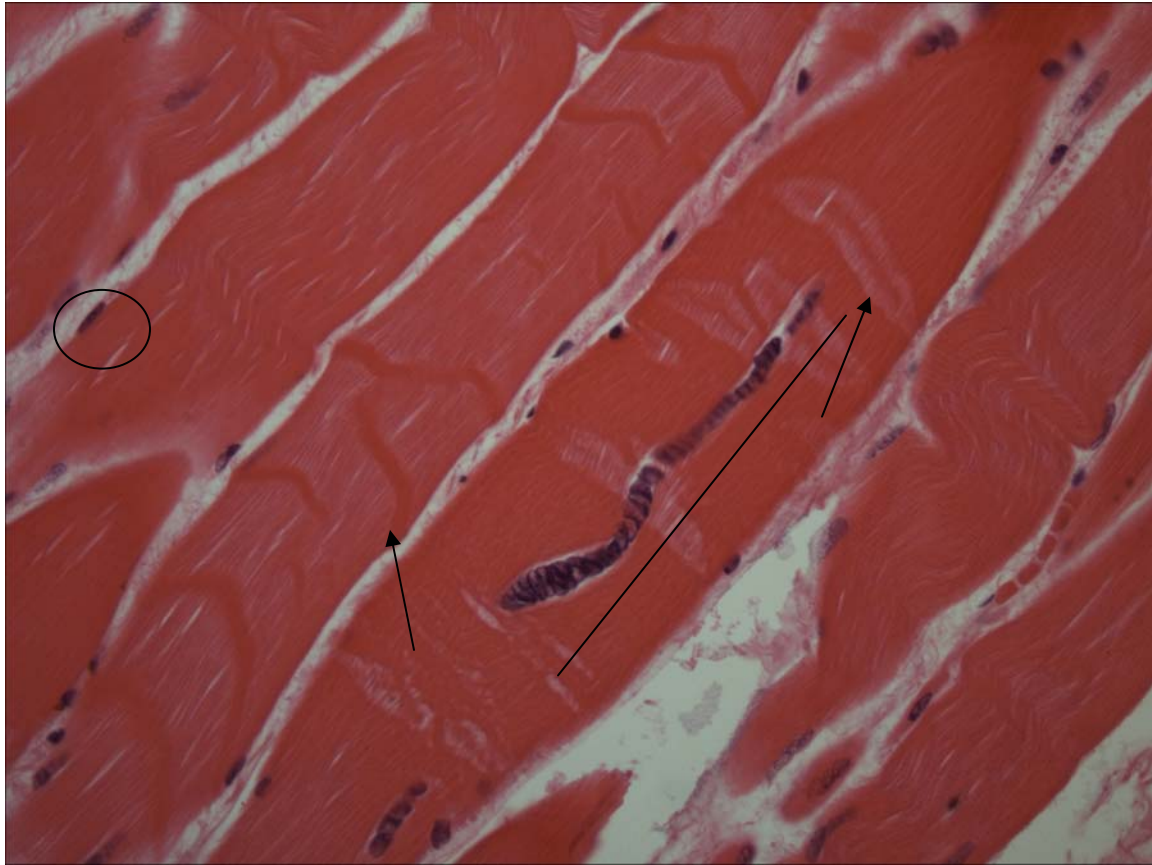


Figure 4. Skeletal Muscle. Contraction bands (arrow) are present. Myofiber nuclei which are typically peripheral (circle) are centralized and form a large chain or row in the affected fiber (line).

ADDENDUM: 14 Dec 2005

History: Eight heads obtained from pilot whales stranded on Bodie Island, NC were examined November 29 and 30th, 2005. Heads were collected from the beach, the site of gross necropsy of the stranded population within (3) days, transported to University of North Carolina at Wilmington and frozen. Heads were thawed for the necropsy procedure.

Sample Disposition: A necropsy data collection was utilized for the procedure to denote samples collected, gross findings, examiners, and acquisition of photos if done. The following samples were collected:

Tissue	Disposition	Comment	Analysis—Individual and Institution
Brain	½ Formalin	Histopath back-up	Rotstein, UT
	Subsamples-Cassette: Cerebrum, Cerebellum, brainstem, pons, thalamus, corpus callosum, spinal cord, pituitary gland, and any observed lesions	Histopath immediate examination	Rotstein, UT
	Freeze	Biotoxin, Viral, or other ancillary diagnostics	Stored at UNCW
	Formalin	Fat Stains	NCSU
	Weight	Body Mass Studies	Pabst/McLellan, UNCW; indicated in gross report
Mandibular (Jaw Fats)	Subsamples: External, internal, and any lesions	Histopath	Rotstein, UT
	Formalin	Fat Stains	NCSU
	In toto	Lipid Analyses	Koopman, UNCW
Ears	Formalin	Histopath	Stored at UT
Parasites	Ethyl Alcohol	ID	Flowers, NCSU
Teeth	Frozen	Age Determination	Hohn, NOAA-NMFS, Beaufort
Melon/CTs	Frozen (?)	CT	Pabst, McLellan, Harper, UNCW
	Formalin	Histopath	Rotstein, UT
Mouth Scars; Other Lesions	Formalin	Histopath	Rotstein, UT
Occipital Condyle (RT50)	Swab Tissue	Culture(swab) Brucellosis*	Rotstein, UT

*At discretion of Larry Dunn at Mystic Aquarium.

General: On 30 Nov 2005, a whole pilot whale head is examined. There is a healed longline scar from left upper lip and right upper lip.

Nervous System:

The pituitary gland is diffusely red-brown. There are no observable lesions. Representative sections are placed in a labeled tissue cassette and the remaining pituitary gland is placed in retained in formalin. The surface of the brain is reddened diffusely. There is a granular red material circumferentially adhered to the surface of the brain stem. There is a 2.0cm pocket of gas within an anterior, midline cerebellar vessel near the cut edge of the vessel. There is a 5 X 5 cm region of deeper reddening of the cerebrum that does not extend into the cut surface. Vessels in the ventral cerebrum and cerebellum and engorged with blood (congestion). There is approximately 2.0 cc (aggregate) of red-tinged fluid within the right and left ventricles. The surface of the ventricles is smooth and white. Representative sections of brain are collected in cassettes for histopath including fat stains. The brain is bisected with one half placed in formalin and the other half frozen at -70C.

Brain Weight

Field ID	Weight (g)
RT107	2865
RT50	3569
RT68	2625
RT103	2415
RT106	2563
RT48	2826
RT59	2892
RT72	2317

Sensory System:

There is umbilication of the left and right cornea. The eyes are placed whole in formalin. Metazoans are present within the left and right pterygoid sinuses with the right more severely affected than the left. There is a 2.0 cm linear, glistening, red, coagulum associated with, but not adhered to the left ventral tympanic bone. Mandibular fats are light yellow and in the left intramandibular fat, there are miliary, white foci (saponification). Representative sections of intra- and extramandibular fats are collected. In the perimelon blubber, there are two, well-demarcated, semi-circular, regions of fatty translucency and diminishment of collagen fibrils. These lesions are on the left and right side. On the right side, the region is 3 X 2 X 8.5 cm and approximately 5.5 cm caudal from the tip of the melon. On the left side, the region is 4 X 3 X 6.5 cm and approximately 6.5 cm from the tip of the melon.

Tongue and Oral Cavity: No observable lesions. Representative sections are obtained.

GROSS DIAGNOSES:

Nervous System:

Brain:

- 1.Vascular congestion, ventral.
- 2.Post-mortem intravascular gas bubble formation (suspect).
- 3.Lateral Ventricles: Hemorrhage, mild.

Integumentary System:

Melon, peri-melon blubber: Fat necrosis vs degradation.

COMMENT-GROSS NECROPSY: Superficial vessels in the cerebrum and cerebellum are congested. This is likely post-mortem hypostatic congestion. There is a single large bubble in a cerebellar vessel. While histologic examination for the presence of post-mortem bacteria may provide more definitive proof, these bubbles are likely the result of post-mortem bacterial gas production. Other considerations including air emboli or post-head removal introduction of gas are also considered possible causes. The well-demarcated lesions in the blubber of the melon are very interesting and may represent a site of fatty trauma or possible infarction, though the absence of observable saponification makes this less likely. Histopathologic examination of this tissue may yield additional information.

MICROSCOPIC FINDINGS

Slide 12

Tongue: No significant histologic findings (NSF).

Oral Mucosa: There are lymphocytes and plasma cells scattered within submucosal glands and rarely within the collagenous stroma.

Slide 13

Right Intramandibular Fat: NSF.

Slide 14

Right External Mandibular Fat: NSF.

Slide 15

Intramandibular Fat-Special stains for fat indicate globules without respect for membrane borders (temperature-related artifact).

Slide 16

Lining of Right Pterygoid Sinus: There is mild, mucosal epithelial hyperplasia. There is a focal coagulum of fibrin, degenerate neutrophils, and cellular debris. There is a lymph node that exhibits mild plasmacytosis and accumulations of macrophages with granular, black, intracytoplasmic pigment (anthracosis).

Slide 17

Lining of Left Pterygoid Sinus: There is mild mucosal epithelial hyperplasia. Lymphocytes and plasma cells expand the stroma and surround mucosal epithelial invaginations.

Slide 18

Left Intramandibular Fat (suspect saponified region): There are occasional, miliary foci of adipocytes that are smudgy and eosinophilic (post-mortem autolysis).

Slide 19

Pituitary Gland: Two sections are examined. No significant histologic findings.

Slides 20-22, 25

Brain: Twelve sections are examined. There is diffuse clefting of the neuropil (freeze artifact). There is mild to moderate autolysis. There is a sprinkling of lymphocytes and plasma cells around vessels. Rare, basophilic, irregular round structures (corpora amylacea) are present.

Slides 23, 24

Brain: Fat Stains: NEGATIVE.

Slide 26

Right Side-Fibrous Blubber (Melon): There is a tinctorial change from brightly eosinophilic, globally, birefringent collagen fibers to lightly eosinophilic, segmentally birefringent collagen fibrils. Nuclei in affected region are shrunken and pyknotic. There are occasional build-up of irregular basophilic debris within a collagen fibril (dystrophic mineralization). Adipocyte margins are less discrete in the affected regions.

Slide 27

Left Side-Fibrous Blubber Lesions (Melon): Findings are similar to Slide 26.

DIAGNOSES

Nervous System:

A. Brain: Perivascular cuffing, non-suppurative, minimal, multifocal.

Sensory System:

Pterygoid Sinus, Left: Sinusitis, lymphoplasmacytic, diffuse, moderate.

Integumentary System:

Blubber (peri-melon): Collagen necrosis with rare dystrophic mineralization.

COMMENT

The most interesting histologic finding was that of the firm lesions within the blubber surrounding the melon. In this region, there is collagen necrosis characterized by pyknotic nuclei and dystrophic mineralization of collagen fibers. Adipocytes in this region are less distinct, but there is no evidence of actual adipocyte necrosis. In addition vessels were present with no evidence of vasculitis or thrombosis. The exact cause is not evident, but given the lack of inflammation, pressure necrosis or possibly, but less likely hypoxia could have occurred. The focal nature of these two regions is interesting as these were not nearby regions. The lesions would suggest two points of contact resulting in localized pressure necrosis. While prior fishery interaction (lines) described involving the lips, it is possible that there may have been involvement of the perimelon region resulting in the random changes observed. Inflammation in the brain was very mild and non-specific. It is likely the result of a prior viral or bacterial exposure and is unlikely to be related to the abdominal granulomas.

DATE: 29 Mar 05 14 Dec 05	REPORTING PATHOLOGIST: David S. Rotstein, DVM, MPVM, DACVP
---------------------------------	---

CETACEAN NECROPSY REPORT:
Pilot Whale Stranding, NC 15/16 Jan 2005

Field ID: RT104
 Accession Number: 05-18C
 Date: 15 Jan 2005
 Species: Globicephala macrorhynchus
 Location: Bodie Island, NC (lat-35.84026, long-75.56089)
 Sex: F
 TL: 267.0 cm (Sub-Adult)

GROSS REPORT
 REPORTING INSTITUTION: NOAA Beaufort

Report adapted from necropsy notes. (Not a complete transcription)

General Examination. The number eleven (#11) is carved into the side of the body).

Musculoskeletal System. The rib count on the right side is 6 double, 4 single, and 1 floater.

Cardiovascular System. There is extensive pericardial adipose.

Hematopoietic/Lymphoreticular System. On cut surface, the mesenteric lymph node is yellow-brown.

Head Dissection completed 15 Feb 2005. Findings reported by C. Harms:

Head necropsies on 2 dwarf sperm whales and two short-finned pilot whales. All part of mass stranding from 15 (pilot whales) and 16 (Kogia) January 2005. The Kogia heads were frozen within half a day of stranding; the pilot whale heads were frozen the evening of the day after the stranding (Sunday). These animals were selected based on quick transfer of the heads to freezer at time of stranding, and relatively small size (pilot whales, possibly more prone to acoustic trauma). All 4 heads were imaged by CT at the NCSU College of Veterinary Medicine on 31 January (Kogia) and 1 February (pilot whales) while still frozen (stored in walk-in freezer overnight). They were then thawed for necropsy starting on 1 February. The necropsies were performed at NMFS Beaufort Laboratory 3 February. At the time of necropsies the Kogia heads were fully thawed and the pilot whale heads were still cold internally.

Both eyes are intact. The right side external auditory meatus distal half is missing due to decapitation location. There are two lymph nodes noted ventral to the base of the tongue, 1.5 - 2.0 cm diameter, pink with white mottling.

There is sand in the pharynx along with a couple of small nematodes. There is sand in the blowhole and nasal sinuses, particularly on the left side. Tip of goosebeak (arytenoids and epiglottis) is bruised.

Subcutis: no hemorrhage in fat external to mandible or in melon.

The intramandibular fat is free of hemorrhage except for a 3 x 1 cm area at the dorso-caudo-lateral margin bilaterally adjacent to the mandible, with corresponding adjacent endosteal hemorrhage, and a small fresh fissure in the mandible on the left.

Ears: External auditory meatus left and remaining portion of right, NSF. There is thin dark-brown fluid in the veins adjacent to the hyomastoid joint and behind the periotic bones, particularly on the left, and there are nematodes caudal to the right periotic bone. There is no hemorrhage in acoustic fat adjacent to ears.

Brain: There is subdural hemorrhage, and congestion in the pia mater and gyri. The cerebellar vermis has a gelatinous appearance in the grey matter on cut surface.

Brain weight 2314 g

Pterygoid sinuses: there is a moderately heavy load of nematodes in both pterygoid sinuses, heavier load in right, extending into the lumen in spider-web-like projection supported by ice crystals. There is also a light load of autolyzed trematodes on both sides. There is soft tissue swelling in both pterygoid sinuses medially and caudally, particularly medially in right sinus.

Collected Samples:

In formalin: both periotic bones, sections of brain.

Additional teeth collected.

ANCILLARY FINDINGS

Urinalysis by C. Harms.

Test	Result
Specific Gravity	1.031
Urobilinogen	0.2
Protein	NEG
pH	6.0
Blood	NEG
Ketones	NEG
Bilirubin	NEG
Glucose	NEG
Collection	N/I

TISSUES/SAMPLES RECEIVED

REPORTING INSTITUTION: UNIVERSITY OF TENNESSEE

Received is two bags of formalin labeled as "RT104 10% Formalin". One bag is received 1 Feb 2005 and the second bag is received 2 March 2005. In the first bag, there are five labeled cassettes and 20 free tissues. Cassettes are labeled as "Pre-scapular Lymph Node", "Lung Lymph Node", "Pericardial Lymph Node", "Mesenteric Lymph Node", and "Colonic Lymph Node"; representative sections are placed in cassettes 1-5, respectively. Representative sections of remaining tissues are placed in Cassettes 1-8. The second bag contains six labeled cassettes and 2 intact ears. Cassettes are labeled as cerebrum (2), cerebellum (2), and brainstem (2). Representative sections of cerebrum, cerebellum, and brainstem are placed in Cassettes 9, 10 (cerebrum; 11, 12 (cerebellum); 13, 14 (brainstem)).

MICROSCOPIC FINDINGS

REPORTING INSTITUTION: UNIVERSITY OF TENNESSEE

Pre-scapular Lymph Node (slide 1): There is regionally expansion of the cortex and medulla by sheets of round cells (Figure 1). Cells have scant to moderate cytoplasm and round to oval nuclei with stippled chromatin (Figure 2). There are scattered apoptotic/necrotic cells with condensed nuclei and deeply eosinophilic cytoplasm. There are increased macrophages within the cortex ("starry sky") and sinuses.

Spleen (slide 1): Peri-arteriolar lymphoid sheaths are hyperplastic.

Heart (slide 1): No significant histologic findings (NSF).

Large Intestine (slide 1): NSF.

Lung Lymph Node (slide 2): There is a mild increase in plasma cells within medullary cords. Medullary sinuses contain increased macrophages. Cortex and medulla are distinct.

Atrium (slide 2): NSF.

Bronchus (slides 2 and 7): There is a mild increase in submucosal plasma cells which extend into submucosal glands. In slide 7, there is marked hyperplasia of BALT.

Adrenal Gland (slide 2): NSF.

Skeletal Muscle (slides 3 and 7): In slide 3, there is multifocal expansion of the sarcoplasm by basophilic 3 to 5 micron irregular round to oval structures (mineral) (Figure 3).

Pericardial Lymph Node (slide 3): There is a mild increase in plasma cells within medullary cords. Medullary sinuses contain moderate numbers of macrophages. Cortex and medulla are distinct.

Mesenteric Lymph Node (slide 4): Unable to be processed.

Blubber (slide 4): NSF.

Colonic Lymph Node (slide 5): There is lymphoid follicular hyperplasia. There are increased hemosiderophages.

Lung (slide 5): Alveolar lumina are filled with small numbers of foamy macrophages (pulmonary edema).

Liver (slide 5): There is diffuse, mild to moderate sinusoidal congestion.

Small Intestine (slide 6): NSF.

Urinary Bladder (slide 6): NSF.

Aorta (slide 6): NSF.

Mammary Gland (slide 6): Nearly all ducts contain small numbers of foamy macrophages and eosinophilic globular material. Acini are collapsed. Small numbers of plasma cells and lymphocytes are sprinkled within the interstitium.

Kidney (slide 7): NSF.

Uterus (slide 7): The endometrium is lined by a single layer of cuboidal epithelial cells. Glandular density is moderately reduced. Glands are present singly and occasionally nested with glands straight to slightly coiled. There are scattered lymphocytes and plasma cells within the submucosa.

Cerebrum (slides 9 and 10): NSF.

Cerebellum (slides 11 and 12): NSF.

Brainstem (slides 13 and 14): NSF.

MORPHOLOGIC DIAGNOSES

Hematopoietic/Lymphoreticular System:

Pre-scapular Lymph Node: Pseudo-lymphomatous lymphoproliferation. (Markedly hyperplastic lymph node).

Respiratory System:

Lung: Pulmonary edema, multifocal, mild.

Musculoskeletal System:

Skeletal Muscle: Mineralization, multifocal, mild.

Reproductive System:

1. Uterus: Non-estrus uterus. (cyclical involution).

2. Mammary Gland: Inactive lactogenesis.

FINAL DIAGNOSES/INTERPRETATIVE SUMMARY

The cause of death in this pilot whale remains open. There is evidence of pulmonary edema which was likely peri-mortem. Findings in the reproductive system indicate an animal that was not pregnant, not in estrus, and did not have an existing calf. Skeletal muscle mineralization indicates sites of muscle damage which could include oxidation injury or prior myositis. Inflammation however, is limited in these mineralized regions.

The most interesting finding, albeit not one that contributed to this animal's demise, was in the pre-scapular lymph node. There is a marked hyperplasia of the lymph node resulting in large numbers of T-cells (CD3 positive). Lymphoma was also considered with unilateral involvement suggestive of Hodgkin's like lymphoma as reported in cats.¹ However, immunohistochemical stains for B-cells (CD79) and T-cells (CD3) indicate a normal follicular structure, albeit with a florid T-cell response. The cause of this response was not identified.

References:

1. Walton and Hendrick. 2001. Vet Pathol 38: 504-511.

FIGURES

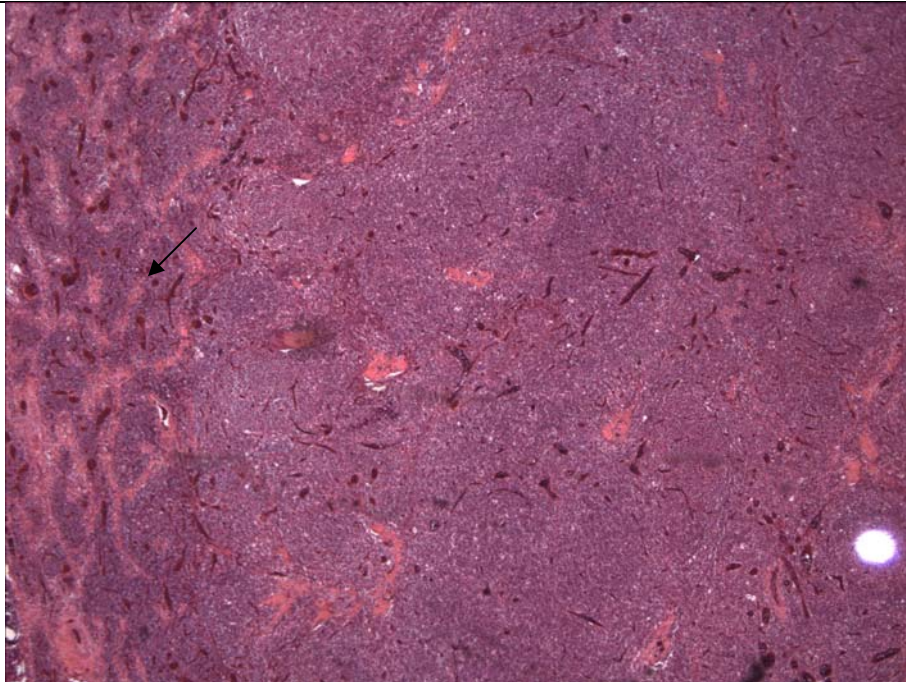


Figure 1. Pre-scapular lymph node. There is a loss of follicular architectures. Medullary cords (arrow) are packed with cells.

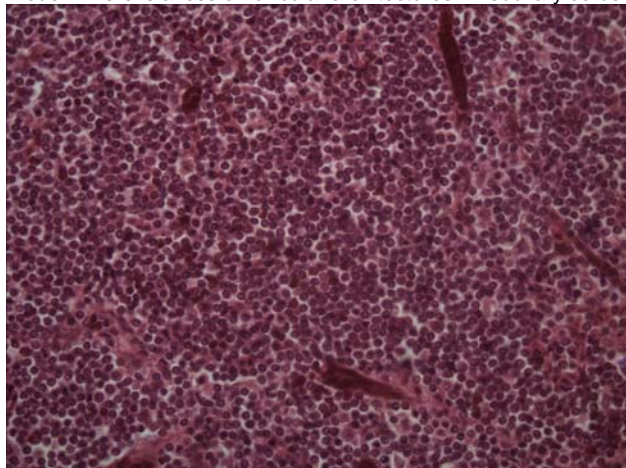


Figure 2. Pre-scapular Lymph Node. There are sheets of small to medium sized round cells.

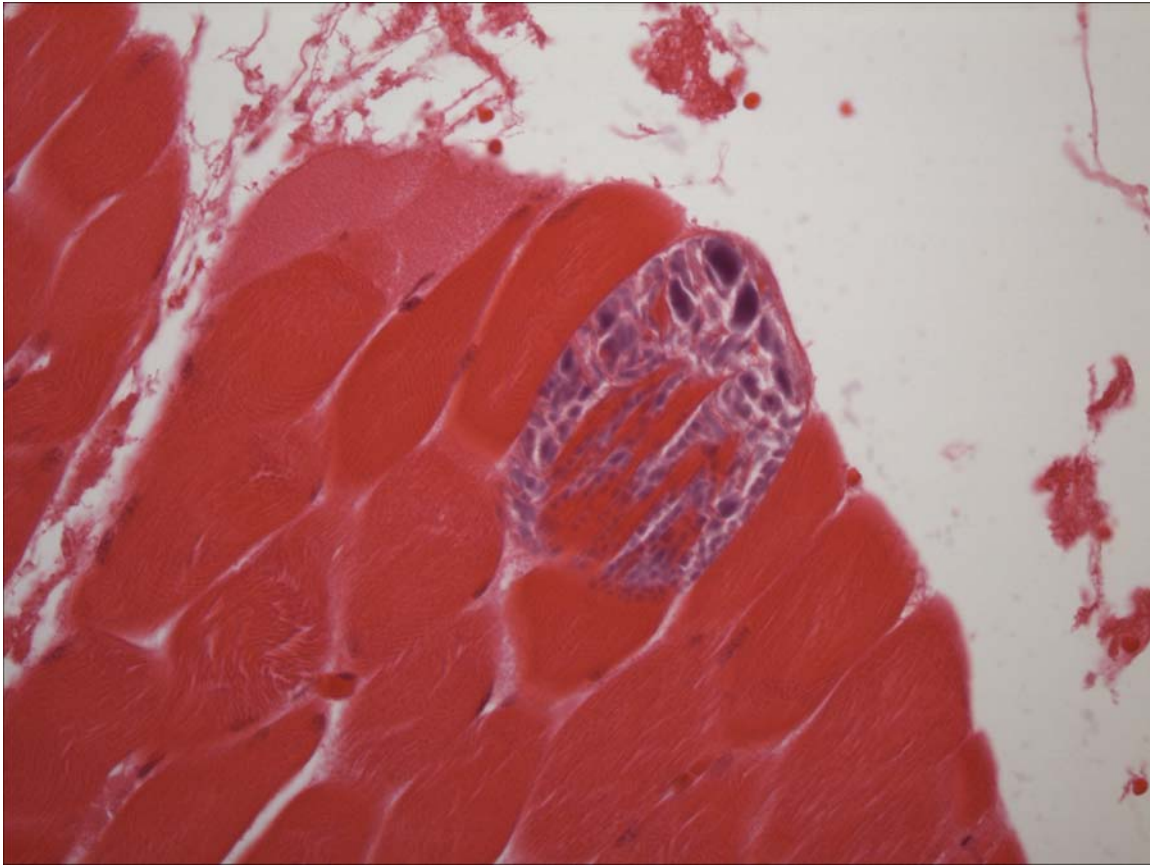


Figure 3. Skeletal Muscle. There is myofibers loss and mineralization.

PENDING			
TEST/HISTO	PURPOSE	SITE	RESULT
Pre-scapular Lymph Node- CD3 and CD79	Lymphosarcoma confirmation	UT	See Comment

DATE: 30 Mar 05	REPORTING PATHOLOGIST: David S. Rotstein, DVM, MPVM, DACVP
--------------------	---

**CETACEAN NECROPSY REPORT:
Pilot Whale Stranding, NC 15/16 Jan 2005**

Field ID: RT 105
Date: 15 Jan 2005
Species: Globicephala macrorhynchus
Location: Bodie Island, NC (lat-35.84026, long-75.56089)
Sex: F
TL: 375.0 cm (Adult)

GROSS REPORT
REPORTING INSTITUTION: NOAA Beaufort

Report adapted from necropsy notes.

External Examination. There are healed FI (fishery interactions) marked including a healed scar on the left and right upper lip and healed scar on left mandible. Remark: Healed FI marks-not cause of death. There is healing of subdermal fat layer (*NB: site not specified*).

Musculoskeletal System. On the right side, there are six double ribs and four single ribs.

Cardiovascular System. The heart is flaccid. There is abundant pericardial and interventricular adipose.

Respiratory System. There are occasional calcified structures and a few worms in the lung.

Hematopoietic/Lymphoreticular Systems. The lung lymph node is dark black. The pancreatic lymph node is mottled black and tan. The right prescapular lymph node is red to green. The spleen is multi-lobed.

Digestive System. There is a 5 X 5 X 5 (cm) round, fluid filled structure associated with the gastric mesentery. The structure is filled with a beige, cheesy substance.

Hepatobiliary System. The liver is dark purplish-gray and has firm margins.

Reproductive System. There is a heavy Monorygma infestation. Corpora albicans scars on present on both ovaries. The left ovary is notched. The diameter of the left and right uterine horns is 4.0 cm.

Head Dissection completed 15 Feb 2005. Findings reported by C. Harms:

Additional head necropsies on five short-finned pilot whales. All part of mass stranding from 15 January 2005.. Four heads started thawing on 13 February and one small head on 14 February for necropsy today, performed at NMFS Beaufort Laboratory.

Right eye is eviscerated (scavenger damage), left eye is intact. There is sand in the blowhole and esophagus.

Teeth are severely worn. In right mandible, 1, 4 5 and 7 are missing (not extracted during necropsy) and 2, 3 and 6 are severely worn. In left mandible, 1, 2, 3, 6 and 7 are missing and 4 and 5 have the rostral halves worn away. Maxillary teeth are in better condition, although 7th on both sides is worn down to the gum line. Maxillary teeth collected for aging because of poor condition of mandibular teeth.

Subcutis: there is no bruising noted.

Musculoskeletal and connective tissue: left occipital condyle is dark pink, right is mottled pink. No significant findings on cut surface of melon. There appears to be increased vascularity the the left extramandibular fat underlying a scar, but the remaining mandibular fat is unaffected. There is mild hemorrhage in the acoustic fat of the caudal mandibular fossa associated with vascular plexus, bilateral, and also staining the adjacent bone. There is a vascular pattern to the cut surface of the intramandibular fat, with an avascular exterior (the outer 4 mm); caudally on the left side the interior is dark red, while on the right side it retains its vascular pattern at same level.

Ears: Left side external auditory meatus unremarkable, on the right side there was thin watery grey fluid around the base near skull. There is not hemorrhage in acoustic fat adjacent to periotic bones. There are several trematodes dorsal to the periotic bone. There are nematodes dorsal to left periotic bone, and some mild congestion, but autolyzed.

Brain: There is moderate congestion of the cerebrum bilaterally.

Brain weight 2740 g

The left pterygoid sinus has mild to moderate load of nematodes and trematodes, and a medial hematoma. The right pterygoid sinus has a mild load of nematodes, a few more trematodes than on left, and a medial hematoma 4 cm across.

The tip of the arytenoids and epiglottis are bruised.

Major gross findings: parasitic sinusitis.

Collected Samples:

In formalin: both periotic bones, epiglottis, sections of brain.

UNC-W collected melon.

ANCILLARY FINDINGS

Urinalysis by C. Harms.

Test	Result
Specific Gravity	1.023
Urobilinogen	0.2
Protein	3+
pH	6.5
Blood	LARGE
Ketones	SMALL (15mmol/L)
Bilirubin	NEG
Glucose	NEG
Collection	N/I

TISSUES/SAMPLES RECEIVED

REPORTING INSTITUTION: UNIVERSITY OF TENNESSEE

Received are four bags of formalin labeled as "RT105 10% Formalin". Two bags are received 1 Feb 2005 and two bags are received 2 March 2005. In the first bag, there are five labeled cassettes and 17 free tissues. Cassettes are labeled as "Pre-scapular Lymph Node", "Pancreatic Lymph Node", "Lung Lymph Node", "Mesenteric Lymph Node", and "Colonic Lymph Node"; representative sections are placed in cassettes 1-5, respectively. Representative sections of remaining tissues are placed in Cassettes 1-10. The second bag has an additional label as "Cyst" and contains portions of the grossly described mesenteric structure. Representative sections are placed in Cassette 10. The third bag contains seven labeled cassettes, 1 "C-shaped" structure, and 2 intact ears. Cassettes are labeled as cerebrum (2), cerebellum (2), brainstem (2), and pituitary (2). Representative sections of the "C-shaped" structure, cerebrum, cerebellum, and brainstem are placed in Cassettes 9A (structure); 10A, 11 (cerebrum); 12, 13 (cerebellum); 14 (brainstem); brainstem (15). The fourth bag contains a cassette labeled as "Stomach" which is placed in Cassette 16.

MICROSCOPIC FINDINGS

REPORTING INSTITUTION: UNIVERSITY OF TENNESSEE

Pre-scapular Lymph Node (slide 1): Lymphocytes are in good numbers. There is moderate plasmacytosis and histiocytosis. There are increased hemosiderophages.

Spleen (slide 1): Lymphocyte numbers are adequate in the periarteriolar sheaths.

Pancreatic Lymph Node (slide 2): Not sectionable.

Kidney (slide 2): No significant histologic findings.

Bronchus (slide 2): There are increased submucosal plasma cells. There are small, multifocal, loosely-arranged aggregates of macrophages containing intracytoplasmic granular black pigment (anthracosis) and birefringent structures (silicosis).

Aorta (slide 2): NSF.

Urinary System (slide 3): NSF.

Blubber (slide 3): NSF.

Lung Lymph Node (slide 3): Lymphoid follicles are adequate in lymphocyte numbers. There are increased plasma cells in the medullary cords. Within the medullary sinus, there are increased macrophages laden with either granular black pigment (anthracosis) and birefringent structures (silicosis) or golden-brown pigment (hemosiderin) ([Figure 1](#)).

Mesenteric Lymph Node (slide 4): There are increased plasma cells and eosinophils.

Lung (slide 4): Approximately 30% of alveolar lumina contain few foamy macrophages and granular eosinophilic material.

Liver (slide 4): One portal tract exhibits moderate periportal fibrosis and a focal, aggregated infiltrate of lymphocytes, plasma cells, and macrophages. Approximately 80% of hepatocytes contain small amounts of intracytoplasmic, granular, golden-brown pigment (hemosiderin vs ceroid-lipofuscin). Multifocally, there are periportal aggregates of hemosiderin-laden macrophages. Kupffer cells contain small amounts of iron.

Colonic Lymph Node (slide 5): There are increased plasma cells in medullary cords and occasionally within the capsule. There are increased hemosiderophages.

Heart (slide 5): NSF.

Small Intestine (slide 6): There are increased plasma cells and eosinophils within the lamina propria.

Atrium (slide 7): There is focal fibrosis and replacement of cardiomyocytes.

Adrenal Gland (slide 7): NSF.

Mammary Gland (slide 7): Ducts contain small numbers of foamy macrophages and granular debris. Acini have diminished lumina or contain inspissated eosinophilic material with or without attenuation of the lining epithelium. There is multifocal loss of acini with replacement by fibrous connective tissue. There are increased lymphocytes and plasma cells within the interstitium.

Skeletal Muscle (slide 8): There is occasional, perivascular infiltrates of lymphocytes and macrophages (Figure 2).

Uterus (slide 8): The endometrium is lined by a single layer of low cuboidal epithelial cells. Glandular density is moderate reduced. Glands are present singly, predominantly and have collapsed lumina or contain small amounts of eosinophilic, proteinaceous substance. There are increased lymphocytes and plasma cells within the lamina propria. There is medial hypertrophy of arteries and occasional media exhibit medial degeneration.

Spinal Cord (slide 9): Approximately 60% of neurons contain moderate amounts of perikaryonal golden-brown pigment (ceroid-lipofuscin).

Oral Cavity (slide 9A): NSF.

Cyst (slide 10): There are abundant collagen bundles with interspersed lymphocytes, plasma cells, and macrophages (Figure 3). There are multiple foci of accumulated round to granular basophilic material (dystrophic mineralization).

Cerebrum (slides 10A and 11): In slide 11, there is a focal, mild infiltrate of lymphocytes within the meninges and superficially, within the subjacent neuropil.

Cerebellum (slides 12 and 13): NSF.

Brainstem (slides 14): NSF.

Pituitary (slide 15): NSF.

Stomach (slide 16): There is autolysis of the mucosal epithelium. Focally, there is ulceration of the mucosal epithelium. Moderate numbers of plasma cells, lymphocytes, fewer eosinophils and macrophages extend from the submucosa into the tunica muscularis, and tunica serosa.

MORPHOLOGIC DIAGNOSES

Digestive System:

Stomach: Gastritis, ulcerative, lymphoplasmacytic, transmural, diffuse, moderate.

Abdominal Cavity, PeriGastric Mesentery: Peritonitis, granulomatous with fibrosis and dystrophic mineralization.

Reproductive System:

1.Uterus: Endometritis, lymphoplasmacytic, diffuse, moderate with glandular atrophy, and vascular medial degeneration (vasculopathy).

2.Mammary Gland:

a.Mastitis, lymphoplasmacytic, multifocal, mild to moderate.

b.Inactive lactogenesis.

Nervous System:

Brain: Meningoencephalitis, non-suppurative, focal, mild.

Musculoskeletal System:

Muscle: Interstitial myositis, lymphohistiocytic and perivascular, multifocal, mild.

Hepatobiliary System:

Liver: Periportal hepatitis, lymphocytic, focal, moderate with periportal fibrosis.

Respiratory System:

1.Lung: Pulmonary edema, multifocal, mild.

2.Bronchus: Anthracosis.

Lymphoreticular/Hematopoietic system:

Lung lymph node: Anthracosis, multifocal, mild.

FINAL DIAGNOSES/INTERPRETATIVE SUMMARY

Endometritis

Gastritis

Anthracosis

Abdominal Abscess, Chronic.

The cause of this animal's demise is not evident. There was a large abscess near the stomach was described grossly, which histologically is composed primarily of fibrous connective tissue and scattered mononuclear (lymphocytes and plasma cells) cells. This mass is fairly quiescent and unlikely to have resulted in significant compromise to this cetacean. This may have been a site of prior parasitism where the dying parasite led to an inflammatory response. Other causes would include intrabdominal foreign material, bacterial, or fungal infection. Evidence of a causative agent was not observed. Inflammation within the stomach was transmural (mucosa to serosa) and chronic; this may reflect spread of inflammation from the peri-gastric mass. If the peri-gastric mass was the result of foreign material, then it is possible it was from the stomach and had penetrated through the wall.

Similar to the peri-gastric mass, inflammation in the liver, mammary gland, and uterus were unlikely to have significant effects upon this cetacean. Anthracosis is the result of inhaled anthropogenic-produced carbon particles. The response was mild. The cause of the interstitial myositis was not evident. Meningoencephalitis was very mild and focal and unlikely to have resulted in significant clinical disease.

FIGURES

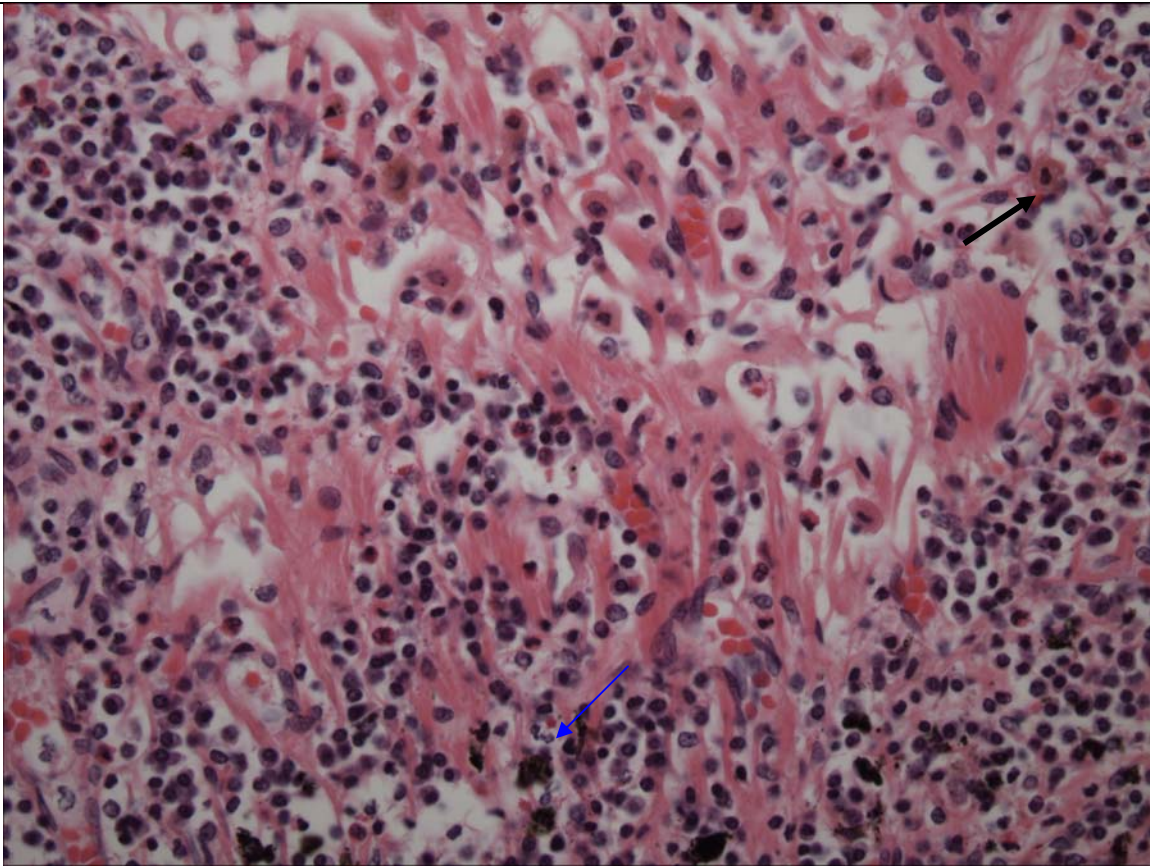


Figure 1. Lymph Node. Hemosiderin is present within some macrophages (black arrow) and carbon pigment within other macrophages (blue arrow).

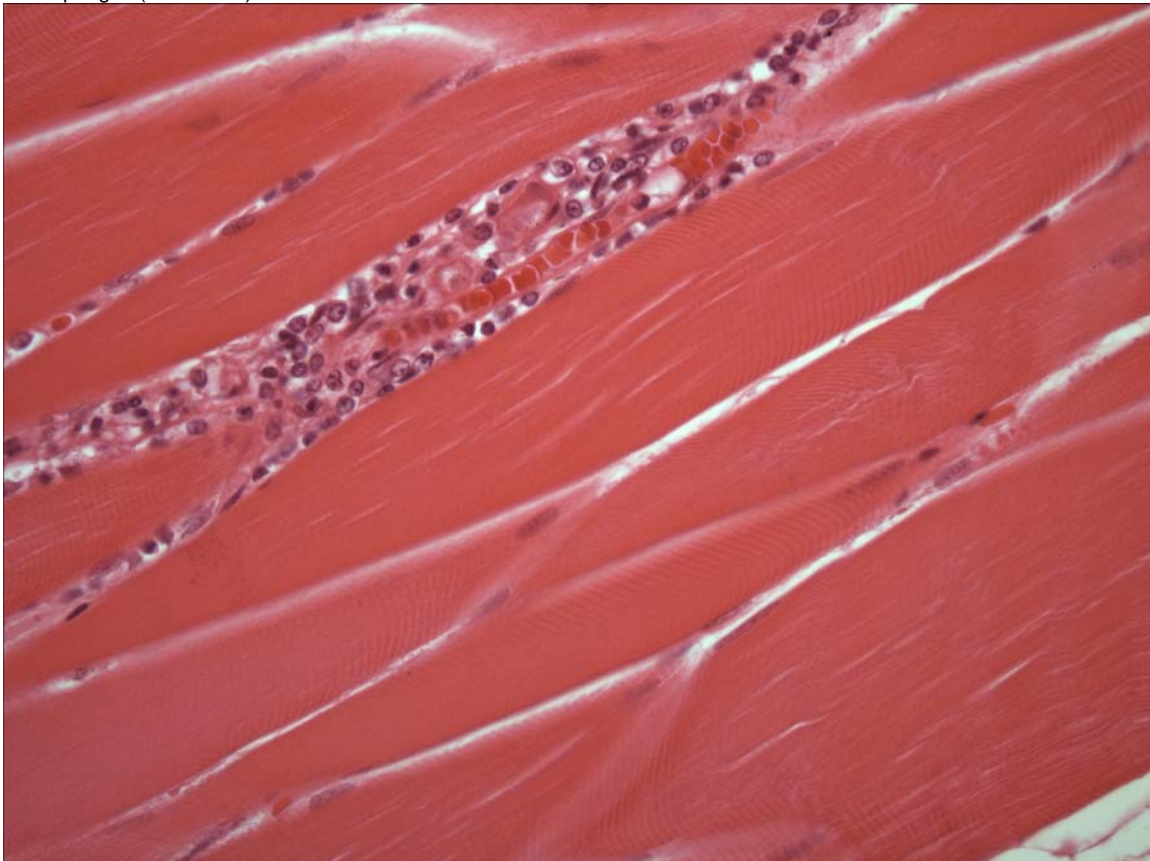


Figure 2. Skeletal muscle. Inflammatory cells expand perivascular spaces and the myofibers perimysium.

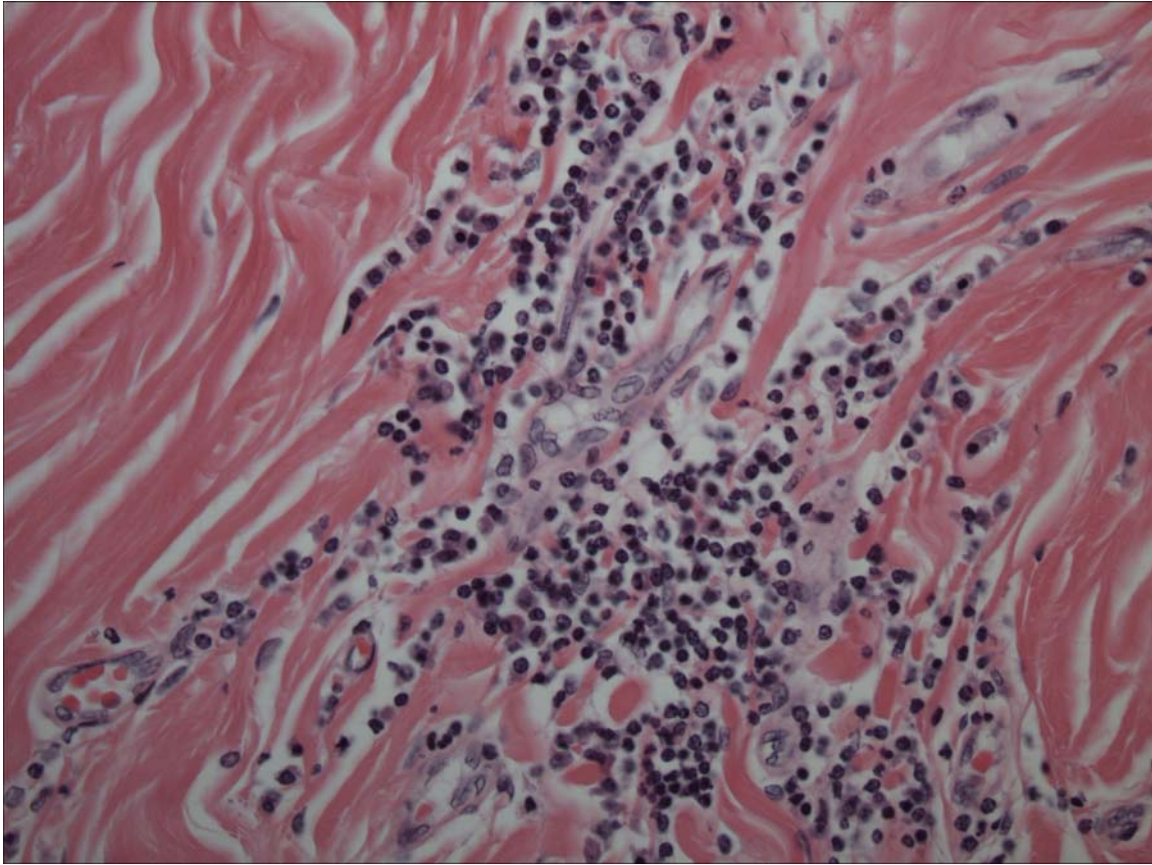


Figure 3.

The peri-gastric mass is composed of collagen with interspersed islands of lymphocytes, plasma cells, and macrophages.

PENDING			
TEST/HISTO	PURPOSE	SITE	RESULT

DATE: 01 Apr 05	REPORTING PATHOLOGIST: David S. Rotstein, DVM, MPVM, DACVP
--------------------	---

**CETACEAN NECROPSY REPORT:
Pilot Whale Stranding, NC 15/16 Jan 2005**

Field ID: RT 106
Accession Number: 05-20C
Date: 15 Jan 2005
Species: Globicephala macrorhynchus
Location: Bodie Island, NC (lat-35.84026, long-75.56089)
Sex: F
TL: 364.0 cm (Adult)

GROSS REPORT

REPORTING INSTITUTION: NOAA Beaufort

Report adapted from necropsy notes.

Musculoskeletal System. There are five double and four single ribs on the left.

Respiratory System. The left ventral lung is adhered to the pericardium. The left lung lymph node is enlarged.

Genitourinary System. There is a corpus luteum on the right ovary. The left and right horns are 31.0 and 60.0 cm in circumference, respectively. There is a 115 cm fetus in the right uterine horn. The urinary bladder contains frothy yellow fluid.

ANCILLARY FINDINGS

N/A

TISSUES/SAMPLES RECEIVED

REPORTING INSTITUTION: UNIVERSITY OF TENNESSEE

Received is one bag of formalin labeled as "RT106 10% Formalin" received 1 Feb 2005. There are five cassettes and 12 free tissues. Cassettes are labeled as "Pre-scapular Lymph Node", "Lung Lymph Node" (1), "Lung Lymph Node" (2), "Mesenteric Lymph Node", and "Colonic Lymph Node"; representative sections are placed in cassettes 1-5, respectively. Representative sections of remaining tissues are placed in Cassettes 1-10.

MICROSCOPIC FINDINGS

REPORTING INSTITUTION: UNIVERSITY OF TENNESSEE

Pre-scapular Lymph Node (slide 1): There are increased macrophages with medullary spaces. Approximately 15% of the macrophages contain intracytoplasmic, brown granular pigment (hemosiderin). There is a mild increase in plasma cells. Lymphoid follicles are primary.

Trachea (slides 1 and 2): No significant histologic findings (NSF).

Kidney (slide 1): NSF.

Lung Lymph Node (1) (slide 2): There is lymphoid hyperplasia with secondary follicles present.

Large Intestine (slide 2): There are increased plasma cells within the lamina propria.

Lung Lymph Node (3) (slides 3 and 6): There is abundant adipose with multifocal islands of lymphocytes, plasma cells, macrophages, and occasional multi-nucleated giant cells (Figure 1). Macrophages contain intracytoplasmic brown, granular pigment (hemosiderin).

Atrium (slide 3): NSF.

Mesenteric Lymph Node (slide 4): There is marked loss of follicles with replacement by large numbers of macrophages and cellular debris. Macrophages contain finely stippled, deeply basophilic granular material with their cytoplasm.

Mammary Gland (slide 4): Ducts contain granular eosinophilic material. Acini are collapsed with little luminal product save for less than 10% of acini which contain eosinophilic material. There is occasional replacement of acini by lymphocytes and plasma cells (Figure 2).

Ventricle (slide 4): NSF.

Colonic Lymph Node (slide 5): There are increased plasma cells and macrophages.

Spleen (slide 5): NSF.

Skeletal Muscle (slide 5): NSF.

Urinary Bladder (slide 6): There is artifactual loss of the mucosa.

Pancreas (slide 6): There is moderate autolysis.

Adrenal Gland (slide 7): NSF.

Liver (slide 7): There is diffuse, mild biliary hyperplasia. Within portal tracts, there is a mild increase in plasma cells and increased macrophages with intracytoplasmic, brown, granular pigment (hemosiderin). There is diffuse, mild fibrosis of central veins.

Lung (slide 8): There is focal, nodular fibrosis replacing bronchioles and alveoli. Occasional alveoli are flooded with eosinophilic, proteinaceous, granular substance.

Heart with Atrioventricular Valve (slide 9): There is focal myocardiocyte disarray.

Spinal Cord (slide 10): NSF.

MORPHOLOGIC DIAGNOSES

Lymphoreticular/Hematopoietic Systems:

1. Lung Lymph Node: Lymphadenitis, granulomatous, multifocal.
2. Mesenteric Lymph Node: Lymphadenitis, granulomatous, diffuse, severe.

Respiratory System:

Lung: Focal fibrosis.

Reproductive System:

Mammary Gland:

- a. Mastitis, lymphoplasmacytic, multifocal, mild to occasionally moderate.
- b. Inactive lactogenesis.

Hepatobiliary System:

Liver: Portal hemosiderosis and biliary hyperplasia, multifocal, mild.

FINAL DIAGNOSES/INTERPRETATIVE SUMMARY

Granulomatous Lymphadenitis

The cause of stranding remains open in this animal. There is evidence of lymphadenitis in two lymph nodes, but no overwhelming infectious/inflammatory process that would result in stranding. The focal cardiomyocyte disarray described in Slide 9 is likely a reflection of cardiomyocytes near the valvular insertion rather than a cardiomyopathy. This was not observed in other examined sections of the heart.

FIGURES

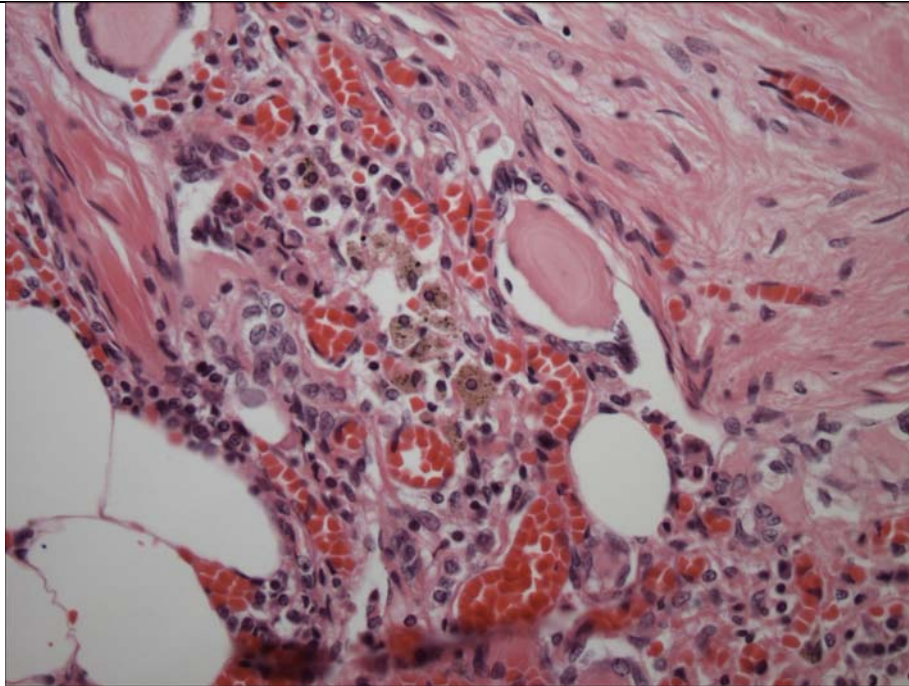


Figure 1. Lung Lymph Node. There are aggregates of macrophages, multinucleated giant cells, and plasma cells.

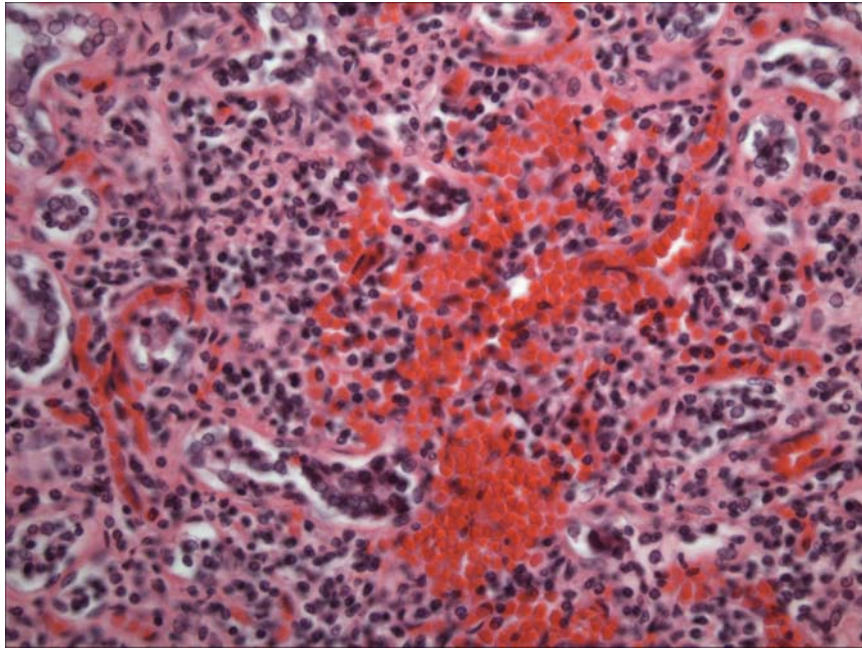


Figure 2. Mammary Gland. There are infiltrates of lymphocytes and plasma cells.

ADDENDUM: 14 Dec 2005

History: Eight heads obtained from pilot whales stranded on Bodie Island, NC were examined November 29 and 30th, 2005. Heads were collected from the beach, the site of gross necropsy of the stranded population within (3) days, transported to University of North Carolina at Wilmington and frozen. Heads were thawed for the necropsy procedure.

Sample Disposition: A necropsy data collection was utilized for the procedure to denote samples collected, gross findings, examiners, and acquisition of photos if done. The following samples were collected:

Tissue	Disposition	Comment	Analysis—Individual and Institution
Brain	½ Formalin	Histopath back-up	Rotstein, UT
	Subsamples-Cassette: Cerebrum, Cerebellum, brainstem, pons, thalamus, corpus callosum, spinal cord, pituitary gland, and any observed lesions	Histopath immediate examination	Rotstein, UT
	Freeze	Biotoxin, Viral, or other ancillary diagnostics	Stored at UNCW
	Formalin	Fat Stains	NCSU
	Weight	Body Mass Studies	Pabst/McLellan, UNCW; indicated in gross report
Mandibular (Jaw Fats)	Subsamples: External, internal, and any lesions	Histopath	Rotstein, UT
	Formalin	Fat Stains	NCSU
	In toto	Lipid Analyses	Koopman, UNCW
Ears	Formalin	Histopath	Stored at UT
Parasites	Ethyl Alcohol	ID	Flowers, NCSU
Teeth	Frozen	Age Determination	Hohn, NOAA-NMFS, Beaufort
Melon/CTs	Frozen (?)	CT	Pabst, McLellan, Harper, UNCW
	Formalin	Histopath	Rotstein, UT
Mouth Scars; Other Lesions	Formalin	Histopath	Rotstein, UT
Occipital Condyle (RT50)	Swab Tissue	Culture(swab) Brucellosis*	Rotstein, UT

*At discretion of Larry Dunn at Mystic Aquarium.

General: On 30 Nov 2005, a whole pilot whale head is examined.

Nervous System:

The pituitary gland is diffusely red-brown. There are no observable lesions. Representative sections are placed in a labeled tissue cassette and the remaining pituitary gland is placed in retained in formalin. The surface of the brain is reddened diffusely. Vessels in the ventral cerebrum and cerebellum and engorged with blood (congestion). Representative sections of brain are collected in cassettes for histopath including fat stains. The brain is bisected with one half placed in formalin and the other half frozen at -70C.

Brain Weight

Field ID	Weight (g)
RT107	2865
RT50	3569
RT68	2625
RT103	2415
RT106	2563
RT48	2826
RT59	2892
RT72	2317

Sensory System:

There is umbilication of the right cornea and complete loss of integrity of the left cornea (scavenging); only the whole right eye is retained. At the junction between the left tympanic and periotic and tympanic bone, there is a linear 2 X 1 reddening of soft tissue. On cut surface, the reddening is superficial and does not span more than 2mm. There are no bony fractures. There is an irregular round, 2.0 cm reddening of the right intramandibular fat that is located in the ventral region. There is a scant amount of red-tinged fluid in the pterygoid sinus. There is mild infestation of metazoans in the left and right pterygoid sinus.

Tongue and Oral Cavity: No observable lesions. Representative sections are obtained.

GROSS DIAGNOSES:

Nervous System:

Brain:Vascular congestion, ventral.

Sensory System:

Peritympanic fibrous connective tissue and adipose: Focal superficial hemorrhage.

COMMENT-GROSS NECROPSY: Superficial vessels in the cerebrum and cerebellum are congested. This is likely post-mortem hypostatic congestion. There is superficial, focal hemorrhage in the periotic soft tissue. This is directly adjacent to a mildly, rounded and slightly jutting portion of tympanic bone. The superficial nature of this lesion and lack of overt hemorrhage into the periotic space, suggests that pressure upon localized vessels may result in hemorrhage as an antemortem event or that there is postmortem pressure resulting in vessel tearing and localized blood pooling. Histopathology is pending.

MICROSCOPIC FINDINGS

Slide 12

Pituitary Gland: No significant histologic findings (NSF).

Slides 12-14, 17

Brain: Eight sections are examined. There is artifactual clefting of the neuropil (freeze artifact). There is mild, multifocal vascular congestion.

Slides 15, 16

Brain: Fat Stains-NEGATIVE.

Slide 18

Peri-Otic Soft Tissue: There is very mild, superficial erythrocyte extravasation.

Slide 20

Left Extramandibular Fat: NSF.

Slide 21

Intramandibular Fat: NSF.

Slide 22

Intramandibular Fat: Special stains for fat (Oil Red O) indicate the presence of fat globules without respect for membranous borders (temperature-related artifact).

Slide 23

Right Pterygoid Sinus: Three sections are examined. Within the adipose, there is leakage of serum and red blood cells around vascular spaces and dissecting along adipocyte membranes. There are lymphocytes and plasma cells forming a variably-dense, laminar infiltrate within the submucosal epithelial collagen stroma. There is a single trematode, 100 microns in width with a 10 micron tegument, solid body cavity, paired ceca, and ova.

DIAGNOSES

Sensory System:

Pterygoid Sinus, Left: Sinusitis, lymphoplasmacytic, diffuse, moderate with intralesional trematodes and multifocal, adipose perivascular hemorrhage and serum exudation.

COMMENT: The grossly observed reddened soft tissue in the periotic region likely represents a localized region of vascular rupture and hemorrhage. It does not extend into the underlying stroma. There is serum exudation and hemorrhage in the adipose of the pterygoid sinus, but no evident rupture of adipocytes. Inflammation in the pterygoid sinus is likely associated with parasitic infestation.

DATE: 05 Apr 05 14 Dec 05	REPORTING PATHOLOGIST: David S. Rotstein, DVM, MPVM, DACVP
---------------------------------	---

**CETACEAN NECROPSY REPORT:
Pilot Whale Stranding, NC 15/16 Jan 2005**

Field ID: RT 107
Accession Number: 05-21C
Date: 15 Jan 2005
Species: Globicephala macrorhynchus
Location: Bodie Island, NC (lat-35.84026, long-75.56089)
Sex: F
TL: 357.0 cm (Adult)

GROSS REPORT

REPORTING INSTITUTION: NOAA Beaufort

Report adapted from necropsy notes.

General Examination. On the maxilla, two (2) rear teeth broken off and on the mandible, last rear tooth is broken off. There are healed fishery interaction (FI) marks that are not attributable to the cause of death. This includes the right mandible where there is a well-healed line mark at the angle of the mouth (commisure).

Abdominal Cavity. There are 3 large (2.5 cm) Monorygma cysts in the broad ligament.

Respiratory System. The lungs contain abundant foamy liquid.

Hematopoietic/Lymphoreticular Systems. The gastric lymph nodes are discolored and "do not look healthy".

Digestive System. There is a 5 X 1.0 (cm) section of pancreas that is moss green.

Urinary System. The urinary bladder is empty. The mucosa is gray and there is a heavy pericystic infestation of Monorygma.

Reproductive System. The milk is green-tinged. There is no evidence of lactation. There are mature corpora on both ovaries.

ANCILLARY FINDINGS

N/A

TISSUES/SAMPLES RECEIVED

REPORTING INSTITUTION: UNIVERSITY OF TENNESSEE

Received is one bag of formalin labeled as "RT107 10% Formalin" received 1 Feb 2005. There are four cassettes and 17 free tissues. Cassettes are labeled as "Pre-scapular Lymph Node", "Lung Lymph Node", "Gastric Lymph Node", and "Lymph Node" (could not read writing); representative sections are placed in cassettes 1-4, respectively. Representative sections of remaining tissues are placed in Cassettes 1-8.

MICROSCOPIC FINDINGS

REPORTING INSTITUTION: UNIVERSITY OF TENNESSEE

Pre-Scapular Lymph Node (slide 1): There are increased plasma cells and macrophages within the medullary spaces. Scattered macrophages contain intracytoplasmic, brown, granular pigment (hemosiderin).

Aorta (slide 1): No significant histologic findings (NSF).

Atrium (slide 1): NSF.

Lung Lymph Node (slide 2): Lymphocytes are adequate in numbers. There are increased macrophages with the medullary spaces. Approximately 20% of macrophages contain intracytoplasmic, brown granular pigment (hemosiderin) and occasional macrophages have intracytoplasmic erythrocytes (erythrophagocytosis).

Kidney (slide 2): NSF.

Heart (slide 2): NSF.

Gastric Lymph Node (slide 3): There is moderate edema characterized by expansion of follicles by clear spaces. There are increased plasma cells and macrophages. Multifocally, macrophages form poorly aggregates clusters laden with abundant intracytoplasmic black, globular pigment (anthracosis vs melanosis).

Blubber (slide 3): NSF.

Spleen (slide 3): NSF.

Urinary Bladder (slide 4): NSF.

Lymph Node, NOS (slide 4): There are scattered macrophages contain intracytoplasmic granular black pigment (anthracosis) and birefringent crystalline material (silicosis).

Liver (slide 4): There is multifocal, mild biliary hyperplasia. There are periportal macrophages with abundant intracytoplasmic granular brown-black pigment (hemosiderin).

Trachea (slide 4): There is diffuse, mild to occasionally moderate expansion of the submucosa by lymphocytes and plasma cells.

Mammary Gland (slides 5 and 7): Occasional ducts and acini contain inspissated eosinophilic, proteinaceous material. Remaining acini have diminished luminal diameters.

Uterus (slide 5): The endometrium is lined by a single layer of low cuboidal epithelial cells. Glandular density is decreased. Glands are present singly. There is a moderate increase in lymphocytes and plasma cells within the submucosa.

Pancreas (slide 6): NSF.

Diaphragm (slide 6): NSF.

Lung (slide 7): NSF.

Spinal Cord (slide 8): The perikaryon of approximately 30% of neurons is expanded by golden, globular pigment (ceroid-lipofuscin).

MORPHOLOGIC DIAGNOSES

Hematopoietic/Lymphoreticular Systems:

- 1.Lung lymph node: Draining lymph node.
- 2.Gastric lymph Node:
 - a.Reactive lymph node.
 - b.Anthracosis vs. silicosis.

Respiratory System:

Trachea: Tracheitis, lymphoplasmacytic, diffuse, mild.

Reproductive System:

- 1.Uterus:
 - a.Endometritis, lymphoplasmacytic, diffuse, mild to moderate.
 - b.Cyclical atrophy.
- 2.Mammary Gland: Inactive lactogenesis.

FINAL DIAGNOSES/INTERPRETATIVE SUMMARY

Draining Lymph Node

A cause of stranding was not evident. Changes within the lymph node were mild and not indicative of systemic disease.

ADDENDUM: 14 Dec 2005

History: Eight heads obtained from pilot whales stranded on Bodie Island, NC were examined November 29 and 30th, 2005. Heads were collected from the beach, the site of gross necropsy of the stranded population within (3) days, transported to University of North Carolina at Wilmington and frozen. Heads were thawed for the necropsy procedure.

Sample Disposition: A necropsy data collection was utilized for the procedure to denote samples collected, gross findings, examiners, and acquisition of photos if done. The following samples were collected:

Tissue	Disposition	Comment	Analysis—Individual and Institution
Brain	½ Formalin	Histopath back-up	Rotstein, UT
	Subsamples-Cassette: Cerebrum, Cerebellum, brainstem, pons, thalamus, corpus callosum, spinal cord, pituitary gland, and any observed lesions	Histopath immediate examination	Rotstein, UT
	Freeze	Biotoxin, Viral, or other ancillary diagnostics	Stored at UNCW
	Formalin	Fat Stains	NCSU
	Weight	Body Mass Studies	Pabst/McLellan, UNCW; indicated in gross report
Mandibular (Jaw Fats)	Subsamples: External, internal, and any lesions	Histopath	Rotstein, UT
	Formalin	Fat Stains	NCSU
	In toto	Lipid Analyses	Koopman, UNCW
Ears	Formalin	Histopath	Stored at UT
Parasites	Ethyl Alcohol	ID	Flowers, NCSU
Teeth	Frozen	Age Determination	Hohn, NOAA-NMFS, Beaufort
Melon/CTs	Frozen (?)	CT	Pabst, McLellan, Harper, UNCW
	Formalin	Histopath	Rotstein, UT
Mouth Scars; Other Lesions	Formalin	Histopath	Rotstein, UT
Occipital Condyle (RT50)	Swab Tissue	Culture(swab) Brucellosis*	Rotstein, UT

*At discretion of Larry Dunn at Mystic Aquarium.

General: On 29 Nov 2005, a whole pilot whale head is examined. There is a long line scar at the gap of the low left mandible.

Nervous System:

The pituitary gland is diffusely red-brown. There are no observable lesions. Representative sections are placed in a labeled tissue cassette and the remaining pituitary gland is placed in retained in formalin. The surface of the brain is reddened diffusely. Vessels

in the ventral cerebrum and cerebellum and engorged with blood (congestion). Midline, in the anterior cerebellum, there is a 2.1 cm segment of vessel which is expanded by gas. This portion is approximately 2.0 cm from the cut end of the vessel. The vessel is aspirated with a 10.0 cc syringe and 19.0 g needle and collected into a red top Vacutainer® tube. A section of cerebellum from this region is placed in a cassette. Smaller (less than 0.5 cm) bubbles within the cerebellar vasculature are occasionally observed. Representative sections of brain are collected in cassettes for histopath including fat stains. The brain is bisected with one half placed in formalin and the other half frozen at -70C.

Brain Weight

Field ID	Weight (g)
RT107	2865
RT50	3569
RT68	2625
RT103	2415
RT106	2563
RT48	2826
RT59	2892
RT72	2317

Digestive System/Oral Cavity:

There is a flat, 6 X 4 x 3 cm dark red streaking of the hyoid muscle. The tongue and oral cavity have no observable lesions. Representative sections are placed in cassettes.

Sensory System:

The left eye has an umbilicated cornea and there is a focal, 1.5 cm central, transmural loss of corneal integrity (scavenging). There is a 1.5 X 0.7 X 0.2 cm fragment of bone separate from the anterior portion of the left tympanic bone (post-mortem fracture). The edges are smooth and there is occasional scalloping of the bone. There is no associated hemorrhage, edema, or trauma to the periosteal connective tissue or adipose. Mandibular fats were light yellow and incised easily. The periosteum peeled easily from the mandible. There were no observable changes to the melon fat. Representative sections of mandibular fat (external, internal) and melon were obtained. The eyes and ear were collected whole in formalin.

GROSS DIAGNOSES:

Nervous System:

Brain:

1. Vascular congestion, ventral.
2. Post-mortem intravascular gas bubble formation (suspect).

COMMENT-GROSS NECROPSY: Superficial vessels in the cerebrum and cerebellum are congested. This is likely post-mortem hypostatic congestion. There is a single large bubble in a cerebellar vessel and few small bubbles observed in other cerebellar vessels. While histologic examination for the presence of post-mortem bacteria may provide more definitive proof, these bubbles are likely the result of post-mortem bacterial gas production. Other considerations including air emboli or post-head removal introduction of gas are also considered possible causes.

MICROSCOPIC FINDINGS

Slide 9

Pituitary Gland: No significant histologic findings (NSF).

Slide 9-12, 14, 14A

Brain: Fourteen sections are examined. There is clefting of the neuropil (freeze artifact). Occasional vessels are expanded by pale spaces without associated hemorrhage (artifact).

Slide 13

Tongue: NSF.

Oral Mucosa: There is a multifocal, mild to moderate periglandular and submucosal infiltrate of lymphocytes and plasma cells. Glands are mildly to markedly ectatic and contain wispy eosinophilic, proteinaceous material, or rarely degenerate neutrophils.

Slide 15

Extramandibular Fat: NSF.

Slide 16

Intramandibular Fat: There is occasional perivascular exudation of serum and erythrocytes.

Slide 17

Melon Fat: NSF.

DIAGNOSIS

Digestive System: Stomatitis, lymphoplasmacytic, diffuse, mild to moderate with glandular ectasia.

COMMENT

Stomatitis is non-specific and has been observed in many of the pilot whales examined. There are random clear spaces in the neuropil of the brain without associated hemorrhage. These are likely the result of post-mortem putrefaction.

DATE: 08 Apr 05 14 Dec 05	REPORTING PATHOLOGIST: David S. Rotstein, DVM, MPVM, DACVP
---------------------------------	---

**CETACEAN NECROPSY REPORT:
Pilot Whale Stranding, NC 15/16 Jan 2005**

Field ID: KMS379
Accession Number: 05-22C
Date: 15 Jan 2005
Species: Kogia simus
Location: Cape Hatteras, NC (lat-35.22235, long-75.53066)
Sex: M
TL: 242.0 cm (Sub-Adult)

GROSS REPORT

REPORTING INSTITUTION: NOAA Beaufort

Report adapted from necropsy notes.

History: This cetacean stranded 1 mile north of another K. simus that was reported as a live stranding.

General Examination. There are abrasions present on the leading edges of flukes and flippers. There is reddening of abdomen (lividity). There is a small, oblong wound extending into the blubber on the right peduncle above the anus. This wound has clean edges. The dorsal fin is cut and the right fluke lobe is missing a section (old, completely healed wounds). Phyllobothrium sp. are present in the blubber and abdomen with the heaviest concentration at the genital slit. The eye girth is 104.0 cm.

Digestive System. The mouth is filled with sand. The esophagus is full of froth. Thirteen teeth are present in the lower jaw. There is a small amount of fluid in the abdominal cavity. Small worms are present in the stomach and are placed in a cassette. Large intestine filled with dark black fecal material. Small intestine has brown bile fluid.

Urinary System. There is multifocal yellowing (fatty) of occasional reniculi. Some of these regions had hard centers. The urinary bladder is full.

Hepatobiliary System. The liver is full of fluid (congestion?).

Respiratory System. The lung is full of foam.

Head dissections completed 15 Feb 2005. Findings recorded by C. Harms.

Head necropsies on 2 dwarf sperm whales and two short-finned pilot whales. All part of mass stranding from 15 (pilot whales) and 16 (Kogia) January 2005. The Kogia heads were frozen within half a day of stranding; the pilot whale heads were frozen the evening of the day after the stranding (Sunday). These animals were selected based on quick transfer of the heads to freezer at time of stranding, and relatively small size (pilot whales, possibly more prone to acoustic trauma). All 4 heads were imaged by CT at the NCSU College of Veterinary Medicine on 31 January (Kogia) and 1 February (pilot whales) while still frozen (stored in walk-in freezer overnight). They were then thawed for necropsy starting on 1 February. The necropsies were performed at NMFS Beaufort Laboratory 3 February. At the time of necropsies the Kogia heads were fully thawed and the pilot whale heads were still cold internally.

The mouth is full of sand, and there is a moderate amount of sand in the blowhole and within the goosbeak. Major trauma to jaw rostrally at site of tooth removal on beach. Also, several teeth are broken.

Subcutis: There are a few Phyllobothrium cysts in the blubber surrounding the mandible. No hemorrhage or congestion is observed.

There is substantial hemorrhage or congestion in the acoustic fat within the mandible, bilateral, with a primary peripheral orientation surrounding an unaffected core, becoming more severe mid-way and rostrally where the full thickness is dark red. The adjacent bone is unaffected. There is intramuscular hemorrhage near the insertion of the left temporalis muscle (NSF on right side).

There is a mild to moderate amount of grey fluid within the canals of the fibrous nasal pad.

Ears: External auditory meatus, NSF bilaterally. Right periotic bone is surrounded by moderate hemorrhage, worse dorsally. Photographs of cross sectional cuts at 6.9, 8.5 and 9.3 cm caudal to the caudal-most tooth on the right side, and of the entire left intramandibular acoustic fat. The hemorrhage (or congestion) is greater on the right than on the left side.

Brain: Dura is diffusely hemorrhagic or congested, pink dorsally to dark red ventrally. The left ventral rostral cerebrum has a focal area of hemorrhage (sampled).

Brain weight 682 g

Both pterygoid sinuses have rostral epithelial hemorrhage. There is substantial soft tissue swelling medially in the left sinus, mild in the right sinus (elevated epithelium with underlying blood). No parasites are observed in the pterygoid sinuses.

Collected Samples: In formalin: both periotic bones, brain stem, cerebellum, left ventral cerebrum.

In cryovials for -80 C storage: tonsils.

ANCILLARY FINDINGS

N/A

TISSUES/SAMPLES RECEIVED

REPORTING INSTITUTION: UNIVERSITY OF TENNESSEE

Received are two bags of formalin-fixed tissues labeled as "KMS 379 10% Formalin". One bag is received 1 Feb 2005 and the second bag is received 2 March 2005. In the first bag, there is one labeled cassette and 20 free tissues. Cassette is labeled as "worms" and is not processed. Representative sections of remaining tissues are placed in Cassettes 1-9. The second bag contains three labeled cassettes. Cassettes are labeled as brain and pterygoid sinus (2). Representative sections of cerebrum and pterygoid sinus are placed in Cassettes 10 (brain) and 11-12 (pterygoid sinus).

MICROSCOPIC FINDINGS

REPORTING INSTITUTION: UNIVERSITY OF TENNESSEE

Kidney (slide 1): Diffusely, there is mild thickening of glomerular Bowman's capsule. Focally, there is distention of a cortical tubule with basophilic granular to irregular material filling the defect (mineral) (Figure 1). Within the collecting ducts, there is occasional intraluminal, eosinophilic, proteinaceous fluid (tubuloproteinosis).

Small Intestine (slide 1): Mucosal-associated lymphoid tissue is mildly hyperplastic.

Lung (slides 1 and 5): Three sections are examined. Alveolar spaces are flooded with extravasated erythrocytes. There is regionally extensive parenchymal loss with replacement by mature collagen (fibrosis) (Figure 2). Interstitial spaces are expanded by collagen.

Epithelium, Oral NOS (slide 2): There is moderate, diffuse epithelial hyperplasia with numerous arborizing rete pegs. The epithelium is irregular and undulating. Focally, there is a poorly-aggregated infiltrate of lymphocytes and plasma cells. Subepithelial vascular channels are prominent and lined by plump endothelial cells. Occasional myofibers exhibit nuclear centralization and ruffling.

Blubber (slide 2): No significant histologic findings (NSF).

Lymph Node, NOS (slide 2): There is diffuse, moderate lymphoid hyperplasia. There are scattered hemosiderophages.

Trachea (slide 2): Plasma cells are sprinkled throughout the submucosa.

Small Intestine (slide 3): NSF.

Urinary Bladder (slide 3): NSF.

Atrium (slides 3 and 5): NSF.

Spleen (slide 4): Periarteriolar lymphoid sheaths are prominent. There is moderate congestion.

Liver (slide 4): There is marked expansion of sinusoidal spaces by erythrocytes and pale spaces. Within the expanded sinusoids, there are increased macrophages many of which contain golden-brown, globular pigment (hemosiderin) or intracytoplasmic erythrocytes (erythrophagocytosis) (Figure 3). Multifocally, hepatocellular cords are attenuated (atrophied) and there is hepatocellular loss. Nearly 80% of hepatocytes have intracytoplasmic, discrete vacuolation (lipid accumulation).

Skeletal Muscle (slide 4): NSF.

Diaphragm (slide 5): NSF.

Adrenal Gland (slide 6): NSF.

Ventricle (slide 6): There is occasional cardiomyocyte disarray and occasional attenuated, undulating cardiomyocytes (wavy fibers). There is multifocal, mild myocardial hypertrophy.

Pancreas (slide 6): NSF.

Lymph Node (slide 7): There are increased macrophages within medullary spaces. Macrophages are foamy or contain intracytoplasmic, brown granular pigment (hemosiderin), or occasionally, erythrocytes (erythrophagocytosis).

Oral Cavity (slide 7): NSF.

Brain (slides 8 and 10): Occasional neurons contain small amounts of perikaryonal golden pigment (ceroid-lipofuscin). There is freeze artifact.

Spinal Cord (slides 8 and 9): Occasional neurons contain small amounts of perikaryonal golden pigment (ceroid-lipofuscin). There is freeze artifact.

Pterygoid Sinus (slides 11 and 12): There is moderate freeze artifact. The lining of the pterygoid sinus is cuboidal and regular. There is accumulation of erythrocytes and serum on the mucosal epithelial surface. Within the adipose, there is congestion of vessels and occasional hemorrhage. Fat globules are occasionally observed.

MORPHOLOGIC DIAGNOSES

Hepatobiliary System:

Liver:

- a. Congestion, diffuse, moderate to severe with erythrophagocytosis, and Kupffer cell hemosiderosis.
- b. Hepatocellular atrophy.
- c. Vacuolar hepatopathy (fatty change).

Respiratory System:

1. Lung:

- a. Pulmonary hemorrhage, diffuse, moderate.
 - b. Interstitial fibrosis and regionally extensive alveolar loss and fibrosis.
2. Pterygoid Sinus, Acoustic Fat: Hemorrhage, multifocal, mild with moderate vascular ectasia.

Cardiovascular System:

Ventricle: Cardiomyocyte disarray and wavy fiber formation, multifocal, mild.

Urinary System:

Kidney:

- a. Collecting ducts: Tubuloproteinosis, multifocal, mild.
- b. Focal tubular mineralization.
- c. Bowman's capsule: Membranous proliferation, diffuse, mild.

Digestive System:

Oral Cavity: Stomatitis, lymphoplasmacytic, focally extensive, moderate with diffuse epithelial hyperplasia.

Hematopoietic/Lymphoreticular System:

Lymph Node, NOS: Histiocytosis and hemosiderosis, diffuse, moderate.

FINAL DIAGNOSES/INTERPRETATIVE SUMMARY

Liver, Congestion, Chronic

Cardiomyopathy, suspect

Stomatitis

While a definitive cause of stranding was not evident, lesions in the hepatobiliary system, lymphoreticular system, respiratory, and cardiovascular system are most consistent with cardiovascular disease. Myocardial changes were not pronounced, but similar to other *Kogia* with "Kogia cardiomyopathy), there was evidence of cardiomyocyte disarray and fiber attenuation. Decreased cardiac flow could have led to increased resistance in pulmonary vasculature and associated interstitial fibrosis. Similarly, portal vascular compromise would have led to hepatic sinusoidal congestion. The presence of hemosiderophages and erythrophagocytosis as well as hepatocellular atrophy indicate that this was an ongoing change rather than congestion associated with a stranded animal where hepatic atrophy and hemosiderosis would not be an expected finding in a short-term stranding. Finally, excess hemosiderin within a lymph node further suggests decreased cardiac function.

Renal changes were mild, but the presence of protein in tubules does suggest a degree of glomerular compromise. Pulmonary hemorrhage which did not have associated hemosiderin-laden macrophages or macrophages in general, was likely a per-acute to acute event occurring before or at the time of stranding.

Hemorrhage was observed in the acoustic fat and within the pterygoid sinus. Due to freeze artifact, the erythrocytes within the pterygoid sinus and acoustic fat are ruptured, and at least in the pterygoid sinus leading to a diffuse eosinophilia. It is difficult to interpret this change as blood present within this region post-mortem (hypostatic congestion) versus antemortem. Antemortem causes would include localized trauma or an iatrogenic bleed.

FIGURES

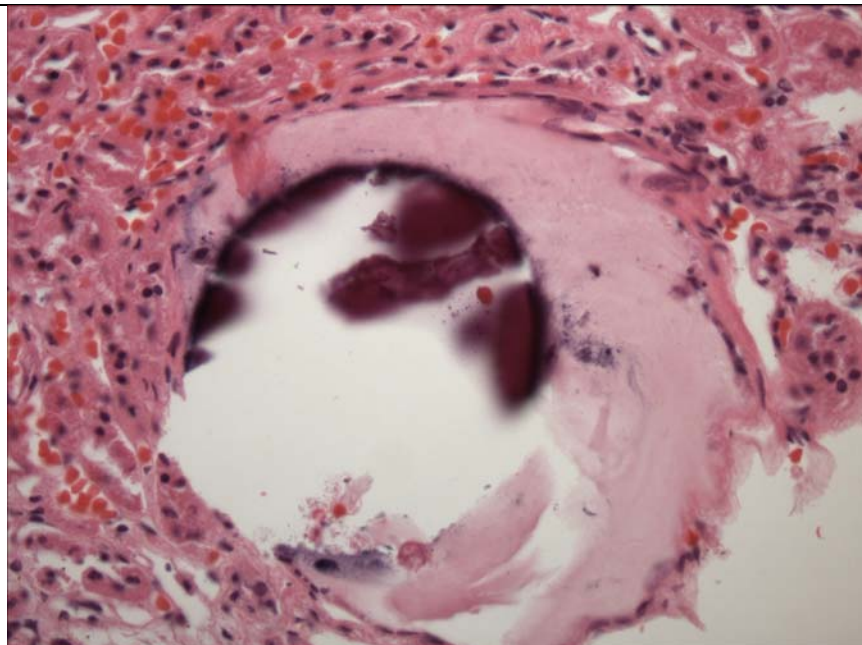


Figure 1. Kidney. There is tubular loss with distention of the space by mineral (dark purple) and collagenous tissue (fibrosis).

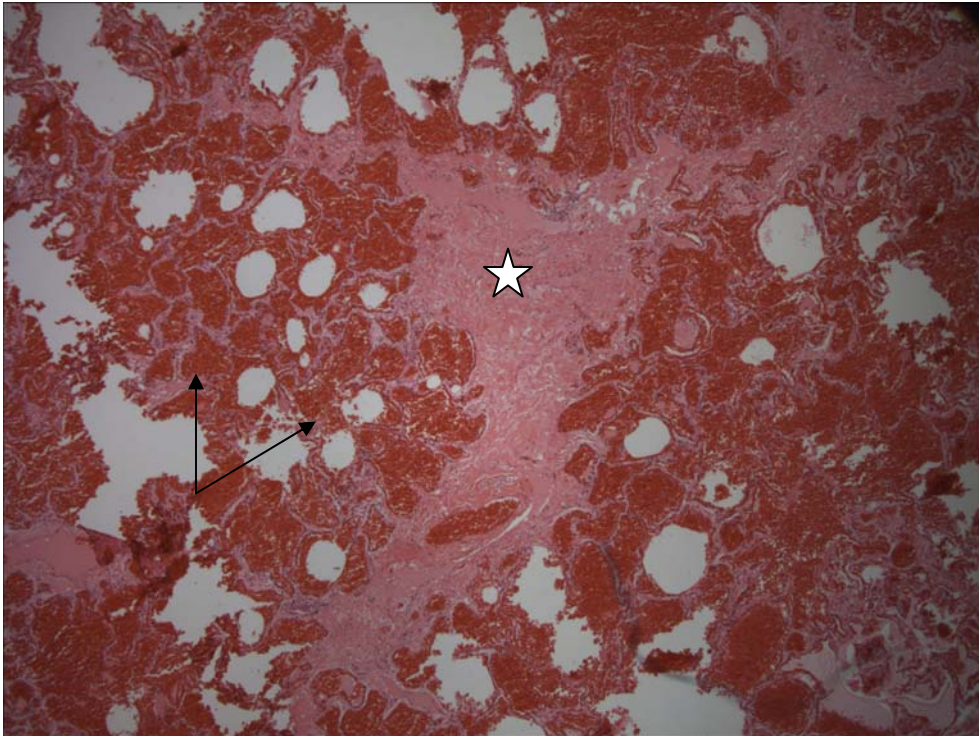


Figure 2. Lung. There is regional fibrosis (star). Alveolar spaces are flooded with red blood cells (arrow).

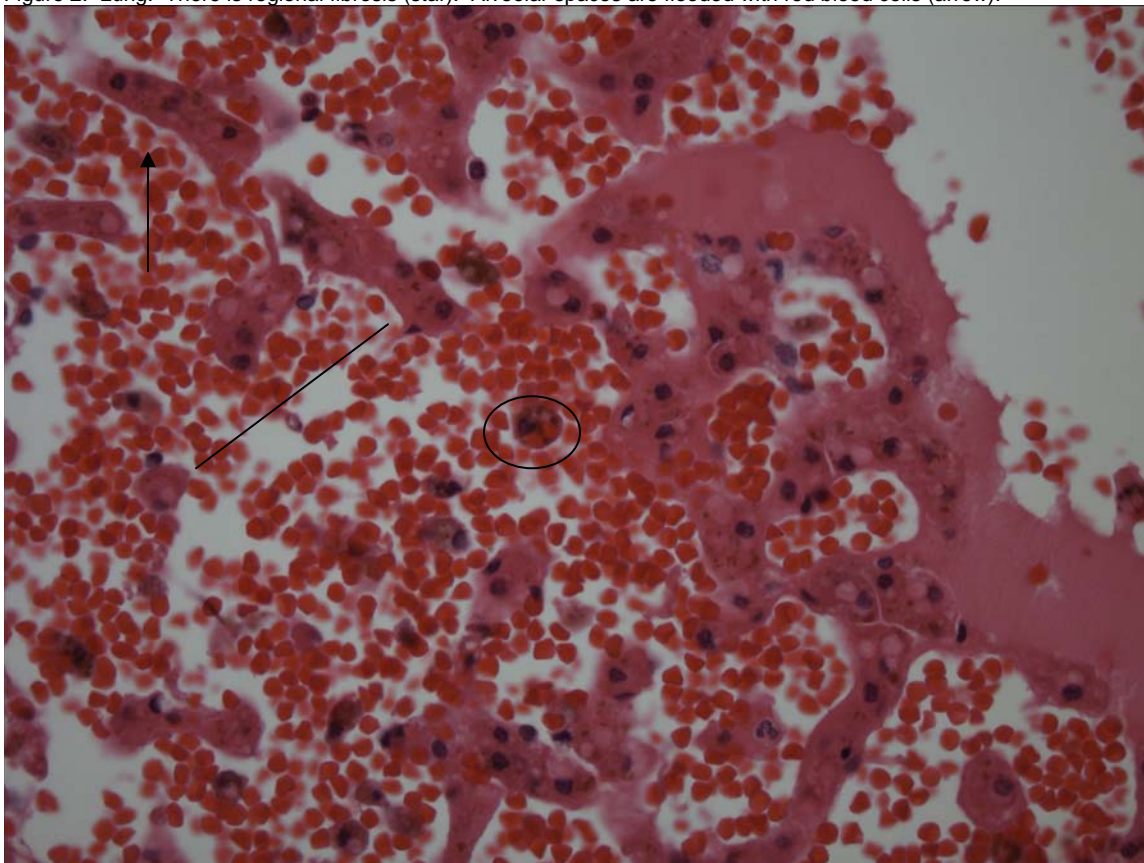


Figure 3. Liver. There is evidence of chronic passive congestion. Hepatocellular cords are atrophied (attenuated) (arrow). Sinusoids are markedly dilated (line) and macrophages contain either hemosiderin or occasional erythrocytes (circle). There is hepatocellular loss.

DATE:
7 April 2005

REPORTING PATHOLOGIST:
David S. Rotstein, DVM, MPVM, DACVP

**CETACEAN NECROPSY REPORT:
Pilot Whale Stranding, NC 15/16 Jan 2005**

Field ID: KMS380
Accession Number: 05-23C
Date: 15 Jan 2005
Species: Kogia simus
Location: Cape Hatteras, NC (lat-35.23412, long-75.53443)
Sex: F
TL: 218.0 cm (Sub-Adult)

GROSS REPORT
REPORTING INSTITUTION: NOAA Beaufort

Report adapted from necropsy notes.

History: This cetacean stranded 1 mile north of another K. breviceps that was reported as a live stranding. The cetacean was dead at time of arrival.

General Examination. There are abrasions present on the leading edges of flukes and right pectoral along with bruising of ventrum (lividity). The left eye was absent and the right eye was scavenged by birds. The eye girth is 104.0 cm.

Digestive System. Small worms are present in the esophagus.

Respiratory System. The lung is full of foam.

Reproductive System. Milk is expressed from mammary glands.
Head dissections completed 15 Feb 2005. Findings recorded by C. Harms.

Head necropsies on 2 dwarf sperm whales and two short-finned pilot whales. All part of mass stranding from 15 (pilot whales) and 16 (Kogia) January 2005. The Kogia heads were frozen within half a day of stranding; the pilot whale heads were frozen the evening of the day after the stranding (Sunday). These animals were selected based on quick transfer of the heads to freezer at time of stranding, and relatively small size (pilot whales, possibly more prone to acoustic trauma). All 4 heads were imaged by CT at the NCSU College of Veterinary Medicine on 31 January (Kogia) and 1 February (pilot whales) while still frozen (stored in walk-in freezer overnight). They were then thawed for necropsy starting on 1 February. The necropsies were performed at NMFS Beaufort Laboratory 3 February. At the time of necropsies the Kogia heads were fully thawed and the pilot whale heads were still cold internally.

Left eye is eviscerated, right external auditory meatus is lost with decapitation.

There is a small amount of sand in the blowhole and oral cavity.

There is a small amount of translucent fluid within the canals of the fibrous nasal pad in the right nasal sinus.

Subcutis: Phyllobothrium cyst in blubber ventromedial to left mandible rostrally. There is a plane of hemorrhage within the fat lateral to the right mandible that extends from the mandible horizontally to the skin, about 2 cm thick, not matched on the left side.

In the left intramandibular fossa there is an adhesion of periosteum to a healed fracture site. The fracture is sigmoid and stable, with slight over-riding of the caudal segment lateral to the rostral segment, and some pink color adjacent to the irregularity indicating continuing remodeling. This healed fracture is visible on the CT images.

Ears: Left external auditory meatus, NSF; right missing. There is mild soft tissue congestion ventral to the right ear, less so for left ear.

Brain: Dura mater is pink dorsally and red ventrally. Brain weight 567 g

Both pterygoid sinuses are clean, with no soft tissue swelling, nor any parasites noted. There is mild hemorrhage rostrally in the right pterygoid sinus. No parasites are observed in the pterygoid sinuses.

Collected Samples:

In formalin: both periotic bones, cerebellum, brain stem, cerebrum.

Teeth collected.

ANCILLARY FINDINGS

N/A

TISSUES/SAMPLES RECEIVED
REPORTING INSTITUTION: UNIVERSITY OF TENNESSEE

Received are two bags of formalin-fixed tissues labeled as "KMS 380 10% Formalin". One bag is received 1 Feb 2005 and the second bag is received 2 March 2005. In the first bag, there are 14 free tissues. Representative sections of tissues are placed in Cassettes 1-7. The second bag contains 2 ears and 6 labeled cassettes. Cassettes are labeled as cerebrum (2), cerebellum (2), and brain stem (2). Representative sections are placed in Cassettes 8 (cerebrum), 9-10 (cerebellum), and 11-12 (brainstem).

MICROSCOPIC FINDINGS
REPORTING INSTITUTION: UNIVERSITY OF TENNESSEE

Liver (slide 1): There is diffuse moderate congestion.

Lung (slide 2): There is multifocal to coalescing intra-alveolar hemorrhage. Multifocally, there is mild, multifocal, subpleural fibrosis with associated alveolar loss and accumulation of foamy macrophages (Figure 1).

Pancreas (slide 2): No significant histologic findings.

Lymph Node, Mesenteric (slide 3): Two sections are examined. There is marked lymphoid hyperplasia with prominent secondary follicles present. There are numerous histiocytes within intracytoplasmic, globular, basophilic nuclear material (tingible bodies) within the center of follicles. There are scattered hemosiderophages and poorly defined aggregates of multinucleated giant cells. Small clear spaces are associated with the multinucleated giant cells (Figure 2). Medullary sinuses are expanded by macrophages with finely, eosinophilic granular cytoplasm.

Uterus (slide 4): There is moderate mucosal epithelial hyperplasia with cloverleaf folds extending into lumina filled with abundant lightly, granular eosinophilic mucinous substance (Figure 3). There are two glands present within the myometrium (adenomyosis) (Figure 4).

Lymph Node, Mesenteric (slide 4): There is marked lymphoid hyperplasia with prominent secondary follicles present. There are numerous histiocytes within intracytoplasmic, globular, basophilic nuclear material (tingible bodies) within the center of follicles. There are scattered hemosiderophages. Medullary sinuses and subcapsular spaces are expanded by eosinophils and macrophages with finely, eosinophilic granular cytoplasm.

Kidney (slide 4): Within the medulla, there is multifocal mineralization of collecting ducts (Figure 5). Adjacent tubular lumina contain aggregated, sloughed epithelial cells (cellular casts). Occasional ducts are lined by attenuated epithelial cells and contain intraluminal eosinophilic substance with fine brown granules (hemoglobin/myoglobin cast).

Small Intestine (slide 5): There is artifactual sloughing of mucosal epithelium. Within the lumen, there is a single sagittal section of a metazoan (Figure 6). The metazoan is approximately 400 X 300 microns with a 20 micron tegument, solid parenchymatous, acoelomate body cavity (suspect larval cestode). There are increased eosinophils within the lamina propria.

Lymph Node, Mesenteric (slide 5): Two sections are examined. There is marked lymphoid hyperplasia with prominent secondary follicles present. There are numerous histiocytes within intracytoplasmic, globular, basophilic nuclear material (tingible bodies) within the center of follicles. There are scattered hemosiderophages. Medullary sinuses are expanded by macrophages with finely, eosinophilic granular cytoplasm.

Heart (slide 6): NSF.

Large Intestine (slide 7): Granular black material is adhered to the mucosal surface (squid ink). There are occasional trematode eggs.

Cerebrum (slide 8): NSF.

Cerebellum (slides 9-10): NSF.

Brainstem (slides 11-12): There is a single neuron with a pale, discrete vacuole within the perikaryon of a neuron.

MORPHOLOGIC DIAGNOSES

Genitourinary System:

1. Uterus:
 - a. Cystic endometrial hyperplasia and mucometra.
 - b. Adenomyosis, mild.
2. Kidney:
 - a. Mineralization, regionally extensive.
 - b. Intraluminal cellular and pigmented casts.

Respiratory System:

- Lung:
- a. Pulmonary hemorrhage, multifocal to coalescing.
 - b. Subcapsular fibrosis, multifocal with intrahistiocytic lipid (lipid pneumonia).

Hematopoietic/Lymphoreticular System:

Lymph Node, Mesenteric: Hyperplasia, diffuse, moderate with moderate eosinophilia, medullary histiocytosis, and occasional granuloma formation.

Digestive System:

1. Small Intestine: Enteritis, eosinophilic with Intraluminal cestodes.
2. Liver: Congestion, moderate.

FINAL DIAGNOSES/INTERPRETATIVE SUMMARY

Cystic endometrial hyperplasia and mucometra
Renal casts and mineralization
Pulmonary fibrosis and lipid pneumonia
Lymphoid hyperplasia

The cause of stranding was not identified and lesions observed in the genitourinary, digestive, hematopoietic/lymphoreticular and respiratory systems would not account for the stranding. There is evidence of cystic endometrial hyperplasia in the uterus with associated increased secretory product. There is no evidence of inflammation (endometritis, metritis). Adenomyosis, or the localization of glands within the myometrium has been observed in many species including elephants, impalas, and domestic ruminants. This is not the same condition as endometriosis where there is extra-uterine implantation of uterine tissue.

Mesenteric lymph node hyperplasia with an associated increase in eosinophils is likely the response to endoparasitism. In addition, there were occasional multinucleated giant cells with associated clear spaces (gas bubbles) and no hemorrhage. These inflammatory foci are likely associated with parasitic migration or possibly gas from the gastrointestinal tract. Such mesenteric lymph node changes may be observed in pigs with pneumatosis intestinalis. In this condition, gas is produced and may be absorbed into regional lymphatics. The intestinal wall is expanded by gas. This was not grossly observed in this case. Casts within the tubules of the kidney were not common, but included cellular and pigmented. This pigmented tubular cast could be a hemoglobin or myoglobin cast. The number of casts were few and the response of tubular epithelial attenuation suggests minimal effect upon the animal. Thus, uremia was unlikely.

There is evidence of per-acute to acute pulmonary hemorrhage. The cause was not evident, but is likely associated with the cessation of cardiac function. Pulmonary hemorrhage was also observed in KMS 379 (*Kogia simus*). Pulmonary barotrauma is mentioned as another cause of pulmonary hemorrhage (in divers), but other associated changes (grossly observed hemorrhages in other tissues) were not described, nor was there evidence to suggest the formation of air emboli.

FIGURES

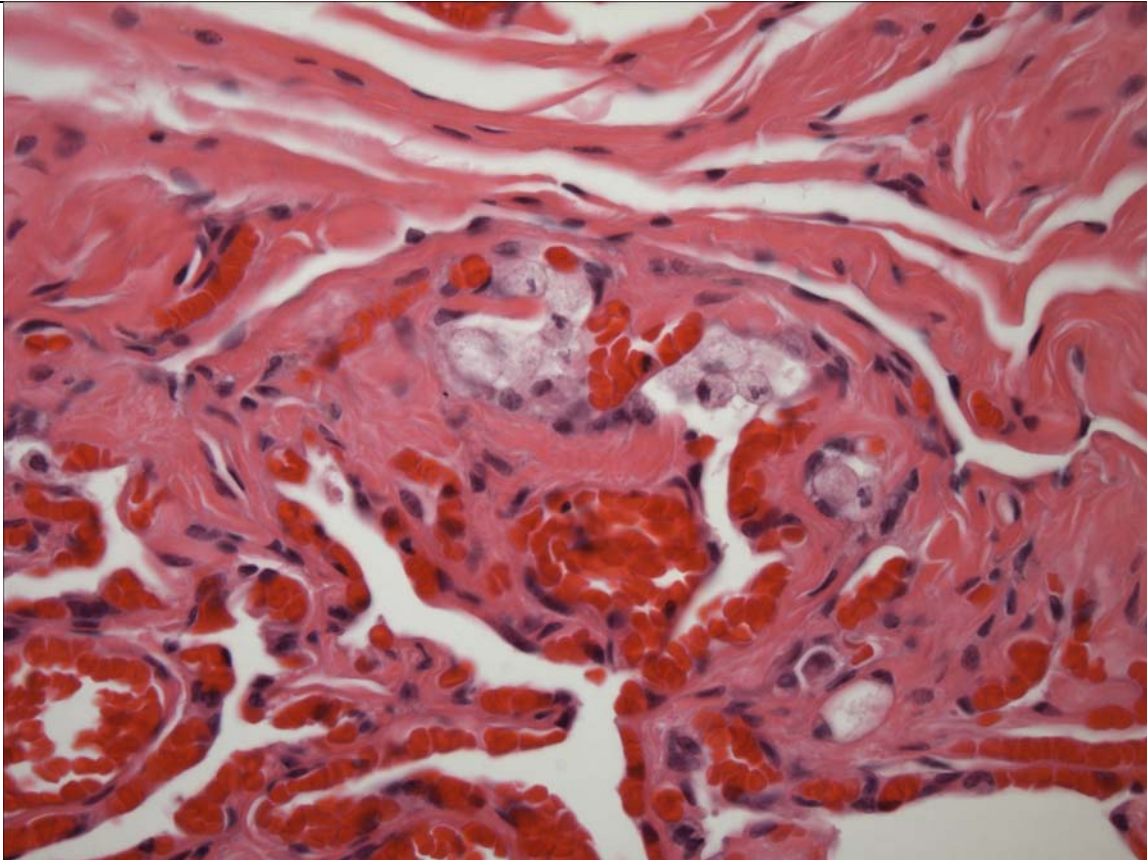


Figure 1.

Lung. There are regions of interstitial fibrosis and accumulation of foamy (lipid filled) macrophages.

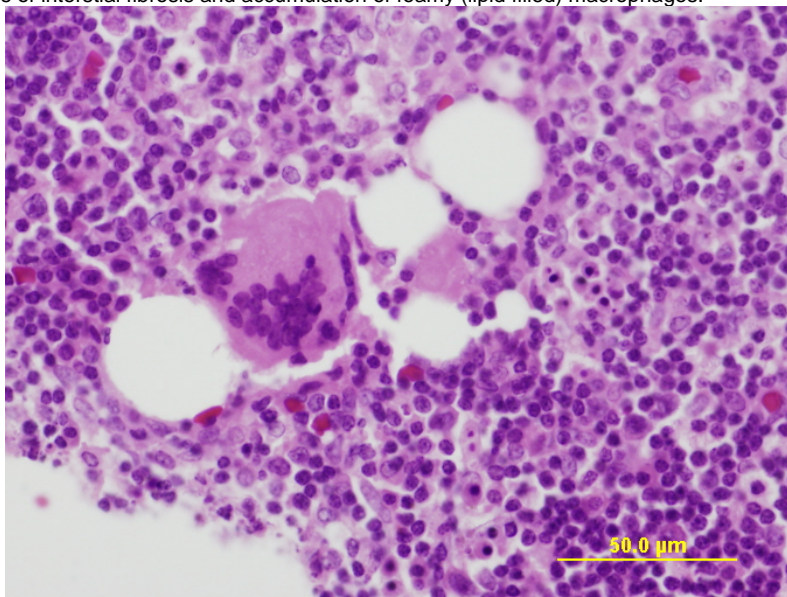


Figure 2. Mesenteric Lymph Node. Multinucleated giant cell with associated gas bubbles.

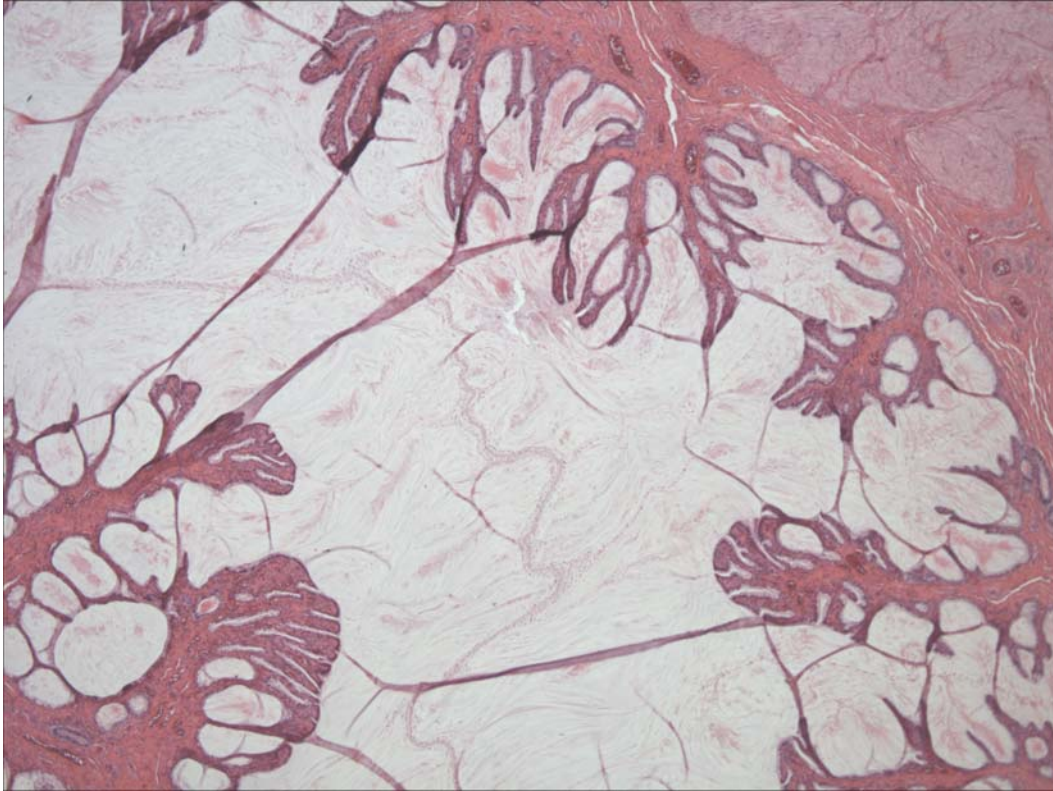

Figure 3. Uterus. There is endometrial hyperplasia and the lumen of the uterus is filled with eosinophilic, wispy mucoid substance.

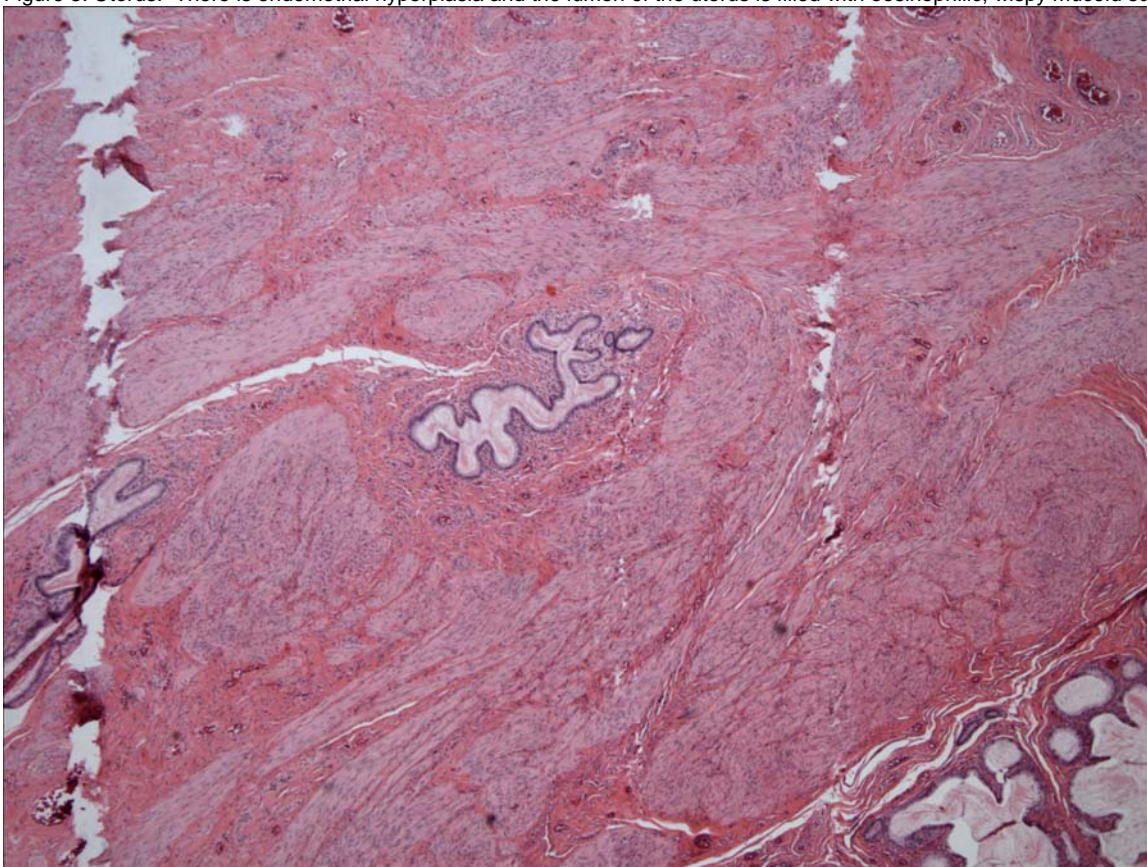


Figure 4. Uterus. Within the myometrium, there are two nests of glands (adenomyosis).

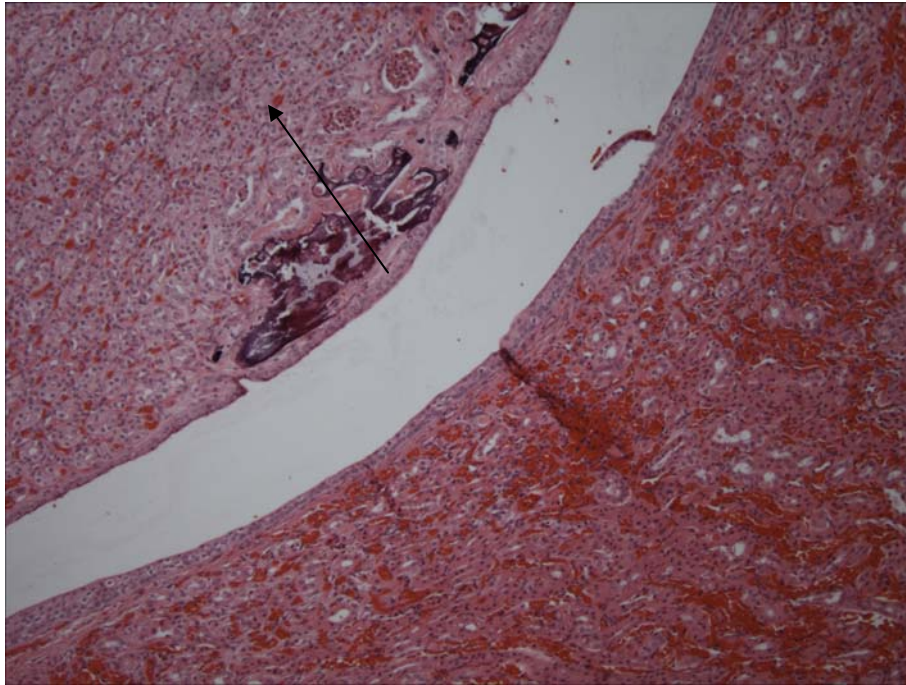


Figure 5. Kidney. There is focal mineralization. Occasional tubules contains aggregated, sloughed epithelial cells (cellular casts) (arrow).

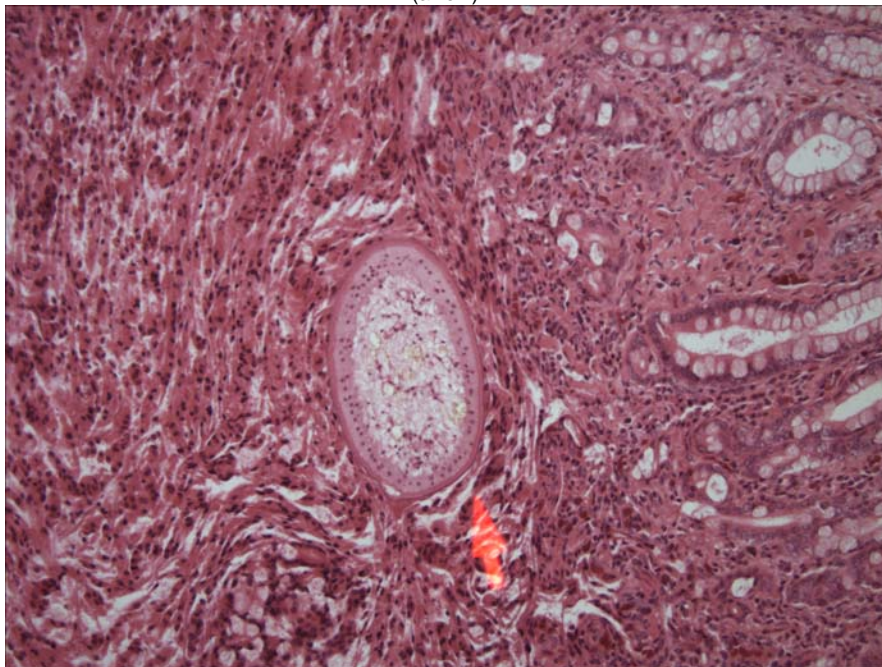


Figure 6. Intestine. Within the lumen, there is a larval cestode (arrow).

DATE:
7 April 2005

REPORTING PATHOLOGIST:
DavidS. Rotstein, DVM, MPVM, DACVP

**CETACEAN NECROPSY REPORT:
Pilot Whale Stranding, NC 15/16 Jan 2005**

Field ID: CTH001
Accession Number: 05-24C
Date: 15 Jan 2005
Species: Minke Whale (Balaenoptera acutorostrata)
Sex: M (calf)
Location: NC
TL: 284.0 cm
TW: 211.4 kg

**GROSS REPORT
REPORTING INSTITUTION: VAQS**

History: The whale was called in to the NC Marine Mammal Stranding Network on 15 Jan 2005 on the same day as a pilot whale mass stranding farther south on the NC outer banks. The whale was alive upon initial observation and sedative (Diazepam) was administered IM followed later by an IP injection of Euthanasol®.

External Exam: The whale was an immature male (probably young on the year) and was extremely emaciated. There were several parallel wrinkles perpendicular to the long axis of the body just caudal to the insertion of the flukes on both the dorsal and ventral peduncle. Originally, these were thought to be possible line impressions, but further examination prior to the necropsy revealed that the marks were natural. There was minor abrasion to the right eye area most likely associated with stranding and carcass manipulation. The umbilicus was completely healed and the fins were not floppy. Rostral and mandibular hairs were obvious. No obvious fetal lines or folds were observed.

Internal Exam:

Blubber: Mild sub-dermal emphysema along scapula and ribs on both right and left sides. There appeared to be serous atrophy of fat in the nuchal area cranial to the scapulae. The blubber and muscle surrounding the euthanasia injection site was discolored and appeared to be necrotic (?). Blubber appeared to be healthy.

Musculoskeletal: Locomotor muscle was collapsed. Synovial fluid in left humeral joint was thickened and straw-colored. Mild hemorrhage around brachial plexus on left side and on the cranial portion of the left epaxial muscle.

Lymph Nodes: Lymph nodes all seemed small, inactive, and the pre-scapular lymph nodes were surrounded by clear edematous tissues (serous fat atrophy?).

CNS: NVL

Heart: Ventricular fat had serous fat atrophy; valves and tissues NVL, ductus arteriosus and foramen ovale were closed.

Lungs: White froth in bronchi of both lungs; left lung was completely sopping and dark red, right lung was 75% dark red, hemorrhagic and sopping, only 25% of the cranial portion of the right lung appeared normal.

GI Tract: Duodenum is quite long. Main and fore-stomach empty except for small amount of sand (2-3 tablespoons) and mucus in for and tan fluid in main. Sphincter between main and fore-stomachs loose and open (2cm diameter). Spleen was triangular in shape, but tissue appeared normal; pancreas NVL; 100 ml of mport wine colored serosanguinous fluid in abdominal cavity.

Liver: NVL

Kidney/Bladder: Kidneys NVL; bladder had 12cc of urine which we collected.

Reproductive Tract: immature, NVL

Parasites: none observed; head collected whole and not examined for parasites

Summary (VAQS): This animal appeared to be healthy, but extremely emaciated. It was the length of a newborn, but weighed approximately one third of the estimated weight at birth. It is likely that this was a dependent calf. The umbilical arteries were closed, but the umbilical vein was open to 3mm. The condition of the lungs was the only obvious pathology. The stranding event may have affect the lungs or it may have been pre-existing.

ANCILLARY FINDINGS

N/A

**TISSUES/SAMPLES RECEIVED
REPORTING INSTITUTION: UNIVERSITY OF TENNESSEE**

Received is one bag of formalin labeled as "CTH 001 10% Formalin" received 1 Feb 2005. There are three cassettes and 23 free tissues. Cassettes are labeled as "Pre-scapular Lymph Node", "Vent Lesion (1)", and "Vent Lesion (2)"; representative sections are placed in cassettes 1 and 2, respectively. Representative sections of remaining tissues are placed in Cassettes 1-9.

**MICROSCOPIC FINDINGS
REPORTING INSTITUTION: UNIVERSITY OF TENNESSEE**

Pre-Scapular Lymph Node (slide 1): Lymphocytes are reduced in number and there are regions of lymphocyte loss and increased macrophages.

Large Intestine (slide 1): Mucosal-associated lymphoid tissue is moderately hyperplastic. There is artifactual loss of greater than 90% of the mucosal epithelium.

Aorta (slide 1): No significant histologic findings (NSF).

Kidney (slide 2): There is occasional expansion of perivascular spaces around small-caliber arteries.

Vent Lesion: Blubber and Panniculus Muscle (slide 2): There is diffuse intracytoplasmic swelling of epithelial cells (hydropic change vs. artifact). There is edema and multifocal myofibers loss and deposition of collagen (fibrosis).

Lung (slide 3): NSF.

Heart (slide 3): NSF.

Trachea (slide 3): NSF.

Skeletal Muscle (slides 3 and 6): NSF.

Oral Cavity (slide 5): There is multifocal cytoplasmic swelling of epithelial cells (hydropic change) with occasional clefting. There is submucosal edema with a few foamy macrophages scattered within the expanded stroma.

Urinary Bladder (slide 5): NSF.

Small Intestine (slide 5): NSF.

Spleen (slide 5): Periarteriolar lymphoid sheaths are mildly depleted. Reticuloendothelial cells (macrophages) are prominent.

Lymph Node, NOS (slide 5): There is moderate lymphoid hyperplasia. There are numerous, artifactual pale clefts throughout the cortex and medulla.

Large Intestine (slide 5): NSF.

Esophagus (slide 5): There is focal, submucosal gland, periductular and ductular infiltration by lymphocytes and plasma cells.

Thymus (slide 6): There is moderate lymphoid depletion. There is artifactual formation of clear clefts throughout the cortex and medulla.

Thyroid Gland (slide 6): Approximately 30% of follicular lumina are filled with homogenous eosinophilic colloid. Remaining follicular acini are collapsed and lined by a single layer of cuboidal cells with clear cytoplasm. There is expansion of perivascular spaces.

Pancreas (slide 7): There is artifactual formation of clear clefts throughout the parenchyma.

Stomach, 2nd Compartment (slide 7): NSF.

Atrium (slide 8): NSF.

Liver (slide 8): There is artifactual formation of clear clefts throughout the parenchyma.

Spinal Cord (slide 9): There is artifactual formation of clear clefts throughout the neuropil.

MORPHOLOGIC DIAGNOSES

Hematopoietic/Lymphoreticular Systems:

Thymus: Lymphoid depletion (involution), moderate.

FINAL DIAGNOSES/INTERPRETATIVE SUMMARY

Thymic depletion.

The cause of stranding was not evident, though the presence of thymic depletion and gross findings of emaciation are consistent with a calf that was either separated or abandoned. There are clear clefts in many tissues which are likely artifactual as a result of the effects of ambient temperature and autolysis.

DATE:
06 Apr 05

REPORTING PATHOLOGIST:
David S. Rotstein, DVM, MPVM, DACVP

Appendix X. Summary of gross findings for 27 pilot whales, 2 dwarf sperm whales, and 1 minke whale calf. Cetaceans with bolded Field ID and systems have significant gross findings. n/e= tissue not examined, n/r = findings not recorded, NVL = no visible lesions

Field ID	RT12	RT13	RT19	RT20	RT22	RT24	RT47	RT48	RT49	RT50
Cardiovascular System	NVL	NVL	NVL	n/r	n/r	n/r	NVL	n/r	n/r	NVL
Respiratory System & Sinuses	Pulmonary congestion	1.Pulmonary granuloma, focal 2.Pterygoid sinus metazoans	1.Pulmonary congestion 2.Pterygoid sinus metazoans & mucosal hyperplasia	Pterygoid sinus metazoans & hematoma	Pterygoid sinus metazoans	Pterygoid sinus metazoans	1.Pterygoid sinus metazoans 2.Pulmonary edema	1.Pulmonary edema 2.Pterygoid sinus Mmetazoans	1.Pulmonary edema 2.Pterygoid sinus metazoans	NVL
Nervous System	n/r	n/r	n/r	Congestion	n/r	Subdural hemorrhage	Congestion	n/r	Post-mortem emphysematous change	Congestion
Lymphoreticular System	NVL	Edema	NVL	n/r	n/r	n/r	Congestion	n/r	NVL	NVL
Digestive System	n/r	n/r	n/r	Verminous esophagitis	n/r	Verminous esophagitis	Verminous esophagitis	Verminous Gastritis	Verminous esophagitis	Verminous Enteritis
Musculoskeletal System	NVL	NVL	n/r	n/r	n/r	n/r	NVL	n/r	NVL	Occipital joint: spondylosis & osteonecrosis
Endocrine System	n/r	NVL	n/r	n/r	n/r	n/r	NVL	n/r	n/r	NVL
Urinary System	n/r	NVL	NVL	n/r	n/r	n/r	NVL	n/r	n/r	NVL
Reproductive System	NVL	NVL	Peri-uterine monorygma	NVL	n/r	Pregnant	NVL	Pregnant	Pregnant	Pregnant
Hepatobiliary System	Congestion	NVL	n/r	n/r	Granulomatous Hepatitis	n/r	NVL	n/r	NVL	NVL
Body as a Whole / Body Cavity	n/r	NVL	NVL	n/r	n/r	n/r	NVL	n/r	NVL	NVL
Integumentary System	n/r	NVL	Healed fishery interaction	Healed fishery interaction	Healed fishery interaction	Healed fishery interaction	1.Rake Marks 2.Verminous Panniculitis	n/r	n/r	NVL

Appendix X. Continued, page 2 of 3

Field ID	RT54	RT57	RT59	RT63	RT66	RT67	RT68	RT69	RT71	RT72	RT74
Cardiovascular System	NVL	NVL	Heart: a.Serous atrophy b.Fibrosis c.ventricular attenuation	n/r	NVL	n/r	n/r	n/e	NVL	n/e	n/e
Respiratory System & Sinuses	1.Pulmonary edema 2.Pterygoid sinus metazoans & focal hemorrhage	Pterygoid sinus metazoans	1.Pulmonary edema 2.Pterygoid sinus metazoans & focal hemorrhage	Pterygoid sinus metazoans	1.Verminous pneumonia 2.Pterygoid sinus metazoans	n/r	1.Pulmonary edema 2.Pterygoid sinus metazoans & fluid	Pterygoid sinus metazoans	1.Pulmonary edema 2.Right pterygoid sinus medial hematoma	n/r	Pterygoid sinus metazoans
Nervous System	NVL	n/r	Congestion	n/r	n/r	n/r	Congestion	n/r	Congestion	Con- gestion	n/r
Hemato / lymphoreticular System	Congestion	NVL	NVL	n/e	Edema	n/r	Edema	n/e	NVL	n/e	n/e
Digestive System	Verminous gastroenteritis	NVL	Verminous esophogastritis	n/e	NVL	n/r	Verminous esophogastritis	Verminous esophogastritis	NVL	n/e	n/e
Musculoskeletal System	n/r	NVL	n/r	Fractured Mandible	NVL	n/r	NVL	n/e	NVL	n/e	n/e
Endocrine System	Adrenocortical hemorrhage (congestion), Bilateral	n/e	NVL	n/e	NVL	n/r	n/r	n/e	NVL	n/e	n/e
Urinary System	NVL	Pericyclic abscess	NVL	n/e	NVL	n/r	NVL	n/e	NVL	n/e	n/e
Reproductive System	NVL	NVL	NVL	n/e	Pregnant	n/r	Perivoarian monorygma	n/e	NVL	n/e	n/e
Hepatobiliary System	NVL	NVL	NVL	n/e	NVL	n/r	n/r	n/e	NVL	n/e	n/e
Body as a Whole / Body Cavity	Single Metazoan Cyst, Body Wall	n/r	n/r	n/e	NVL	n/r	n/r	n/e	NVL	n/e	n/e
Integumentary System	n/r	Healed fishery interaction	Verminous panniculitis	n/e	NVL	n/r	Ulceration, Focal	n/e	NVL	n/e	n/e

Appendix X. Continued, page 3 of 3

Field ID	RT102	RT103	RT104	RT105	RT106	RT107	KMS379	KMS380	CTH001
Cardiovascular System	NVL	n/r	NVL	NVL	n/r	NVL	n/r	NVL	Serous atrophy
Respiratory System & Sinuses	1. Granulomatous pneumonia, focal 2. Pterygoid sinus metazoans & hematoma	Pterygoid sinus metazoans & hematoma	Pterygoid sinus metazoans & hematoma	1. Verminous pneumonia 2. Pterygoid sinus metazoans & hematoma	1. Pulmonary fibrosis (focal) 2. Pterygoid sinus metazoans	1. Pulmonary Edema 2. Pterygoid sinus metazoans	1. Pulmonary edema 2. Pterygoid sinus metazoans & hematoma	1. Pulmonary edema 2. Pterygoid sinus hemorrhage (mild)	Pulmonary edema
Nervous System Hemato / lymphoreticular System	n/r	Post-mortem intravascular gas bubble	Focal Subdural Hemorrhage and Congestion	Congestion	Congestion	1. Congestion 2. Post-mortem intravascular gas bubble	1. Congestion 2. Focal hemorrhage	Congestion	NVL
Digestive System	Verminous esophagitis	n/r	NVL	Peri-gastric Abscess	n/r	NVL	Verminous Gastritis	Verminous Esophagitis	Empty
Musculoskeletal System	n/r	n/r	NVL	NVL	n/r	NVL	n/r	NVL	NVL
Endocrine System	n/r	n/r	NVL	NVL	n/r	NVL	n/r	NVL	n/r
Urinary System	n/r	n/r	NVL	NVL	n/r	Pericystic parasitism	NVL	NVL	NVL
Reproductive System	n/r	NVL	NVL	Monorhygma	Pregnant	NVL	n/r	NVL	NVL
Hepatobiliary System	Granulomatous hepatitis	n/r	NVL	NVL	n/r	NVL	Hepatic congestion	NVL	NVL
Body as a Whole / Body Cavity	n/r	Abdominal granulomas	NVL	Abdominal granulomas	n/r	NVL	NVL	NVL	emaciation, serous atrophy of fat
Integumentary System	Verminous panniculitis	Peri-melon fat necrosis	NVL	Healed fishery interaction	n/r	Healed fishery interaction	Ventral bruising	NVL	NVL

Appendix XI. Summary of gross and histopathological results of acoustic tissues and brain from pilot whales and dwarf sperm whales that stranding during UMESE0501Sp, including all specimens for which cranial tissues were collected (RT57, 63, 102). n/r = not recorded, n/c=not collected, NVL = no visible lesion, NSF = no significant finding, n/a = not applicable.

Field ID	Extramandibular fat		Intramandibular Fat		Auditory meatus		Peribullar acoustic fat		Peribullar soft tissue	
	Gross	Histo	Gross	Histo	Gross	Histo	Gross	Histo	Gross	Histo
RT 12	n/r	n/c	n/r	n/c	n/c	n/c	n/r	n/c	n/r	n/c
RT 13	n/r	n/c	n/r	n/c	n/c	n/c	n/r	n/c	n/r	n/c
RT 19	n/r	n/c	n/r	n/c	n/c	n/c	n/r	n/c	n/r	n/c
RT 20	NVL	n/c	hemor. (lt, rt)	n/c	missing	n/c	n/r	n/c	n/r	n/c
RT 22	n/r	n/c	n/r	n/c	n/c	n/c	n/r	n/c	n/r	n/c
RT 24	n/r	n/c	n/r	n/c	n/c	n/c	n/r	n/c	n/r	n/c
RT 47	n/r	n/c	congestion	n/c	perimeatal reddening (rt), NVL (lt)	n/c	NVL	n/c	n/r	n/c
RT 48	NVL	NSF	focal hemor. (rt)	perivascular hemor.	NVL	NSF	NVL	NSF	focal hemor. (lt, rt)	NSF
RT 49	n/r	n/c	hemor. (lf, rt)	n/c	NVL	n/c	NVL	n/c	n/r	n/c
RT 50	NVL	NSF	NVL	NSF	NVL	NSF	NVL	NSF	NVL	peribulitis
RT 54	n/r	n/c	n/r	n/c	NVL (lf), missing (rt)	n/c	NVL	n/c	n/r	n/c
RT 59	NVL	NSF	NVL	NSF	NVL	NSF	NVL	NSF	NVL	NSF
RT 66	n/r	n/c	n/r	n/c	n/r	n/c	n/r	n/c	n/r	n/c
RT 67	n/r	n/c	n/r	n/c	n/r	n/c	n/r	n/c	n/r	n/c
RT 68	NVL	mild perivascular edema, hemor.	NVL	mild perivascular edema, hemor.	n/r	n/c	n/r	n/c	n/r	n/c
RT 69	n/r	n/c	n/r	n/c	n/r	n/c	n/r	n/c	n/r	n/c
RT 71	NVL	n/c	presumptive hemor.	NSF	petechiae (rt), perimeatal congestion	NSF	NVL	n/c	NVL	NSF
RT 72	NVL	NSF	tawny brown (rt), focal hemor. (lt)	perivascular hemor. and serum	n/r	n/c	NVL	NSF	superficial hemor. (lt)	n/c
RT 103	n/r	NSF	miliary supponification	autolysis of fat (post-mortem)	n/r	n/c	n/r	n/c	n/r	n/c
RT 104	n/r	n/c	focal hemor. (lt)	n/c	NVL	n/c	NVL	n/c	n/r	n/c
RT 105	n/r	n/c	hemor. (lt)	n/c	perimeatal transudate (rt)	n/c	NVL	n/c	n/r	n/c
RT 106	NVL	NSF	focal reddening (rt)	NSF	n/r	n/c	n/r	n/c	superficial focal hemor. (lt)	superficial focal hemor.
RT 107	NVL	NSF	NVL	perivascular hemor., serum	n/r	n/c	n/r	n/c	n/r	n/c
KMS 379	n/r	n/c	hemor. (lt, rt)	n/c	NVL	n/c	n/r	n/c	n/r	n/c
KMS 380	n/r	n/c	hemor. (rt)	n/c	NVL	n/c	n/r	n/c	congestion (rt)	n/c

Field ID	Peribullar sinus		Pterygoid sinus		Melon		Brain	
	Gross	Histo	Gross	Histo	Gross	Histo	Gross	Histo
RT 12	n/r	n/c	NVL	n/c	n/r	n/c	n/r	NSF
RT 13	n/r	n/c	metazoans	n/c	n/r	n/c	n/r	myelin sheath swelling, hypoxic change
RT 19	n/r	n/c	mucosal hyperplasia (rt), metazoans (lt)	n/c	n/r	n/c	n/r	n/r
RT 20	n/r	n/c	metazoans, hematoma (lt, rt)	n/c	n/r	n/c	congestion	NSF
RT 22	n/r	n/c	light metazoans (lt, rt)	n/c	n/r	n/c	n/r	myelin sheath swelling, hypoxic change
RT 24	n/r	n/c	mucosal hyperplasia, metazoans (lt, rt)	n/c	n/r	n/c	subdural hemor. and congestion	leptomeningeal hemor., spongiosis, hypoxic change
RT 47	metazoans (lt, rt)	n/c	metazoans (lt, rt)	sinusitis	n/r	n/c	congestion	en/cephalitis
RT 48	NVL	NSF	metazoans (lt, rt)	n/c	NVL	n/c	NVL	NSF
RT 49	metazoans (rt)	n/c	metazoans (lt, rt)	n/c	NVL	n/c	post-morem emphysematous change	NSF
RT 50	metazoans (lt)	n/a	NVL	verminous sinusitis	NVL	n/c	vascular congestion	NSF
RT 54	n/r	n/c	metazoans (lt, rt), focal hemor. (lt)	n/c	n/r	n/c	NVL	NSF
RT 59	NVL	NSF	fluid (lt), metazoans (lt, rt)	verminous sinusitis	n/r	n/c	congestion	perivascular hemosiderin accumulation (prior hemor.)
RT 66	n/r	n/c	metazoans (lt, rt)	n/c	n/r	n/c	n/r	NSF
RT 67	n/r	n/c	n/r	n/c	n/r	n/c	n/r	n/c
RT 68	n/r	n/c	metazoans (lt, rt), fluid (lt)	verminous sinusitis	n/r	n/c	vascular congestion,	myelin sheath swelling, hypoxic change
RT 69	n/r	n/c	metazoans (lt, rt)	n/c	n/r	n/c	n/r	perivascular edema
RT 71	fluid	n/a	medial hematoma (rt)	congestion of vascular rete	n/r	n/c	congestion	NSF
RT 72	metazoans (rt)	n/c	n/r	n/c	n/r	n/c	congestion	focal en/cephalitis
RT 103	~2 mm clot	clot (post-mortem)	metazoans (lt, rt)	sinusitis	fat n/ecrosis		post-mortem intravascular gas bubble, mild ventricular hemor. (rt, lt)	mild en/cephalitis
RT 104	metazoans (rt)	n/c	metazoans, hematoma (lt, rt)	n/c	n/r	n/c	subdural hemor. and congestion	NSF
RT 105	metazoans (lt, rt)	n/c	metazoans, hematoma (lt, rt)	n/c	NVL	n/c	congestion	focal meningeal en/cephalitis
RT 106	n/r	n/c	metazoans (lt, rt)	verminous sinusitis	n/r	n/c	congestion	congestion
RT 107	n/r				NVL	NSF	congestion, post-mortem intravascular gas bubble	NSF
KMS 379	hemor. (rt)	n/c	hemor. and hematoma (lt, rt)	vascular congestion, hemor.	n/r	n/c	congestion, focal hemor. lt ventral cerebrum	NSF
KMS 380	n/r	n/c	mild hemor. (rt)	n/c	n/r	n/c	congestion	NSF

Appendix XII. Summary of histologic findings for 25 pilot whales, 2 dwarf sperm whales, and 1 minke whale calf from UMSE0501Sp. Specimens with bolded ID and systems are those with significant disease processes. n/e = tissue not examined, NSF = no significant histologic findings.

Field ID	RT12	RT13	RT19	RT20	RT22	RT24	RT47	RT48	RT49	RT50
Cardiovascular System	Cardiomyocyte necrosis	NSF	NSF	n/e	n/e	n/e	NSF	NSF	Atrial fibrosis	Epicarditis
Respiratory System & Sinuses	Verminous pneumonia	1.Congestion 2.Pulmonary hemorrhage	Pulmonary edema	n/e	n/e	n/e	Pterygoid sinusitis	Pulmonary edema	Broncho-alveolitis	A.Lung: 1.Eosinophilic interstitial pneumonia 2.Alveolar & bronchiolar histiocytosis B. Pterygoid sinus: Verminous sinusitis
Nervous System	NSF	Hypoxic change	NSF	NSF	Hypoxic change	1.Subdural Hemorrhage 2.Spongiosis 3.Hypoxic Change	1.Hypoxic change 2.Encephalitis, minimal	NSF	NSF	NSF
Hemato / lymphoreticular System	NSF	Edema	Edema & histocytosis	n/e	n/e	n/e	NSF	Granulomatous lymphadenitis	NSF	NSF
Digestive System	Enteritis	NSF	Gastric ulcer	n/e	n/e	Verminous gastritis	NSF	Verminous gastritis	NSF	1.Verminous Enteritis 2.Stomatitis
Musculoskeletal System	NSF	NSF	NSF	n/e	n/e	n/e	NSF	NSF	NSF	1.Occipital joint: fibrosis & lymphoplasmacytic inflammation 2.Right occipital condyle-osteonecrosis
Endocrine System	NSF	NSF	NSF	n/e	n/e	n/e	NSF	NSF	NSF	NSF
Urinary System	NSF	Interstitial nephritis	NSF	n/e	n/e	n/e	NSF	NSF	Cystitis	Intraluminal mineral
Reproductive System	NSF	Endometritis	1.Endometritis 2.Focal aneurysmal dilation 3.Angiopathy	n/e	n/e	n/e	1.Balanitis 2.Testicular involution	NSF	NSF	NSF
Hepatobiliary System	Congestion	Congestion	NSF	n/e	1.Granulomatous hepatitis 2.Portal fibrosis	n/e	NSF	NSF	NSF	1.Congestion (early telangiectasia) 2.Subcapsular venular dilation 3.Biliary hyperplasia
Body as a Whole / Body Cavity	NSF	NSF	NSF	n/e	Abdominal granuloma	n/e	NSF	NSF	NSF	NSF
Integumentary System	NSF	Fibrosis	NSF	n/e	n/e	n/e	NSF	NSF	NSF	NSF

Field ID	RT54	RT57	RT59	RT66	RT67	RT68	RT69	RT71	RT72	RT102
Cardiovascular System	NSF	n/e	Fibrosis	NSF	n/e	Fibrosis (focal)	n/e	n/e	n/e	NSF
Respiratory System & Sinuses	NSF	n/e	A.Lung: bronchitis B.Pterygoid sinus: verminous sinusitis	Verminous pneumonia	n/e	NSF	n/e	n/e	n/e	Fibrosis
Nervous System	NSF	n/e	Perianglioneuritis (mild, focal)	NSF	Perivascular edema	Hypoxic change	Perivascular edema	NSF	Encephalitis, focally extensive	n/e
Hemato / lymphoreticular System	Congestion	NSF	Lymphadenitis & fibrosis	Granulomatous lymphadenitis	n/e	Edema & congestion	n/e	n/e	n/e	Lymphoid Depletion
Digestive System	NSF	n/e	Tongue & oral cavity: glossitis & stomatitis	Gastritis	n/e	NSF	n/e	n/e	n/e	n/e
Musculoskeletal System	NSF	n/e	NSF	NSF	n/e	NSF	n/e	n/e	n/e	n/e
Endocrine System	NSF	n/e	A.Thyroid gland: thyroid follicular cysts B.Pituitary gland: fibrosis, mineralization	NSF	n/e	NSF	n/e	n/e	n/e	n/e
Urinary System	Congestion	n/e	Membranous glomerulopathy	Cystitis	n/e	Chronic Infarct	n/e	n/e	n/e	n/e
Reproductive System	NSF	Testicular involution	NSF	NSF	n/e	NSF	n/e	n/e	n/e	NSF
Hepatobiliary System	1.Congestion 2.Biliary hyperplasia	n/e	1.Periportal fibrosis, hepatitis, & hemosiderosis 2.Hemosiderosis (sinusoidal & hepatocellular) 3.Centrilobular venular fibrosis	NSF	n/e	1.Periportal hepatitis 2.Focal phlebitis	n/e	n/e	n/e	NSF
Body as a Whole / Body Cavity	NSF	n/e	NSF	NSF	n/e	NSF	n/e	n/e	n/e	NSF
Integumentary System	NSF	n/e	Mammary gland: 1.fibrosis 2.mastitis	NSF	n/e	A.Mammary gland: mastitis B.Left medial canthus: fibrosis	n/e	n/e	n/e	NSF

Field ID	RT103	RT104	RT105	RT106	RT107	KMS379	KMS380	CTH001
Cardiovascular System	Aortitis	NSF	NSF	NSF	NSF	Cardiomyocyte disarray & wavy fiber formation	NSF	NSF
Respiratory System & Sinuses	Pterygoid sinusitis	Pulmonary edema	Pulmonary edema	A.Lung: fibrosis (focal) B.Pterygoid sinus: verminous sinusitis	Tracheitis	A.Lung: 1.Pulmonary hemorrhage 2.Interstitial fibrosis B.Pterygoid sinus/acoustic fat: hemorrhage & serum exudation	1.Pulmonary hemorrhage 2.Lipid pneumonia, subpleural	NSF
Nervous System	Encephalitis, multifocal, minimal	NSF	NSF	NSF	NSF	NSF	NSF	NSF
Hemato / lymphoreticular System	Plasmacytosis & histiocytosis	Lymphoid hyperplasia (pseudolymphomatous) (focal)	Anthracosis	Granulomatous lymphadenitis	Draining lymph node	Histiocytosis & hemosiderosis	Hyperplasia	Thymic involution
Digestive System	NSF	NSF	Gastritis	NSF	Stomatitis	Stomatitis	Intraluminal cestodes	NSF
Musculoskeletal System	Contraction band formation	Mineralization	Interstitial myositis	NSF	NSF	NSF	NSF	NSF
Endocrine System	NSF	NSF	NSF	NSF	NSF	NSF	NSF	NSF
Urinary System	1.Interstitial nephritis 2.Capsulitis	NSF	NSF	NSF	NSF	Tubuloproteinosis	Mineralization & cast formation	NSF
Reproductive System	NSF	Cyclical involution	Uterus: 1.Endometritis 2.Vasculopathy	Inactive	Endo-metritis	NSF	1.Cystic endometrial hyperplasia & mucometra 2.Adenomyosis	NSF
Hepatobiliary System	NSF	NSF	Periportal fibrosis & hepatitis	Portal hemosiderosis & biliary hyperplasia	NSF	1.Congestion & sinusoidal hemosiderosis & erythrophagocytosis 2.Hepatocellular atrophy	NSF	NSF
Body as a Whole / Body Cavity	Abdominal granuloma	NSF	Abdominal granuloma	NSF	NSF	NSF	NSF	NSF
Integumentary System	Peri-Melon fat: collagen necrosis	NSF	NSF	NSF	NSF	NSF	NSF	NSF

Appendix XIII. Bacteria cultured from the whales involved in UMESE0501Sp. H=heavy, M=moderate, L=light.

Field ID	Blowhole Culture									Genital Culture						Abscess Culture
	Blowhole Culture	Aeromonas hydrophilia/caviae	Aeromonas sobria	Burkholderia cepacia	Enterobacter aerogenes	E. coli	Klebsiella pneumoniae	Pseudomonas fluorescens	Serratia fonticola	Genital Culture	Aeromonas hydrophilia/caviae	Aeromonas sobria	Enterobacter sp	E. coli	Pseudomonas fluorescens	Aeromonas hydrophilia/caviae
RT12	Yes			M			H		Yes	L				M		
RT13	No								No							
RT19	No								No							
RT20	No								No							
RT21	No								No							
RT22	No								No							
RT24	No								No							
RT47	Yes	M	H				M		Yes	H						
RT48	Yes			M	M		M		Yes	M				M		
RT49	Yes	H	H					H	Yes		H					
RT50	Yes	H							Yes			H				
RT54	Yes	M	M				H		Yes	H				H		
RT57	No								No							
RT59	Yes		H			M			Yes	M						
RT63	No								No							
RT66	No								No							
RT67	No								No							
RT68	Yes	H						H	Yes	M			H			
RT69	No								No							
RT71	No								No							
RT72	No								No							
RT74	No								No							
RT89	No								No							
RT100	No								No							
RT101	No								No							
RT102	No								No							
RT103	No								No						H	
RT104	No								No							
RT105	No								No							
RT106	No								No							
RT107	Yes	H							Yes					M		
KMS379	No								No							
KMS380	No								No							
CTH001	No								No							

Appendix XIV. Parasites found in pilot whales (RT) and dwarf sperm whales (KMS) sampled during UMESE0501Sp.

Field ID	Host Location	Helminth Identification	Number of Helminths
No ID	Esophagus	Anisakis sp.	7
RT12	Stomach	Anisakis sp.	1
RT15	Stomach	Anisakis sp.	19
RT19	Stomach	Anisakis sp.	135
	Stomach	Spirurid? nematode A	1
RT20	Stomach	Anisakis sp.	120
RT22	Stomach	Anisakis sp.	32
RT24	Stomach	Anisakis sp.	34
RT47	Stomach	Anisakis sp.	129
	Pterygoid	Stenurus sp.	1000+
	Pterygoid	Nasitrema sp.	10
RT48	Stomach	Anisakis sp.	120
RT49	Stomach	Anisakis sp.	123
RT50	Stomach	Anisakis sp.	208
	GI	Bolbosoma capitatum	1
	GI	Trigonocotyle lintoni	1
RT54	Stomach	Anisakis sp.	290
	Nasal	Stenurus sp.	200+
RT57	Stomach	Anisakis sp.	111
RT59	Stomach	Anisakis sp.	86
RT63	Stomach	Anisakis sp.	463
RT66	Stomach	Anisakis sp.	63
RT67	Stomach	Anisakis sp.	5
	Stomach	Braunia sp.	1
RT68	Stomach	Anisakis sp.	48
RT69	Stomach	Anisakis sp.	107
RT71	Stomach	Plant material	1
RT72	Stomach	Anisakis sp.	87
	Stomach	Spirurid? nematode A	1
RT74	Stomach	Anisakis sp.	39
RT102	Stomach	Anisakis sp.	111
RT103	Stomach	Anisakis sp.	178
RT104	Stomach	Anisakis sp.	163
	Stomach	Trichostrongylid nematodes	2
RT105	Stomach	Anisakis sp.	139
RT106	Stomach	Anisakis sp.	32
RT107	Stomach	Anisakis sp.	153
KMS379	Stomach	Anisakis sp.	198
KMS380	Stomach	Anisakis sp.	219

Appendix XV. *Monorygma* and *Phyllobothrium* parasite loads found in pilot whales (RT) and dwarf sperm whales (KMS) sampled during UMESE0501Sp. n/r = not recorded.

Field ID	<i>Monorygma</i>			<i>Phyllobothrium</i>		
	Present	Location	Relative Quantity	Present	Location	Relative Quantity
RT12	n/r			n/r		
RT13	Yes	Near bladder	Light	n/r		
RT19	Yes	Uterus mesentery	Heavy	n/r		
RT19	Yes	Ventral blubber	n/r	n/r		
RT20	n/r			n/r		
RT22	n/r			n/r		
RT24	n/r			n/r		
RT47	n/r			n/r		
RT48	Yes	Abdominal cavity	n/r	Yes	Peduncle blubber	n/r
RT49	Yes	Abdominal cavity	Light	None		
RT50	Yes	Near uterus	n/r	n/r		
RT54	Yes	Abdominal wall	Light	n/r		
RT57	Yes	Abdominal wall	n/r	n/r		
RT59	Yes	Urogenital region	Heavy	Yes	Ventral blubber	Moderate
RT63	n/r			n/r		
RT66	Yes	Abdominal wall	Light	n/r		
RT67	n/r			n/r		
RT68	Yes	Below L ovary	n/r	n/r		
RT69	n/r			n/r		
RT71	n/r			n/r		
RT72	n/r			n/r		
RT74	n/r			n/r		
RT102	n/r			n/r		
RT103	Yes	Abdominal cavity	Heavy	n/r		
RT104	n/r			n/r		
RT105	Yes	Around reprod. tract	Heavy	Yes	Blubber	Light
RT106	n/r			n/r		
RT107	Yes	Abdominal cavity	Light	Yes	Ventral blubber	Light - Moderate
RT107	Yes	Bladder	Heavy			
KMS379	n/r			Yes	Ventral blubber	Heavy
KMS380	None			None		
CTH001	n/r			n/r		

Appendix XVI. Reported individual or multiple strandings of pilot whales, dwarf and pygmy sperm whales, and minke whales. The location of stranding, date of stranding, number of animals, gross and histologic findings and cause of death are indicated when they were reported.

Species	Location	Date	Number & Sex	Gross Necropsy / Histologic Evaluation	Cause of Death	Citation
Pilot Whales						
Long-finned	Sable Island, Nova Scotia	Dec-76	130 (65M, 34F)	Not indicated	Unknown	Geraci and St. Aubin 1977
Short-finned	San Clemente Is., CA	Jan-71	28 (6M, 21F)	Gastrointestinal tract examined	Natural event: Tide, beach, food availability	Hall et al. 1971
Short-finned	Hawaiian Archipelago	Jun-57 Oct-58 Oct-58 May-59 Jan-89	2 24 12 28 4	Not indicated for all strandings	Speculative cause: geomagnetic and geophysical factors	Mazzuca et al. 1999
Long-finned	Tryphena Harbour, New Zealand		38	Not indicated	Not determined	Dawson et al. 1985
Short-finned	Aoshima Beach, Miyazaki Pref., Japan	May-83	12	Gross -- Peribullar and perineural Nasitrema. Histo -- Degeneration of cranial nerve eight	Paristogenic eighth cranial nerve neuropathy.	Morimitsu et al. 1987
Long-finned	MA, CN, NY	Nov-82 Dec-86 Dec-86 Oct-87 Sep-89 Dec-90 Sep-91 Sep-91 Sep-91 Oct-91 Dec-91 Dec-92 Jul-98 Nov-93 Jul-94	66 21 37 1 1 57 26 1 13 9 26 38 4 1 1	Histologic findings reported indicate "incidental lesions", lymphoid depletion in 50% of sample population, and morbillivirus infection in a calf	Morbillivirus infection Serologic evidence of morbillivirus infection.	Duigan et al. 1995
Short-finned	FL - Little Talbot Is.	Jul-86 Aug-86 Sep-86 Apr-91 Feb-94	33 17 2 30 30			

Appendix XVI continued

Species	Location	Date	Number & Sex	Gross Necropsy / Histologic Evaluation	Cause of Death	Citation
Short-finned	North Atlantic	1980	1	Histo -- Bacterial bronchopneumonia	Streptococcal bronchopneumonia	Higgins et al. 1980
Long-finned	MA, Cape Cod	1620 – 1990	5670 in 87 strandings	Not indicated	Not determined	McFee 1990
Short-finned	FL	Jul-86	33	Gross -- Peribullar metazoans. Histo -- Gastritis, pneumonia, myocarditis, fatty livers, depletion of lymphoid organs	Not determined	Bossart et al.,1991
Pygmy and Dwarf Sperm Whales						
Pygmy and dwarf	Southeast U.S.	N/I	N/I	Gross -- Heart: myocardial fibrosis, right ventricular dilation and flaccidity. Liver: chronic passive congestion. Stomach: gastric nodules (verminous). Blubber & skeletal Muscle: ncysted parasites. Histo -- Heart: myocardial fibrosis, interstitial fibrosism, myofiber disarray. Liver: Centrilobular congestion. Stomach: verminous gastritis	Congestive heart failure	Bossart et al. 1985
Pygmy	NC	Nov-02	1	Gross -- struvite penile urethral calculi, verminous panniculitis, verminous gastritis. Histo -- urethrobalanitis, gastritis, panniculitis, lymphoid depletion, pulmonary congestion	Not determined	Harms et al. 2004
Minke Whale						
Minke Whale	Italy	1993	1	Histo: pneumonia, encephalitis, enteritis, lymphadenitis, pancreatitis, cystitis, orchitis, tracheitis	Multifactorial; anti-canine distemper virus 1:16	DiGuardo et al. 1995

Appendix XVII. Reviewers of cases (histology slides).

Gregory D. Bossart, VMD, Ph.D.
Director and Head of Pathology
Div. of Marine Mammal Research and Conservation
Harbor Branch Oceanographic Institution
5600 US 1 North
Ft. Pierce, Florida 34946

Antonio Fernández, DVM, PhD, ECVP
Professor of Veterinary Pathology
Veterinary Histology and Pathology
Institute for Animal Health
Veterinary School
University of Las Palmas de Gran Canaria
Canary Islands, Spain

Paul D. Jepson, BVMS, PhD, MRCVS
Coordinator, Marine Mammal Strandings Research
Zoological Society of London
Regent's Park
London NW1 4RY U.K.

Debra Lee Miller, DVM, Ph.D.
Associate Professor/Veterinary Pathologist
Veterinary Diagnostic and Investigational Lab.
The University of Georgia
College of Veterinary Medicine
43 Brighton Road
Tifton, GA 31793-1389

Stephen Raverty, DVM, Dipl. ACVP
Animal Health Center
1767 Angus Campbell Road
Abbotsford, BC, Canada

Appendix XVIII. Reviewers of the report.

Gerald D'Spain, Ph.D.
Associate Research Geophysicist
Marine Physical Laboratory
Scripps Institution of Oceanography, UCSD
9500 Gilman Drive
La Jolla CA 92093-0704

Antonio Fernández, D.V.M., Ph.D., ECVP
Professor of Veterinary Pathology
Veterinary Histology and Pathology
Institute for Animal Health
Veterinary School
University of Las Palmas de Gran Canaria
Canary Islands, Spain

Michelle Fleetwood, D.V.M., Dipl. ACVP
Member, Working Group on Marine Mammal
Unusual Mortality Events
Armed Forces Institute of Pathology
6825 16th Street NW
Washington, DC 20306-6000

Ailsa Hall, Ph.D.
Member, Working Group on Marine Mammal
Unusual Mortality Events
Senior Research Scientist
Sea Mammals Research Unit
Univ. of St. Andrews, Gatty Marine Laboratory
St. Andrews, Fife
KY16 8LB U.K.

Paul D. Jepson, BVMS, Ph.D., MRCVS
Coordinator, Marine Mammal Strandings Research
Zoological Society of London
Regent's Park
London NW1 4RY U.K.

Suzanne Kennedy-Stoskopf, D.V.M., Ph.D., Dipl. ACZM
Member, Working Group on Marine Mammal
Unusual Mortality Events
Research Professor
North Carolina State University
College of Veterinary Medicine
Dept. of Population Health and Pathobiology
4700 Hillsborough Street
Raleigh, NC 27606

Michael J. Kinsel, D.V.M., Dipl. ACVP
Chief, Zoological Pathology Program
University of Illinois
LUMC, Bldg 101, Rm 0745
2160 South First Ave.
Maywood, IL 60153

Michael Moore, D.V.M., Ph.D.
Biology Department
Woods Hole Oceanographic Institution
Woods Hole MA 02543

Teri Rowles, D.V.M., Ph.D.
Coordinator, National Marine Mammal Health and
Stranding Response Program
Office of Protected Resources
National Marine Fisheries Service, NOAA
Silver Spring, MD 20910

Lori Schwacke, Ph.D.
NOAA Center for Marine Animal Health
National Ocean Service, NOAA
219 Fort Johnson Rd
Charleston, SC 29412

M. Andrew Stamper, D.V.M., Dipl. ACVP
Research Biologist/Clinical Veterinarian
Epcot's The Living Seas
Walt Disney World Resorts
EC Trl. W-251
2020 North Avenue of the Stars
Lake Buena Vista, FL 32830-1000

Randall S. Wells, Ph.D.
Chair, Working Group on Marine Mammal
Unusual Mortality Events
Conservation Biologist, Chicago Zoological Society
Director, Center for Marine Mammal &
Sea Turtle Research
Mote Marine Laboratory
1600 Ken Thompson Parkway
Sarasota, Florida 34236 USA