


Coral Disease and Health WORKSHOP: CORAL HISTOPATHOLOGY II

JULY 12-14, 2005

MEDICAL UNIVERSITY OF SOUTH CAROLINA



NOAA TECHNICAL MEMORANDUM NOS NCCOS 56

NOAA TECHNICAL MEMORANDUM CORAL REEF CONSERVATION PROGRAM (CRCP) 4



Coral Disease and Health Workshop: Coral Histopathology II

SB Galloway, CM Woodley, SM McLaughlin

NOAA/NOS/NCCOS

Center for Coastal Environmental Health and Biomolecular Research

TM Work, VS Bochsler, CU Meteyer, L Sileo

US Geological Survey, National Wildlife Health Center

EC Peters

Tetra Tech, Inc.

E Kramarsky-Winters

Tel Aviv University, Department of Zoology

JF Morado

NOAA/NMFS/Alaska Fisheries Science Center

PG Parnell

Clemson Veterinary Diagnostic Center

DS Rotstein

University of Tennessee, College of Veterinary Medicine

RA Harley, J Nicholson

MUSC, Department of Pathology and Laboratory Medicine

TL Reynolds

Johns Hopkins University, Department of Pathobiology

NOAA Technical Memorandum NOS NCCOS 56 and CRCP 4

December 2006



United States Department
of Commerce

National Oceanic and
Atmospheric Administration

National Ocean Service

Carlos M. Gutierrez
Secretary

Conrad C. Lautenbacher, Jr.
Administrator

John (Jack) H. Dunnigan
Assistant Administrator

About This Document

Editors' Acknowledgements: This document was prepared and printed with support from the National Oceanic and Atmospheric Administration (NOAA) through the Coral Reef Conservation Program (CRCP). Layout and design was provided by Thierry Work, US Geological Survey (USGS), Sylvia Galloway and Cheryl Woodley, NOAA/National Centers for Coastal Ocean Science/Center for Coastal Environmental Health and Biomolecular Research (NOAA/NCCOS/CCEHBR). The text was prepared and edited by the Workshop Participants, with final production edits provided by Sylvia Galloway.

Photo Credits:

Images of coral specimens were provided by: Thierry Work, Kathy Price, Dana Williams, Molly Billmyre, Ernesto Weil, Debbie Santavy, Andy Bruckner, Esther Peters and Robert Jonas.

Photomicrographs were captured, by the Workshop Participants during the group discussions, from histological slides provided by Shawn McLaughlin from NOAA's International Registry of Coral Pathology (IRCP) collection.

Meeting photographs were provided by: James Nicholson and Sylvia Galloway.

Cover Design: James Nicholson, Medical University of South Carolina, Department of Pathology and Laboratory Medicine

Coral Illustrations: Jennifer Clark, Jennifer Clark Scientific Illustrations

Workshop Group Photo: James Nicholson, Medical University of South Carolina, Department of Pathology and Laboratory Medicine

Citation –

Please cite this report as follows:

Galloway SB, Work TM, Bochsler VS, Harley RA, Kramarsky-Winters E, McLaughlin SM, Meteyer CU, Morado JF, Nicholson JH, Parnell PG, Peters EC, Reynolds TL, Rotstein DS, Sileo L, and Woodley CM. 2007. Coral Disease and Health Workshop: Coral Histopathology II. NOAA Technical Memorandum NOS NCCOS 56 and NOAA Technical Memorandum CRCP 4. National Oceanic and Atmospheric Administration, Silver Spring, MD. 84p.

**CORAL DISEASE AND HEALTH WORKSHOP:
CORAL HISTOPATHOLOGY II**

TABLE OF CONTENTS

EXECUTIVE SUMMARY	1
GOAL.....	2
PREFACE.....	3
INTRODUCTION	7
<i>STUDY SETS.....</i>	7
<i>ANATOMY OF CORALS</i>	8
<i>FIGURE LEGENDS.....</i>	10
<i>HISTOPATHOLOGICAL EXAMINATION.....</i>	20
<i>RECOMMENDED FORMAT</i>	21
CONSENSUS HISTOPATHOLOGY DESCRIPTIONS	22
<i>Slide 1.....</i>	22
<i>Slide 2.....</i>	24
<i>Slide 3.....</i>	26
<i>Slide 4.....</i>	28
<i>Slide 5.....</i>	30
<i>Slide 6.....</i>	32
<i>Slide 7.....</i>	34
<i>Slide 8.....</i>	36
<i>Slide 9.....</i>	38
<i>Slide 10.....</i>	40
<i>Slide 11.....</i>	42
<i>Slide 12.....</i>	44
<i>Slide 13.....</i>	46
<i>Slide 14.....</i>	48
<i>Slide 15.....</i>	50
SUMMARY	52

RECOMMENDATIONS.....	54
ACKNOWLEDGEMENTS	55
GLOSSARY.....	57
REFERENCES.....	77
AGENDA	80
WORKSHOP PARTICIPANTS	82

EXECUTIVE SUMMARY

The health and continued existence of coral reef ecosystems are threatened by an increasing array of environmental and anthropogenic impacts. Coral disease is one of the prominent causes of increased mortality among reefs globally, particularly in the Caribbean. Although over 40 different coral diseases and syndromes have been reported worldwide, only a few etiological agents have been confirmed; most pathogens remain unknown and the dynamics of disease transmission, pathogenicity and mortality are not understood. Causal relationships have been documented for only a few of the coral diseases, while new syndromes continue to emerge. Extensive field observations by coral biologists have provided substantial documentation of a plethora of new pathologies, but our understanding, however, has been limited to descriptions of gross lesions with names reflecting these observations (e.g., black band, white band, dark spot). To determine etiology, we must equip coral diseases scientists with basic biomedical knowledge and specialized training in areas such as histology, cell biology and pathology. Only through combining descriptive science with mechanistic science and employing the synthesis epizootiology provides will we be able to gain insight into causation and become equipped to handle the pending crisis.

One of the critical challenges faced by coral disease researchers is to establish a framework to systematically study coral pathologies drawing from the field of diagnostic medicine and pathology and using generally accepted nomenclature. This process began in April 2004, with a workshop titled *Coral Disease and Health Workshop: Developing Diagnostic Criteria* co-convened by the Coral Disease and Health Consortium (CDHC), a working group organized under the auspices of the U.S. Coral Reef Task Force, and the International Registry for Coral Pathology (IRCP). The workshop was hosted by the U.S. Geological Survey, National Wildlife Health Center (NWHC) in Madison, Wisconsin and was focused on gross morphology and disease signs observed in the field. A resounding recommendation from the histopathologists participating in the workshop was the urgent need to develop diagnostic criteria that are suitable to move from gross observations to morphological diagnoses based on evaluation of microscopic anatomy.

As a continuation of building the foundation and framework for coral disease diagnostics, the CDHC convened the *Coral Disease and Health Workshop: Coral Histopathology II* in Charleston, South Carolina, July 11-14, 2005. The workshop was hosted by the Department of Pathology and Laboratory Medicine at the Medical University of South Carolina, Charleston, SC which provided expertise, facilities and equipment in support of the workshop. All of the histological slides and related photographs used in the discussions were prepared and supplied by the IRCP. This workshop brought together 15 experts in veterinary and medical pathology and coral biology from national and international research institutes and government laboratories. The mission was to devise a standardized approach to examining microscopic anatomy and pathology of corals and a standardized nomenclature to facilitate accurate descriptions of the microscopic morphology of corals and enhance communication among specialists investigating causes of coral death.

The participants of this workshop deliberated for 3 days to refine the nomenclature for gross and microscopic anatomy of corals and systematically described microscopic changes associated with selected coral diseases. The findings and recommendations from the deliberations will be submitted to the research community for peer review. The standardized nomenclature and descriptions produced at this workshop will ultimately be made available to the scientific community through a variety of media including the World Wide Web.

An exciting highlight of this meeting was provided by Professor Robert Ogilvie (MUSC Department of Cell Biology and Anatomy) when he introduced participants to a new digital technology that is revolutionizing histology and histopathology in the medical field. The Virtual Slide technology creates digital images of histological tissue sections by computer scanning actual slides in high definition and storing the images for retrieval and viewing. Virtual slides now allow any investigator with access to a computer and the web to view, search, annotate and comment on the same tissue sections in real time. Medical and veterinary slide libraries across the country are being converted into virtual slides to enhance biomedical education, research and diagnosis. The coral health and disease researchers at this workshop deem virtual slides as a significant way to increase capabilities in coral histology and a means for pathology consultations on coral disease cases on a global scale.

GOAL: Set an internationally recognized standard for the description of coral microscopic anatomy and pathology.

SPECIFIC OBJECTIVES:

- Refine nomenclature of gross and microscopic anatomy.
- Describe microscopic changes associated with selected diseases.
- Develop diagnostic criteria for coral conditions for a web-based learning tool for coral histology and histopathology.
- Set internationally recognized standards for the description of coral histology.
- Standardize terminology for the description of microscopic lesions of corals.
- Develop morphological diagnoses for the histopathology of lesions from selected coral syndromes.



Dr. Lou Sileo, facilitator of the July coral histopathology workshop. (Photo: Jim Nicholson)

PREFACE

Pathology is the study of the cause of disease and the modifications to cellular structure and function resulting from a diseased state. Diagnostic techniques such as histology, electron microscopy, immunocytochemistry and molecular pathology are powerful technologies for detecting such changes, but they have not been rigorously applied to coral disease investigations. The CDHC is organizing a series of workshops to focus on coral pathobiology to provide a forum for translating advances in biomedical and veterinary sciences, pathology, toxicology, and biotechnology to the study of coral disease and health. The cross-disciplinary nature of these workshops serves to provide the means by which coral disease researchers can interface with the mainstream biomedical community and allow more rapid progress in understanding the causes of coral disease and devising appropriate strategies for disease management.

The first workshop in this series, ‘*Coral Disease and Health Workshop: Developing Diagnostic Criteria*’ held in 2004, focused on gross morphology and disease signs observed in the field. During deliberations, problems with inconsistent data collection and the lack of objective criteria to describe cellular changes associated with disease at the microscopic



Presumed white band disease observed on *Acropora palmata* in Puerto Rico. (Photo: Andy Bruckner)



Tissue sloughing in *Acropora prolifera* observed in the Dry Tortugas, USA (Photo: Dana Williams)

level (histopathology) were identified as major impediments. Furthermore, routine use of the principles and practices of epizootiology and pathology of corals are just beginning. Confusion and uncertainty as to how cellular changes in these organisms should be described are evident in the literature. The second Coral Histopathology Workshop, reported here, was convened to address this issue. The workshop involved coral biologists and pathologists from various institutions to refine nomenclature of gross and microscopic anatomy and to systematically describe microscopic changes associated with selected diseases.

To date most field diagnoses have been descriptive in nature, failing to use traditional histopathological criteria. The workshop was organized around the review of histological slide sets from coral lesions associated with a variety of field diagnosed diseases. The workshop participants agreed to review a set of known coral lesions as a group and to develop a set of histopathological terms applicable to the description of these lesions. They also agreed to review independently unidentified histology slides containing coral lesions, followed by a group discussion of their independent observations, and to reach a consensus morphological diagnosis for the unknowns.



Workshop participants reviewing a photomicrograph.
(Photo: Jim Nicholson)



Debra Hazen-Martin, Jim Nicholson and Bob Ogilvie of MUSC. (Photo: Jim Nicholson)

The work of the group was greatly facilitated by the logistical support and expertise provided by MUSC's Department of Pathology and Laboratory Medicine. The group had microscopes allowing pathologists to independently review slides, and a projection microscope for the group discussions. In addition photographs were captured from specific regions of each reviewed histological slide that illustrated the morphological diagnosis ascertained by the group.

Finally, the workshop participants were given the opportunity to view and use the latest in histopathology technology¹, Virtual Slides².

An Aperio Virtual Slide Viewer³ was demonstrated during the first day of the workshop.

¹ Disclaimer: This publication does not constitute an endorsement of any commercial product or intend to be an opinion beyond scientific or other results obtained by the National Oceanic and Atmospheric Administration (NOAA). No reference shall be made to NOAA, or this publication furnished by NOAA, in any advertising or sales promotion which would indicate or imply that NOAA recommends or endorses any proprietary product mentioned herein, or which has as its purpose an interest to cause directly or indirectly the advertised product to be used or purchased because of this publication.

² Advances in Pathology, Microscopy & Molecular Morphology edited by Jiang Gu and Gerhard W. Hacker: 'Virtual Microscopy and Virtual Slides in Teaching, Diagnosis, and Research' by Jiang Gu and Robert W. Ogilvie; CRC, Taylor & Francis, Boca Raton, London, New York, Singapore, 2005, 356p.

³ <http://www.aperio.com/>

Representative sections from each coral lesion under review were digitized using this system. These images were provided to each participant on a DVD for future viewing. Aperio viewing software is available (and downloadable) free from their website. The virtual slide viewer provides the same quality image, resolution, and magnifications that a user would get with a microscope. The scanner contains 80 micro lenses and has a 24 mega-pixel capability. A unique feature of the software associated with the scanner is the ability to conference and view slides jointly over the internet, with control of slide movement and focus available (permission granted by scanner operator) to each participant of the conference. It was agreed that this technology would be extremely useful to share information on histopathology among colleagues interested in coral disease diagnosis and as a teaching tool.



Aperio Representative demonstrating Virtual Slides to Bob Ogilvie (Photo: Jim Nicholson)

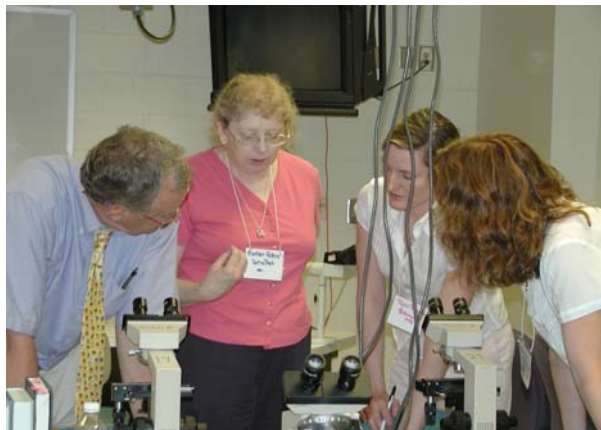INTRODUCTION

The prevalence and severity of reef degradation due to coral disease has increased considerably over the last two decades. Emerging coral diseases have been linked to biotic and abiotic stressors and their synergistic interactions. Coral disease research is in its infancy and only beginning to take advantage of technologies and methodologies routinely used in epizootiology, clinical and diagnostic medicine, and pathology. This Coral Histopathology Workshop (and its predecessor) provided forums to begin adapting advances in biomedical and veterinary sciences, pathology, toxicology, and biotechnology to the study of coral disease and health; it also provided a foundation on which to build a framework for coral disease research that can interface with mainstream medical and veterinary research. The goals of this Workshop were to produce standards for (1) morphological descriptors based on accepted medical terminology, (2) consistent and concise descriptions of lesions in the field, as well as (3) clinical morphological diagnoses in the laboratory. Consensus reached during this workshop will be peer reviewed by the coral scientific community, both in public settings where the materials will be presented in workshop/discussion formats, directly soliciting review by others establishing terminology for the field, and through opinion papers in the peer-review literature to adopt specialized terminologies to facilitate communication among histopathologists. Once adopted, the terminology and microscopic descriptions will enable development of instructional materials and distance learning tools for coral histopathology.

STUDY SETS OF HISTOLOGY SLIDES PROVIDED BY THE IRCP

An important facet of this workshop was the use of study sets of slides with serial sections from the same sample for independent individual microscopic review. Study sets for the workshop were provided by the International Registry of Coral

Pathology at the NOAA/NOS/NCCOS/CCEHBR Cooperative Oxford Laboratory (COL) in Oxford, MD. Microslides were prepared from coral tissues accessioned by IRCP, from paraffin blocks provided by individual investigators, and the Registry of Tumors in Lower Animals (RTLA) in Sterling, VA. Contributors included Andy Bruckner, Margaret Miller, Esther Peters, Caroline Rogers, Debbie Santavy, Lou Sileo, Ernesto Weil, Dana Williams, Thierry Work, and Cheryl Woodley. COL staff who contributed to the preparation of the study sets included Kathy Price, Molly Billmyre, Dorothy Howard, Bob Bingaman and Shawn McLaughlin.



E. Peters discusses coral pathology with R. Harley, T. Reynolds and V. Boschler. (Photo: Sylvia Galloway)

ANATOMY OF CORALS

(Note: Terms relevant to the description of coral histology are shown in blue at their first mention in the text, and are linked to the Glossary)

Gross anatomy of a scleractinian polyp from an imperforate coral (Fig. 1a)

Colonial scleractinian corals are composed of numerous interconnected [polyps](#). The [coenenchyme](#) is the tissue between polyps and consists of a tubular network of [gastrovascular canals](#) that connect the [gastrovascular cavity](#) (gastric cavity) of adjacent polyps. At the [oral](#) end of the polyp are [tentacles](#) surrounding the [oral disk](#); they have a bulbous structure at their tips, the [acrosphere](#). The tentacles are studded with [nematocysts/spirocysts](#), either scattered or clustered. Inside the ring of tentacles, within the oral disk, is a structure that surrounds the mouth and may be elevated, the [peristome](#). Below the mouth is an invagination of the [epidermis](#) to form a short muscular tubular passageway to the gastric cavity, the [actinopharynx](#). The area comprising the oral disk and actinopharynx is the column. The lower portion from the actinopharynx to the [aboral](#) end of the polyp is the [coenosteum](#). Polyps and interconnecting tissues alike are made up of the same tissue layers. The [surface body wall](#) contains [epidermis](#), [mesoglea](#), [gastrodermis](#) and is found in the polyp and coenenchyme. The actinopharynx body wall lines the lumen of the actinopharynx. The [basal body wall](#) is the tissue apposed to [skeleton](#), consists of [calicodermis](#) and gastrodermis separated by mesoglea, and is found in the aboral region of the polyp and lining the gastrovascular canals. Within the gastrovascular cavity are [mesenteries](#), that provide structural support and increase the surface area of the gastrodermis to improve nutrient absorption, and the gonads develop within these structures.

Gross anatomy of a gorgonian polyp (Fig. 1b)

Colonial gorgonian polyps have some similarities in structure to scleractinian polyps but differ in significant aspects. The oral (distal) portion of the polyp, bearing the mouth and tentacles, is the [anthocodia](#). Gorgonian polyp tentacles are characterized by two diametrically arrayed rows of short [pinnules](#). The polyps are anchored to the [axis](#) at their aboral end and in some species the polyp is surrounded by a rigid structure, the [anthostele](#), into which the anthocodia may be withdrawn. The axis has a [central chord](#) and is surrounded by an [axial cortex](#) and sheath. The [axial sheath](#) contains longitudinal canals characterized by [sclerites](#) that differ from those found in the coenenchyme. The coenenchyme is the tissue continuous between polyps, consisting of the surface body wall, gastrovascular canals and [solenia](#), penetrating through the thick mesoglea stiffened with sclerites.

Skeletal features of a noncolonial scleractinian coral (Fig. 1c)

The skeleton deposited by an individual polyp within a colony is the [corallite](#). The corallite is defined by three regions, the [calice](#) the [columella](#), and the [theca](#). The [column](#)-shaped skeletal projection of the central [basal plate](#) or modified inner [septal](#) edges is the columella. The calice includes the upper oral surface of a corallite, while the theca is the wall of the skeletal cup (corallite). The septa, vertical calcareous partitions, radiate from the corallite wall toward the central axis within the calice and provide support to the mesenteries. Extensions of the septa outside the calice onto the coenosteum are the [costa](#).

Skeletal features of colonial scleractinians (Fig. 2)

The coral skeleton may be porous ([perforate](#)), with connections between the polyps through the skeleton (**Fig. 2a-b**), or nonporous ([imperforate](#)) (**Fig. 2c-d**).

Mesentery features of a scleractinian polyp (Fig. 3)

Mesenteries are internal longitudinal partitions of tissue that provide structural support and increase surface area within the gastrovascular cavity. They are important in nutritional functions as well as fertility of anthozoans. A mesentery develops by infolding of the mesoglea and its lining gastrodermis from the body wall of the polyp. Multiple mesenteries are arranged radially within the gastrovascular cavity of the polyp (between the septa in scleractinian corals) and are attached to the oral disk. In the oral region, [mesogleal pleats](#) supporting the longitudinal retractor muscles are prominent; in the aboral region, [gonads](#) and loops of the [mesenterial filament](#) develop. [Complete mesenteries](#) attach to the polyp wall whereas [incomplete mesenteries](#) float free within the lumen of gastrovascular canals. The free edge of mesenteries consists of a [cnidoglandular band](#) with adjacent [lobes](#).

Surface body wall organization of a scleractinian polyp; cell types associated with the epidermis, mesoglea, and gastrodermis (Fig. 4)

The generic cellular organization of coral tissue layers consists of an epidermis, the mesoglea and a gastrodermis. The epidermis may be either, located next to the external environment (surface body wall), located next to the skeleton (basal body wall) or located in the actinopharynx ([actinopharynx body wall](#)). The epidermis contains numerous cells including [cnidae](#), [mucocytes](#) (mucosecretory cells), [pigment cells](#), [calicoblastic cells](#), [epitheliomuscular cells](#) and other [supporting cells](#). The calicoblastic epithelium (calicodermis) is apposed to and secretes the calcium carbonate, [aragonite](#), skeleton. The epidermis of the actinopharynx has more supporting cells than the surface body wall epidermis, with notably elongated [cilia](#), that function to move food particles and fluid into and out of the gastrovascular cavity. The mesoglea is a homogenous connective tissue layer of variable thickness that may contain isolated cells. It is bordered either by epidermis and gastrodermis or by gastrodermis on both sides (as occurs in the mesentery, Fig. 3). The gastrodermis lines the digestive lumen, underlies the mesoglea, and contains [zooxanthellae](#), or symbiotic algae, in membrane bound [vacuoles](#). The gastrodermis may contain ciliated or flagellated support cells, cnidocytes, [amoebocytes](#), sensory cells, mucocytes, [granular gland cells](#) and pigment cells. [Neurons](#) and epitheliomuscular cells are found in both epidermis and gastrodermis. The base of an epitheliomuscular cell contains a contractile portion within the plasma membrane, the [myoneme](#), which attaches to the nucleus-containing portion of the cell by a peduncle and also attaches the cell to the mesoglea.

FIGURE LEGENDS FOR FIGURES 1-4.

Figure 1a. Gross anatomy of a scleractinian polyp from an imperforate coral.

Figure 1b. Gross anatomy of a gorgonian polyp.

Figure 1c. Diagram of skeletal features of a noncolonial scleractinian coral. Only those skeletal features included in the glossary are labeled. Additional features important in scleractinian taxonomy are not labeled here.

Figure 2a. Left, sagittal section through *Acropora* polyps, a perforate coral. Tissue fixed in Helly's solution and stained with azocarmine G. Below, tissue section from a different *Acropora* sample, stained with hematoxylin and eosin.

Figure 2b. Oblique section through *Acropora* polyps. The plane of the section passes through both oral (actinopharynx) and aboral (gonad) portions of polyps.

Figure 2c. Left, sagittal section through *Montastraea* polyps, an imperforate coral. Tissue fixed in Z-Fix solution and stained with azocarmine G. Below, tissue section from a different *Montastraea* sample, stained with hematoxylin and eosin.

Figure 2d. Oblique section through a *Montastraea* polyp. The plane of the section is from the oral region of a contracted polyp.

Figure 3. Three-dimensional diagram of the key features of a scleractinian polyp mesentery. In the oral region, mesogleal pleats supporting the longitudinal retractor muscles are prominent; in the aboral region, gonads and loops of the mesenterial filament develop.

Figure 4. Three-dimensional diagram of the surface body wall of a scleractinian polyp, showing cell types of the epidermis, mesoglea, and, gastrodermis.

Figure 1a.

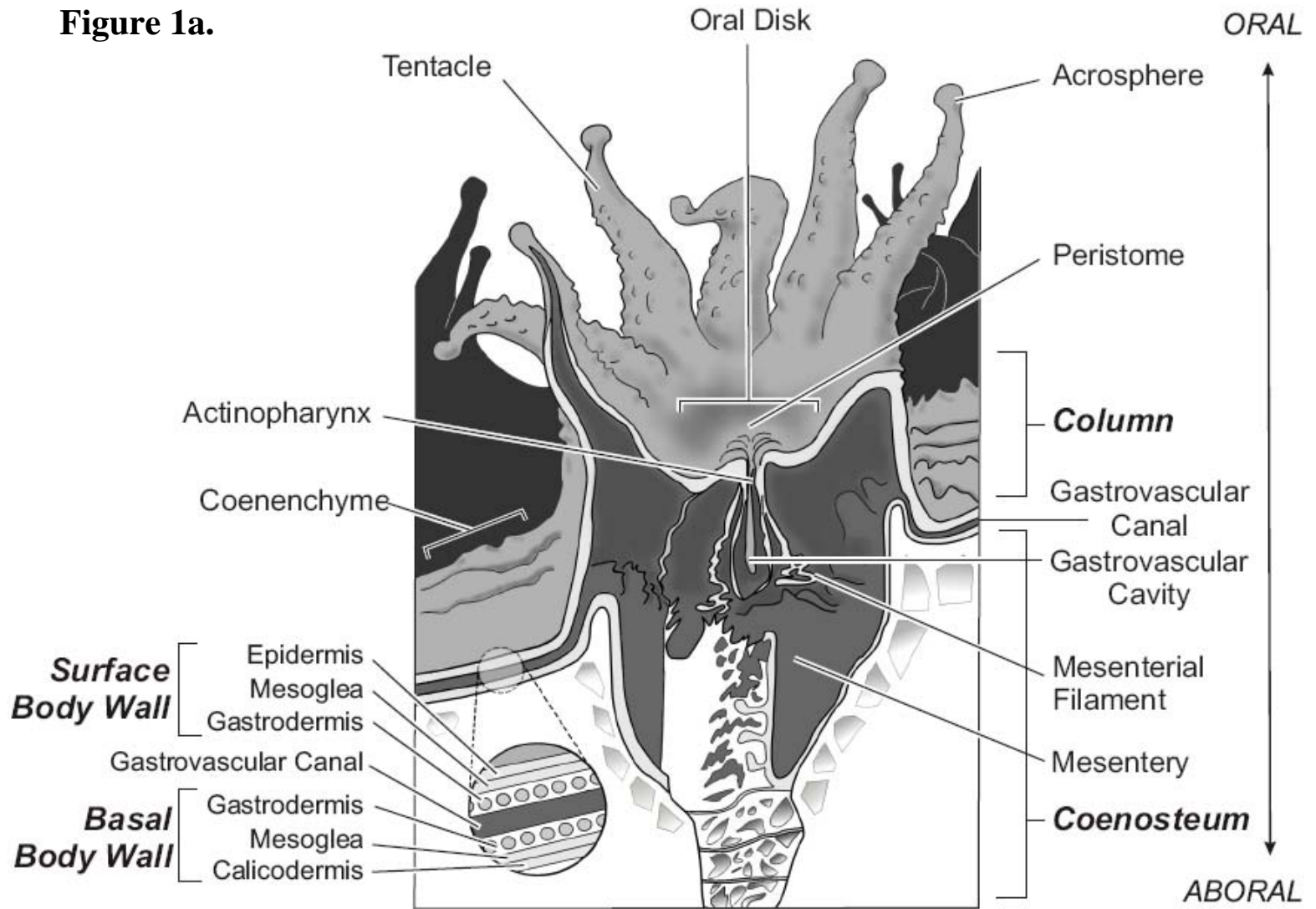


Figure 1b.

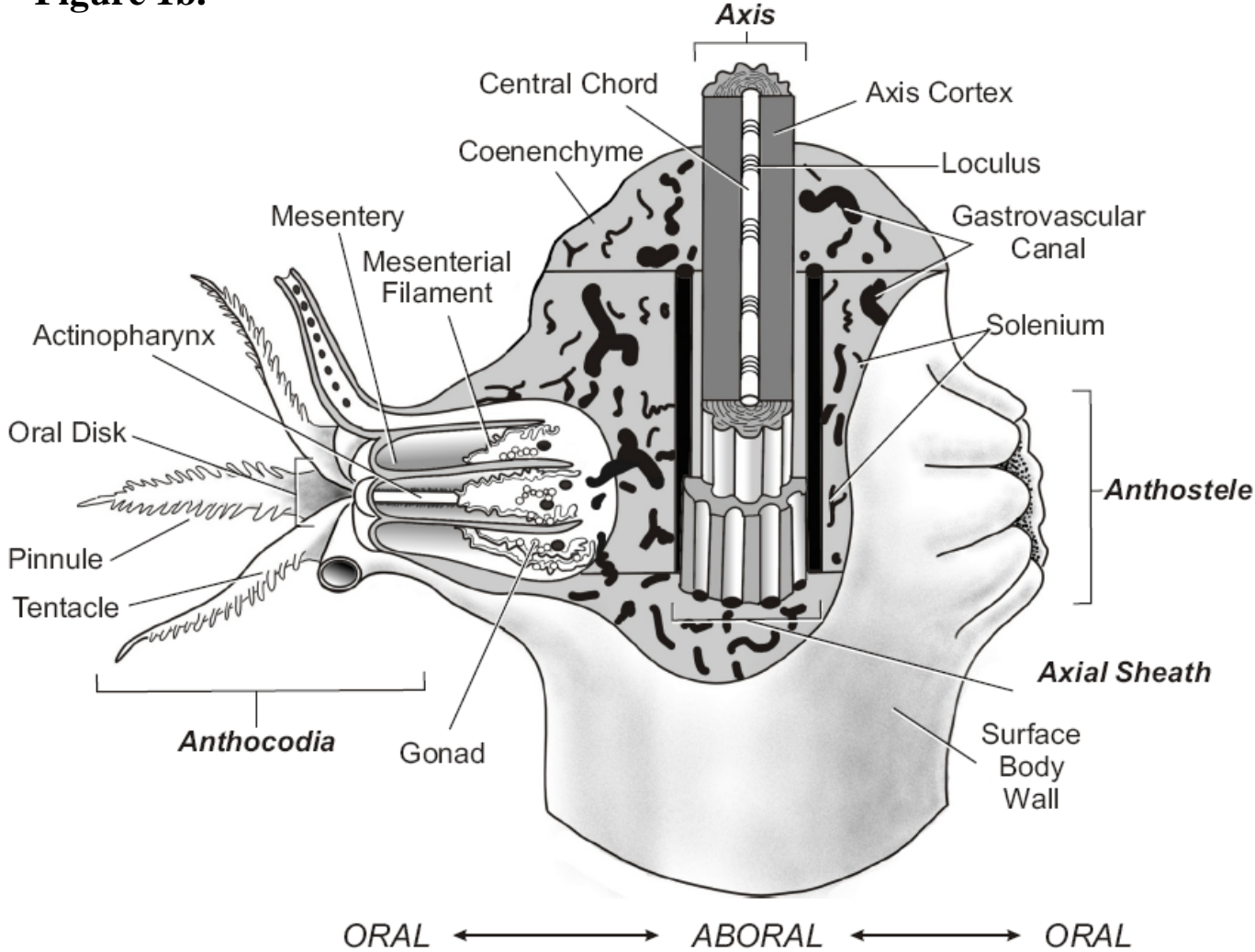


Figure 1c.

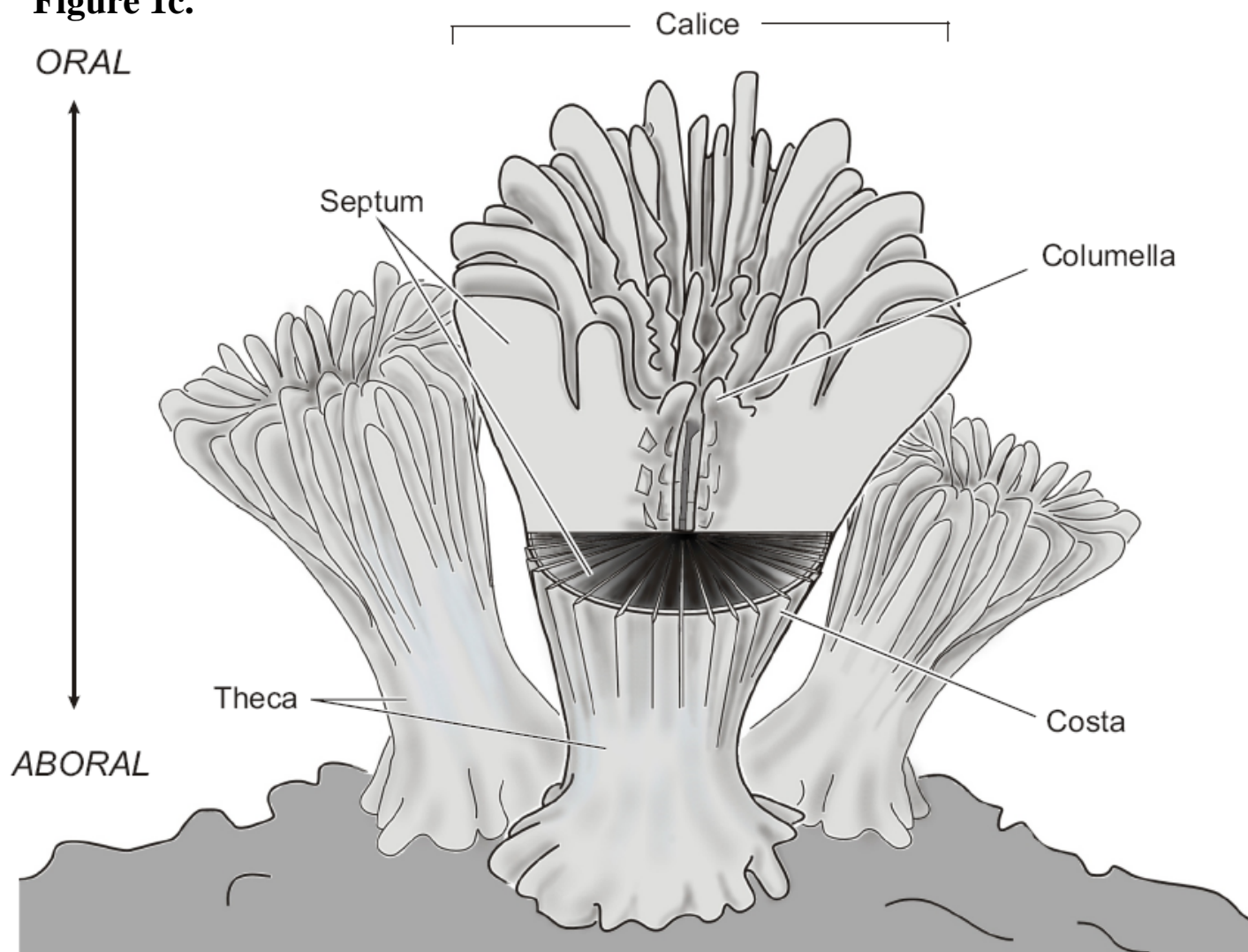


Figure 2a.

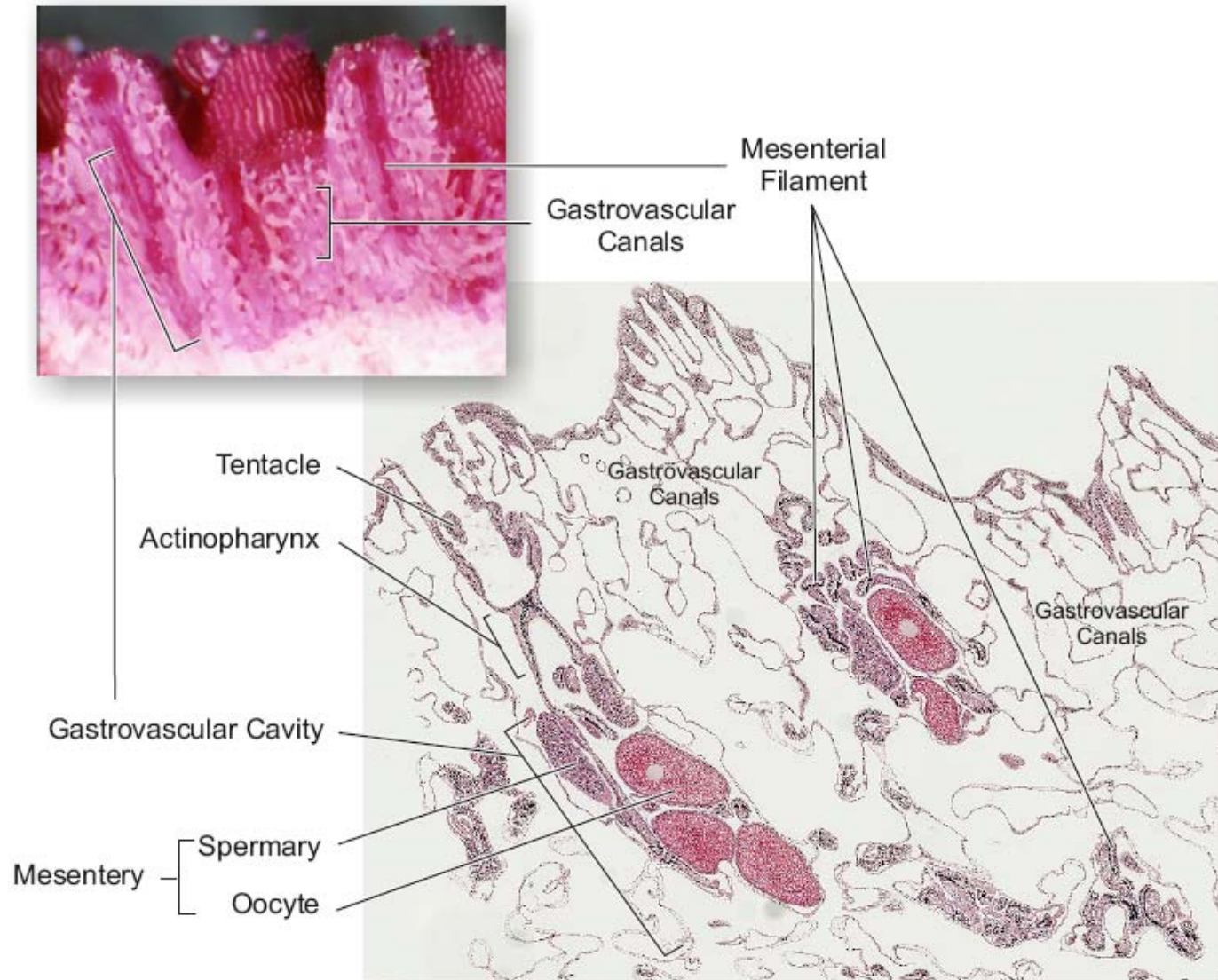


Figure 2b.

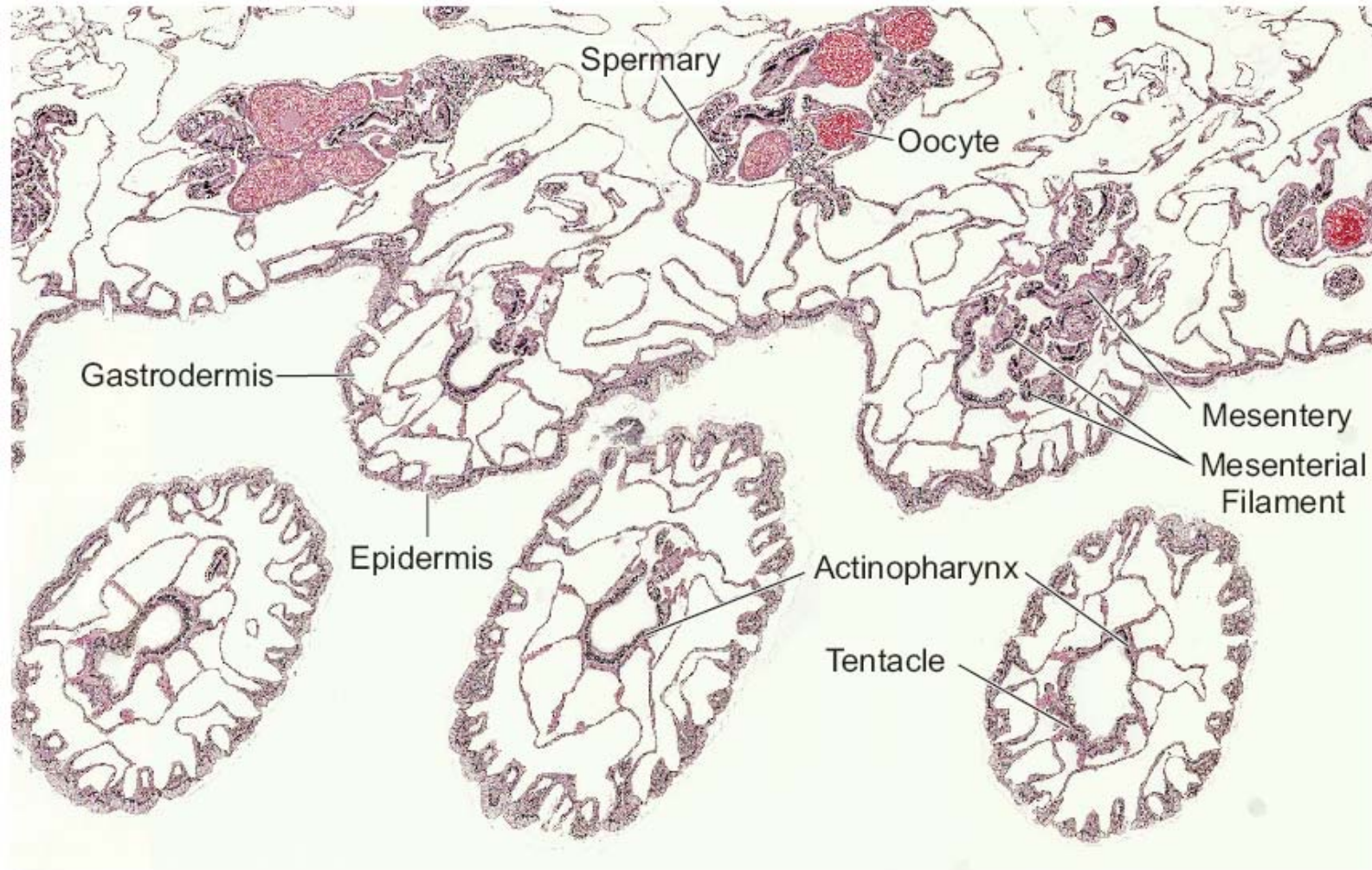


Figure 2c.

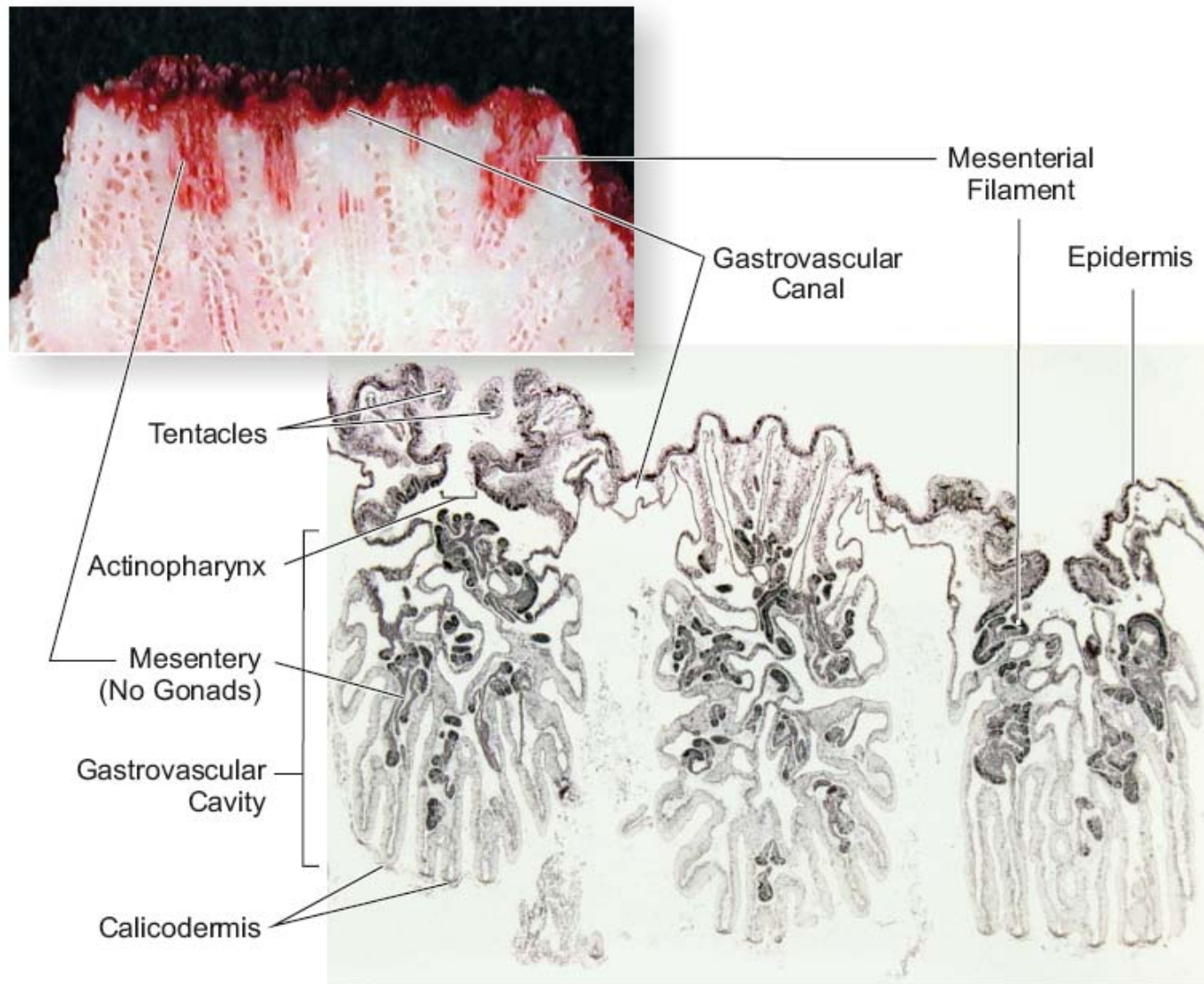


Figure 2d.

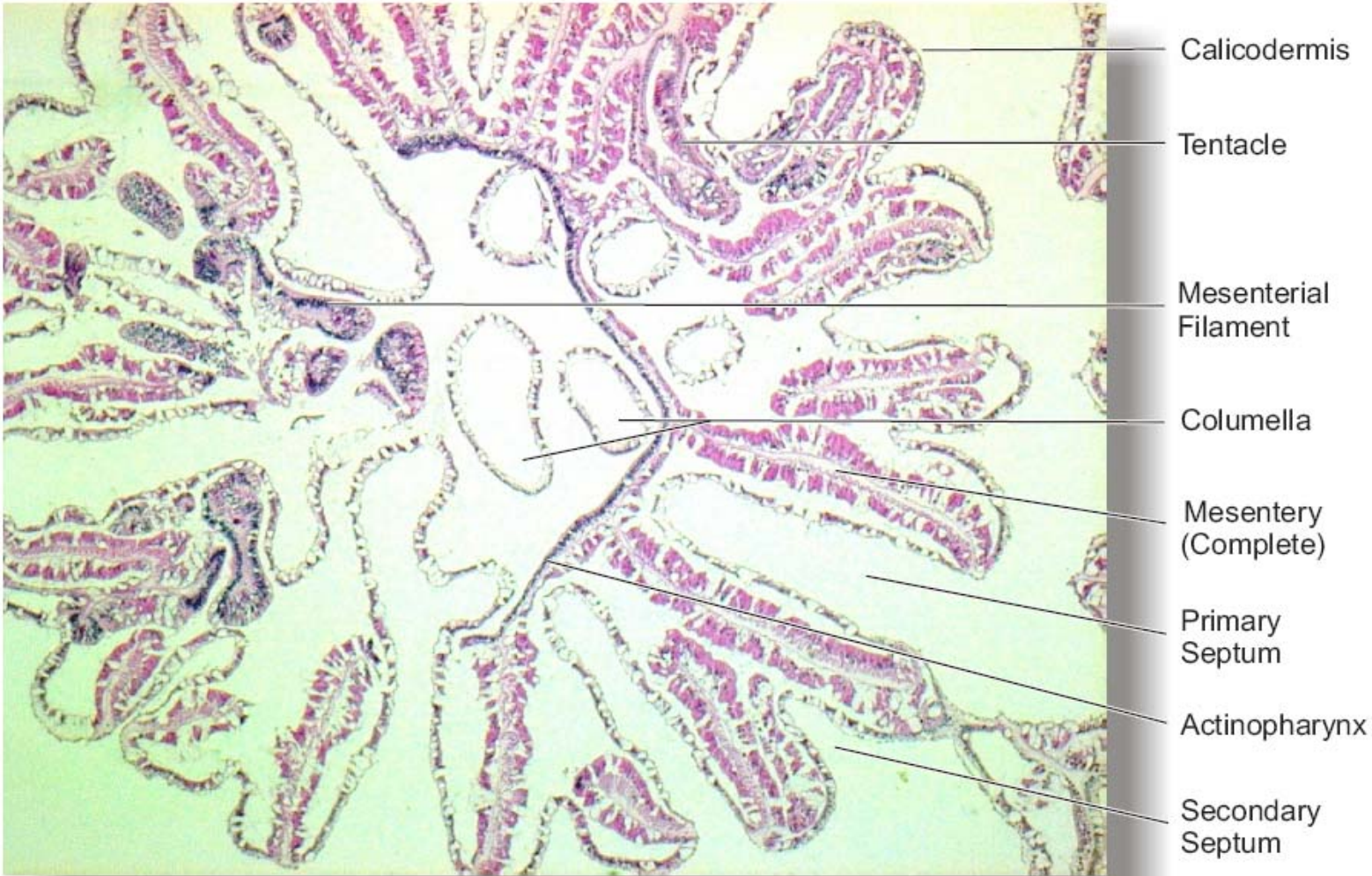

Figure 3.

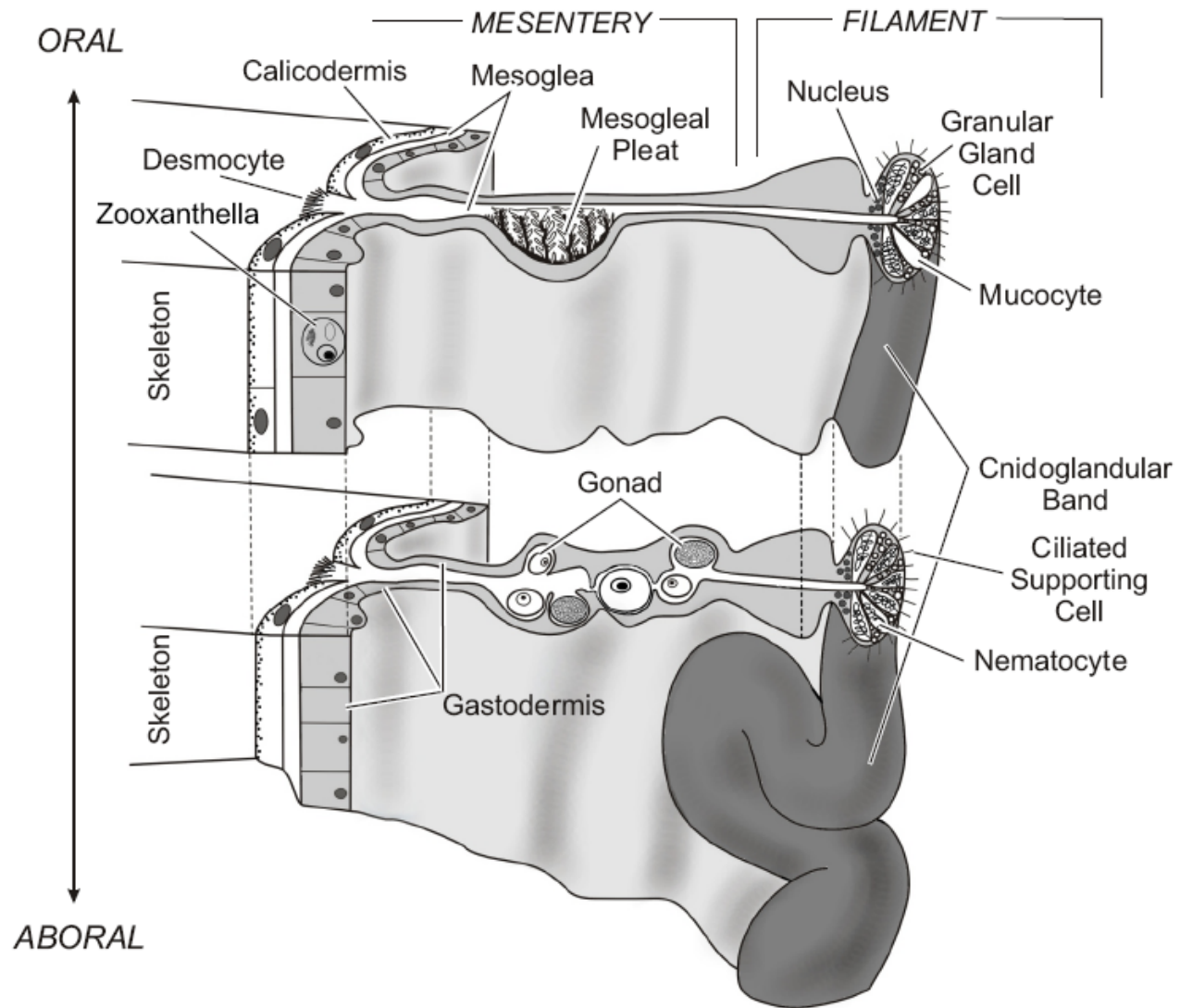
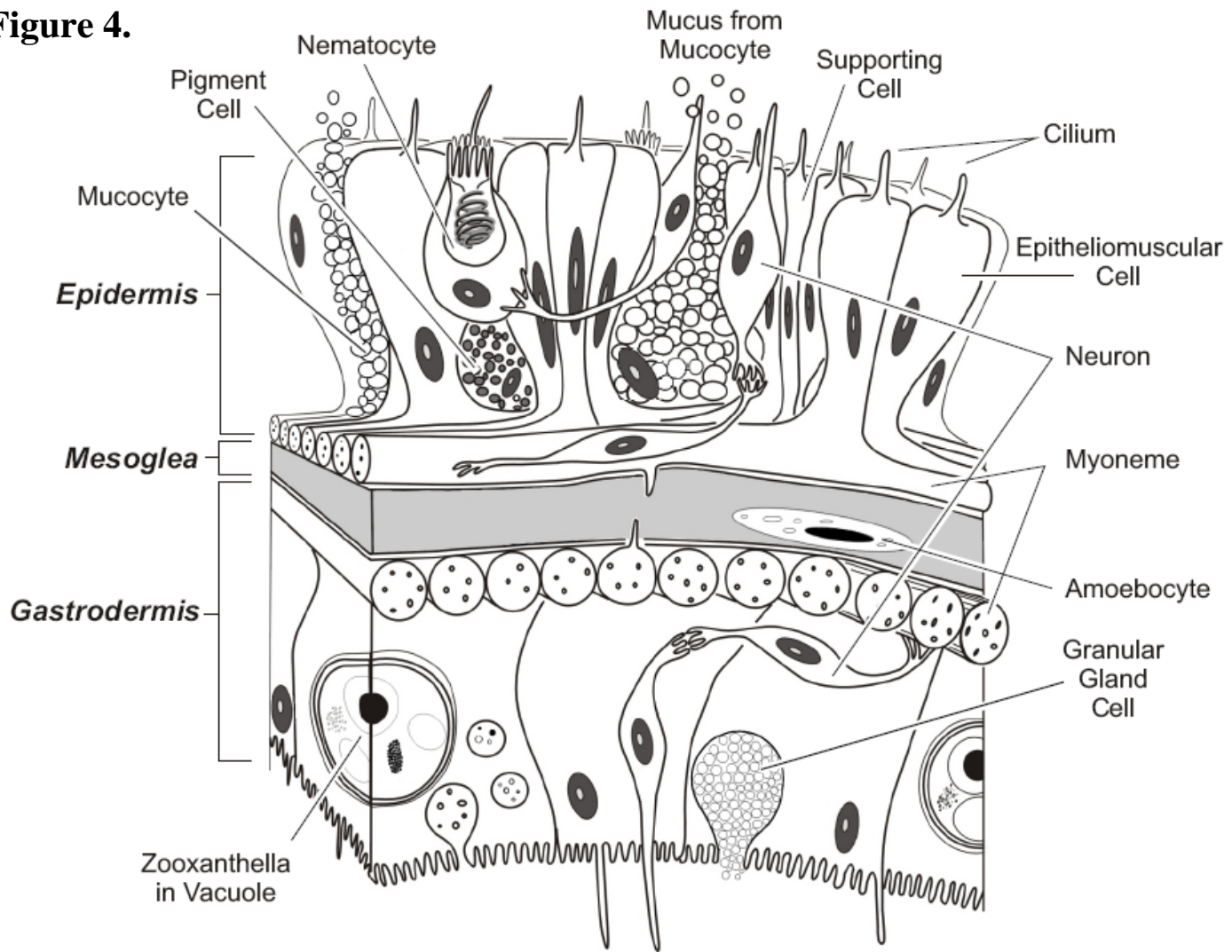


Figure 4.



HISTOPATHOLOGICAL EXAMINATION OF CORAL TISSUE

Three regions and their accompanying structures and *tissue types* are examined:

1. Coenenchyme

- a. Gastrovascular canals (*surface and basal body walls*)

2. Polyp

- a. Oral

tentacles (surface body wall)

oral disk (surface body wall)

peristome (surface body wall)

actinopharynx (actinopharynx body wall)

- b. Aboral

body

wall (surface and basal)

mesenteries (complete or incomplete)

proximal

mesogleal pleats

gonads

filaments

lobes

cnidoglandular band

gastric cavity

3. Skeleton

- a. septa
- b. columella
- c. corallum
- d. basal plate

RECOMMENDED FORMAT FOR DESCRIBING HISTOLOGY AND HISTOPATHOLOGY OF CORALS

Signalment/History:

Specimen information (genus-species, common name, shape descriptors);

Description of affected coral (color change, tissue loss, skeletal damage, growth anomaly, other descriptors);

Sample information (identification number, healthy tissue, diseased tissue, other species, sediment/soil/sand, water);

Reef descriptors (name, general location, type, depth, GPS coordinates);

Collection site data (water clarity, map, transect information, disturbance signs, photos, videos);

Observer information (name, address, contact information, date of observation).

Field Diagnosis: Complete description of the gross [lesion](#) and a preliminary diagnosis of the disease condition or suspected disease name.

Histopathology Description: description given for each of three tissue areas.

Coenenchyme

Polyp

Skeleton

Morphologic Diagnosis:

Description of tissue lesions using consensus coral histopathology terms.


Recommendations: specific sampling, sectioning, staining or amplification suggestions.

CONSENSUS HISTOPATHOLOGY DESCRIPTIONS FOR SELECTED CORAL LESIONS

Slide 1

Signalment/History: *Acropora palmata* (IRCP 180-A2) collected from Lameshur Bay, US Virgin Islands on 15 July 2004 by Lou Sileo, Thierry Work and Caroline Rogers.

Field Diagnosis: Presumed White Patch



Figures 5 A & B. White patch lesions on *Acropora palmata*: A- field photo (Thierry Work); B- fixed specimen (Kathy Price).

Histopathology Description (Fig. 6):

Coenenchyme: Viable tissue terminates abruptly and is characterized by full thickness tissue loss. A narrow edge of necrotic tissue precedes the termination (Fig. 6B, ↑). There is focal ulceration of the surface body wall characterized by ablation of epidermis and mesoglea and dissociation of gastrodermal cells with liberation of zooxanthellae some of which exhibit vacuolization of the cytoplasm. These vacuolated zooxanthellae are found within gastrovascular canals and are admixed with necrotic debris in the superficial peristome. There is multifocal to focally extensive vacuolization of gastrodermis which was more severe within the deep region. The epidermis is focally sloughed and vacuolated. No bacterial aggregates are seen. Aborally, there are scattered areas of necrotic gastrodermis occasionally associated with [hyalinized](#) mesoglea.

Polyp: Within ova there is central clumping of [eosinophilic](#) granules (yolk); vacuolization of surrounding wall (Fig. 6C, ↑); presence of multiple round structures with [basophilic](#) stippling surrounded by a vacuole. Occasional filamentous structures infiltrate gastrodermis; there is no associated [necrosis](#). Cnidoglandular bands are necrotic and characterized by [pyknosis](#) and [dissociation](#)

of gastrodermal cells, of many proximal mesenteric filaments. Occasional [spermaries](#) are noted.

Skeleton: Well within the portion denuded of tissue, there are abundant mixed populations/mats of [endolithic](#) organisms.

Other, [mucus](#): There are scattered clumps of eosinophilic debris and [spirocysts](#) (Fig. 6A, ↑).

Morphologic Diagnosis: None

Recommendations:

- Gram stains for bacteria
- [GMS](#) for fungi
- [Giemsa](#) for suspect organisms in the tissues surrounding ova.
- Trichrome or Aniline Blue for hyalinized mesoglea.

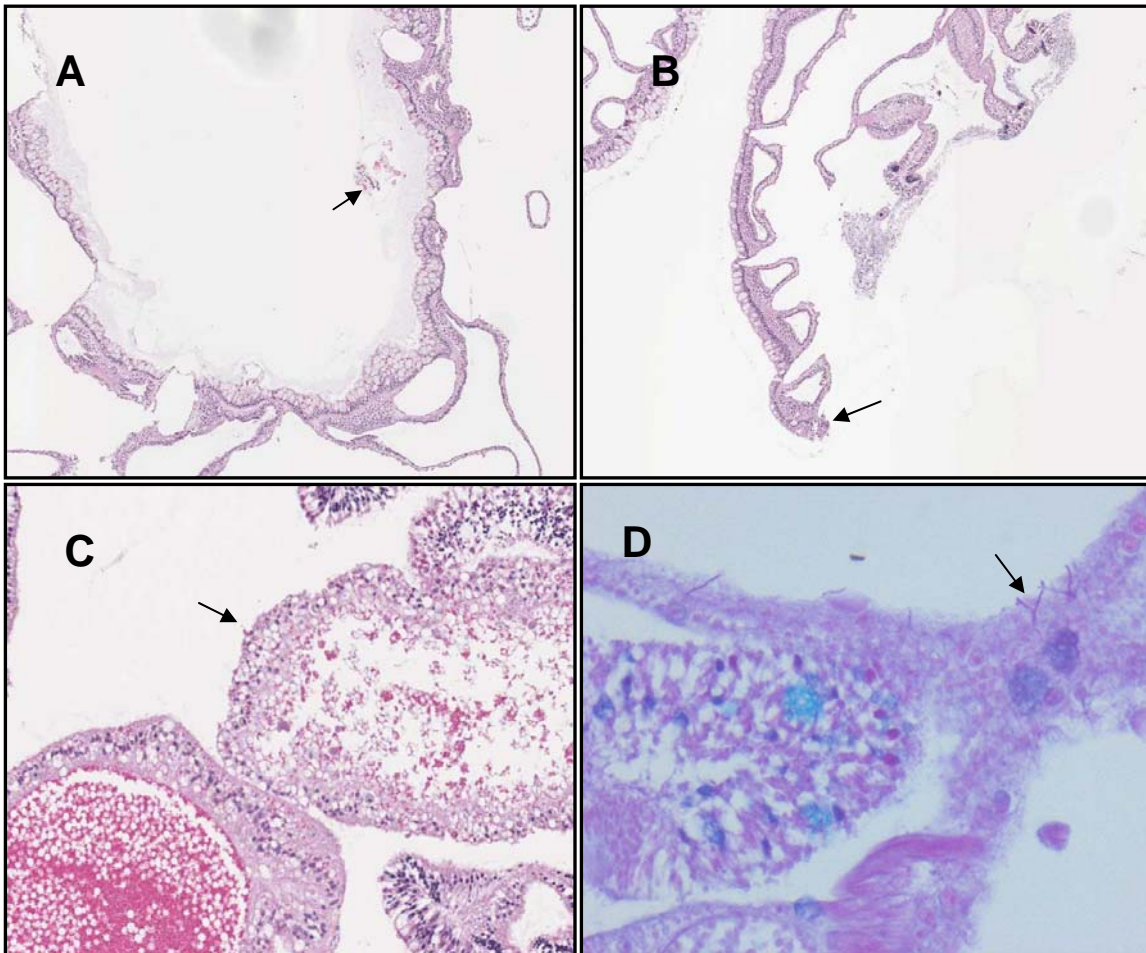
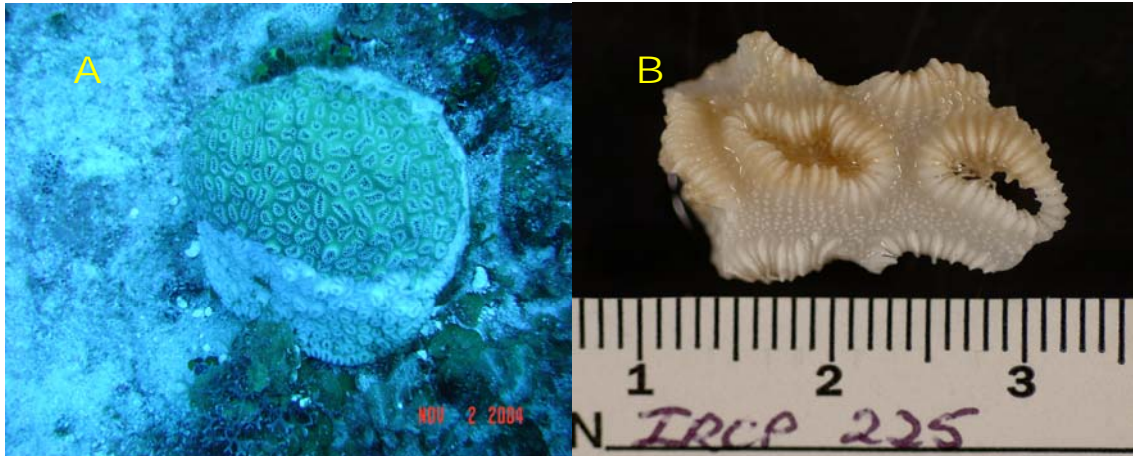


Figure 6 A-D. Photomicrographs of diseased *Acropora palmata* tissue fixed in seawater:Z-Fix⁵ and stained with MHE⁶ (A, B, C) and PAS/AB⁷ (D): **A-** 4x⁸, surface body wall showing eosinophilic debris and spirocysts in mucus layer (↑); **B-** 2x, surface body wall showing necrotic tissue preceding the termination (↑); **C-** 20x, showing ovum vacuolization of surrounding wall (↑); **D-** note fungal [hyphae](#) invading gastrodermis of basal body wall (↑).

Slide 2

Signalment/History: *Dichocoenia stokesii* (IRCP 225) collected from Navassa Island, US National Wildlife Refuge, on November 2004.

Field Diagnosis: Presumed white plague.



Figures 7 A & B. White plague lesion on *Dichocoenia stokesii*: **A-** field photo (Dana Williams); **B-** fixed specimen (Molly Billmyre).

Histopathology Description (Fig. 8):

Coenenchyme: Diffusely, in surface body wall, there are few zooxanthellae. Surface body wall diminishes progressively. There is abrupt termination of the epidermis and gradual diminution of the basal body wall.

Polyp: Near the edge of the section, there is [full thickness](#) ablation of the surface body wall revealing underlying mesenteric filaments with necrotic gastrodermis characterized by dissociation of cells (Fig. 8A&B, ↑). Moderate numbers of [coccidian](#) oocysts are within lobes of mesenterial filaments (Fig. 8C, ↑). The apposition of these 2 layers at the edge of a lesion is indicative of the first stages of tissue repair (Fig. 8D, ↑).

Skeleton: No remarkable lesions seen.

Morphologic Diagnosis:

- Severe, focal, ablation associated with gastrodermal necrosis, surface body wall, and polyp.

Recommendations:

- Conduct further characterization to investigate and better understand the process of tissue repair in corals.
- Conduct laser capture of the coccidian oocysts within the lobes of the mesenterial filaments in order to further identify.

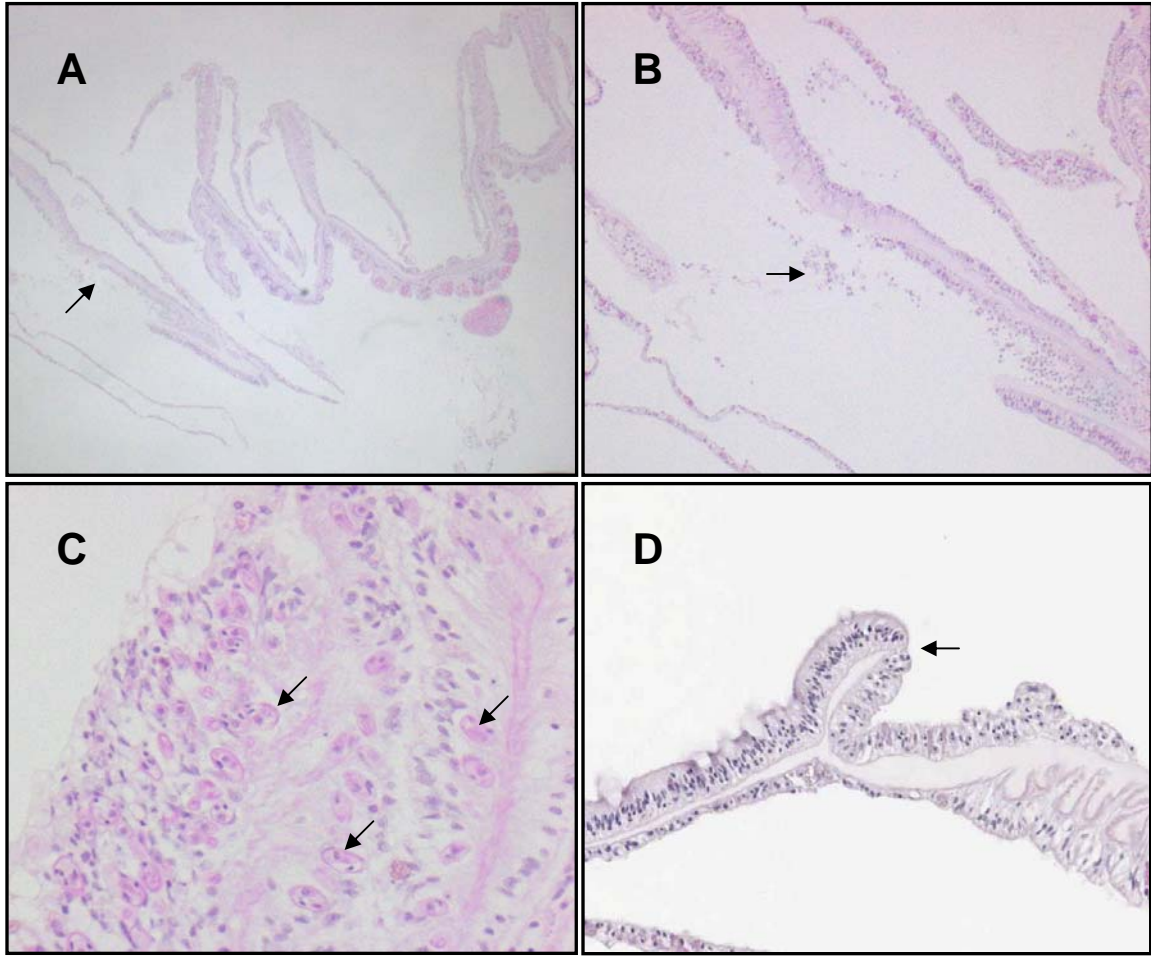


Figure 8 A-D. Photomicrographs of diseased *Dichocoenia stokesii* tissue fixed in seawater:Z-Fix and stained with MHE: **A-** 4x, necrotic gastrodermis (↑); **B-** 20x enlargement of **A** showing necrotic gastrodermis (↑); **C-** 40x, [Coccidia](#) in mesenterial filaments (↑); **D-** apposed epidermis and gastrodermis (↑).

⁵ Anatech Ltd., Battle Creek Michigan.

⁶ MHE = Mayer's Hematoxylin and Eosin (AFIP).

⁷ PAS/AB = Periodic Acid Schiff/Alcian Blue (AFIP)

⁸ All magnifications provided for photomicrographs reflect the objective used, not that the image is magnified that many times

Slide 3

Signalment/History: *Acropora palmata* (IRCP 206-3B) collected from Mona Island, Puerto Rico on 13 July 2004 by Andy Bruckner.

Field Diagnosis: Presumed white band disease.




Figure 9 A & B. Presumed white band disease observed on *Acropora palmata*: **A-** field photo (Andy Bruckner); **B-** fixed specimen (Kathy Price).

Histopathology Description (Fig. 10):

Coenenchyme/Polyp: There are numerous nematodes (Fig. 10B) mixed with debris and fragments of laminar eosinophilic material (hyalinized mesoglea). Cellular debris with intact nuclei (2-3 μm) is present in the intestine of the nematodes. Surface body wall is dissociated and there is multi-focal loss of epidermis. Zooxanthellae appear pale and vacuolated. There is multifocal necrosis of gastrodermis characterized by cytoplasmic fragmentation, pyknosis, [karyorrhexis](#) and liberation of zooxanthellae with swelling of mesoglea (Fig. 10A, \uparrow). Accumulations of cellular debris are present in the lumen of the gastrovascular canals.

Polyp: Epidermal nematocysts are infrequent. There is segmental loss of mesoglea.

Skeleton: No remarkable lesions are seen.

Morphological Diagnosis:

- Mild multifocal necrosis in the gastrodermis of the coenenchyme and polyps.

Recommendation: Obtain larger section of coral tissue for examination.

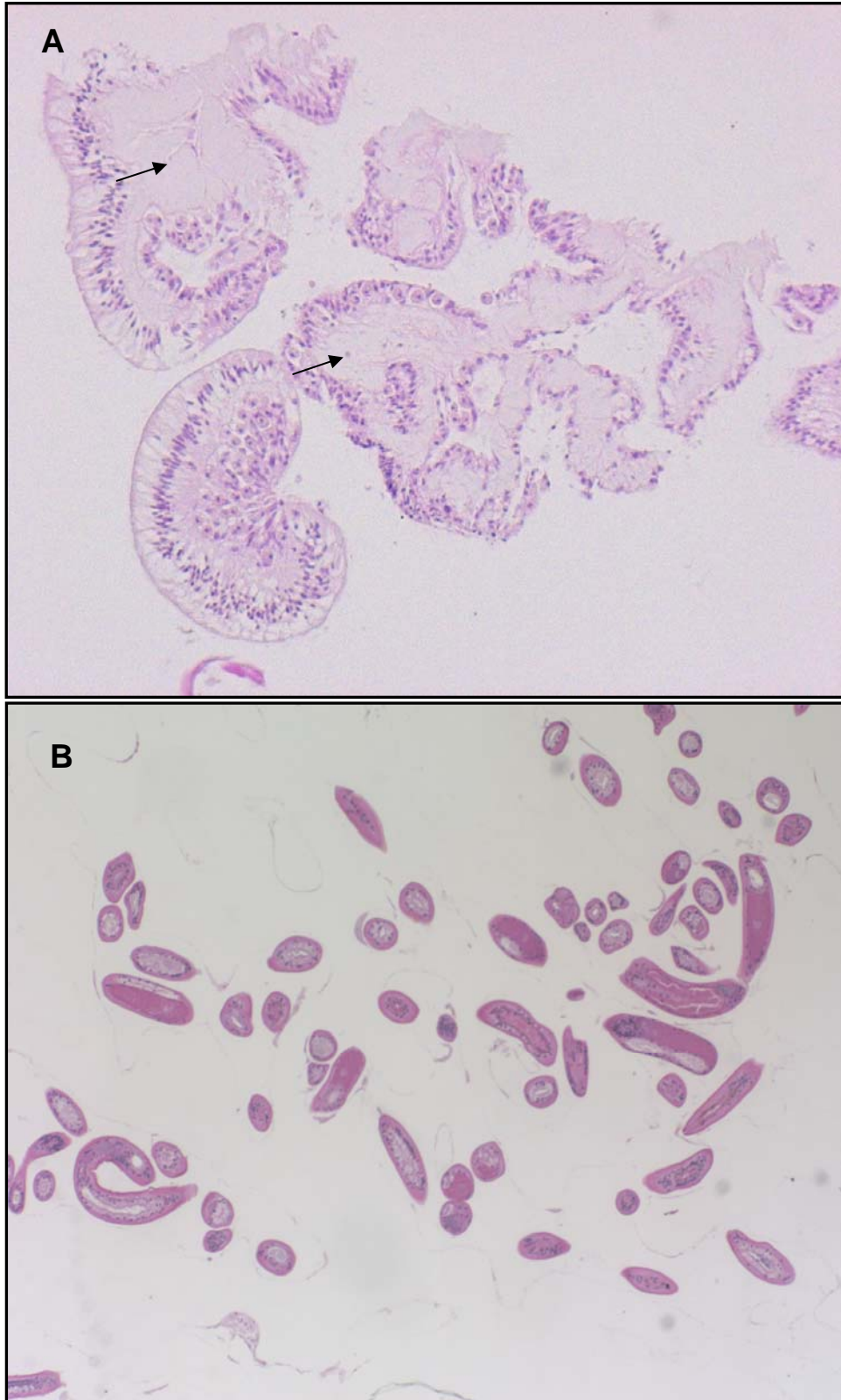


Figure 10. **A.** Photomicrograph of diseased *Acropora palmata* tissue fixed in Helly's and stained with MHE: 4x, note swelling of mesoglea (↑); **B.** Nematodes in *A. palmata* tissue; undetermined whether they are scavenging or are involved in the pathology.

Slide 4

Signalment/History: *Acropora prolifera* (IRCP 110) collected from Dry Tortugas, Florida on 23 July 2003 by Dana Williams and Margaret Miller.

Field Diagnosis: Presumed white band disease.




Figure 11 A & B. Presumed white band disease observed in *Acropora prolifera*: **A-** field photo (Dana Williams); **B-** fixed specimen (Kathy Price).

Histopathology Description (Fig. 12):

Coenenchyme: Tissue terminates abruptly as evidenced by rare isolated nests of viable tissue within gastrovascular canals within denuded skeleton remote from contiguous tissue. Numerous aggregates of basophilic rods are within mesoglea. Zooxanthellae within gastrodermis of the surface body wall appear pale. Basal body wall epidermis is segmentally attenuated and full thickness surface body wall characterized by linear arrangement of gastrodermal cells with shrunken cytoplasm. Scattered arthropods are present, adjacent to terminus of tissues, significance unknown.

Polyp: No remarkable lesions seen.

Skeleton: No remarkable lesions seen.

Morphologic Diagnosis:

- Numerous bacterial aggregates within the mesoglea of the coenenchyme.
- Moderate multifocal attenuation of the surface and basal body wall of the coenenchyme.

Recommendation: None.

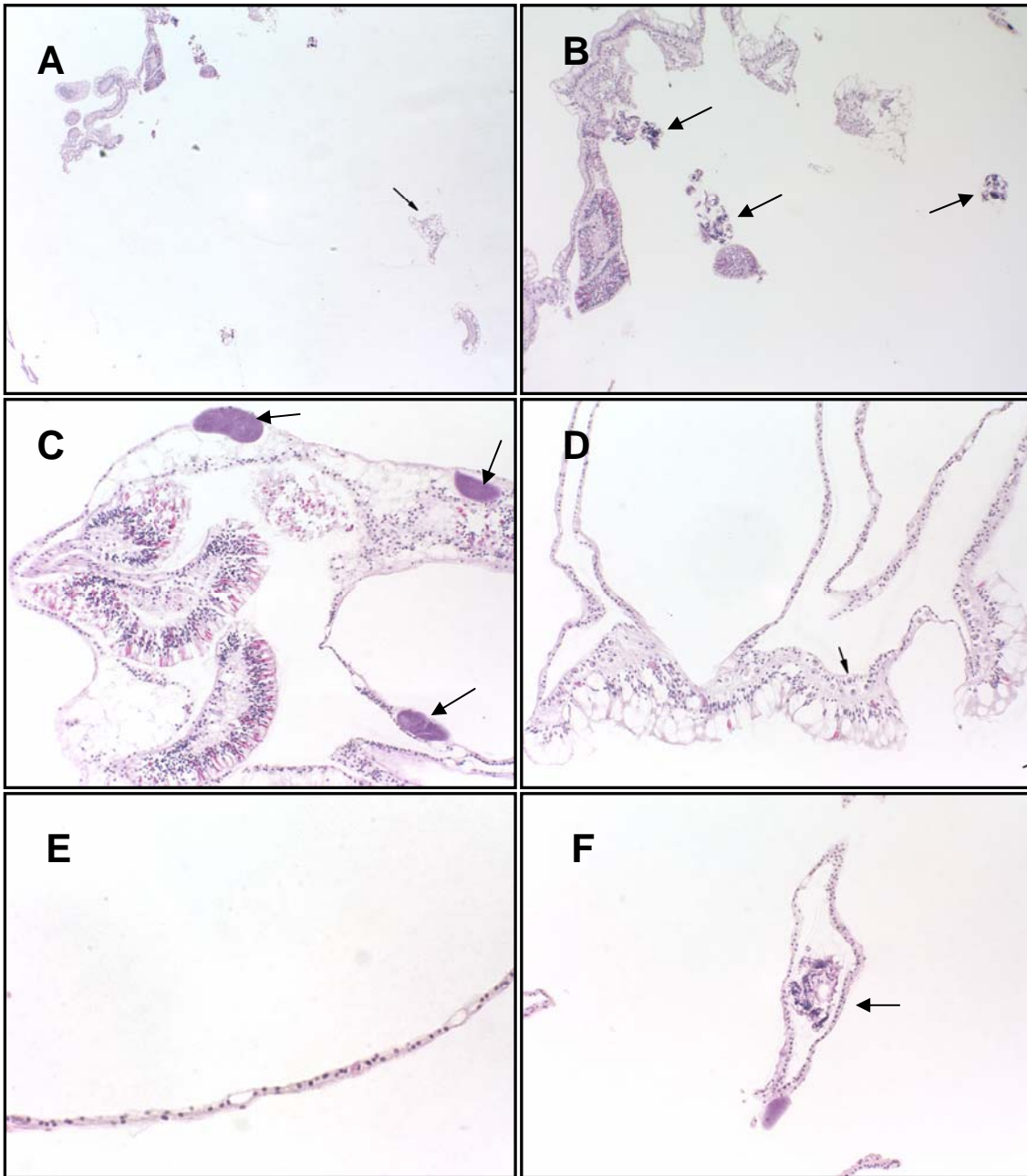


Figure 12 A-F. Photomicrographs of diseased *Acropora prolifera* tissue fixed in seawater:Z-Fix and stained with MHE: **A-** 4x, remnant tissue; **B-** 10x, arthropods; **C-** 20x, bacterial aggregates (↑) in coenenchymal basal body wall (↑); **D-** 20x, surface body wall, zooxanthellae (↑); **E-** 40x, attenuation of coenenchymal basal body wall; **F-** 20x, arthropod (↑) in lumen of gastrovascular canal, bacterial aggregate in basal body wall.

Slide 5

Signalment/History: *Siderastrea siderea* (IRCP 156-B2) collected from Turrumote, Puerto Rico on 4 April 2004 by Ernesto Weil.

Field Diagnosis: Presumed dark spots.




Figure 13 A & B. Presumed dark spots observed in *Siderastrea siderea*: **A-** field photo (Ernesto Weil); **B-** fixed specimen (Kathy Price).

Histopathology Description (Fig. 14):

Coenenchyme: There is multifocal exfoliation of 20-30% of the surface body wall. This observation may be an artifact rather than a lesion (Fig. 14B&C, ↑). Free zooxanthellae and cell debris are within canals. Diffusely, variably sized large clear vacuoles distort all cell layers (normal for *Siderastrea*) (Fig. 14D, ↑). At interface between deep gastrovascular canals and skeleton, there are multifocal dense accumulations of **pleomorphic** bulbous thick walled **nonseptate** organisms with irregular walls (fungi) (Fig. 14E, ↑). In a separate area, there is an extra-cellular matrix with cellular debris necrosis intermixed with islands of viable tissue.

Polyp: No remarkable lesions seen.

Skeleton: No remarkable lesions seen.

Other, Mucus: Sloughed cellular debris is entrapped within the mucus layer multifocally overlying regions of depressed coral tissue (Fig. 14A, ↑).

Morphologic Diagnosis:

- Severe multifocal full thickness tissue loss of the coenenchyme.
- Endolithic mycosis.

Recommendation: Prepare undecalcified **sections** for histopathologic preparation to examine the interaction of suspect fungi with tissue and skeleton.

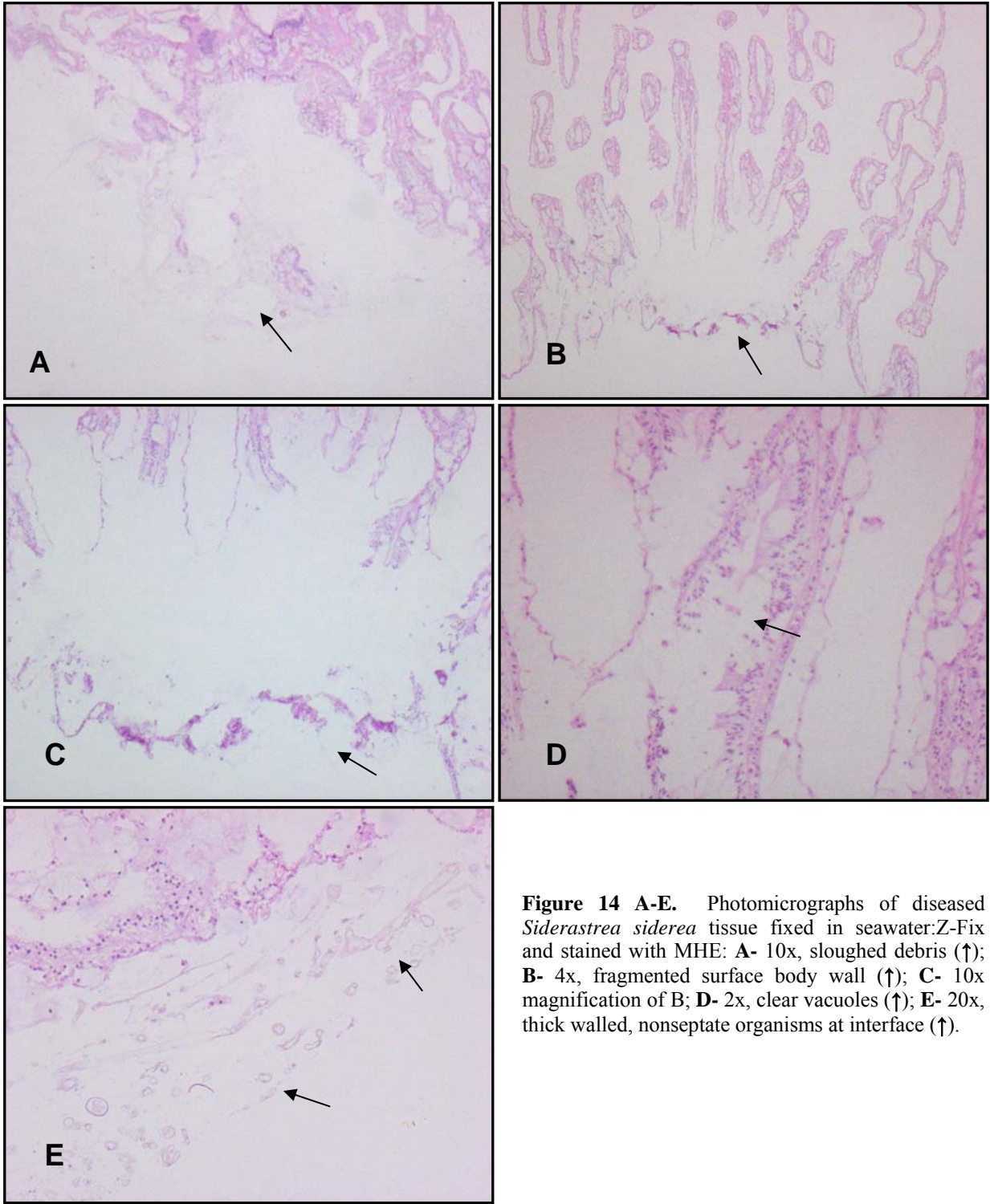


Figure 14 A-E. Photomicrographs of diseased *Siderastrea siderea* tissue fixed in seawater:Z-Fix and stained with MHE: **A-** 10x, sloughed debris (↑); **B-** 4x, fragmented surface body wall (↑); **C-** 10x magnification of B; **D-** 2x, clear vacuoles (↑); **E-** 20x, thick walled, nonseptate organisms at interface (↑).

Slide 6

Signalment/History: *Montastraea annularis* (EPA FLK9503B2) collected from Sand Key, Florida in March 1995 by Debbie Santavy.

Field Diagnosis: Presumed yellow blotch.




Figure 15 A & A'. Presumed yellow blotch observed on *Montastraea annularis*: **A**- example of gross disease signs on an affected colony, field photo, **A'**- closeup example of lesion (Esther Peters); fixed specimen photo unavailable.

Histopathology Description (Fig. 16):

(Comment: The quality of preparation is poor.)

Coenenchyme: Clumps of eosinophilic debris mixed with [pyknotic](#) nuclei are within the lumen of gastrovascular canals. This observation may be necrosis or [autolysis](#), but was not determined.

Polyp: Gastrodermis of some mesenterial filaments contains large numbers of eosinophilic granular cells. Multiple foci of gastrodermal cells are dissociating and sloughing into the lumen of gastrovascular canals (autolysis, Fig. 16C). Within the gastric cavity are accumulations of golden-brown granules. Within cnidoglandular bands are intracellular accumulations of golden-brown pigment (normal).

Skeleton: There are clumps of golden-brown debris (Fig. 16A, ↑) adjacent to a loose mat of thick non-septate, irregular walled fungal hyphae (Fig. 16B, ↑). These appear to be in the skeleton.

Morphologic Diagnosis: Undetermined.

Recommendation: None.

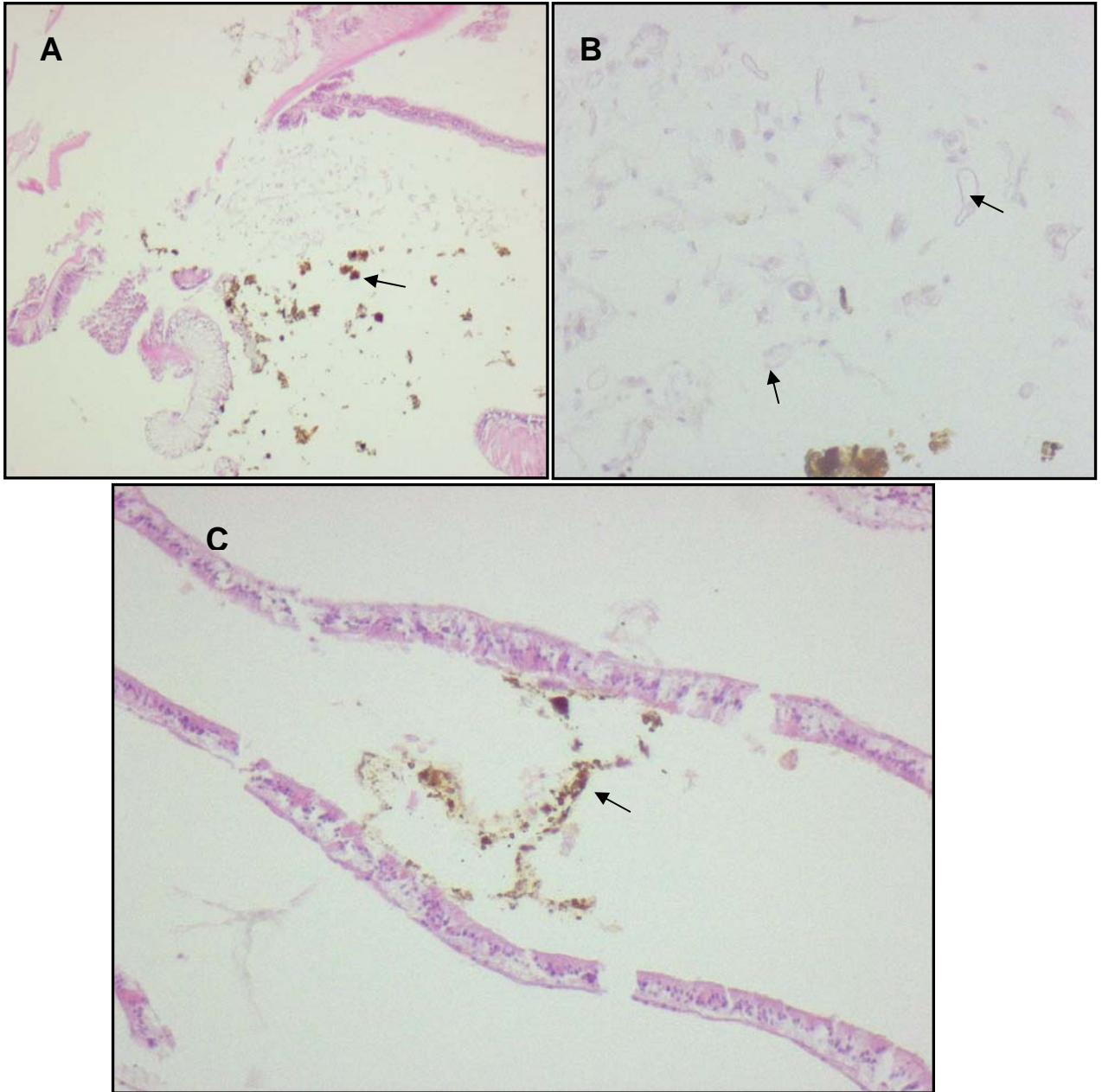


Figure 16 A-C. Photomicrographs of diseased *Montastraea annularis* tissue fixed in Helly's and stained with MHE: **A-** 10x, golden brown debris in the gastrovascular canal region that has lost its integrity (↑); **B-** 40x, loose mat of non-septate, irregular walled organisms within skeleton (↑); **C-** 20x, golden brown debris in the gastrovascular canal lumen (↑).

Slide 7

Signalment/History: *Acropora palmata* (RTLA 5091) collected from Tague Bay, US Virgin Islands on 28 July 1981 by Esther Peters.

Field Diagnosis: Colony not showing disease, but located in the vicinity of colonies with external signs of presumed white band disease.

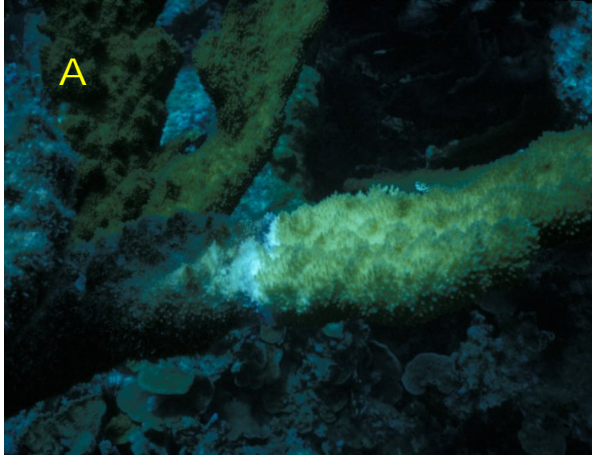


Figure 17 A. *Acropora palmata* exhibiting signs presumed to be white band disease (Esther Peters): both field and fixed specimen photos unavailable for this sample.

Histopathology Description (Fig. 18):

Coenenchyme: There is multifocal full thickness fragmentation of surface body wall on one end of the section accompanied by sloughing of gastrodermis. Multifocally, within deep basal body wall epithelia and surface body wall mesoglea is denuded (↑). Occasional bacterial aggregates (basophilic rods appearing eosinophilic) are within mesoglea of calicodermis. Zooxanthellae were diffusely interspersed in the gastrodermis, but this may suggest species variation. There are focally extensive areas where no zooxanthellae were seen in gastrodermis of surface body wall. There are free zooxanthellae within gastrovascular canals (▶).

Polyp: Cnidoglandular band cells are focally dissociated. Ova and spermaries were present.

Skeleton: No remarkable lesions seen.

Morphologic Diagnosis:

- Moderate decrease of zooxanthellae in the gastrodermis of the coenenchyme.
- Mild multifocal bacterial aggregates in the basal body wall of the coenenchyme.
- Mild multifocal fragmentation of surface body wall of the coenenchyme.

- Mild multifocal loss of the surface body wall and calicodermis of the coenenchyme.
- Mild focal dissociation of the cells in the cnidoglandular band of the polyp.

Recommendation: None.

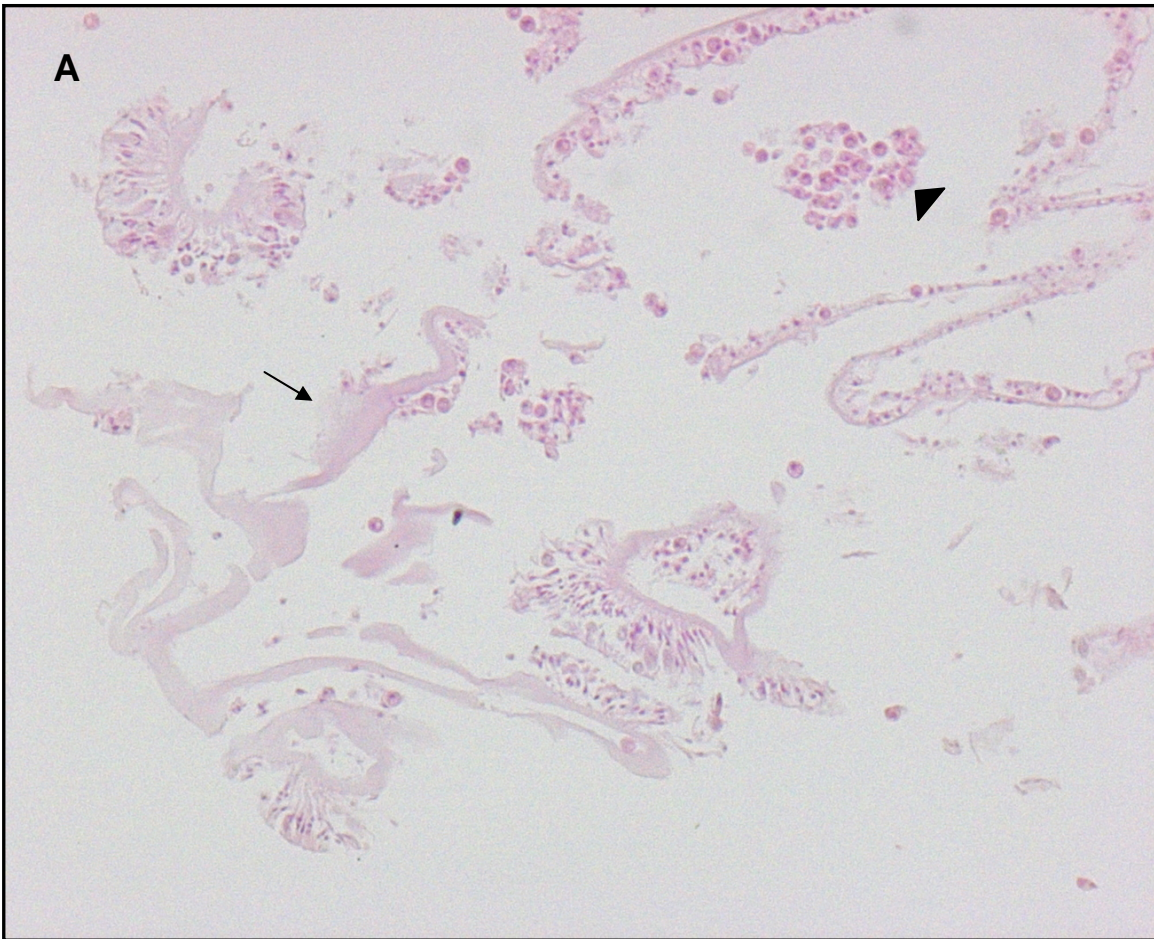


Figure 18. Photomicrograph of *Acropora palmata* tissue fixed in Helly's and stained with MHE: A- 20x, showing denuded mesoglea (↑) and free zooxanthellae in the gastrovascular canals (▶).

Slide 8

Signalment/History: *Montastraea faveolata* (IRCP 144B) collected from Weimburg, Puerto Rico in April 2004 by Ernesto Weil.

Field Diagnosis: Presumed white plague.




Figure 19 A & B. Presumed white plague observed on *Montastraea faveolata*: **A-** similar field photo (Robert Jonas); **B-** fixed specimen (Kathy Price).

Histopathology Description (Fig. 20):

Coenenchyme: Clumps of gastrodermal cells are within the lumina of gastrovascular canals. Diffusely, zooxanthellae appear to have a granular eosinophilic cytoplasm, the [pyrenoid body](#) is often difficult to visualize, and [tinctorial contrast](#) is lacking (loss of viability).

Polyp: Within one polyp, there is diffuse necrosis of gastrodermis characterized by small fragments of cytoplasm and nuclear debris free in the lumen accompanied by free zooxanthellae; this is more prevalent in the mesenteries but also found in surface body wall (Fig. 20B&C, ►). Within areas of sloughing gastrodermis, zooxanthellae appear to have a granular eosinophilic cytoplasm, the pyrenoid body is often difficult to visualize, and a tinctorial contrast is lacking (loss of viability). There is an unstructured fibrillar [amphophilic](#) mass that appears to be mesoglea and which is surrounded by extracellular zooxanthellae (Fig. 20C, ↑). Epidermis and gastrodermis is lost regionally adjacent to the mass. At the base there is segmental loss of calicodermis (Fig. 20D, ↑). There is a focus of amorphous eosinophilic debris with free zooxanthellae within a single cnidoglandular band. Spermaries noted.

Skeleton: There are mats of mixed fine eosinophilic filaments and thick irregular septate amphophilic structures (endolithic organisms) (Fig. 20A, ↑).

Other: At the periphery of the entire section, tissue lysis is suggestive of collection artifacts (↑).

Morphologic Diagnosis:

- Moderate, diffuse, necrosis, gastrodermis, mesentery and surface body wall, one polyp. **Addendum:** Upon review of the gross lesion, it appears that the lesion

described above as peripheral collection artifact was actually part of the gross margin of tissue loss (the grossly observed lesion).

Amended Morphologic Diagnosis:

- Diffuse gastrodermal necrosis, circumferential polyps.

Recommendation: Perform a silver stain for demonstration of fungi.

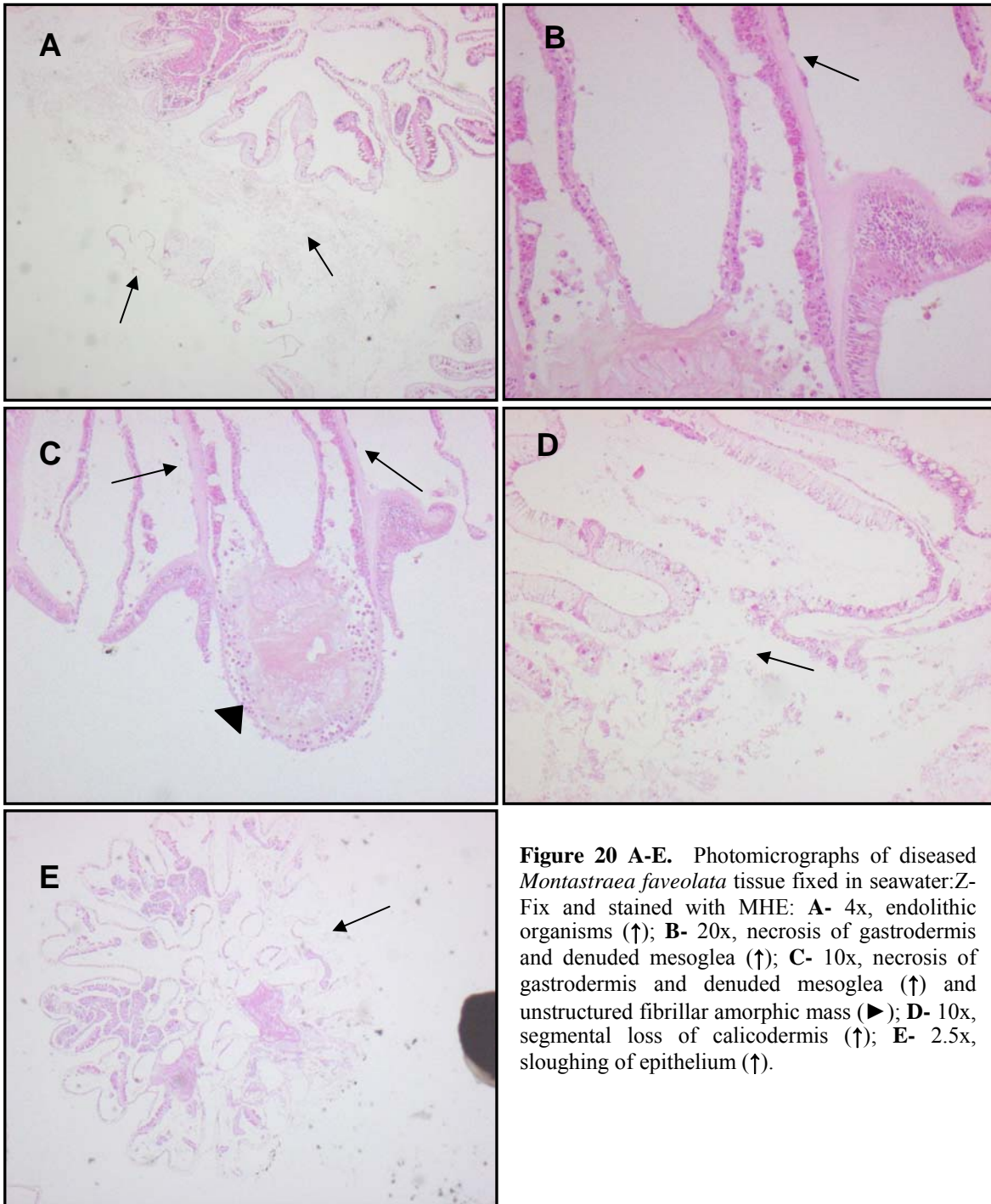


Figure 20 A-E. Photomicrographs of diseased *Montastraea faveolata* tissue fixed in seawater: Z-Fix and stained with MHE: **A-** 4x, endolithic organisms (↑); **B-** 20x, necrosis of gastrodermis and denuded mesoglea (↑); **C-** 10x, necrosis of gastrodermis and denuded mesoglea (↑) and unstructured fibrillar amorphous mass (▶); **D-** 10x, segmental loss of calicodermis (↑); **E-** 2.5x, sloughing of epithelium (↑).

Slide 9

Signalment/History: *Acropora cytherea* (USGS 15440-006B) collected from Johnston Atoll, Central Pacific on 30 March 2001 by Thierry Work.

Field Diagnosis: Growth anomaly.




Figure 21 A. Malformed *Acropora cytherea*: A-field photo (Thierry Work); fixed specimen photo unavailable.

Histopathology Description (Fig. 22):

Coenenchyme: Multifocal, poorly demarcated, unencapsulated regions of proliferation of haphazardly folded calicodermis with decreased space separating them (increased soft tissue density relative to skeletal density) are present (Fig. 22A, ↑). These regions are composed of well-differentiated gastrodermis and calicoblastic epithelium (+/- increased cell density) and fewer polyps. Gastrodermal cells within the regions of proliferation are cuboidal and well-differentiated with round [euchromatic](#) nuclei and vacuolated cytoplasm. Calicoblastic epithelial cells are also well differentiated with euchromatic nuclei (Fig. 22B, ↑). Mitoses are not observed. This region is covered by [surface body wall](#); multifocally, the gastrodermis has few to no zooxanthellae and the epidermis lacks mucocytes. Mesoglea in the deep calicodermis is focally denuded.

Polyp: Within the regions of proliferation, there is general absence of polyps. Existing polyps are haphazardly arranged within the peripheral regions of the masses (Fig. 22C, ↑).

Skeleton: No remarkable lesions seen.

Morphologic Diagnosis:

- Multifocal extensive hyperplasia of gastrovascular canals with an absence of zooxanthellae in the coenenchyme:

- chaotic arrangement of scant polyps and,
- overlying surface body wall lacks mucocytes and spirocysts.

Recommendation: Conduct immunohistochemical stains for calicoblastic epithelium.

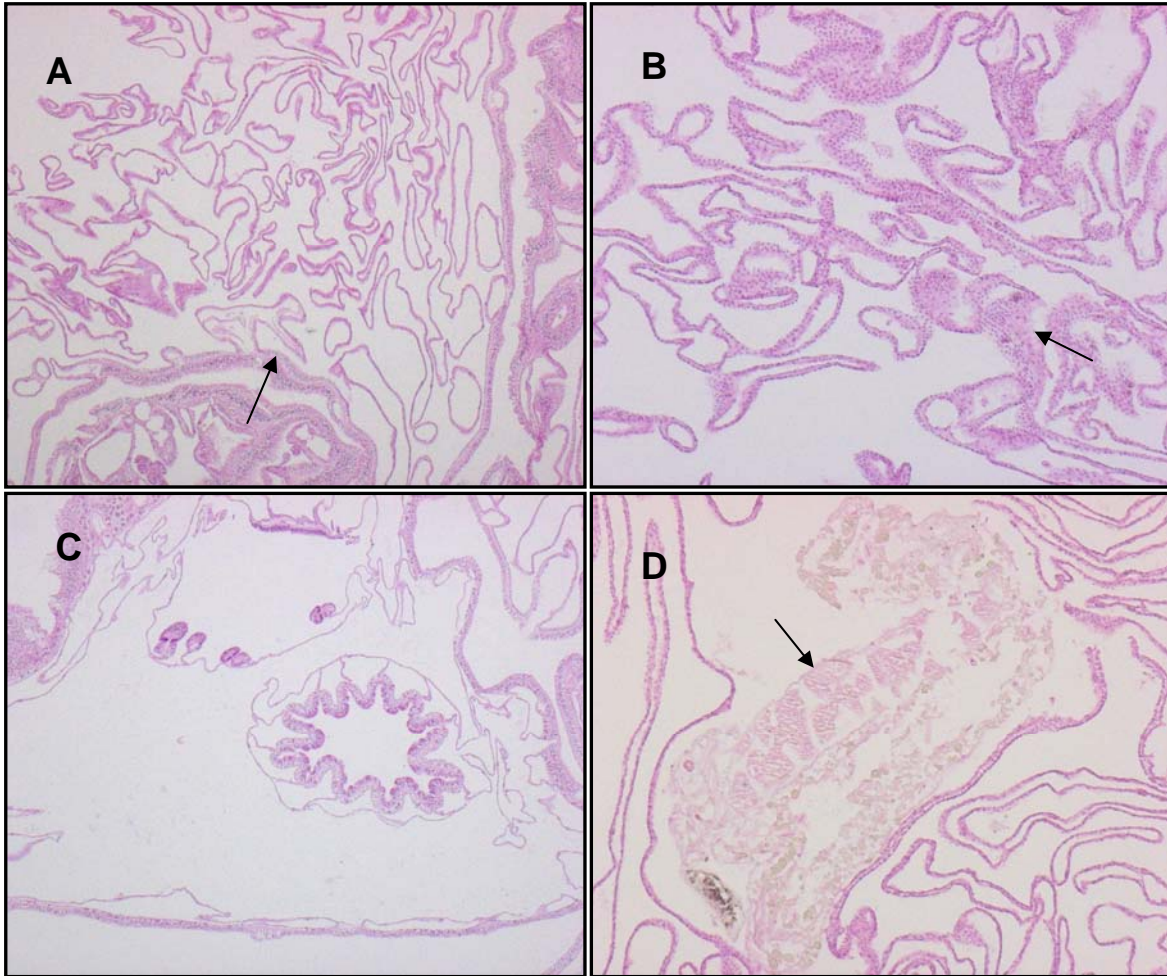


Figure 22 A-D. Photomicrographs of diseased *Acropora cytherea* tissue fixed in Helly's and stained with MHE: **A-** 10x, haphazardly folded basal body wall (↑); **B-** 10x, high density of well-differentiated calicoblastic epithelial cells (↑); **C-** 4x, chaotic arrangement of polyps; **D-** 10x, showing metazoan organism (↑).

Slide 10

Signalment/History: *Siderastrea siderea* (IRCP 97-1) collected from Maryland Shoals, Florida, on 15 July 2003 by Esther Peters.

Field Diagnosis: Presumed dark spots.

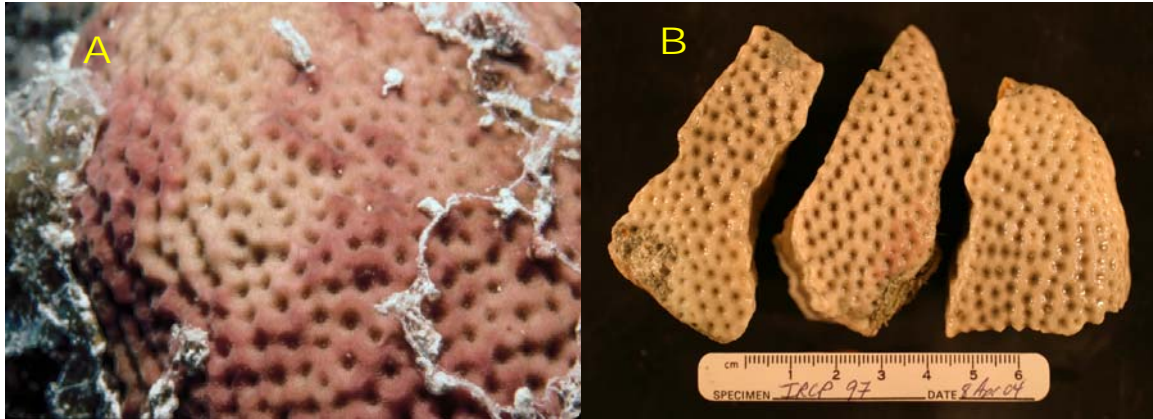


Figure 23 A & B. *Siderastrea siderea* observed with presumed dark spots disease: **A-** similar field photo (Esther Peters); **B-** fixed specimen (Kathy Price).

Histopathology Description (Fig. 24):

Polyp: There are two pieces of tissue on this histoslide. One was embedded so that the section is through the upper polyp region and there are nice cross-sections through the polyps above the oral disc, showing tentacular and septal covering tissues. There is no evidence of skeletal endolithic organisms in most of this piece. At one margin, there is one polyp that is cut through a slightly deeper plane on one side so that two mesenteries with oocytes are shown. Endolithic organisms are present in the septa adjacent to the gonad bearing mesenteries in this polyp (Fig. 24A, ↑). The other piece of tissue was embedded as a longitudinal section of polyps from the colony margin, which had appeared “dark” when collected. The lesion edge is colonized by mixed plants and animals (Fig. 24B, ↑). There are few zooxanthellae within gastrodermis, and those present were often shrunken with pale granular cytoplasm with indistinct cell walls. Large variably sized vacuoles distort the epidermis and gastrodermis of surface body wall and gastrodermis of mesenteries (species variation).

Coenenchyme: No remarkable lesions seen.

Skeleton: The skeleton shows an increased density of endolithic organisms aborally. The calicoblastic epidermis adjacent to, and sometimes being touched by the endoliths, has swollen and vacuolated mucocytes and the contents of the acidophilic granulocytes are dispersed, or the epidermis is necrotic (Fig. 24A, ↑).

Morphologic Diagnosis:

- Severe diffuse degeneration of zooxanthellae.

- Endolithic mycosis.
- Full thickness disruption of the basal body wall at the leading edge of the endolithic fungi.

Recommendations:

- Stain with PAS and GMS to identify fungi.
- Examine histology of dark spot in species other than *Siderastrea*.
- Perform TEM on zooxanthellae.

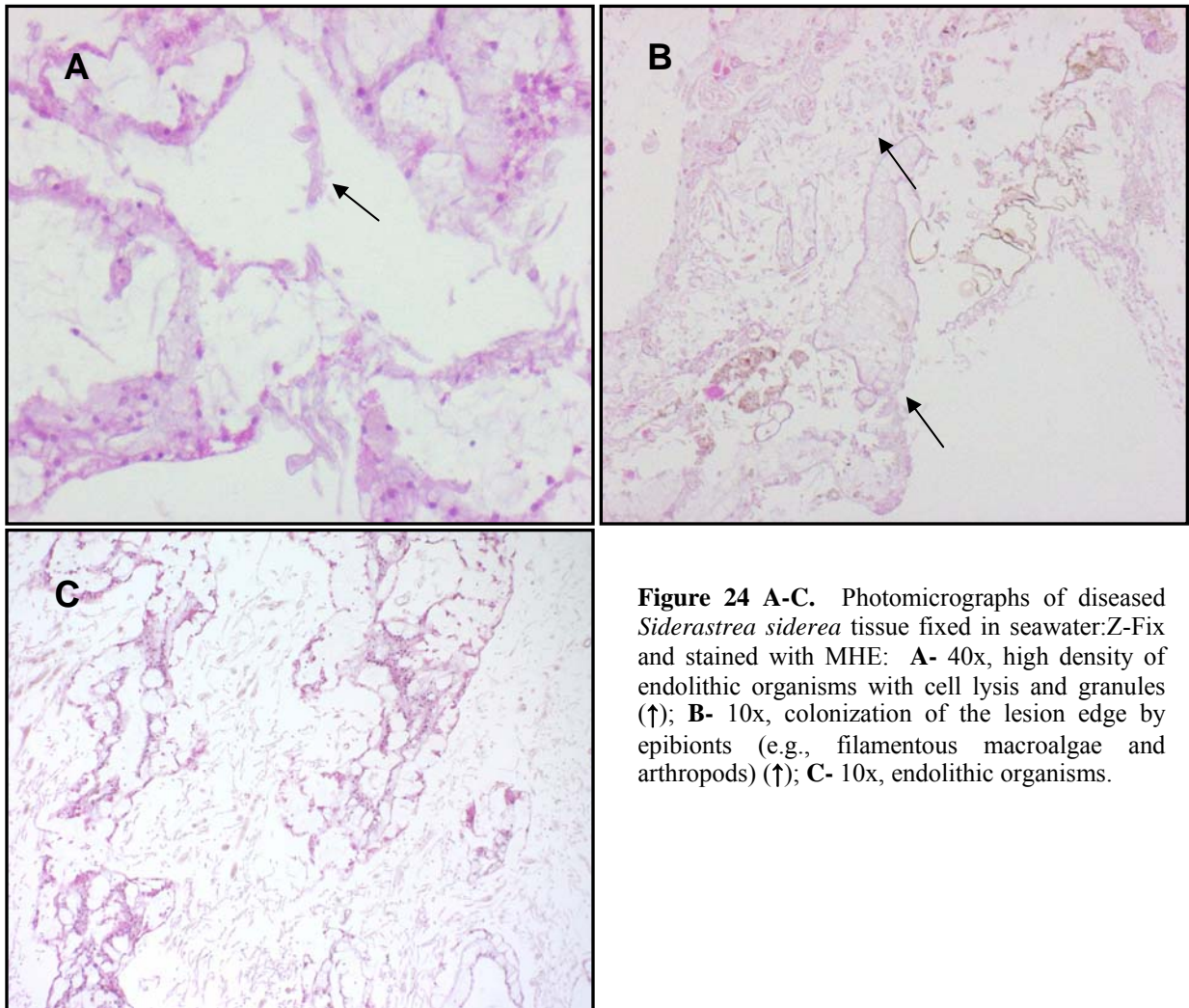


Figure 24 A-C. Photomicrographs of diseased *Siderastrea siderea* tissue fixed in seawater:Z-Fix and stained with MHE: **A-** 40x, high density of endolithic organisms with cell lysis and granules (↑); **B-** 10x, colonization of the lesion edge by epibionts (e.g., filamentous macroalgae and arthropods) (↑); **C-** 10x, endolithic organisms.

Slide 11

Signalment/History: *Gorgonia ventalina* (IRCP 151-B2) collected from Turrumote, Puerto Rico on 4 April 2004 by Ernesto Weil.

Field Diagnosis: Presumed aspergillosis.

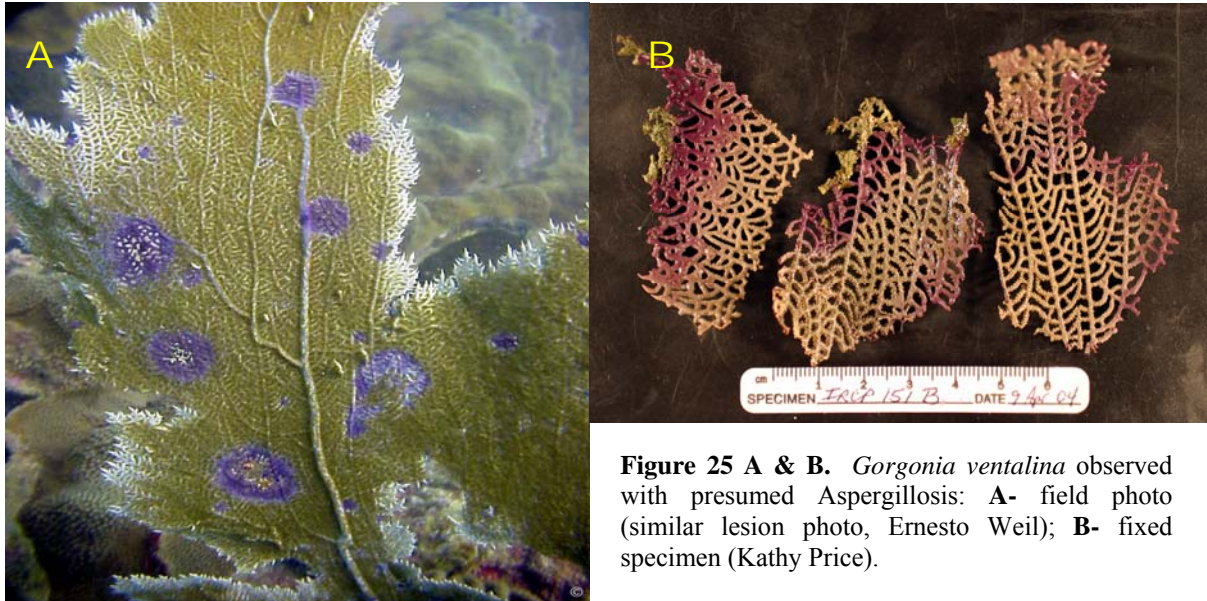


Figure 25 A & B. *Gorgonia ventalina* observed with presumed Aspergillosis: **A-** field photo (similar lesion photo, Ernesto Weil); **B-** fixed specimen (Kathy Price).

Histopathology Description (Fig. 26):

Polyp: No remarkable lesions are seen.

Skeleton/coenenchyme: There are large clefts between tissue and gorgonin and within gorgonin. In some cases, fan-shaped clusters of thin branching non-staining structures invade the edge of the gorgonin (Fig. 26A, ↑). Tissues adjoining the cleft are lined by a thin brown membrane ([melanized](#) gorgonin cortex) (Fig. 26A, ►). Gorgonin cortex is thickened and melanized surrounding empty clefts and infected regions of gorgonin. Multifocally, the edge of the cortex is frayed. Adjoining these clefts are numerous eosinophilic granular cells (Fig. 26B, ↑). Within solenia are aggregates of cellular debris (Fig. 26C, ↑). In some cases, within the clefts, are large non-parallel walled structures containing intraluminal [pyriform](#) bodies. Cyanobacteria and concatenated rods and algae are also seen. These are surrounded by homogenous eosinophilic material.

Morphologic Diagnosis:

- Granulocytic infiltration of the mesoglea associated with moderate multifocal intra-gorgonal fungi.

Recommendation: None.

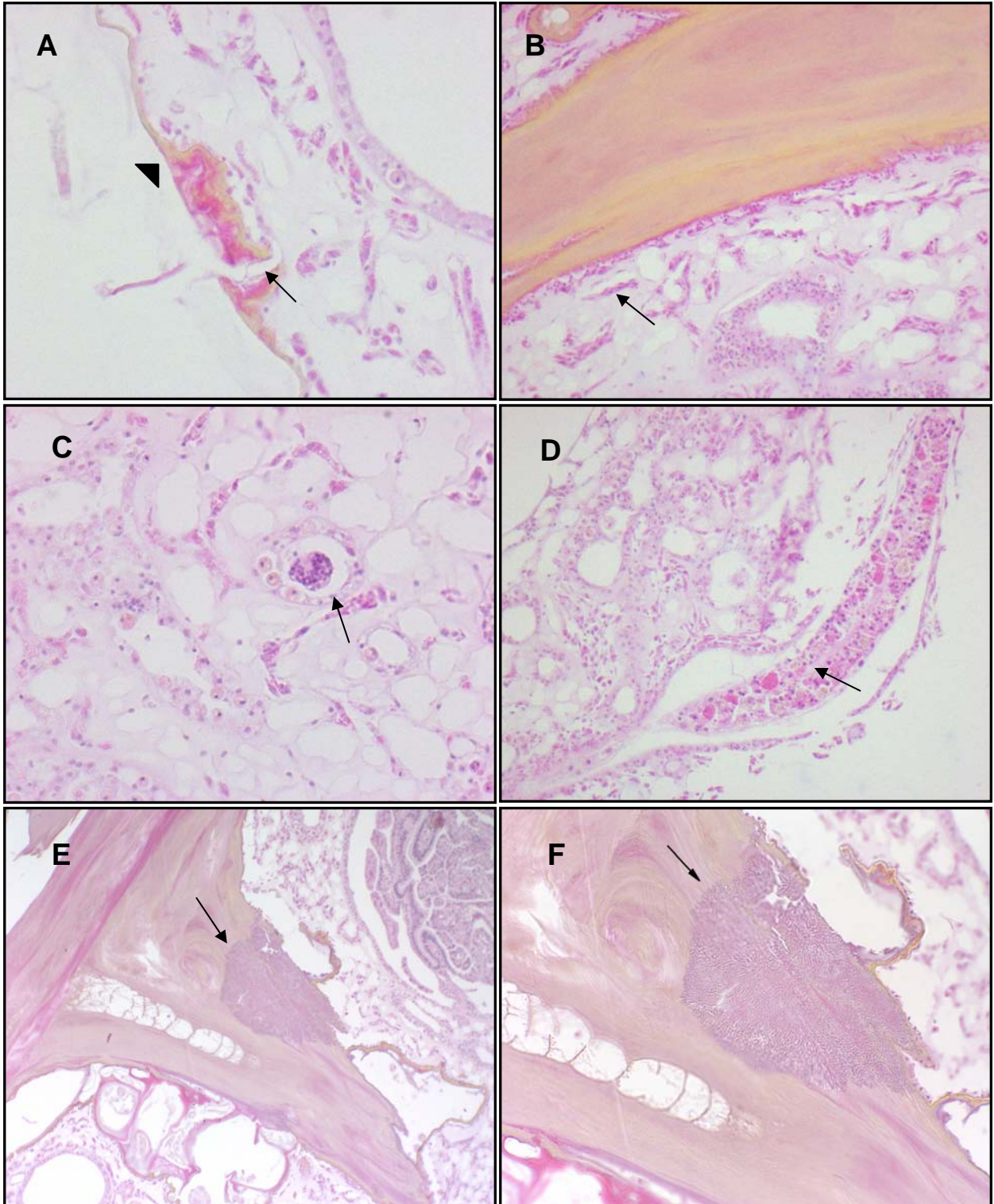


Figure 26 A-F. Photomicrographs of diseased *Gorgonia ventalina* tissue fixed in seawater:Z-Fix and stained with MHE: **A-** showing non-staining structures (hyphae) (↑) and deposited melanin (yellowish area) with adjacent tiny granules (▶); **B-** 20x, aggregates of eosinophilic granular cells (↑); **C-** accumulations of debris in the lumen of the solenia (↑); **D-** 10x, cross section of a planula (↑); **E-** 10x, note fan-shaped aggregation of fungal hyphae (↑); **F-** higher power view of fan-shaped invasion of fungal hyphae (↑).

Slide 12

Signalment/History: *Montastraea faveolata* (IRCP 154-B3) collected from Turrumote, Puerto Rico on 4 April 2004 by Ernesto Weil.

Field Diagnosis: Presumed yellow blotch.




Figure 27 A & B. Presumed yellow blotch observed in *Montastraea faveolata*:
A- field photo (photo similar lesion, Ernesto Weil); **B-** fixed specimen (photo: Kathy Price).

Histopathology Description (Fig. 28):

Coenenchyme: Unremarkable.

Polyp: Unremarkable.

Skeleton: There are sparse mats of large filamentous irregular structures (Fig. 28B).

Morphologic diagnosis: No remarkable lesions.

Recommendation: Reevaluate section.

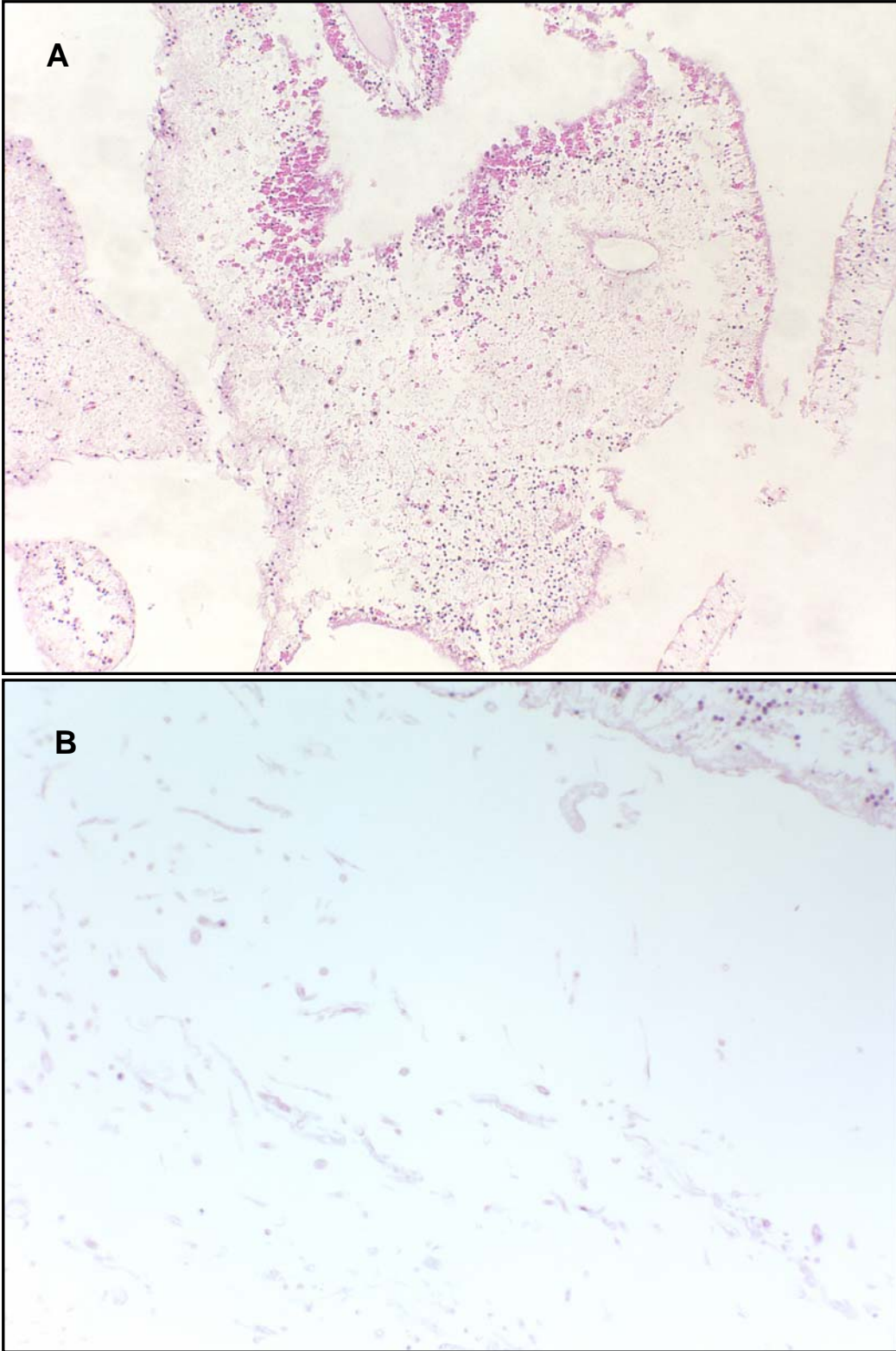


Figure 28. Photomicrograph of *Montastraea faveolata* tissue fixed in seawater:Z-Fix; **A-** 10x, unusual cut of an otherwise normal sample; **B-** 20x, sparse mats of large filamentous structures.

Slide 13

Signalment/History: *Acropora prolifera* (IRCP 57) collected from Dry Tortugas, Florida on 5 June 2003 by Dana Williams and Margaret Miller.

Field Diagnosis: Sloughing tissue, no obvious diagnosis.




Figure 29 A & B. Sloughing tissue in *Acropora prolifera*: A- field photo (Dana Williams); B- fixed specimen (Kathy Price).

Histopathology Description (Fig. 30):

Coenenchyme: Moderate numbers of aggregates of basophilic bacilli are within the mesoglea between calicodermis and gastrodermis of the basal body wall lining gastrovascular canals (Fig. 30A, ↑). Some of the aggregates are in a space surrounded by mesoglea. There is an abrupt termination of viable tissue (full thickness) on one edge (Fig. 30B, ↑). Associated with that abrupt termination are numerous crustaceans (Fig. 30B, ►) and occasional ciliates and diatoms. Ova and spermaries are absent.

Polyp: No remarkable lesions are seen.

Skeleton: No remarkable lesions are seen.

Morphologic Diagnosis:

- Multiple bacterial aggregates located within the mesoglea of the gastrodermis and basal body wall.
- Focal acute full tissue thickness loss with associated crustacean and ciliates.
- Occasional ciliates are present within gastrovascular canals.

Recommendation: None.

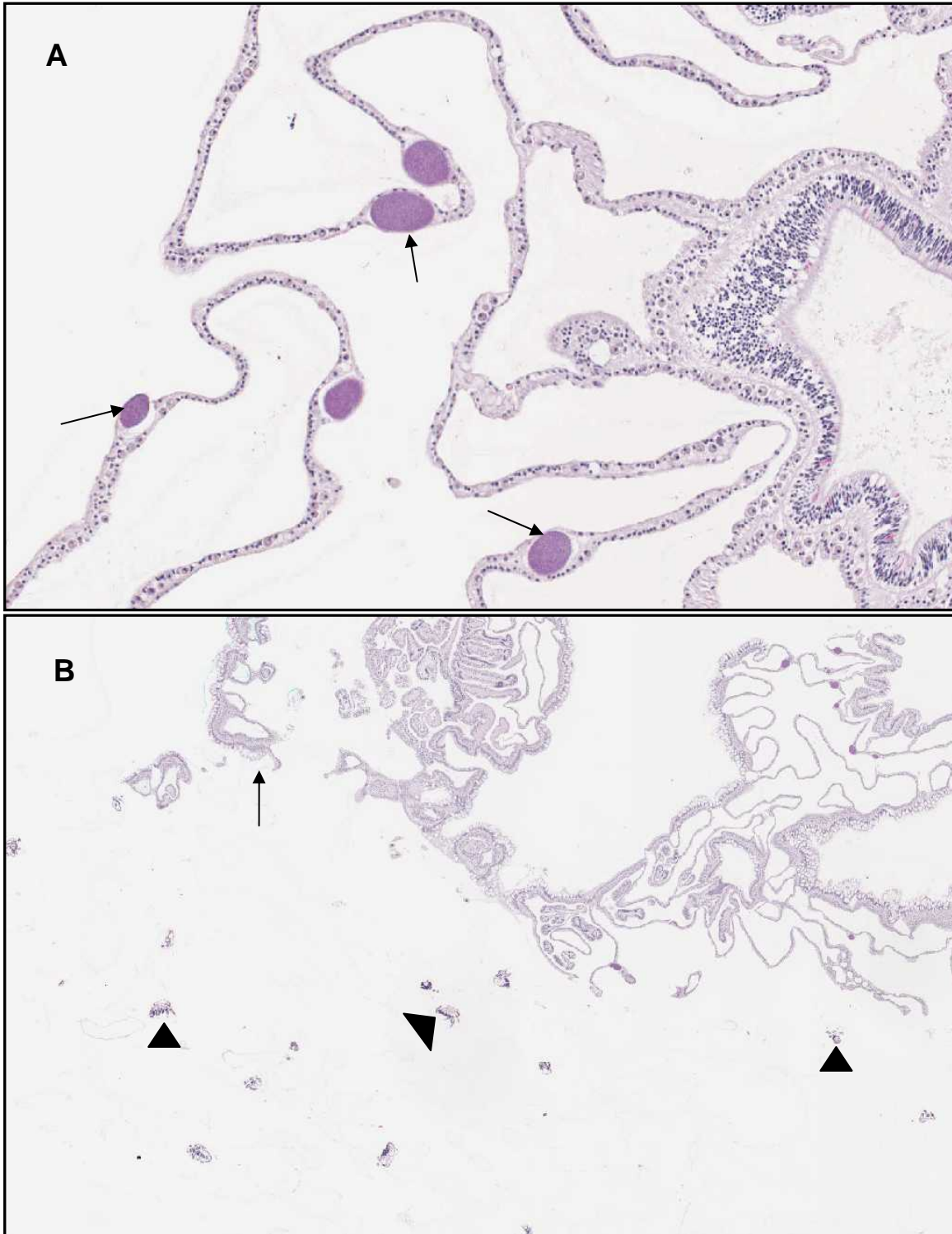


Figure 30 A & B. Photomicrographs of *Acropora prolifera* tissues fixed in seawater:Z-fix and stained with MHE: **A-** 10x, aggregates of ovoid basophilic bodies (not shown here, these are composed of basophilic rods) (↑); **B-** showing abrupt termination (↑) and crustaceans (▴).

Slide 14

Signalment/History: *Montastraea annularis* (IRCP 18-2) collected from Tague Bay, US Virgin Islands collected on 10 July 1980 by Esther Peters.

Field Diagnosis: Black band disease.

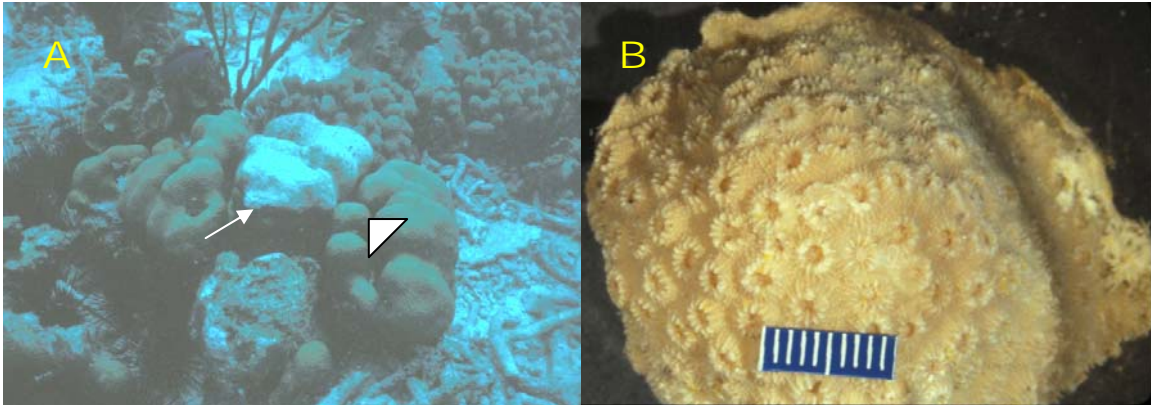


Figure 31 A & B. Black band disease in *Montastraea annularis*: **A-** field photo (Esther Peters); **B-** fixed specimen, scale =1 cm (Esther Peters); taken from area adjacent (►) to diseased tissue (↑) as shown in Fig. 31A.

Histopathology Description (Fig. 32):

(Comment: Staining quality is poor; tissue not representative of black band edge.)

Coenenchyme: No remarkable lesions are seen.

Polyp: Near one edge of the section is a large sponge (Fig. 32A, ↑). The sponge tissue is separated from the coral tissue. There numerous endolithic organisms between the sponge and coral polyp. An adjacent polyp has vacuolization of the polyp epidermis (Fig. 32A, ►); it lacks nuclei and stains pale. There is loss of integrity (Fig. 32B, ↑) exemplified by cell lysis with release of zooxanthellae.

Skeleton: Mats of non-staining wide structures with asymmetric walls and bulbous filaments are present, suggestive of endolithic fungi.

Morphologic diagnosis:

- Acute necrosis of polyps.
- A focus of endolithic fungi.

Addenda: The lesions observed were not related to black band mats.

Recommendation: None.

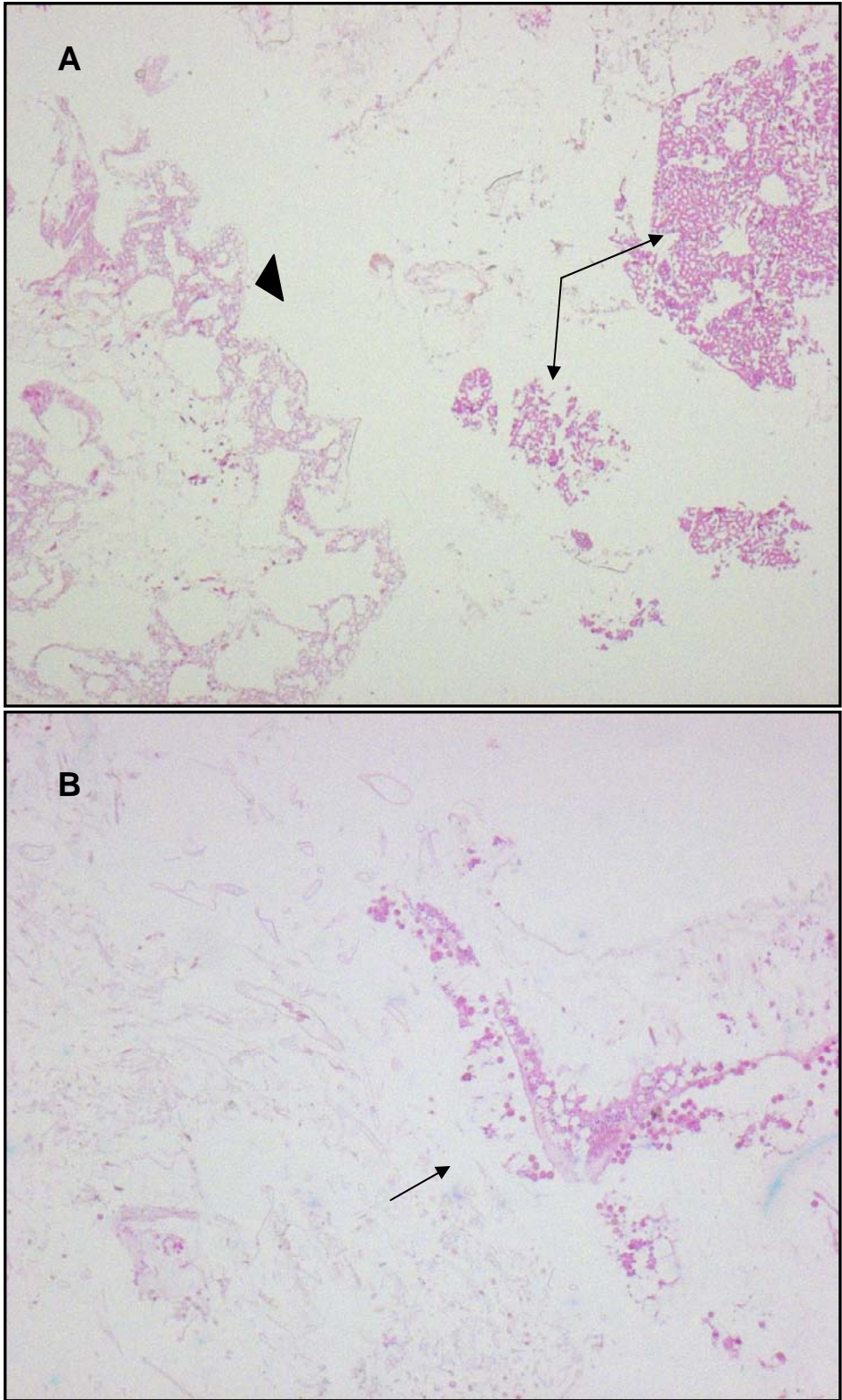


Figure 32 A & B. Photomicrographs of diseased *Montastraea annularis* tissues fixed in Helly's and stained with MHE: **A-** 4x, showing a large sponge (↑) and polyp remnant (▶) along with unidentifiable debris between the sponge and polyp; **B-** 10x, polyp fragmentation (↑); abundant endolithic fungi.

Slide 15

Signalment/History: *Acropora cervicornis* (IRCP 178) collected from the Virgin Islands on 15 July 2004 by Lou Sileo, Thierry Work and Caroline Rogers.

Field Diagnosis: Suspected snail predation.




Figure 33 A & B. Suspected snail predation observed on *Acropora cervicornis*: **A-** field photo (Thierry Work); **B-** fixed specimen (Kathy Price).

Histopathology Description (Fig. 34):

Coenenchyme: Full tissue thickness loss culminates in abrupt termination (Fig. 34A, ↑). Epidermis is segmentally lost and gastrodermis is atrophied. Ova are abundant (Fig. 34B, ↑). Adjacent to intact tissue are scattered arthropods in the lumina of non-viable gastrovascular canals mixed with clumps of necrotic tissue characterized by aggregates of eosinophilic debris and **karyorrhectic** nuclei mixed with zooxanthellae. The deep gastrovascular canals are bereft of viable tissue, and this is more prominent at the edge of viable and non-viable tissue. There is diffuse depletion of zooxanthellae from gastrodermis. In deeper tissues, there are eosinophilic lamina (hyalinized mesoglea) sometimes associated with spiral and rod-shaped bacteria.

Polyp: Within the mesoglea of a mesentery is a single irregularly round structure with central basophilic inclusions and a central nucleus surrounded by a vacuole (40-60 μm) (Fig. 34C, ↑). Also within mesenteries, within gastrodermal cells and near ova, are round brightly eosinophilic homogenous structures about the same size as zooxanthellae (Fig. 34C, ↑). Within deep gastrovascular canals, there is multifocal disassociation of gastrodermal cells of mesentery and attenuation of calicodermis (Fig. 34D, ↑).

Skeleton: No remarkable lesions are seen.

Morphologic Diagnosis:

- Abrupt tissue loss of the coenenchyme and polyps.

- Severe diffuse reduction of zooxanthellae in the gastrodermis and coenenchyme.
- Focal sloughing of the gastrodermis and epidermis of the coenenchyme.
- Multiple eosinophilic inclusions in the tissue of the gastrodermis surrounding the oocytes.

Recommendation: None.

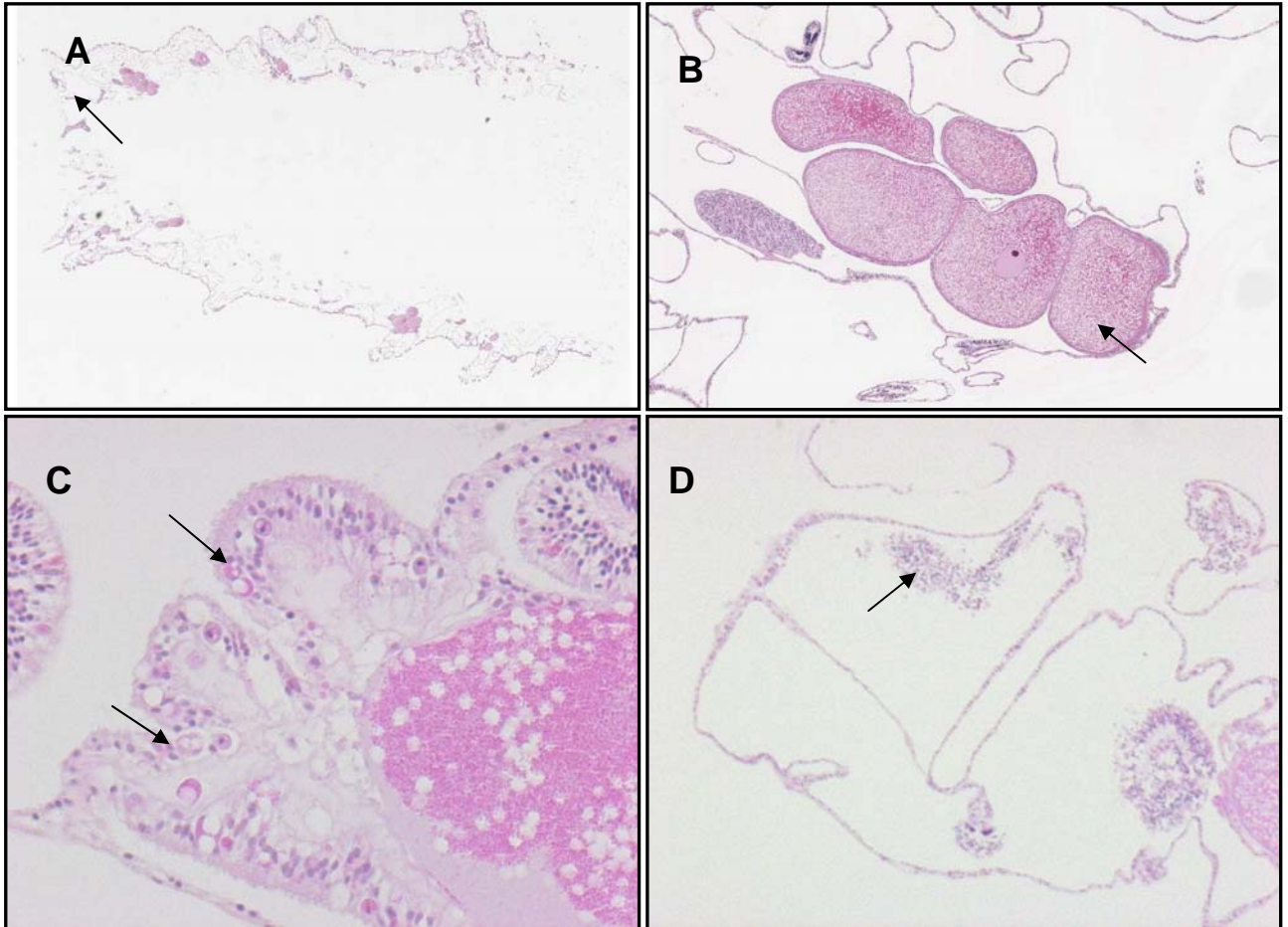


Figure 34 A-D. Photomicrographs of *Acropora cervicornis* tissues fixed in seawater:Z-fix and stained by MHE: **A-** showing abrupt termination (↑); **B-** 2x, abundant ova (↑); **C-** 40x, brightly eosinophilic structures (↑) and zooxanthellae; **D-** 10x, disassociated gastrodermal cells (↑).

WORKSHOP SUMMARY

Workshop Achievements

The goals and objectives set for the Workshop were met and exceeded. The following areas capture achievements from this workshop:

Nomenclature for Microscopic Anatomy of Corals

The first formalized group effort to describe the histopathology of coral lesions was undertaken at this workshop. During the deliberations several of the participants expressed concern about the lack of adequate terminology for histopathologists to precisely describe the locations of lesions in hexacorals and octacorals. Several new terms were suggested that were thought to better identify tissues by function, recognizing that different etiologic agents can affect different functional tissues and have very different effects on the animal. As a result, the drafting of a white paper has been recommended that outlines the coral histopathology terminology dilemma, offers suggested terminology and definitions, and seeks critical review from the invertebrate zoology, histology, cell biology and pathology communities.

Coral Lesion Description and Diagnostic Criteria

Over 40 different coral ‘diseases and syndromes’ have been reported worldwide (Green and Bruckner 2000). Participants at this workshop conducted a histopathology review of 15 lesions from 9 presumed disease conditions based on gross observations (aspergillosis, black band, dark spots, growth anomaly, yellow blotch, white band, white patch, white plague II and an unknown disease characterized by tissue sloughing) and one presumed physical damage (snail predation). These lesions were collected from 8 scleractinian coral species (*Acropora cytherea*, *Acropora palmata*, *Acropora prolifera*, *Dichocoenia stokesii*, *Montastraea annularis*, *Montastraea faveolata*, *Siderastrea siderea*) and one gorgonian species (*Gorgonia ventalina*).

This review provided a consensus of microscopic findings associated with each of these lesions and consistent findings were noted for some of the field diagnosed diseases. These did not provide, however, definitive differential diagnostic characters for any of the diseases except gorgonian mycosis. The descriptions for all of the lesions though will provide benchmarks for future studies.

Obviously these efforts were only the beginning of an in-depth, critical comparative review of coral lesions to confirm field diagnoses. There remain a number of disease lesions that were not reviewed. Many more descriptions of normal tissue and the histopathology associated with the lesions of recognized coral diseases will have to be added to these first attempts. It was also recognized that it is imperative for collection and processing techniques to be optimized with the goal of eliminating all autolysis, collection and processing artifacts.

Advanced Training

This workshop provided one of the first opportunities for board-certified medical and veterinary pathologists and invertebrate histopathologists to come together to exchange

information, identify gaps in our knowledge of, and gain experience with, coral histopathology. This workshop served as a form of continuing education or cross-training for all of the participants. As more individuals with experience in reading coral histology slides are trained to conduct coral histopathology, the field of coral pathology will grow. Their contributions along with the integration of information from marine biologists, microbiologists, virologists, toxicologists, and molecular biologists will provide more parameters to enhance the accuracy of differential diagnosis and elucidation of the pathogenesis and etiology of coral diseases. Bringing together the diversity of specialists needed to develop coral pathology is difficult, but their interest drives their involvement. We recognize that new means of facilitating these valuable interactions must be identified. One means to facilitate interactions and bring together specialists from remote locales is a new technology, introduced at this workshop, Virtual Slides. The Virtual Slide Technology allows connection among investigators via web conferencing to explore and develop coral microscopic anatomy and pathology. The participants recommended pursuing access to this technology to meet the needs of coral researchers, especially those in remote locations, interested in histology and histopathology for both education and consultation pursuits.

Overall, the following were achieved at this workshop:

- a) A standardized approach for describing microscopic morphology.
- b) A standardized format for describing histology.
- c) The initiation of standardized nomenclature for microscopic anatomy of corals.
- d) Descriptions of 15 lesions using the above formats for corals from the Atlantic and Pacific.
- e) Consensus on a standardized format for histopathology reports, nomenclature for microscopic anatomy and pathology, and recommendations to improve histological features reached during this workshop will enable development of instructional materials and distance learning tools for coral histopathology.

Coral pathologists must adopt strict standards for their field to become recognized by the medical and diagnostic communities. To take advantage of the depth and breadth of experience in those communities, standards must be adopted for (1) descriptors based on accepted medical terminology, (2) consistent and concise descriptions of lesions in the field, as well as (3) clinical morphological diagnoses in the laboratory and review of diagnostic criteria for new and emerging diseases among the coral pathology community.

RECOMMENDATIONS:

- Record the normal range of histological characteristics for the priority species of healthy corals in the Pacific and the Western Atlantic. This would include developing standardized methods to collect corals on a spatial and temporal basis and conduct histology using light and electron microscopy on selected specimens.
- Develop a web-based virtual archive of coral histology and histopathology to facilitate contributions by new scientists to the field of coral health and to enhance the capabilities of existing scientists.
- Disseminate the report via the Coral Reef Information System and other appropriate outlets.
- Develop a white paper to justify the rationale for an internationally recognized systematic terminology for coral histopathology in consultation with experts in scientific nomenclature.
- Conduct monthly reviews of coral lesions, using Virtual Slide technology and teleconferencing, to continue adding to the body of knowledge of coral histopathology.
- Recommend the kinds of data necessary for epizootiological studies. These data need to be gathered during sample collections as they will not be available later.
- Develop a standard protocol that identifies the type of samples and analyses needed based on known pathology and etiology of a disease from gross observations.
- Develop GIS expertise within the consortium for mapping disease distribution, trends and environmental factors.

ACKNOWLEDGEMENTS

The generous contribution of time, effort and expertise from a number of individuals made the *Coral Disease and Health Workshop: Coral Histopathology II* and this publication possible. We offer a sincere thank you to all of you.

We would like to recognize the Organizing Team, Drs. Lou Sileo, Shawn McLaughlin, Sylvia Galloway and Cheryl Woodley, who set the vision for the workshop, developed the agenda and identified expertise in key facets of pathology, histopathology and coral histopathology to establish a common nomenclature for the microscopic study of coral disease. Drs. Lou Sileo and Cheryl Woodley both deserve a special note of appreciation: Lou for his efforts and time prior to the meeting to devise a process to effectively generate a morphologic diagnosis and then his hard work to shepherd the group discussions to a productive end; and Cheryl for her leadership, working with those from disciplines other than her own, which has proven crucial in moving this coral histopathology effort forward.

Particular thanks go to Ms. Julie Higgins (NOAA NOS CCEHBR) who jumped in to help with the final preparations for the workshop on her first day on the job and to Ms. Samantha Ryan for helping to transport workshop participants.

We are especially grateful to NOAA's International Registry of Coral Pathology and Dr. Shawn McLaughlin and Ms. Kathy Price for the many long hours they spent prior to the meeting preparing the histological slides and slide sets to allow individual and collective deliberations of representative coral lesions. Without these materials and this valuable resource (i.e., IRCP), this workshop just would not have happened.

We would like to express sincere appreciation to the Department of Pathology and Laboratory Medicine at the Medical University of South Carolina who hosted the workshop. The assistance and accommodations provided by the Department were incredible. In particular, we appreciate the time Dr. Debra Hazen-Martin spent helping logistically and in various other critical matters to the workshop. We also appreciate the expertise in human pathology and wisdom that Dr. Russell Harley brought to the discussions. We are most grateful to Mr. James Nicholson who truly went beyond the call of duty in helping us in almost every facet of the meeting from setting up a webpage with frequent updates prior to the meeting to lending his expertise in all of the technology involved in this conference. Mr. Nicholson made arrangements to have high quality microscopes, cameras and going the extra-mile in digitizing slides to allow us to have access to the most current technology available in histology – virtual slides –for our deliberations. He also challenged confocal microscopy with coral tissue – live and fixed! And added such special touches as a group photo and a DVD of the images obtained during the meeting for each participant to take home. It is unlikely we would have accomplished as much as we did without his expert assistance, patience and dedication. Jim, we thank you.

We would like to thank Dr. Robert Ogilvie, MUSC Department of Cell Biology and Anatomy, for introducing us to a new digital technology that is revolutionizing histology and histopathology in the medical field. His presentation and the use of the virtual microscope opened a lot of eyes during the meeting, revealing just how powerful and useful this tool can be to share knowledge among pathologists and a significant enhancement to coral histopathology and its communications globally.

We also thank Dr. Ogilvie and Aperio Technologies for bringing the ScanScope slide digitizer for demonstration at the workshop. Access to the Aperio System allowed us to exceed our expectations for the meeting.

Dr. Sylvia Galloway deserves special recognition for the role she has played in producing this report. Her role began by serving as recorder during the four days of deliberation, where she so aptly synthesized the discussions for each participant to review and then facilitated bringing them to consensus on each pathology opinion that is offered in this report. Sylvia didn't stop there, but has spearheaded the editing, layout and design of this publication.

We must acknowledge Dr. Thierry Work for his contributions to the workshop and the generation of this publication. Thierry constantly kept us focused on the need for this workshop to have a useful product. During the meeting his initiative, drive and just plain energy, got us over some humps and propelled us into having a draft report before everyone left the meeting and well on the way to a finalized product within three weeks. Thierry we are exceedingly grateful for your leadership in this endeavor.

We are especially grateful for the advice provided by four outside experts in anthozoan and coral anatomy and histology: Stephen Cairns, National Museum of Natural History, Smithsonian Institution; Daphne Fautin, University of Kansas; Walter Goldberg, Florida International University; and Jaroslaw Stolarski, Intytut Paleobiologii PAN. Their combined wisdom enabled us to provide strong definitions for several terms that were troubling to the workshop participants and thus will further good communication amongst coral biologists and histopathologists.

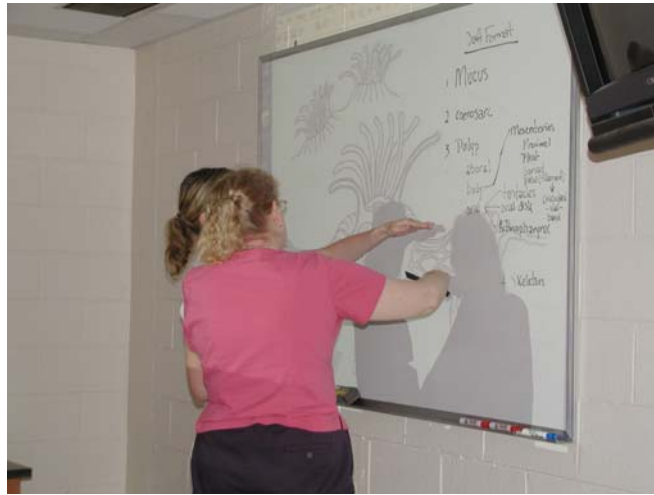
We are particularly indebted to Dr. Esther Peters, a pioneer in the field of coral histology and histopathology for freely giving of her time and expertise both during the workshop and afterwards. Her detailed review/editing of this report insured that it is of high quality. In particular, we appreciate the refinement of the glossary that she and Dr. Esti Winter worked on together calling upon the expertise within the coral community to provide the most authoritative definitions.

Financial support for this workshop was provided by NOAA through the Coral Reef Conservation Program. We also acknowledge the support of NOAA's National Ocean Service Center for Coastal Environmental Health and Biomolecular Research.

GLOSSARY of CORAL ANATOMY and HISTOPATHOLOGY TERMS

BACKGROUND

In the Introduction to the *Glossary of Biochemistry and Molecular Biology*, Glick (2006) states that “In the sciences, an essential aspect of recognizing, recalling and communicating something, be it a substance, relationship or method, is the naming of it. To create names for new concepts, methods or items, we invent new words, often using the roots of a Classical language (apoptosis, glycocalyx, isosbestic), and we recruit familiar words and invest them with new meanings (chaperone, kringle, library).” In either case, dictionaries and glossaries have become more



Esther Peters points out specialized anatomical structures to workshop participants.

important than ever in helping scientists understand what they are studying and to communicate new discoveries in rapidly evolving fields. Workshop participants realized early in the session that being able to communicate across coral biology, pathology, and histology might require reconsideration of pertinent terms and their definitions to make them applicable to coral histopathology and understandable to wider audiences.

The definitions for the terms in this glossary have been derived from diverse sources, which are cited below and in the references at the end of this section. During and following the workshop, participants discussed the utility of terms currently used to describe the microscopic anatomy and pathology as it pertains to hexacorals and octacorals (= corals) and suggested including a glossary in the report to assist in explaining the histopathological findings from the coral sections reviewed by the participants. Most of the anthozoan anatomical terms were developed from dissections and histological studies used to distinguish taxa. Polyp features have been largely based on studies of sea anemones and octacorals, and primarily skeletal features have been used to distinguish taxa among scleractinians. Histological examinations of corals have expanded to include the study of diseases only since the late 1970s. The participants agreed that most descriptors commonly used in the evaluation of vertebrate disease processes could be adapted to the study of coral diseases; however, some new terms might be needed to facilitate interpreting the histological observations being made of coral specimens and making morphological diagnoses.

Some terms were confusing to veterinary and comparative histopathologists and some anatomical terms did not appear to adequately distinguish regions that consist of similar cell types but have different functions and might show different reactions when diseased. For example, “column wall” fits the cylindrical body of an anemone polyp, but should this be used for the colonial polyps embedded in mesoglea or skeleton? Is there a term that could be used to specifically identify the location of lesions in the part of the polyp in contact only with the skeleton or only with the seawater? Are other modifiers needed with “epidermis” and “calicoblastic epidermis”? Participants debated using the term “integument” to identify the unit of the three layers of cells and mesoglea forming the polyp, with modifiers of “paralithic” or “paramaric” to mean “beside the stone (skeleton)” or “beside the sea.” The term “calicoblastic layer” has been used to mean the unit composed of calicoblastic epidermis-mesoglea-gastrodermis, but “layer” means only a single thickness of cells or of a homogeneous substance. Participants proposed writing a white paper to justify the rationale for an internationally recognized terminology for coral histopathology in consultation with experts in the scientific nomenclature of coral anatomy and histology.



Workshop participants discuss pros and cons of terminology; T. Work, C. Woodley, and L. Sileo.

During preparation of the workshop report, proposed and confusingly defined terms were presented to four outside experts in anthozoan and coral anatomy and histology: Stephen Cairns, National Museum of Natural History, Smithsonian Institution; Daphne Fautin, University of Kansas; Walter Goldberg, Florida International University; and Jaroslaw Stolarski, Intytut Paleobiologii PAN. The experts had diverse opinions as to the appropriateness and need for these terms, but all urged caution in developing new terms. Dr. Stolarski noted that separating

human bones into those that are completely inside the body and those that extrude as limbs might be “useful for casualty ward but awkward for perfectly homologous structures.”

But we are talking about the “casualty ward” for corals here and finding pathological changes in just the epidermis in contact with seawater rather than the epidermis that aids in skeletal deposition mean differences in organism function and prognosis for the animal, much as a broken ulna versus a broken pelvis do in humans. After more consideration, thought, and much research in publications, glossaries, and dictionaries, one new term is presented in this proposed glossary (“calicodermis,” marked with an “*” below). Other terms that have been in long use for anthozoans were found to be appropriate for the corals.

The terms that generated the most discussion were “ectoderm,” “endoderm,” “epidermis,” and “gastrodermis.” Workshop participants were familiar with the use of the first two terms in developmental biology to refer to the outer and inner layers of cells that form during development of an embryo from the blastula into the gastrula. The cnidarian literature presented references to “ectoderm” and “epidermis” as the outer layer of cells of a polyp and “endoderm” or “entoderm” and “gastrodermis” as the inner layer of cells of a polyp. Libbie Hyman assigned the term “epidermis” to the outer adult cnidarian epithelium and proposed the term “gastrodermis” for the inner adult cnidarian epithelium, noting that “ectoderm” and “endoderm” were embryological terms ((Hyman 1940), her first volume in *The Invertebrates* series). Fautin and Mariscal (1991) used “epidermis” and “gastrodermis” in their chapter on Anthozoa in Volume 2 of the *Microscopic Anatomy of Invertebrates* series. Because of this and usage of “epidermis” and “gastrodermis” in other recent anthozoan published works, including the *Illustrated Trilingual Glossary of Morphological and Anatomical Terms Applied to Octocorallia* (Bayer et al. 1983), the workshop participants included these four terms in the glossary, noting their application to the embryological or adult epithelial layers.

In her review of the draft glossary, Dr. Fautin stated that “ectoderm” and “endoderm” refer to the embryological development of the inner and outer layers of cells only in triploblastic animals. She noted that the editor of Volume 2, Jane Westfall, had insisted that Fautin and Mariscal use the terms “epidermis” and “gastrodermis” despite their protests that “ectoderm” and “endoderm” were originally assigned to identify the outer and inner epithelia of adult cnidarians and were later appropriated for embryonic cell layers in the context of ontogenetic recapitulation of the adult layers of Cnidaria. She further reported that Hyman, in her final volume VI (1967), wrote “In a project of such magnitude some errors of fact and judgment are inevitable. It was a mistake on my part to replace the terms ectoderm and entoderm on the grounds that they are embryological terms. They were in fact created by Allman for the two body layers of coelenterates [cnidarians]. I advise that gastrodermis be dropped and regret having introduced it.” In conclusion, she stated that Westfall now regrets having enforced its use (D. Fautin, pers. comm.).

The workshop participants discussed these arguments. Although some sources use “ectoderm” or “ectodermis” to refer to the outer cell layer and “endoderm” or “endodermis” to refer to the inner cell layer in adult Cnidaria, these epithelia change in composition and function as the animal grows. The simple endoderm and ectoderm established during gastrulation are not the same as fully differentiated adult tissues in any eumetazoan, whether it is diploblastic or triploblastic. In the Cnidaria, the cells within each layer differentiate first into ciliated supporting cells, and then other cell types differentiate (e.g., mucocytes or nematocytes) or other functions are expressed (e.g., cells of the outer polyp layer develop microvilli for nutrient uptake or secrete an organic matrix for calcification; stem cells form amoebocytes or germ cells as needed for defense or reproduction; cells lining the gastrovascular cavity develop the ability to maintain zooxanthellae without harming them). Thus, the adult epithelia are not the same as the layers in the gastrula.

After much debate among participants and reviewers, “epidermis” and “gastrodermis” were included in the glossary as the terms for the adult epithelia that are derived from the embryonic ectoderm and endoderm, respectively. “Calicodermis” is the ectoderm that assists in building the calcified exoskeleton of scleractinians after the planula settles on the substratum. This term was proposed to shorten the currently used “calicoblastic epidermis” and to correct the misunderstanding that cells here are “calicoblasts” because they do not secrete the crystals of aragonite. Instead, the organic matrix, secreted by these cells, aids in the deposition of the crystals within the space between the cells and the skeleton.

As noted by one of the participants, most terms and descriptors of microscopic anatomy and pathological processes in human and veterinary medicine have evolved over the past centuries through a process of proposal, use, modification, incorporation into the published literature, and general acceptance. The vocabulary and nomenclature for coral histopathology will evolve similarly in time.

The glossary below presents our best compilation of terms found in the literature to date. Sources of the definitions are cited; however, most definitions have been clarified to better explain their pertinence to usage in coral studies. Not all anthozoan anatomical terms are included here as we have focused on those terms that should be most commonly needed for light microscopic histopathological examinations of these organisms, not those that are additionally needed for taxonomic or ultrastructural descriptions. The literature cited should be consulted as needed for other coral anatomical terms, particularly for specific taxa, as well as for terms to describe pathological changes, as necessary. Note also that new discoveries in coral anatomy and histology probably remain, as recently found by Goldberg (2002a; 2002b) for *Mycetophyllia reesi*, and might lead to adoption of new terms in this field.

GLOSSARY

(Terms highlighted in blue are linked back to their definition in this glossary)

Aboral – region of [polyp](#) directly opposed to, away from, or remote from the mouth; the terms [Basal](#) or [Proximal](#) can also be used to describe this region. (Dorland 2006)

Acrosphere – globular tip of scleractinian [tentacle](#), containing numerous [nematocytes](#). (Fautin 2005)

Actinopharynx (preferred term; synonyms – stomodaeum, pharynx) – invagination of the [epidermis](#) to form a short muscular tubular passageway between the mouth and [gastric cavity](#) in a [polyp](#), mostly lined with [flagellated supporting cells](#). (Fautin 2005; Peters 2001)

Acute – exposure to a pathogen or a health effect that is brief, intense, short-term, or severe. The terms acute and subacute as they refer to pathology in coral are not currently precise enough to apply to cellular/microscopic changes and these terms as they are used

in the current document will refer only to colony-level (gross) observations. (Stedman 1995)

Amoebocyte – a cell possessing [pleomorphic](#) form and high elasticity, the principal cellular defense element of Cnidaria and typically found in the [mesoglea](#). Granular amoebocytes contain small, dense, acidophilic granules in the cytoplasm, may secrete collagen fibers or sclerites, phagocytize and digest particulate matter, or differentiate into other cell types. (Fautin and Mariscal 1991)

Amphophilic – having an affinity both for acid and basic dyes. (Pharma 2006)

Anthocodia (plural Anthocodiae) – the [distal](#) part of an octocorallian [polyp](#), bearing the mouth and tentacles. (Bayer et al. 1983)

Anthostele (= Calyx) – the rigid part of polyps seen in some species of octocorals, often stiffened by [sclerites](#), and into which the anthocodia may be withdrawn. (Bayer et al. 1983)

Antipathin – a material composed of proteins and chitin that forms the [axis](#) in an antipatharian (black coral). (Goldberg 1976)

Apical– opposite of [basal](#), situated near the apex or tip of a structure, as in the apical portion of a cell. (Stedman 1995)

Apoptosis (a form of programmed cell death) – a morphologic pattern of cell death formation of cytoplasmic blebs, and fragmentation of the cell into membrane-bound affecting single cells, marked by shrinkage of the cell, condensation of chromatin, apoptotic bodies that are phagocytosed by other cells. (Dorland 2006; Stedman 1995)

Aragonite – mineral variation of calcium carbonate (CaCO₃) with a crystal structure different from the other two forms of CaCO₃, vaterite and calcite. It is formed mainly by marine organisms (e.g., coral) that use it to make their shells and skeletons. (Coris 2006)

Atrophy – diminution of tissues, organs, or entire body, as from death and reabsorption of cells, diminished cellular proliferation, decreased cellular volume, malnutrition, or lessened function. (Stedman 1995)

Attenuated – thinned or weakened, cause unknown. (Stedman 1995)

Autolysis – [lysis](#), enzymatic digestion, of cells by the enzymes present within them. (Stedman 1995)

Axial Polyp – the longest polyp of a group of polyps, which produces secondary (daughter) polyps by lateral budding from its body wall. (Bayer et al. 1983)

Axial Sheath – that part of the colonial [coenenchyme](#) immediately surrounding the axis in the octocoral taxa Gorgonacea and Pennatulacea, containing the longitudinal canals and characterized by [sclerites](#) commonly different in form from those of the overlying coenenchyme. (Bayer et al. 1983)

Axis – inner supporting structure of Gorgonacea and Pennatulacea. It is usually composed of collagen (see [Gorgonin](#)); however, the antipatharian (black coral) axis consists of different proteins and chitin (see [Antipathin](#)). The axis can be mineralized in some groups, usually by magnesium calcite (as in [sclerites](#)), but in some, the mineral in the axis is [aragonite](#) and amorphous hydroxyapatite also occurs in some axial skeletons. (Bayer et al. 1983; Bayer and Macintyre 2001; Goldberg 1976; Holl et al. 1992)

Axis Cortex – layer around the [central chord or core](#) of the axis, deposited by an axis epithelium. (Bayer et al. 1983)

Axis Epithelium – layer of cells derived from [ectoderm](#) consisting of two types of cells: [corticoocytes](#) (cells that produce the axis) and [desmocytes](#) (cells that attach the octocoral tissues to the axis). (Bayer et al. 1983)

Basal - situated near the base of a structure in relation to a specific reference point, opposite of [apical](#). (Stedman 1995)

Basal Plate – [aragonite](#) structure built by the [polyp](#) at the bottom or base of the skeletal cup ([corallite](#)) enclosing a scleractinian polyp. (Stachowitsch 1992)

Basophilic – denoting components of cells having an affinity for basic dyes under specific pH conditions. Basophilic compounds (e.g., nucleic acids) stain blue with hematoxylin in the ‘hematoxylin and eosin’ (H&E) staining procedure. (Pharma 2006)

Body Wall – the three layers of tissues ([epidermis](#), [mesoglea](#), [gastrodermis](#)) that form the surfaces of the [polyp](#), enclosing the [gastrovascular cavity](#) and, in colonial corals, the [gastrovascular canals](#). (Bayer et al. 1983; Goldberg 2002b)

Surface Body Wall – in contact with seawater, covering the [coenenchyme](#), [tentacles](#), [oral disk](#), [peristome](#), and polyp neck zone and [anthostele](#) (octocoral) or [column](#) (hexacoral).

Basal Body Wall – the [calicodermis*](#), mesoglea, and gastrodermis that covers the exoskeleton of the scleractinian coral, surrounding the gastrovascular cavity and canals.

Actinopharynx Body Wall – the specialized (heavily [ciliated](#) or [flagellated](#)) epidermis, mesoglea, and gastrodermis that forms the [actinopharynx](#).

Calice – the upper open or [oral](#) surface of the [corallite](#). (Peters 1984)

Calicoblast – primary cell type of the calicodermis* that secretes the organic matrix involved in calcification and formation of the skeleton in the scleractinians. (Puverel et al. 2005)

Calicodermis* (= **Calicoblastic Epithelium**) – the thin but complex layer of ectodermally derived cells around a scleractinian [polyp](#) whose primary function is building the exoskeleton. In a colonial coral, as new polyps are formed, the calicodermis continues as the cell layer immediately adjacent to the skeleton of the interconnecting [gastrovascular canals](#) in imperforate corals and completely surrounds the gastrovascular canals embedded in the exoskeleton in perforate corals. Most of the cells are modified to secrete an organic matrix that may have a crucial role in the formation of [aragonite](#) crystals to form the exoskeleton. These cells, currently referred to as calicoblasts, do not form aragonite intracellularly. Other cells in the calicodermis are modified to attach the tissue to the exoskeleton (see [Desmocyte](#)). This [epithelium](#) can also contain [mucocytes](#), [pigment cells](#), or [amoebocytes](#), but usually lacks [cnidocytes](#). (Goldberg 2002b; Goldberg 2001a; Peters 1984, Coral Histopathology Workshop 2005)

Calyx (plural Calyces) – see [Anthostele](#)

Central Chord or Core – the central part of the [axis](#), made of [gorgonin](#) alone, or gorgonin permeated with calcareous matter, sometimes hollow and cross-chambered, not always present. (Bayer et al. 1983)

Chromophore Cell – [amoeboid cell](#) containing cytoplasmic pigment granules in the scleractinian genus *Porites*. The granules appear yellow to tan when stained with hematoxylin and eosin using incandescent light microscopy and are bright green in unstained polyp [sections](#) when using a filter for green fluorescent protein with epifluorescence microscopy. (Duerden 1902; Smith 2004)

Chronic – long-term exposure to a [pathogen](#) or a prolonged health effect. The term chronic as it refers to pathology in coral is not currently precise enough to apply to cellular/microscopic changes and this term as used in the current document will refer only to colony-level (gross) observations. (Stedman 1995, Coral Histopathology Workshop 2005)

Cilium (plural Cilia) – one of the motile extensions of the surface of an epithelial cell containing nine longitudinal double microtubules made of structural proteins arranged in a ring around a central pair. (Stedman 1995)

Cinclide – small opening or “soft spot” in the body wall through which [mesenterial filaments](#) can be extruded. (Fautin and Mariscal 1991)

Cnida (plural Cnidae) – a collagenous capsule that develops in a cnidocyte and contains a tubule or thread that everts when triggered. There are three types of cnidae: [nematocysts](#), [spirocysts](#), or [ptychocysts](#). Cnidae are non-self-replicating organelles

secreted by the Golgi apparatus, and are the most complex secretory products in the animal kingdom. (Hessinger and Lenhoff 1989; Mariscal 1984)

Cnidocyst – [cnida](#). (Mariscal 1984)

Cnidocyte – epithelial cell that can produce a cnida in the Cnidarians, see also [Nematocyst](#) and [Spirocyst](#). (Mariscal 1984)

Cnidoglandular Band (or Lobe) – the [distal](#) thickened rim or free [margin](#) along a [mesentery](#). It consists of the median band or tract of a [mesenterial filament](#) containing [nematocytes](#), ciliated columnar or [collar cells](#), [mucocytes](#), and [granular gland \(zymogen\) cells](#), may have two lateral lobes distal to the median lobe, consisting mainly of nutritive/absorptive cells. (Fautin and Mariscal 1991; Goldberg 2002b; Hyman 1940)

Coccidian – a single-celled organism belonging to the protistan Phylum Apicomplexa, characterized by merogony and a life cycle comprising both sexual and asexual stages, parasitic in epithelial cells of invertebrates and vertebrates. (Upton and Peters 1986)

Coenenchyme – the tissues between and continuous with the [polyps](#) in a colonial anthozoan, consisting of the [surface body wall](#) and [gastrovascular canals](#) found either on the surface of or penetrating the skeleton (in hexacorals) or consisting of the surface body wall, gastrovascular canals, and [solenia](#) penetrating through the thick [mesoglea](#) stiffened with [sclerites](#) (in octacorals). The edge zone of the coenenchyme is that portion extending outside the peripheral polyps at the edge of a colony or outside the [theca](#) in a solitary coral. (Bayer et al. 1983; Stachowitsch 1992)

Coenosteum – skeleton deposited outside and between the [corallite](#) walls of the [polyps](#) of a colonial scleractinian. (Peters 1984; Stachowitsch 1992)

Collar Cell – specialized cell found in the epithelia of the [mesenterial filament](#) and [actinopharynx](#). Requires transmission electron microscopy to distinguish its characteristic feature, a cilium with shallow rootlet surrounded by fibril-linked microvilli, with small fibrous or [lysosome](#)-like [apical](#) inclusions. (Goldberg 2002b)

Column – the body wall of an anemone, the cylindrical surface of a [polyp](#). In a scleractinian, that portion of the polyp that can extend outside the [calice](#). (Fautin 2005; Peters 1984)

Columella – column-shaped skeletal projection of the central [basal](#) plate or modified inner [septal](#) edges, may be solid or not. (Peters 1984; Stachowitsch 1992)

Corallite – the skeleton deposited by an individual [polyp](#) within a colony. (Peters 1984, Acropora Biological Review Team)

Corallum – the entire skeletal structure formed by either a solitary (single [corallite](#)) or colonial (group of corallites) coral. (Peters 1984)

Corticocyte – cell that produces [gorgonin](#) and forms the [axis](#) in a gorgonian. (Tidball 1982)

Costa – the extension of the septa outside the calice onto the coenosteum. (Peters 1984)

Degeneration – a nonspecific term applied to retrogressive but sometimes reversible pathological change in cells or tissues, resulting in impairment or destruction of functions; deterioration; preferably the specific changes observed should be fully described. (Dorland 2006; Stedman 1995)

Desmocyte – anchoring cell of the [calicodermis](#)* (scleractinian) or [axis epithelium](#) (gorgonian), characterized by unique [apical](#) and [basal](#) modifications for attachment to skeletal surfaces and [mesoglea](#) respectively. (Chapman 1974; Goldberg 2001b; Muscatine et al. 1997)

Diagnosis – the determination of the nature of a disease. (Stedman 1995)

Field Diagnosis – made from the study of the macroscopic changes of a coral disease observed in the field.

Laboratory Diagnosis – made by a chemical, virological, parasitological, microbiological, or immunological study of secretions, discharges, or tissues.

Morphologic Diagnosis – made from an anatomical or histological study of the lesions present.

Etiologic Diagnosis – the determination of the cause of the disease.

Differential Diagnosis – a systematic comparison and contrasting of similar disease signs and findings to determine which of two or more diseases is considered to be most likely present in the organism, although one or more other diseases are considered less likely to be present but possible. (See also [Pathognomonic](#)) A differential diagnosis is also made to distinguish between closely related species in taxonomy.

Disassociation (or Dissociation) – a separation of relationships, as in the separation of epithelial cells because of damage to the intercellular junctions. (Stedman 1995)

Disease – any deviation from, or interruption of, the normal structure or function of any body part, organ, or system that is manifested by a characteristic set of signs and whose etiology, pathology, and prognosis may be known or unknown (Dorland 2006); any impairment that interferes with or modifies the performance of normal function, including responses to environmental factors such as nutrition, toxicants, and climate; infectious agents; inherent or congenital defects, or combinations of these factors. (Wobeser 1981)

Distal – that part of a structure situated away from the center of or point of origin, the extremity or distant part of a limb or organ, e.g., distal tentacle. For a polyp, the distal part is the oral end of the entire polyp. (Fautin 2005; Stedman 1995)

Ectoderm – the outer layer of pluripotential cells in the embryo, after establishment of the primary germ layers during the gastrula stage of development. (Hyman 1940; Martindale et al. 2004; Stedman 1995 discussed the diploblastic versus triploblastic nature of cnidarians)

Endocoel – the region of the [gastrovascular cavity](#) between two [mesenteries](#) belonging to the same pair; in the endocoel of [nondirective mesenteries](#), the longitudinal retractor muscles on the [mesogleal pleats](#) of the two mesenteries protrude into the cavity; in the endocoel of [directive mesenteries](#), the longitudinal retractor muscles on the mesogleal pleats are on the side of the mesenteries so they do not protrude into the cavity. (Fautin 2005)

Endoderm (or Entoderm) – the inner layer of pluripotent cells in the embryo, after establishment of the primary germ layers during the gastrula stage of development. (Hyman 1940; Martindale et al. 2004; Stedman 1995 discussed the diploblastic versus triploblastic nature of cnidarians)

Endolithic – growing within a rock or any other hard inorganic substratum, e.g., coral skeleton. (Coris 2006)

Eosinophilic – cell or tissue elements staining readily with eosin dyes, appear pink to red when using a hematoxylin and eosin staining procedure; sometimes referred to as “acidophilic.” (Pharma 2006)

Epidermis – external epithelium of coral [polyps](#) and [coenenchyme](#) derived from the [ectoderm](#), may be composed of columnar [supporting cells](#) (with [apical](#) specializations such as microvilli, cilia, or flagella), ciliated sensory cells, [mucocytes](#), [epitheliomuscular cells](#), [cnidocytes](#), [pigment cells](#), [neurons](#), [amoebocytes](#). The epidermis can be reduced in octocorals (supporting cells, sensory cells, cnidocytes, [scleroblasts](#), mucocytes, amoebocytes) and may secrete a covering on [basal](#) parts of octocoral colonies. (Fautin and Mariscal 1991; Hyman 1940)

Epitheliomuscular Cell – cnidarian cell in which the cell body is columnar and the nucleus is situated in the [basal](#) portion of the cell. It is joined to other epithelial cells in the [epidermis](#) or [gastrodermis](#) and has elongated basal cytoplasmic extensions containing actin and myosin filaments, known as muscle fibrils or [myonemes](#). The extensions are perpendicular to the cell body and attach to the surface of the [mesoglea](#), facilitating polyp movement and contraction. The [apical](#) surface of the cell may have a [flagellum](#). (Fautin and Mariscal 1991)

Epithelium – layer of cells covering both [ectodermally](#) and [endodermally](#) derived tissues of the polyp body and canals, bound together by various junctions and cementing substances to provide strength and mediate the exchange of metabolic and messenger molecules, and bound to and supported by basement membrane or basal lamina. (Dorland 2006; Stedman 1995)

Euchromatic (= Orthochromatic) – denoting any tissue or cell that stains the color of the dye used, i.e., the same color as the dye solution with which it is stained. (Pharma 2006)

Exocoel – the region of the [gastrovascular cavity](#) between two [mesenteries](#) belonging to different pairs. Except for the exocoels flanking the [directive mesenteries](#), retractor muscles do not protrude into an exocoel. (Fautin 2005)

Filament – see [Mesenterial Filament](#)

Flagellum (plural **Flagella**) – single, elongate motile structure consisting of nine pairs of microtubules around two single central proteinaceous microtubules extending from the apical surface of an epithelial cell or tail of spermatozoan. (Stedman 1995)

Full Thickness (= Transmural) – a lesion, wound, or process that involves all layers of a tissue: [epidermis](#) or [calicodermis](#)*, [mesoglea](#), and [gastrodermis](#). (Coral Histopathology Workshop 2005)

Fusiform – spindle-shaped, tapering at both ends, as in a fusiform cell. (Stedman 1995)

Gastric Cavity – see [Gastrovascular Cavity](#)

Gastrodermal Canal – see [Gastrovascular Canal](#)

Gastrodermis – the inner epithelium of a coral polyp derived from the embryonic [endoderm](#), lining the [gastrovascular cavity](#) and polyp-connecting canals. Some cells in this epithelium are [phagocytic](#) to digest food particles, absorb nutrients, and release waste products; [zooxanthellae](#) often reside within membrane-bound [vacuoles](#) in these cells. The gastrodermis may also contain ciliated or [flagellated supporting cells](#), [cnidocytes](#), [amoebocytes](#), sensory cells, [mucocytes](#), and [pigment cells](#). (Fautin and Mariscal 1991; Goldberg 2002a; Hyman 1940; Peters 1984)

Gastrovascular Canal – a system of tubes lined with [gastrodermis](#) that connect the [gastrovascular cavities](#) of colonial coral polyps. The canals extend along the surface of the [coenosteum](#) in all colonial scleractinians; in some species additional canals extend from the gastrovascular cavities to penetrate through the coenosteum between polyps, forming a porous or perforated skeleton. In the octocorals, the gastrovascular canals are embedded in the [mesoglea](#) and connect to thinner canals called [solenia](#). (Bayer et al. 1983; Peters 1984)

Gastrovascular Cavity – the interior space of a coral polyp, also referred to as the coelenteron in anthozoans, the saclike cavity within a polyp connected to the mouth by the actinopharynx. (Bayer et al. 1983; Fautin and Mariscal 1991)

Germ Cell – oocyte or spermatocyte; cell originating in the [gastrodermis](#) of a [mesentery](#) that migrates into the [mesoglea](#) and develops into either an oocyte or spermatocyte. (Fautin and Mariscal 1991)

Giemsa – a stain that contains both basic and acidic dyes and will therefore differentiate acidic and basic granules in [granulocytes](#). It is also often used to stain tissue [sections](#) suspected to contain protozoan parasites. (Pharma 2006)

GMS – Grocott-Gomori's Methenamine Silver Stain, a modification of Gomori's methenamine-silver staining procedure for fungi in which [sections](#) are pretreated with chromic acid before addition of the methenamine-silver solution and then counterstained with light green to demonstrate black-brown fungi against a pale green background. (Pharma 2006; Stedman 1995)

Gonad – gametogenic region of a mesentery in a polyp. (Fautin and Mariscal 1991)

Gorgonin – a fibrous, collagenous protein that provides skeletal support for sea fans and other members of the octocoral order Gorgonacea. (Coris 2006; Hyman 1940)

Granular Gland Cell (= [Zymogen Cell](#)) – secretory epithelial cell containing acidophilic granules (e.g., [lysosomes](#)) that are released into the [gastrovascular cavity](#) for extracellular digestion of prey. (Fautin and Mariscal 1991; Hyman 1940)

Holdfast – the portion of an octocoral colony attaching it to or in the substrate. (Bayer et al. 1983)

Hyalin – a translucent, homogenous, structureless, eosinophilic, albuminoid substance occurring in tissue [degeneration](#). (Pharma 2006; Stedman 1995)

Hyalination – process of deposition of a cellular amorphous homogeneous substance which stains bright red with hematoxylin and eosin. (Stedman 1995)

Hyaline – having the properties of hyalin. (Stedman 1995)

Hydropic – excess of water or watery fluid. (Stedman 1995)

Hyperplasia – an increase in the number of normal cells in normal arrangement in a tissue or organ, increasing its size. (Dorland 2006; Stedman 1995)

Hyphae – the fine, branching tubes which make up the body (or mycelium) of a multicellular fungus. (Pharma 2006)

Imperforate coral – corals which have solid skeletons with no connections between the polyps. (Coris 2006)

Infection – invasion and multiplication of parasitic organisms within the body. (Stedman 1995)

Inflammation – a fundamental pathological process aimed at destroying, diluting, and walling off the injurious agent. The process generally consists of a dynamic complex of cytological and chemical reactions that occur in affected tissues in response to an injury or abnormal stimulation caused by a physical, chemical, or biologic agent, including the local reactions and resulting morphologic changes, the destruction or removal of injurious material, and the responses that lead to repair or healing. (Dorland 2006; Sparks 1985; Stedman 1995)

Karyolysis – swelling of the nucleus of a cell and gradual loss of its chromatin, indicated by paling of the basophilic reaction in hematoxylin and eosin staining. (Dorland 2006; Stedman 1995)

Karyorrhexis – rupture of the nucleus of a cell and the chromatin disintegrates into small pieces, which are extruded from the cell. (Dorland 2006)

Lesion – a wound or injury, or any pathologic change in the tissues. (Stedman 1995)

Lesion Distribution – distinguished on the basis of number of that particular type of lesion (focal: single, localized area; multifocal: relating to, arising from, or occurring in more than one place; diffuse: spread about, not restricted; systemic: spread throughout the entire organism).

Lesion Severity – semiquantitative, subjective ranking of the degree of damage or extent of pathological change seen in tissues or an organism (ranging from minimal: smallest amount or lowest limit; mild; moderate; marked; to severe: intensely or extremely bad, very poor condition, or greatest in degree or extent).

Loculus (plural **Loculi**) – calcified area or fiber-filled space within an [axis](#) (the axial skeleton of a gorgonian) or a space within the [gastrovascular cavity](#) between [septa](#) (interseptal loculus). (Bayer et al. 1983; Fautin 2005)

Lysis – dissolution or destruction of cells or structures. Lyse means to break up, disintegrate, or to effect lysis. (Stedman 1995)

Lysosome – a cytoplasmic membrane-bound vesicle containing a variety of glycoprotein hydrolytic enzymes (lysozymes) active at an acid pH, for digesting exogenous material such as bacteria or worn-out organelles of the cell. (Stedman 1995)

Margin – a boundary, edge, or border, as of a surface or structure. In anthozoans, also where the polyp column meets the [oral disk](#). (Fautin 2005; Stedman 1995)

Melanin – high molecular weight polymer of indole quinone produced by animals, this pigment can be black, brown, yellow, red, or violet. It is produced by gorgonian cells ([corticocytes](#)) to encapsulate infectious agents. (Petes et al. 2003; Pharma 2006)

Melanized – characterized by deposition of melanin. (Stedman 1995)

Mesenterial Filament – a convoluted, elongated or ribbonlike extension of the free inner edge of the mesentery, composed of cells which aid in capture and digestion of food. These filaments, which appear as white loops with translucent mesentery, may also help to protect the coral from substrate competitors and invaders by protrusion through the mouth or through temporary openings in the tissue. The free edge is the [cnidoglandular band](#), which may or may not be flanked by lateral ciliated tracts or lobes depending on the species and location along the edge. In octocorals, the filaments of the two mesenteries opposite the [siphonoglyph](#) are very long and heavily [flagellated](#), whereas the remaining six are shorter and glandular. (Bayer et al. 1983; Goldberg 2002b; Peters 1984)

Digestive Filament – specialized ciliated, thin, grossly translucent, unequally bilobed, stalk-like contractile structure with spatulate distal end found in the scleractinian coral *Mycetophyllia reesi*. One lobe contains [cnidae](#), [mucocytes](#), [collar cells](#), and [granular cells](#) and it protrudes through the polyp mouth during feeding (this species lacks tentacles). It is histologically distinct from [mesenterial filaments](#) and is housed in mesenterial ducts, radially arranged specially modified tubular mesenteries connecting to the [actinopharynx](#). (Goldberg 2002b)

Mesentery – internal longitudinal partition of tissue providing structural support and increasing surface area, which is important in nutrition and fertility of anthozoans. A mesentery develops by infolding of the mesoglea and its lining gastrodermis from the body wall of the polyp. Multiple mesenteries are arranged radially within the gastrovascular cavity of the polyp (between the septa in scleractinian corals) and are attached to the oral disk. (Fautin 2005)

Directive Mesentery – one of a pair of mesenteries attached to the [actinopharynx](#) in which the [mesogleal pleats](#) of the longitudinal retractor muscles face away from each other, toward the [exocoel](#).

Nondirective Mesentery – one of a pair of mesenteries attached to the actinopharynx in which the mesogleal pleats of the longitudinal retractor muscles face each other, toward the endocoel.

Complete Mesentery – extends from the body wall to attach to the actinopharynx.

Incomplete Mesentery – the free inner edge does not reach the actinopharynx.

Mesoglea – the connective tissue of coral and all cnidarians consisting of collagenous fibers embedded in a gelatinous material or ground substance of highly hydrated protein and neutral polysaccharide polymers and containing [amoebocytes](#) and other cells. The proportion of matrix to fiber and cells in this layer varies with the species and its condition. (Fautin and Mariscal 1991; Peters 1984)

Mesogleal pleat – sheets of [myonemes](#) known as longitudinal retractor muscles are anchored into mesoglea and pleated accordion-fashion so that the mesoglea is sandwiched between two monolayers of epithelia within the middle portion of a [mesentery](#). (Fautin and Mariscal 1991; Peters 1984)

Mucocyte – modified columnar epithelial cell with basal nucleus containing basophilic granules or spumous inclusions, also referred to as a mucous secretory cell or [mucosecretory cell](#). The cell synthesizes and secretes mucus through an [apical](#) pore to aid in feeding, protection, and sediment removal. (Peters 1984)

Mucus – protective secretion of [mucocytes](#) consisting of a polysaccharide-protein-lipid complex; it traps particles non-selectively, removes sediment, lubricates the passage of food within the [actinopharynx](#) (ciliary-mucus feeding) and helps digest it, provides protection against desiccation, and presents a barrier against environmental stresses, including salinity and temperature changes and exposure to UV radiation. Mucus may also be involved in self-recognition and the immune response of cnidarians. Some of the properties of mucus can be distinguished in histology by using a staining procedure involving alcian blue, periodic acid, and Schiff's reagent (AB/PAS). (Brown and Bythell 2005; Carson 1997; Fautin and Mariscal 1991; Goldberg 2002a)

Mycosis – any disease caused by a fungus. (Pharma 2006)

Myoneme – contractile portion of [epitheliomuscular cell](#) or muscle fibril (myofibril) contained within the plasma membrane that anchors it to the [mesoglea](#). It is attached by a long peduncle or process to the nuclear-containing portion of the cell. Myonemes may be diffuse or clustered into longitudinal and circular contracting sheets of muscle. (Fautin and Mariscal 1991)

Necrosis – cell death characterized by irreversible damage, the earliest of which is mitochondrial. Changes visible with light microscopy are nuclear ([pyknosis](#), [karyolysis](#), or [karyorrhexis](#)) and generally accompanied by cytoplasmic hyper-eosinophilia, shrinkage, or fragmentation. After such changes, the outlines of individual cells are indistinct and affected cells may become merged, sometimes forming a focus of coarsely granular, amorphous, or [hyaline](#) material. (Stedman 1995)

Necrotic – pertaining to or affected by necrosis. (Stedman 1995)

Nematocyst – a type of [cnida](#), secreted by the Golgi apparatus, produced exclusively by a [cnidocyte](#) or [nematocyte](#) of the Cnidaria. It consists of a double-walled capsule and an elongated hollow, sometimes externally spiny tubule that evaginates on mechanical or

chemical stimulation to entangle or deliver toxin to prey or repel attackers. About 30 types of nematocysts have been defined, based on morphology of the capsule and tubule. (Fautin and Mariscal 1991; Goldberg 2002b; Hessinger and Lenhoff 1989; Peters 1984)

Nematocyte – cell that produces a nematocyst. (Mariscal 1984)

Nematode – member of the Nematoda, a class of unsegmented helminthes with fundamental bilateral symmetry and secondary triradial symmetry of the oral and esophageal structures. Many species are parasites. (Pharma 2006)

Neoplasia – the pathological process that results in the formation and growth of a neoplasm. (Stedman 1995)

Neoplasm – an abnormal tissue that grows by cellular proliferation more rapidly than normal and continues to grow after the stimuli that initiated the new growth cease. A neoplasm is often characterized by partial or complete lack of structural organization and functional coordination with the normal tissue, usually forming a distinct mass. (Stedman 1995)

Neuron – multifunctional (combined characteristics of sensory, motor, inter- and neurosecretory neurons), morphological and functional unit of the nerve net consisting of the nerve cell body and processes, axon and dendrite(s) (sometimes these processes are referred to as neurites), communicating through electrical conduction or secretion of neuropeptides. (Fautin and Mariscal 1991; Grimmelikhuijzen and Westfall 1995)

Nodule – a small node, a circumscribed mass of tissue, or knob-like or knotty swelling of tissue. (Stedman 1995)

Nonseptate – not divided internally by partitions. (Stedman 1995)

Oocyte – female sex cell or gamete, immature ovum. (Stedman 1995)

Oral – describing the region of a coral polyp near or toward the mouth; the terms [Apical](#) and [Distal](#) can also be used to describe this region. (Fautin 2005)

Oral Disk – the part of the polyp through the center of which the mouth opens, including [peristomal](#) tissue and tentacles. (Peters 1984)

Ovum – the mature female germ cell (egg; female gamete). (Coris 2006)

Parasite – an organism that lives on (ectoparasite) or in (endoparasite) another organism and derives its nourishment from that host organism. (Stedman 1995)

Pathogen – any virus, microorganism, or other substance causing disease. (Stedman 1995)

Pathognomonic – typical characteristic signs, findings, or pattern of abnormalities specific for a given disease and not found in any other condition. Few disease signs and findings are characteristic for a single disease (see also [Differential Diagnosis](#)). (Stedman 1995)

Perforate coral – coral that has a porous skeleton with gastrovascular canals that connect the gastrovascular cavities of the polyps along the surface and through the skeleton. (Coris 2006)

Peristome – the portion of the [oral disk](#) surrounding the mouth and inside the ring of tentacles; may be elevated. (Peters 1984)

Pigment cell – basally located epithelial cell that produces pigmented granules (e.g., green fluorescent protein-like pigments, animal coloration pigment). The genus *Porites* contains specialized pigment granule-producing [amoeboid](#) cells called [chromophore cells](#). Note that [phagocytes](#) can contain lipofuscin pigment granules obtained from necrotic cells. (Duerden 1902; Peters 1984)

Phagocyte – a cell capable of ingesting bacteria, foreign particles, and other cells, present on the [lobes of the mesenterial filaments](#) and elsewhere in corals. (Hyman 1940; Peters 1984; Stedman 1995)

Pharynx – see [Actinopharynx](#)

Pinnule – one of the lateral processes along the [tentacle](#) of an octocoral. (Bayer et al. 1983)

Planula (plural Planulae) – the ciliated planktonic larval stage of the coral, developing from the zygote, occasionally noted in histological sections. The planula undergoes metamorphosis upon settlement on a suitable substrate. Some species of corals produce free-swimming planulae and other species brood planulae within the gastric cavity for variable periods of time. (Peters 1984)

Pleomorphic – polymorphic, occurring in more than one morphologic form. (Stedman 1995)

Polyp – the basic structural unit of an anthozoan, consisting of a sac-like cylindrical body, a basal (aboral) disk that may be modified to produce a calcium carbonate or gorgonin exoskeleton or attach the polyp to the substrate, and an oral disk bearing mouth and tentacles. (Peters 1984)

Proximal – that part of a structure nearest to the point of origin on an organism, as in a part of a limb or organ, e.g., proximal portion of tentacle. For a polyp the proximal part is its base that is attached to a surface or in mesoglea or skeleton. (Fautin 2005; Stedman 1995)

Ptychocyst – a type of [cnida](#) used in tube construction by burying anemones (Ceriantharia). These anemones build a tube into which they can contract for protection almost entirely from the everted flattened, sticky tubules of the ptychocysts that trap sand grains to form the tube. (Hyman 1940)

Pyknosis – a condensation or reduction in size of the cell or its nucleus. Nuclear pyknosis is contraction of the nucleus to a deep staining irregular or round mass, a stage of [necrosis](#) or sign of cell death. (Pharma 2006; Stedman 1995)

Pyknotic – characterized by pyknosis. (Stedman 1995)

Pyrenoid – a small proteinaceous body found within the cytoplasm of [zooxanthellae](#) (and other phytoflagellates) and closely associated with the chloroplasts. It contains the enzyme ribulose-1,5-bisphosphate carboxylase/oxygenase (RubisCO), which adds carbon dioxide to the sugar ribulose-1,5-bisphosphate as it synthesizes and deposits polysaccharides. The pyrenoid is visible in fixed, stained sections of zooxanthellae as a small round refringent body surrounded by a pale staining starch sheath. (Dorland 2006; Leggat et al. 1999)

Pyriform – pear-shaped. (Pharma 2006)

Regeneration – reproduction or reconstitution of a lost or injured part or an entire organism. (Stedman 1995)

Sclerite – minute magnesium-calcite element in octocoral mesoglea or axis. (Bayer et al. 1983; Goldberg 1976)

Scleroblast – cell within the [mesoglea](#) of octocorals that produces a sclerite. The sclerite may be formed intracellularly in some octocorals or by a combination of intra- and extracellular calcification. (Bayer et al. 1983)

Section – a thin slice of tissue, cells, macroorganisms, or any material for examination under the microscope. (Stedman 1995)

Cross – sliced at right angles (or transverse) to the longitudinal axis of the organism. A cross-section of a polyp is one sliced at right angles to the longitudinal axis running in the oral to aboral direction. A cross-section of a coral colony branch is one sliced at right angles to the longitudinal axis extending from the axial polyp to the base of the branch.

Sagittal – sliced along or parallel to the longitudinal axis of the polyp or branch (see Cross for explanation of axes).

Oblique – a diagonal cross section that is neither parallel to the longitudinal axis nor at right angles to this axis (see Cross for explanation of axes).

Septum (plural Septa) – one of the vertical calcareous plates or partitions radiating from the [corallite](#) wall toward the central axis within the [calice](#) that provide support to the [mesenteries](#). (Peters 1984)

Primary – full plates/partitions that separate two sets of mesenterial pairs.

Secondary – partial plates/partitions that separate mesenteries within a mesenterial pair.

Signalment – identification of the organism whose health is being examined, by describing distinguishing peculiar, appropriate, or characteristic physical marks or signs (e.g., species name, age or stage in development, size, coloration, gross lesions) and collection site and date collected. The basic signalment is aided by including collection site information, the specific samples collected from the specimen for investigation, and other observations on the history of the specimen's condition, to the extent known. (CDHC Workshop: Coral Histopathology II, this document page 20)

Siphonoglyph – the strongly ciliated groove extending down the side of the [actinopharynx](#) to direct water into the [gastrovascular cavity](#). Scleractinian polyps lack siphonoglyphs; a polyp of an octocoral, cerianthid, and zoanthid has one siphonoglyph; an antipatharian polyp has two siphonoglyphs; although an actinarian and corallimorpharian polyp usually has two siphonoglyphs, it may have none, one, three, or more of them. (Bayer et al. 1983; Fautin 2005; Hyman 1940)

Skeleton – the structurally supporting matrix of [aragonite](#) crystals formed by a scleractinian on the outside of the polyp, technically an exoskeleton, or the structural support for an octocoral. (Bayer et al. 1983; Stachowitsch 1992)

Solenium (plural Solenia) – in octocorals, a small canal lined with [gastrodermis](#), penetrating the [coenenchyme](#), forming a network, and fusing with the larger [gastrovascular canals](#) to interconnect the [gastrovascular cavities](#) of the polyps. (Bayer et al. 1983)

Spermary – gonad producing male gametes within the [mesoglea](#) of a [mesentery](#). It may appear as an unattached cyst-like structure within the [gastrovascular cavity](#) of a sectioned octocoral polyp, but the mesentery producing it is attached to the underside of the [oral disk](#). (Bayer et al. 1983; Fautin and Mariscal 1991)

Spermatocyte, Spermatozoan – male gamete or sex cell that contains the genetic information to be transmitted by the male. (Stedman 1995)

Spirocyst – single-walled capsule which contains a tightly coiled tubule bearing microtubules that form a web of fine, adhesive microfibrillae when discharged for prey capture or attachment, produced by a spirocyte. (Goldberg and Taylor 1996; Mariscal 1984; Peters 1984)

Spirocyte – a cell lacking a sensory cilium that produces the spirocyst and occurs only in anthozoans. (Fautin and Mariscal 1991)

Stem Cell – any precursor cell, a cell whose daughter cells may differentiate into other cell types. The term “interstitial cell” or “I-cell” has been used in the literature to refer to undifferentiated cnidarian (particularly Hydrozoa) cells lying between epithelial cells or migrating through the mesoglea that differentiate into the germ cells, nematocytes, and other cell types as needed. The term is rarely used in discussions of Anthozoa. More recent resources did not include this term, and “interstitial cell” has other specific meanings in vertebrate histology. “Stem cell” has universal meaning in all organisms. (Fautin and Mariscal 1991; Hyman 1940; Stedman 1995; Thomas and Edwards 1991)

Stomodeum – mouth and [actinopharynx](#) as it begins developing in the coral embryo and [planula](#), is also often applied to the actinopharynx of the adult. (Hyman 1940; Stedman 1995)

Supporting cell – columnar cell of the epidermis or gastrodermis with central nucleus, may have apical specializations of microvilli, cilia, or flagella. (Goldberg 2002a)

Tentacle – hollow, contractile extension of the polyp’s [oral disk](#) distal to the [mesenteries](#), typically cylindrical, commonly tapering to a point but in some species terminating in a spherical [acrosphere](#), and rarely branched. In octocorals, each tentacle has two diametrically arrayed rows of short [pinnules](#). The tentacle’s internal cavity is continuous with the [gastrovascular space](#), continuous with that of the main body. In most species, it is studded with [nematocysts](#) and/or [spirocysts](#), either scattered or arrayed in batteries. Tentacles are typically used in food capture, defense, and sediment removal; in some species, some tentacles are specialized to take up dissolved organic matter from seawater. (Acropora Biological Review Team 2005; Peters 1984; Stachowitsch 1992)

Theca – wall of the skeletal cup ([corallite](#)) surrounding the scleractinian polyp. (Stachowitsch 1992)

Tinctorial – relating to coloring or staining. (Pharma 2006)

Tissue – a collection of similar cells and the intercellular substances surrounding them united in the performance of a particular function. Cnidaria possess all four of the basic tissues: (1) epithelium, (2) connective, (3) muscle, and (4) nerve. (Dorland 2006; Hyman 1940; Stedman 1995)

Transmural – see [Full Thickness](#)

Vacuole – a tiny fluid-filled cavity or a membrane-bound vesicle formed in the protoplasm of a cell. (Dorland 2006; Stedman 1995)

Vacuolated – having vacuoles. (Stedman 1995)

Vacuolization (or **Vacuolation**) – formation or multiplication of vacuoles. (Stedman 1995)

Zooxanthellae – dinoflagellates (unicellular photosynthetic organisms) that live within the [gastrodermal cells](#) of some scleractinians, octocorals, sea anemones and other animals (not cnidarians), which give corals a characteristic brown coloration. Zooxanthellae provide energy in the form of photosynthate, use animal wastes (nitrogenous ones and carbon dioxide) and, in calcifying organisms, enhance calcification. (Peters 1984)

Zymogen – Proenzyme, precursor of an enzyme requiring a change in the molecule to make it active. (Stedman 1995)

REFERENCES

- Bayer, F. M., M. Grasshoff, and J. Verseveldt. 1983. Illustrated Trilingual Glossary of Morphological and Anatomical Terms Applied to Octocorallia. Leiden: E.J. Brill, Dr. W. Backhuys.
- Bayer, F. M., and I. G. Macintyre. 2001. The mineral component of the axis and holdfast of some gorgonacean octocorals (Coelenterata: Anthozoa), with special reference to the family Gorgoniidae. *Proceedings of the Biological Society of Washington* **114**: 309-345.
- Boulon, R., M. Chiappone, R. Halley, W. Jaap, B. Keller, B. Kruczynski, M. Miller, and C. Rogers. 2005. 'Atlantic *Acropora* Status Review Document.' Report to National Marine Fisheries Service, Southeast Regional Office. March 3, 2005, p. 152 p + App.
- Brown, B. E., and J. C. Bythell. 2005. Perspectives on mucus secretion in reef corals. *Mar. Ecol. Prog. Ser.* **296**: 291-309.
- Carson, F. L. 1997. *Histotechnology: A Self-Instructional Text*. American Society of Clinical Pathologists.
- Chapman, D. M. 1974. Cnidarian Histology, p. 1-92. *In* L. Muscatine and H. Lenhoff [eds.], *Coelenterate Biology, Reviews and New Perspectives*. Academic Press.
- Coris. 2006. NOAA's Coral Reef Information System, Glossary.
- Dorland, W. A. N. 2006. *Dorland's Illustrated Medical Dictionary*. Saunders, W.B. .
- Duerden, J. 1902. West Indian madreporarian polyps. *National Academy of Sciences* **7**: 399-648.
- Fautin, D. G. 2005. *Interactive Glossary of Actinarian (Sea Anemone) Anatomical Terms*.
- Fautin, D. G., and R. N. Mariscal. 1991. Cnidaria: Anthozoa, p. 267-358. *In* F. W. Harrison and J. A. Westfall [eds.], *Placozoa, Porifera, Cnidaria, and Ctenophora. Microscopic Anatomy of Invertebrates*. Wiley-Liss.
- Glick, D. 2006. *Glossary of Biochemistry and Molecular Biology*.
- Goldberg, W. 2002a. Feeding behavior, epidermal structure and mucus cytochemistry of the scleractinian *Mycetophyllia reesi*, a coral without tentacles. *Tissue & Cell* **34**: 232-245.

- . 2002b. Gastrodermal structure and feeding responses in the scleractinian *Mycetophyllia reesi*, a coral with novel digestive filaments. *Tissue & Cell* **34**: 246-261.
- Goldberg, W. M. 1976. Comparative study of the chemistry and structure of gorgonian and antipatharian coral skeletons. *Marine Biology* **35**: 253-257.
- . 2001a. Acid polysaccharides in the skeletal matrix and calicoblastic epithelium of the stony coral *Mycetophyllia reesi*. *Tissue & Cell* **33**: 376-387.
- . 2001b. Desmocytes in the calicoblastic epithelium of the stony coral *Mycetophyllia reesi* and their attachment to the skeleton. *Tissue & Cell* **33**: 388-394.
- Goldberg, W. M., and G. T. Taylor. 1996. Ultrastructure of the spirocyst tubule in black corals (Coelenterata: Antipatharia) and its taxonomic implications. *Marine Biology* **125**: 655-662.
- Green, E. P., and A. W. Bruckner. 2000. The significance of coral disease epizootiology for coral reef conservation. *Biological Conservation* **96**: 347-361.
- Grimmelikhuijzen, C., and J. Westfall. 1995. The nervous systems of cnidarians. *EXS* **72**: 7-24.
- Hessinger, D. A., and H. M. Lenhoff. 1989. *The biology of nematocysts*. Academic Press.
- Holl, S. M., J. Schaefer, W. M. Goldberg, K. J. Kramer, T. D. Morgan, and T. L. Hopkins. 1992. Comparison of black coral skeleton and insect cuticle by a combination of carbon-13 NMR and chemical analyses. *Arch. Biochem. Biophys.* **292**: 107-111.
- Hyman, L. H. 1940. *The Invertebrates: Protozoa through Ctenophora*. McGraw-Hill Book Company.
- . 1967. *The Invertebrates. Mollusca* McGraw Hill.
- Leggat, W., M. R. Badger, and D. Yellowlees. 1999. Evidence for an Inorganic Carbon-Concentrating Mechanism in the Symbiotic Dinoflagellate *Symbiodinium* sp. *Plant Physiol.* **121**: 1247-1255.
- Mariscal, R. N. 1984. Cnidaria: Cnidae, p. 57-68. *In* J. Bereiter-Hahn, A. Matoltsy and K. S. Richards [eds.], *Biology of the Integument*. Springer-Verlag.
- Martindale, M. Q., K. Pang, and J. R. Finnerty. 2004. Investigating the origins of triploblasty: 'mesodermal' gene expression in a diploblastic animal, the sea anemone *Nematostella vectensis* (phylum, Cnidaria; class, Anthozoa). *Development* **131**: 2463-2474.
- Muscatine, L., E. Tambutte, and D. Allemand. 1997. Morphology of coral desmocytes, cells that anchor the calicoblastic epithelium to the skeleton. *Coral Reefs* **16**: 205-213.
- Peters, E. C. 1984. *A survey of the normal and pathological histology of scleractinian corals with emphasis on the effects of sedimentation stress*. Dissertation.
- . 2001. *Coral Tissue Slide Reading Workshop*.
- Petes, L. E., C. D. Harvell, E. C. Peters, M. A. H. Webb, and K. M. Mullen. 2003. Pathogens compromise reproduction and induce melanization in Caribbean sea fans. *Mar. Ecol. Prog. Ser.* **264**: 167-171.
- Pharma. 2006. *Medi-Lexicon, Medical Terms Dictionary*.
- Puverel, S., E. Tambutte, D. Zoccola, I. Domart-Coulon, A. Bouchot, S. Lotto, D. Allemand, and S. Tambutte. 2005. Antibodies against the organic matrix in

- scleractinians: a new tool to study coral biomineralization. *Coral Reefs* **24**: 149-156.
- Smith, C. B. 2004. Water clarity flux due to variable light intensity and its effects on fluorescent proteins of *Porites porites*: A hard coral from the tropical Western Atlantic. PhD dissertation. George Mason University.
- Sparks, A. K. 1985. *Synopsis of Invertebrate Pathology Exclusive of Insects*. Elsevier Science Publishers.
- Stachowitsch, M. 1992. *The Invertebrates: An Illustrated Glossary*. Wiley-Liss.
- Stedman, T. 1995. *Stedman's Medical Dictionary, 26th Edition* ed. Williams & Wilkins.
- Thomas, M. B., and N. C. Edwards. 1991. Cnidaria: Hydrozoa, p. 91-183. *In* F. W. Harrison and J. A. Westfall [eds.], *Placozoa, Porifera, Cnidaria, and Ctenophora. Microscopic Anatomy of Invertebrates*. Wiley-Liss.
- Tidball, J. G. 1982. An ultrastructural and cytochemical analysis of the cellular basis for tyrosine-derived crosslinks in *Leptogorgia virgulata* (Cnidaria: Gorgonacea). *Cell Tissue Res.* **22**: 635-645.
- Upton, S. J., and E. C. Peters. 1986. A new and unusual species of *Coccidium* (*Apicomplexa: Agamococcidiorida*) from Caribbean scleractinian corals. *J. Invertebr. Pathol.* **47**: 184-193.
- Wobeser, G. A. 1981. *Diseases of Wild Waterfowl*. Plenum Press.

AGENDA

Coral Disease and Health Workshop: Coral Histopathology II

Medical University of South Carolina (MUSC)
Department of Pathology and Laboratory Medicine
Walton Research Building
Room RS-106 & RS-107 Module 5
39 Sabin Street, Charleston, SC
July 11-14, 2005

Monday, July 11th

1:00-5:00 pm

ScanScope virtual slide scanning demonstration at MUSC for early arrivals (Aperio Technologies)

Evening

Reception - (Dr. Sylvia Galloway's House – James Island)

Tuesday, July 12th

8:30 am

Welcome – Cheryl Woodley, Ph.D. CDHC
NOAA NOS CCEHBR
Marine Biomedicine & Environmental Sciences
Debra Hazen-Martin, Ph.D. MUSC
Jim Nicholson, MUSC
Department of Pathology and Laboratory
Robert Ogilvie, Ph.D. MUSC
Department of Cell Biology and Anatomy

9:00 am

Introductions

Dr. Lou Sileo will outline the work plan and expected final products of the workshop:

- (1) An illustrated glossary of lesion descriptors and morphological diagnoses for coral lesions
- (2) Descriptions of the histopathology of specific "diseases" of coral

10:00-Noon

Demonstration of ScanScope virtual slide scanner

12:30-5:00 pm**

Coral Histopathology Review

Practicing coral histopathologists will review the microscopy of coral abnormalities. A glossary of lesion descriptors and morphologic diagnoses will be developed during this review – Facilitator, Dr. Lou Sileo.

- These reviews will be formatted from an organ perspective.
- The group will discuss and reach consensus on a conceptual framework for the 'blind' review of glass slides of coral lesions

Development of terminology for the description of coral lesions.

- Pathologists will begin private examination of the glass slides from the first selected lesion without reference to the history information followed by group discussions at the multi-headed scope with projection screen.
- A composite description of the lesion is formulated by the group for use in diagnostic criteria development. Once all individual observations have been synthesized into a composite description

of the lesion, photos of the gross lesion will be presented along with the field diagnosis.

Wednesday, July 13th

8:30-5:00 pm**

Continue 'blind' review, group discussions and description development of selected coral lesions (e.g., growth anomalies, disease, physical damage)

Thursday, July 14th

8:30-5:00 pm **

Continue 'blind' review, group discussions and description development of selected coral lesions (e.g., growth anomalies, disease, physical damage)




Compare and synthesize the descriptions of lesions from the same "disease"

Polish the 'glossary of lesion descriptors and morphologic diagnoses', and integrate these into the Diagnostic Key developed at Madison Workshop

Plan workshop report and website information

**May extend past 5pm on certain days as warranted.



 **CORAL HISTOPATHOLOGY WORKSHOP II**
Medical University of South Carolina, Department of Pathology, Charleston, SC
July 12-14, 2005  

WORKSHOP PARTICIPANTS (top left to bottom right): Valerie Bochsler, Sylvia Galloway, Russell Harley, Pam Parnell, Taylor Reynolds, Esther Peters, Louis Sileo, Cheryl Woodley, Carol Meteyer, Shawn McLaughlin, Frank Morado, Esti Kramarsky-Winter, David Rotstein, Thierry Work.

WORKSHOP PARTICIPANTS:

Valerie Shearn-Bochsler, DVM
USGS National Wildlife Health Center
6006 Schroeder Rd
Madison, WI 53711
Phone: (608) 270-2457
Fax: (608) 270-2415
Email: vbochsler@usgs.gov

Sylvia B. Galloway, PhD
NOAA/CCEHBR &
Marine Biomedicine and
Environmental Sciences Program
Medical University of South Carolina
221 Ft. Johnson Road
Charleston, SC 29412
Phone: (843) 953-0772
Fax: (843) 953-0774
Email: sylvia.galloway@noaa.gov

Russell Harley, MD
Pathology & Laboratory Medicine
MUSC Medical Center
165 Ashley Avenue
PO Box 250908
Charleston, SC 29425
Phone: (843) 792-4444
Email: harleyr@musc.edu

Esti Kramarsky-Winter, PhD
Dept. of Zoology
George S Wise Faculty of Life Sciences
Tel Aviv University
Tel Aviv, Israel 69978
Phone: 972-3-640-9809
Fax: 972-3-640-7682
Email: wintere@post.tau.ac.il

Shawn M. McLaughlin, PhD
NOAA National Ocean Service
904 S. Morris St.
Oxford, MD 21654
Phone: (410) 226-5193
FAX: (410) 226-5925
Email: shawn.mclaughlin@noaa.gov

Carol Uphoff Meteyer, DVM,
Diplomate ACVP
Wildlife Pathologist
USGS – National Wildlife Health Center
6006 Schroeder Rd
Madison, WI 53711
Phone: (608) 270-2462
Email: carol_meyer@usgs.gov

Frank Morado, PhD
NOAA, National Marine Fisheries Service
Alaska Fisheries Science Center
7600 Sand Point Way, N.E.
Seattle, WA 98115-0070
Phone: (206) 526-6572
Email: Frank.Morado@noaa.gov

Pamela G. Parnell, DVM, PhD,
Diplomate ACVP
Director, Clemson Veterinary Diagnostic Center
PO Box 102406
Columbia, SC 29224-2406
Phone: (803) 788-2260 ext 245
Fax: (803) 699-8910
Email: pprnll@CLEMSON.EDU

Esther Peters, PhD
4016 Whispering Lane
Annandale, VA 22003
Phone: (703) 642-1289
Email: esther.peters@verizon.net

Taylor Reynolds, DVM
Department of Pathobiology
Johns Hopkins University
School of Medicine
720 Rutland Avenue, Ross 558
Baltimore, MD 21205
Phone: (443) 287-3163
Email: treynol6@jhmi.edu

David S Rotstein, DVM, MPVM,
Diplomate ACVP
Assistant Professor, Department of Pathobiology
College of Veterinary Medicine
University of Tennessee
2407 River Drive, Room A201
Knoxville, TN 37996-4542
Phone: (865) 974-8205
Email: drotstein@mail.ag.utk.edu

Lou Sileo, PhD
USGS, National Wildlife Health Center
6006 Schroeder Rd.
Madison, WI 53711
Voice: (608) 270-2461
Fax: (608) 271-2415
Email: lou_sileo@usgs.gov

Cheryl Woodley, Ph.D.
DOC/NOAA/NOS/NCCOS
Center for Coastal Environmental
Health and Biomolecular Research
Hollings Marine Laboratory
331 Fort Johnson Rd
Charleston, SC 29412
Phone: (843) 762-8862
Fax: (843) 762.8737
Email: cheryl.woodley@noaa.gov

Thierry M. Work, DVM
USGS-National Wildlife Health Center
Honolulu Field Station
PO Box 50167
Honolulu, HI 96850
Phone: (808) 792-9520
Fax: (808) 792-9596
Cell: (808) 554-6490
Email: Thierry_work@usgs.gov

Support provided by:

Debra Hazen-Martin, PhD
Pathology & Laboratory Medicine
MUSC Medical Center
165 Ashley Avenue
PO Box 250908
Charleston, SC 29425
Phone: (843) 792-2906
Email: Hazenmad@musc.edu

Julie Higgins, MS
DOC/NOAA/NOS/NCCOS
Center for Coastal Environmental
Health and Biomolecular Research
Hollings Marine Laboratory
331 Fort Johnson Rd
Charleston, SC 29412
Phone: (843) 762-8959
Fax: (843) 762-8737
Email: julie.higgins@noaa.gov

James Nicholson
Pathology & Laboratory Medicine
MUSC Medical Center
165 Ashley Avenue
PO Box 250908
Charleston, SC 29425
Phone: (843) 792-4158
Email: micholsj@musc.edu

Robert W. Ogilvie, PhD
Department of Cell Biology and Anatomy
173 Ashley Avenue
MUSC Medical Center
P.O. Box 250508
Charleston, SC 29425
Phone: (843) 792-2667
Email: ogilvieb@musc.edu

Samantha Ryan
DOC/NOAA/NOS/NCCOS
Center for Coastal Environmental
Health and Biomolecular Research
Hollings Marine Laboratory
331 Fort Johnson Rd
Charleston, SC 29412

United States Department of Commerce

Carlos M. Gutierrez
Secretary

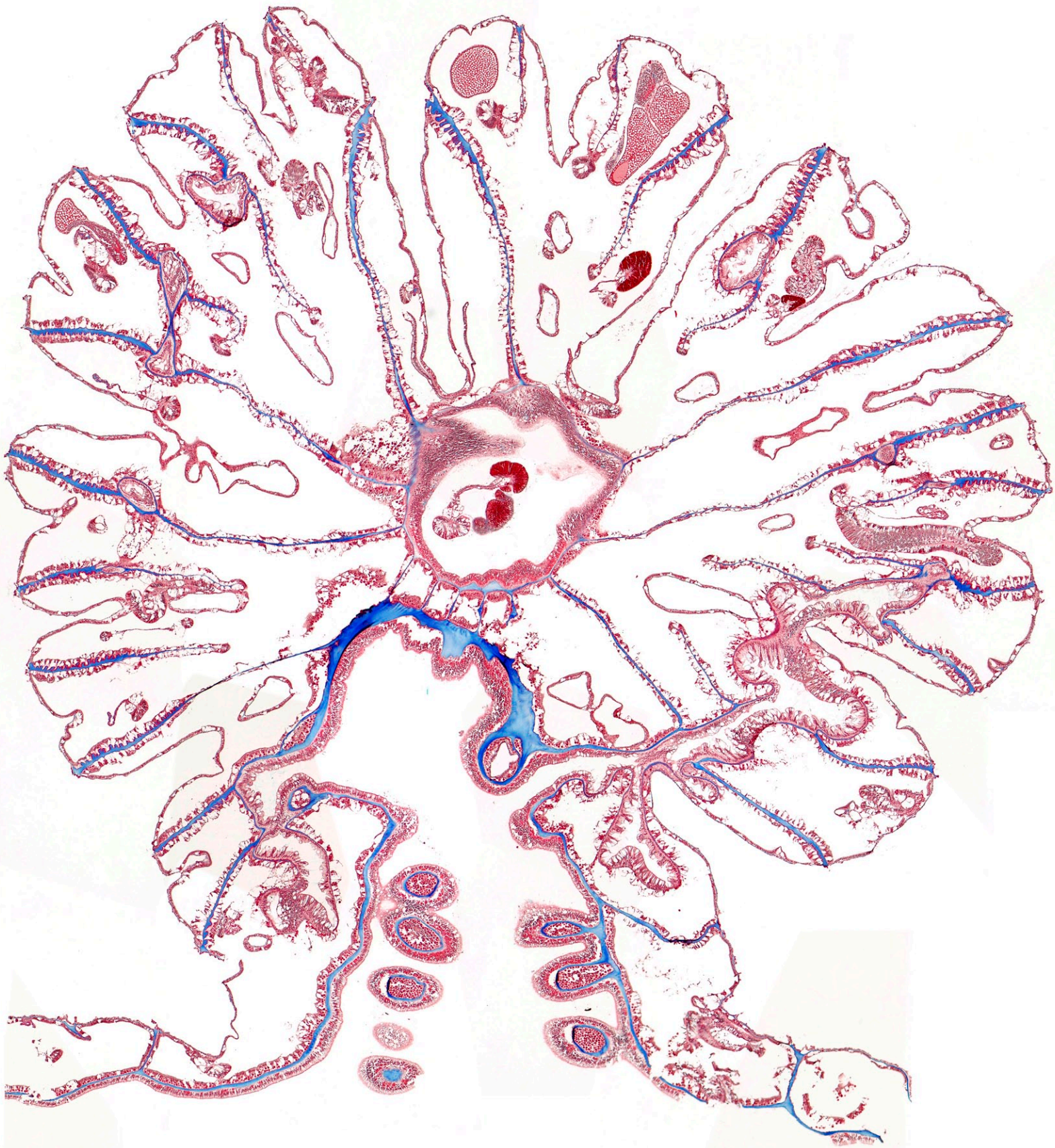
National Oceanic and Atmospheric Administration

Vice Admiral Conrad C. Lautenbacher, Jr. USN (Ret.)
Under Secretary of Commerce for Oceans and Atmosphere

National Ocean Service

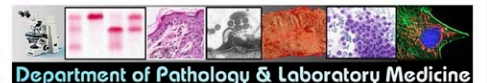John (Jack) H. Dunnigan
Assistant Administrator for Ocean Service and Coastal Zone Management





SPONSORED BY THE NATIONAL OCEANIC
AND ATMOSPHERIC ADMINISTRATION

MUSC
MEDICAL UNIVERSITY
OF SOUTH CAROLINA



Department of Pathology & Laboratory Medicine

HOSTED BY THE DEPARTMENT OF PATHOLOGY & LABORATORY MEDICINE
MEDICAL UNIVERSITY OF SOUTH CAROLINA, CHARLESTON, SC